



• THE BIG PICTURE •

# PATHOLOGY

WALTER L. KEMP | DENNIS K. BURNS | TRAVIS G. BROWN

Mc  
Graw  
Hill

**LANGE**

THE BIG PICTURE

**PATHOLOGY**

### **NOTICE**

Medicine is an ever-changing science. As new research and clinical experience broaden our knowledge, changes in treatment and drug therapy are required. The authors and the publisher of this work have checked with sources believed to be reliable in their efforts to provide information that is complete and generally in accord with the standards accepted at the time of publication. However, in view of the possibility of human error or changes in medical sciences, neither the authors nor the publisher nor any other party who has been involved in the preparation or publication of this work warrants that the information contained herein is in every respect accurate or complete, and they disclaim all responsibility for any errors or omissions or for the results obtained from use of the information contained in this work. Readers are encouraged to confirm the information contained herein with other sources. For example and in particular, readers are advised to check the product information sheet included in the package of each drug they plan to administer to be certain that the information contained in this work is accurate and that changes have not been made in the recommended dose or in the contraindications for administration. This recommendation is of particular importance in connection with new or infrequently used drugs.

# THE BIG PICTURE

## PATHOLOGY

### **Walter L. Kemp, MD**

Deputy State Medical Examiner  
Forensic Science Division, Montana State Department of Justice  
Missoula, Montana  
and  
Clinical Assistant Professor  
The University of Texas Southwestern Medical Center at Dallas  
Dallas, Texas

### **Dennis K. Burns, MD**

Professor of Pathology  
Distinguished Teaching Professor  
The University of Texas Southwestern Medical Center at Dallas  
Dallas, Texas

### **Travis G. Brown, MD**

Resident, Department of Family Medicine  
John Peter Smith Hospital  
Forth Worth, Texas



**Medical**

New York Chicago San Francisco Lisbon London Madrid Mexico City  
New Delhi San Juan Seoul Singapore Sydney Toronto



Copyright © 2008 by The McGraw-Hill Companies, Inc. All rights reserved. Manufactured in the United States of America. Except as permitted under the United States Copyright Act of 1976, no part of this publication may be reproduced or distributed in any form or by any means, or stored in a database or retrieval system, without the prior written permission of the publisher.

0-07-159379-9

The material in this eBook also appears in the print version of this title: 0-07-147748-9.

All trademarks are trademarks of their respective owners. Rather than put a trademark symbol after every occurrence of a trademarked name, we use names in an editorial fashion only, and to the benefit of the trademark owner, with no intention of infringement of the trademark. Where such designations appear in this book, they have been printed with initial caps.

McGraw-Hill eBooks are available at special quantity discounts to use as premiums and sales promotions, or for use in corporate training programs. For more information, please contact George Hoare, Special Sales, at [george\\_hoare@mcgraw-hill.com](mailto:george_hoare@mcgraw-hill.com) or (212) 904-4069.

#### TERMS OF USE

This is a copyrighted work and The McGraw-Hill Companies, Inc. ("McGraw-Hill") and its licensors reserve all rights in and to the work. Use of this work is subject to these terms. Except as permitted under the Copyright Act of 1976 and the right to store and retrieve one copy of the work, you may not decompile, disassemble, reverse engineer, reproduce, modify, create derivative works based upon, transmit, distribute, disseminate, sell, publish or sublicense the work or any part of it without McGraw-Hill's prior consent. You may use the work for your own noncommercial and personal use; any other use of the work is strictly prohibited. Your right to use the work may be terminated if you fail to comply with these terms.

THE WORK IS PROVIDED "AS IS." McGRAW-HILL AND ITS LICENSORS MAKE NO GUARANTEES OR WARRANTIES AS TO THE ACCURACY, ADEQUACY OR COMPLETENESS OF OR RESULTS TO BE OBTAINED FROM USING THE WORK, INCLUDING ANY INFORMATION THAT CAN BE ACCESSED THROUGH THE WORK VIA HYPERLINK OR OTHERWISE, AND EXPRESSLY DISCLAIM ANY WARRANTY, EXPRESS OR IMPLIED, INCLUDING BUT NOT LIMITED TO IMPLIED WARRANTIES OF MERCHANTABILITY OR FITNESS FOR A PARTICULAR PURPOSE. McGraw-Hill and its licensors do not warrant or guarantee that the functions contained in the work will meet your requirements or that its operation will be uninterrupted or error free. Neither McGraw-Hill nor its licensors shall be liable to you or anyone else for any inaccuracy, error or omission, regardless of cause, in the work or for any damages resulting therefrom. McGraw-Hill has no responsibility for the content of any information accessed through the work. Under no circumstances shall McGraw-Hill and/or its licensors be liable for any indirect, incidental, special, punitive, consequential or similar damages that result from the use of or inability to use the work, even if any of them has been advised of the possibility of such damages. This limitation of liability shall apply to any claim or cause whatsoever whether such claim or cause arises in contract, tort or otherwise.

DOI: 10.1036/0071477489



# Professional



## Want to learn more?

We hope you enjoy this McGraw-Hill eBook! If you'd like more information about this book, its author, or related books and websites, please [click here](#).

## DEDICATION

To my mom, dad, and sister, for your love, support, and encouragement.

To Julie Ann, for making me finally realize that spare time  
should be treasured and used wisely and not wasted.

To Kris, for sharing Montana with me.

To my good friend, Brian Kieffer, for showing me how an individual can persevere  
in the face of real and not imagined hardship, and that all the “rigors” of becoming a doctor  
are truly an imagined hardship when compared to the challenges others face.

—*Walter L. Kemp*

My small contribution to this work is dedicated with love and gratitude to my wife, Carol,  
and to my children, Kelly and Evan, my greatest sources of encouragement and inspiration.

—*Dennis K. Burns*

Dedicated to the memory of Earnest Franklin Brown (December 19, 1929–March 6, 2004)  
and to my friend and classmate Kelly Dianne Werlinger, MD (March 19, 1974–July 10, 2006).

—*Travis G. Brown*

*This page intentionally left blank*

## CONTENTS

<i>About the Authors</i> .....	viii	<b>CHAPTER 12</b> Hematopathology .....	173
<i>Acknowledgments</i> .....	ix	<b>CHAPTER 13</b> Pulmonary Pathology .....	209
<i>How to Use This Book</i> .....	x	<b>CHAPTER 14</b> Gastrointestinal Pathology .....	231
<b>CHAPTER 1</b> Cellular Pathology .....	1	<b>CHAPTER 15</b> Pathology of the Liver, Gallbladder, and Pancreas .....	261
<b>CHAPTER 2</b> Inflammation and Repair .....	13	<b>CHAPTER 16</b> Pathology of the Kidney and Bladder .....	283
<b>CHAPTER 3</b> Pathology of the Immune System ...	23	<b>CHAPTER 17</b> Pathology of the Male and Female Reproductive Tract and Breast .....	309
<b>CHAPTER 4</b> Neoplasia .....	35	<b>CHAPTER 18</b> Endocrine Pathology .....	337
<b>CHAPTER 5</b> Environmental and Nutritional Pathology .....	47	<b>CHAPTER 19</b> Pathology of the Bones and Joints .....	361
<b>CHAPTER 6</b> Genetic Disorders .....	55	<b>CHAPTER 20</b> Dermatopathology .....	379
<b>CHAPTER 7</b> Pediatric Pathology .....	71	<b>CHAPTER 21</b> Practice Examination .....	391
<b>CHAPTER 8</b> Hemodynamics .....	81	Answers .....	413
<b>CHAPTER 9</b> Vascular Pathology .....	93	<i>Index</i> .....	423
<b>CHAPTER 10</b> Cardiac Pathology .....	109		
<b>CHAPTER 11</b> Neuropathology .....	133		

## ABOUT THE AUTHORS

**Walter L. Kemp, MD**, completed his residency in Anatomic and Clinical Pathology and fellowship in Forensic Pathology at The University of Texas Southwestern Medical Center in Dallas, Texas. After completing his forensic fellowship, he was appointed Assistant Professor at UT Southwestern, where he taught for two years. In each of his two years as a faculty member, he received one of the Outstanding Teacher awards given by the second-year medical students. He is currently the Deputy State Medical Examiner in his home state of Montana, and continues to teach a two-week pathology course in the summer at UT Southwestern.

**Dennis K. Burns, MD**, is a full-time faculty member at The University of Texas Southwestern Medical Center, where he currently serves as Associate Director of the Division of Neuropathology, co-director of the first year medical neuroscience course, and director of the second year pathology

course. In 2006, Dr. Burns was elected to the University of Texas Southwestern Academy of Teaching and to the University of Texas Academy of Health Science Education, and he received the title of Distinguished Teaching Professor. For his efforts, Dr. Burns has been awarded fourteen teaching awards by medical students and pathology residents at The University of Texas Southwestern Medical Center.

**Travis G. Brown, MD**, is a graduate of The University of Texas Southwestern Medical School in Dallas, Texas, and is currently a resident in the Department of Family Medicine at John Peter Smith Hospital in Fort Worth, Texas. He has served as a teaching assistant for the second-year pathology course, a course instructor for the USMLE examinations, and continues to teach the pathology section of the **spring** USMLE preparation course at UT Southwestern.



## ACKNOWLEDGMENTS

To me, success in life is the result of many people's contributions, and this book is the result of the contributions of many people who have knowingly or unknowingly helped in this pursuit. Having the chance to write this book is one pinnacle of my career, and I would like to acknowledge and thank everyone who helped me reach this point.

To all of my grade school, junior high, and high school teachers for giving me an excellent background for college. To my high school English teacher Rose Goyen for proofreading my draft manuscript. To my college professors, most notably Father Joseph Harrington and Dr. John Addis, for giving me the best preparation possible for medical school.

To Dr. Tom Nicholas for calling me in to watch an autopsy, an experience that I had not signed up for but one that instantly decided my career path. To Drs. Kenneth Sims, William "Bill" Hunter, and Gary Dale for guiding my initial steps into pathology as a career. To Drs. Jeffrey Barnard, Joe Prahlow, Dave Dolinak, Joseph Guileyardo, and Steve Cohle for their willingness to do more than was required of them to further my education in autopsy and forensic pathology. To all of the pathologists at University of Texas Southwestern (UTSW) for giving me a broad and firm knowledge base in pathology. To Dr. Reade Quinton for pulling me out of the dark ages and teaching me that digital photography is a useful tool.

To Drs. Al Hesser and Ramiah Subramanian for supporting and encouraging my initial teaching efforts. To Dr. Swapan Nath for having faith in my teaching efforts and recommending me to Jason Malley as an author for this book.

To Jason Malley and McGraw-Hill for accepting my book proposal, and for guiding my efforts in the publication of this book. To Susan Kelly for her editorial expertise and constructive comments. And, to everyone at McGraw-Hill who turned the finished manuscript and images into the final product.

To Bill Unger, Dr. Gary Dale, and the Montana State Department of Justice for bringing me back to my home state of Montana. Lolo Peak, Mt. Sentinel, and the Bitterroot Mountains provided wonderful scenic inspiration for me while I wrote this book.

Although I created the majority of the images used in this text, I thank colleagues Drs. Janis Townsend-Parchman, Sheila Spotswood, Jill Urban, Gary Dale, Steve Cohle, Dominick Cavuoti, and Sean Hussey for contributing images that were not in my own collection. To Hamo Muergerditchian, Erin Duddleston, J.B. Watts, Sidney Eakin, Pamela Steger, and the other

Dallas County Medical Examiner autopsy technicians for helping me take pictures, and to Beth McHenry, for taking some of the pictures used in the book. To Beverly Shackelford and Dr. Ramiah Subramanian for providing me the medical student glass slide study set to photograph. To Drs. Brad Barker, Jeffrey Barnard, Dave Dolinak, Buddy Fuda, Brian Levenson, Joni McClain, Keith Pinckard, Reade Quinton, Steven Kroft, Joseph Zhou, and Lynn Salzberger for allowing me to photograph their cases.


To Jesse Yanes, UTSW medical student, for reading a draft and offering helpful suggestions to improve the manuscript.

To Dr. Travis Brown, for his contributions and knowledge of clinical medicine, for sharing his recent test-taking expertise, for his strong continuing interest in pathology, and for his willingness to join this project at a late stage, coordinating his efforts with the demands of his busy residency program.

To Dr. Dennis Burns for being an outstanding mentor, colleague, and friend to a young pathologist and for his work on Chapters 1, 2, 4, 6, 8, 9, 10, 11, and 18.

Finally, to all the medical students I have had the privilege to work with for encouraging and promoting my enthusiasm for pathology and for teaching. And, to all the patients, who, through their deaths, have educated me, and who will continue to help teach future physicians. Thank you.

—Walter L. Kemp



*Libby, Montana, at the base of the Cabinet Mountains*

## HOW TO USE THIS BOOK

This pathology text offers medical students a concise and organized (i.e., “Big Picture”) approach to the presentation of information needed for second-year medical school pathology courses and for study for the USMLE Step 1 licensing examination. In addition, pathology residents as well as other residents and physicians who want to brush up on their pathology may find the text useful.

*Pathology: The Big Picture* includes several features to facilitate learning and comprehension of the material.

- Outline format discussion of pathologic conditions, with each condition’s features divided by subheadings to promote access of information through an organized approach to each topic.
- About 435 four-color images depicting important gross and microscopic pathologic conditions, complete with a detailed figure legend that explains the pathologic features and clinical presentation of the condition.
- Integration of pathology and clinical information in support of the ongoing trends in medical education.
- About 60 succinct tables highlighting key points (i.e., often those requiring memorization), as well as key comparison and contrast tables.
- Practice examination of 130 questions, with clinical scenarios, and answers explained in relevant detail. In addition, 20 questions utilize images of common pathologic conditions with classic features.

Although the text is extensive, it primarily highlights common and uncommon conditions and common and uncommon causes of those conditions. Remember that the text is not an exhaustive source for material, and should be used as a review book or as a supplemental source to a general pathology textbook.

A scanning electron micrograph (SEM) showing a highly textured, three-dimensional surface of a cell. The surface is covered in numerous small, rounded protrusions and deep, irregular folds, giving it a complex, almost crystalline appearance. The lighting creates strong highlights and shadows, emphasizing the topography of the cell's exterior.

# CHAPTER 1

## CELLULAR PATHOLOGY

### OVERVIEW

**Pathology**, in the broadest terms, is the **study of disease**. Disease occurs for many reasons. Some diseases represent spontaneous alterations in the ability of a cell to proliferate and function normally, and in other cases, disease results when external stimuli produce changes in the cell's environment that make it impossible for the cell to maintain homeostasis. In such situations, cells must adapt to the new environment. These adaptations include **hyperplasia**, **hypertrophy**, **atrophy**, and **metaplasia**, and can be physiologic or pathologic, depending upon whether the stimulus is normal or abnormal. A cell can adapt to a certain point, but if the stimulus continues beyond that point, failure of the cell, and hence the organ, can result. If cells cannot adapt to the pathologic stimulus, they can die. This chapter will discuss cellular adaptation, cell injury, cellular accumulations, and cellular aging.

### CELLULAR ADAPTATION

**Overview:** The four basic types of cellular adaptation to be discussed in this section are hyperplasia, hypertrophy, atrophy, and metaplasia.

#### HYPERPLASIA

**Basic description:** Increase in the number of cells.

##### Types of hyperplasia

- **Physiologic hyperplasia:** Occurs due to a normal stressor. For example, increase in the size of the breasts during pregnancy, increase in thickness of endometrium during menstrual cycle, and liver growth after partial resection.
- **Pathologic hyperplasia:** Occurs due to an abnormal stressor. For example, growth of adrenal glands due to production of adrenocorticotrophic hormone (ACTH) by a pituitary adenoma, and proliferation of endometrium due to prolonged estrogen stimulus.

**Important point regarding hyperplasia:** Only cells that can divide will undergo hyperplasia; therefore, hyperplasia of the myocytes in the heart and neurons in the brain does *not* occur.



## HYPERTROPHY

**Basic description:** Increase in the size of the cell.

### Types of hypertrophy

- **Physiologic hypertrophy:** Occurs due to a normal stressor. For example, enlargement of skeletal muscle with exercise.
- **Pathologic hypertrophy:** Occurs due to an abnormal stressor. For example, increase in the size of the heart due to aortic stenosis. Aortic stenosis is due to a change in the aortic valve, which obstructs the orifice, resulting in the left ventricle working harder to pump blood into the aorta.

**Morphology of hyperplasia and hypertrophy:** Both hyperplasia and hypertrophy result in an increase in organ size; therefore, both cannot always be distinguished grossly, and microscopic examination is required to distinguish the two (Figure 1-1).

**Mechanisms by which hyperplasia and hypertrophy can occur:** Up regulation or down regulation of receptors and induction of new protein synthesis. The two processes can occur together. For example, up regulation of receptors results in the induction of new protein synthesis; or up and down regulation of receptors and induction of new protein synthesis can occur as independent processes. The types of new proteins induced include transcription factors (e.g., c-Jun, c-Fos), contractile proteins (e.g., myosin light chain), and embryonic proteins (e.g.,  $\beta$ -myosin heavy chain).

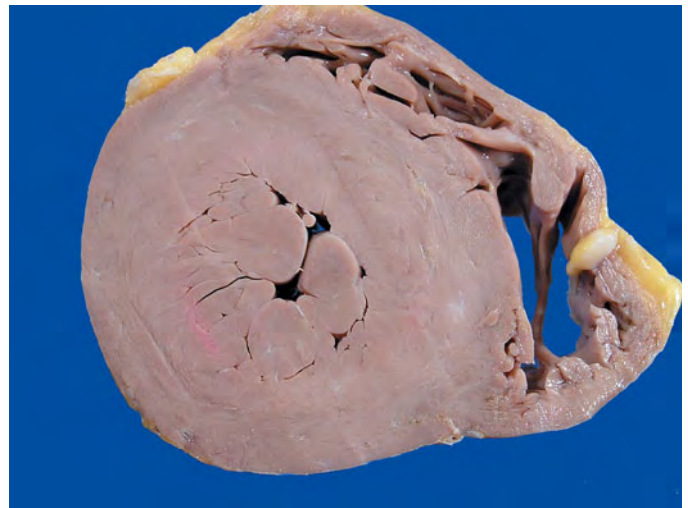
## ATROPHY

**Basic description:** Decrease in the size of a cell that has at one time been of normal size.

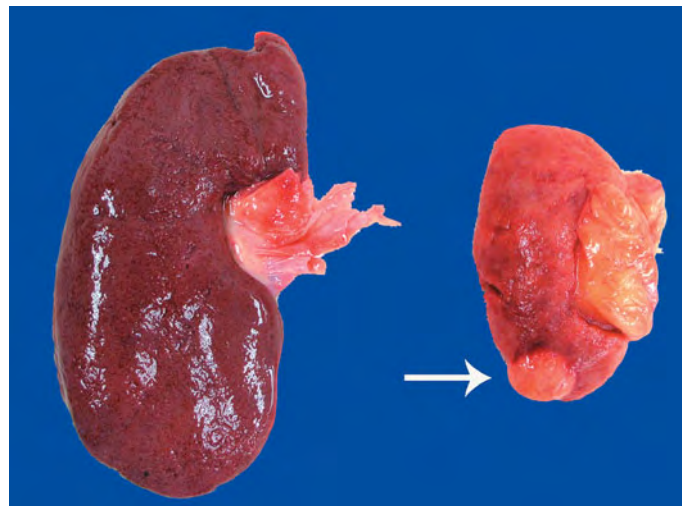### Types of atrophy

- **Physiologic atrophy:** Occurs due to a normal stressor. For example, decrease in the size of the uterus after pregnancy.
- **Pathologic atrophy:** Occurs due to an abnormal stressor. In general, atrophy is due to the loss of stimulus to the organ. Specific types of loss of stimulus include loss of blood supply or innervation, loss of endocrine stimulus, disuse, mechanical compression, decreased workload, or aging.

**Gross morphology of atrophy (Figure 1-2):** The organ is smaller than usual. Atrophy occurs in a once normally developed organ. If the organ was never a normal size (i.e., because it did not develop normally), the condition is called **hypoplasia**.



**Figure 1-1.** Cross-section of the heart of a patient with systemic hypertension. The patient had high blood pressure, which increased the workload of the left ventricle and resulted in concentric hypertrophy of the left ventricular myocardium. In response to the increasing pressure load, the cardiac myocytes increased their content of contractile proteins, resulting in enlargement of individual myocytes.



**Figure 1-2.** Kidneys from two different patients. The kidney on the left is normal in size, whereas the kidney on the right is atrophic. The kidney on the right was from a patient who had severe atherosclerosis of the renal artery, which led to ischemia (i.e., decreased perfusion) of the organ. Due to an insufficient supply of oxygen and nutrients, the cells of the kidney decreased in size to adapt. An incidental renal cell carcinoma is visible near the pole of the atrophic kidney (arrow).

## METAPLASIA

**Basic description:** Change of epithelium at a site, or location, from one type of epithelium to another type. In metaplasia, the epithelium is normal in appearance but in an abnormal location.

**Mechanism of metaplasia:** The epithelium normally present at a site cannot handle the new environment so it converts to a type of epithelium that can adapt.

**Examples:** Barrett esophagus is due to reflux of gastric contents into the esophagus, which causes the epithelium type to convert from squamous to glandular (Figure 1-3 A and B). Squamous metaplasia in the lungs is due to exposure of respiratory epithelium to toxins in cigarette smoke.

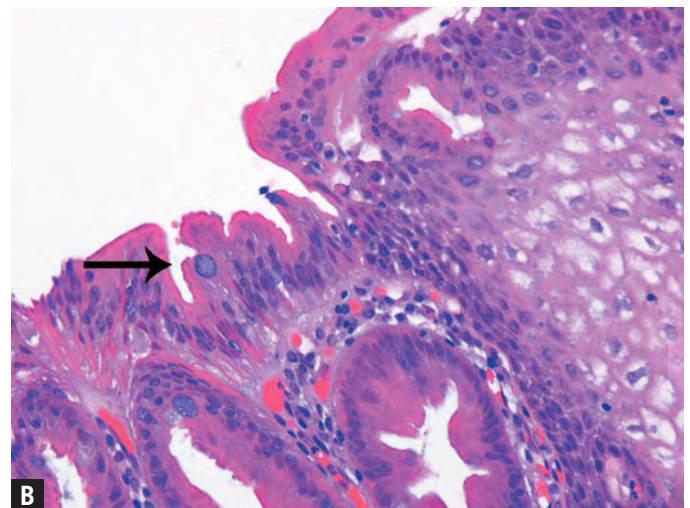
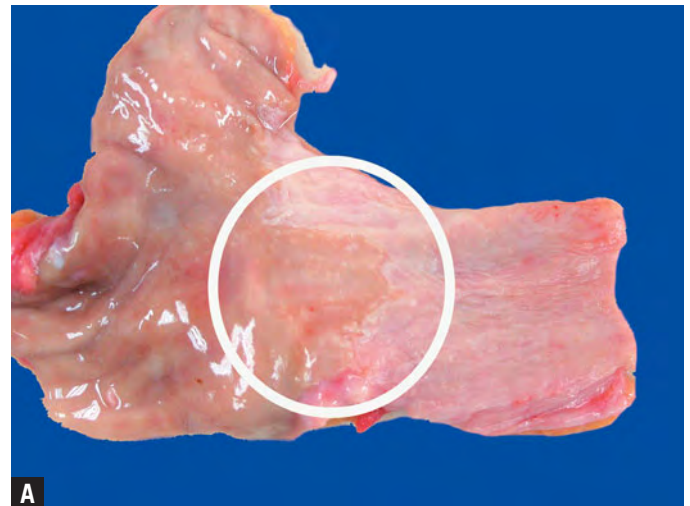
## CELL INJURY

**Overview:** Cell injury occurs when the cells cannot adapt to their new environment.

**Causes of cell injury:** Hypoxia (decreased oxygen), ischemia (decreased blood flow), physical and chemical agents, trauma, infectious agents, radiation and toxins, metabolic abnormalities (genetic or acquired), immune dysfunction (hypersensitivity reactions and autoimmune disease), aging, and nutritional imbalances.

### Important points regarding cell injury

- Hypoxia and ischemia are two common sources of cellular injury. Of the two, ischemia is much more damaging because it involves hypoxia plus a lack of other nutrients and an accumulation of toxic cellular metabolites.
- When does injury occur? This varies from cell to cell. It depends upon the type, duration, and severity of injury, and the type, adaptability, and makeup of the affected cell.
- Cellular injury may or may not result in the death of the cell. Four cellular systems are especially vulnerable to cellular injury, and include:
  1. DNA
  2. Cell membranes
  3. Protein generation
  4. Adenosine triphosphate (ATP) production
- Although some of the causes of cellular injury have specific mechanisms, the mechanism of cellular injury due to many substances is not understood.



**Figure 1-3.** Barrett esophagus (glandular metaplasia). **A**, This specimen is taken from the region of the gastroesophageal junction and includes a segment of proximal stomach (on the left side) in continuity with the distal esophagus (on the right side). A small patch of mucosa with an appearance similar to the gastric mucosa extends proximally (*circle*), above the gastroesophageal junction. In this area, the normal stratified squamous epithelium of the esophagus has been replaced by glandular epithelium. Glandular metaplasia of the esophagus occurs in response to gastric acid reflux. **B**, The right side of the image shows stratified squamous epithelium, and the left side shows glandular epithelium, with goblet cells present (*arrow*). Transformation of one type of tissue to another type of tissue is termed metaplasia; in this case, stratified squamous epithelium was transformed to intestinal-type epithelium. Hematoxylin and eosin, 200 $\times$ .

### Mechanisms of cellular injury

1. **Hypoxia:** In general, decreased oxygen results in decreased production of ATP. ATP is normally required by the Na/K<sup>+</sup> pump and Ca<sup>2+</sup> pump. When ATP levels decrease, these pumps fail and sodium (along with water, which follows sodium) enters the cell, causing swelling. Also, calcium enters the cell, which activates endonucleases, proteases, phospholipases, and DNAses, which damage the cell. Cells switch to anaerobic respiration to produce ATP, which results in accumulation of lactic acid. The accumulation of lactic acid decreases the cellular pH. Decreased pH causes disaggregation of ribosomes from endoplasmic reticulum.
2. **Generation of oxygen-derived free radicals by a stressing agent**

**Basic description of free radical:** A free radical is a molecule with an unpaired electron in the outer orbit. Another term for oxygen-derived free radicals is **reactive oxygen species**.

**How free radicals are generated:** Free radicals are generated by normal physiologic reduction-oxidation reactions, ultraviolet light, x-rays and ionizing radiation, and transitive metals. Also, metabolism of exogenous chemicals, such as carbon tetrachloride, induces formation of reactive oxygen species.

**Damage by free radicals:** Lipid peroxidation (damages cell membranes), DNA fragmentation, and protein cross-linking (e.g., sulfhydryl groups), which results in increased degradation and decreased activity.

### Methods to prevent formation of reactive oxygen species

- **Catalase**, which degrades hydrogen peroxide.
  - **Superoxide dismutase**, which converts superoxide to hydrogen peroxide.
  - **Glutathione**, which catalyzes breakdown of hydroxyl radicals.
  - **Vitamins A, C, and E**, which have an antioxidant effect.
3. **Chemical injury:** Some chemicals are directly toxic to the cells, and others require conversion to a toxic metabolite. For example, ethylene glycol (antifreeze) is not toxic, but its metabolite, oxalic acid, is. In contrast, cyanide directly inactivates cytochrome oxidase, which impairs the formation of ATP.
  4. **Increased mitochondrial cytosolic calcium:** Increased mitochondrial cytosolic calcium leads to lipid peroxidation and formation of mitochondrial permeability transition (a nonselective pore that dissipates the proton gradient). Also, increased mitochondrial cytosolic calcium causes release of cytochrome c, which in turn activates apoptosis.

### Two types of cellular injury

- **Reversible cellular injury:** As described above in the discussion of mechanisms of cellular injury, the decreased production of ATP causes sodium to enter the cell, bringing water and causing cellular and organelle swelling. The conversion from aerobic to anaerobic respiration decreases the pH of the cell. These changes are all reversible. If ATP is once again produced by the cell, the Na/K<sup>+</sup> ratio and pH will be corrected.



- **Irreversible cellular injury:** This type of injury occurs with damage to plasma or lysosomal membranes, loss of DNA, or loss of mitochondria. In these cases, the damage cannot be reversed. The two most important factors determining irreversible damage are membrane disturbances and the inability to reverse mitochondrial dysfunction.

#### Light microscope morphologic changes of cellular injury

- **Reversible injury:** Cellular swelling and fatty change.
- **Irreversible injury:** **Nuclear karyolysis** (loss of basophilia), **pyknosis** (shrinkage of nucleus), and **karyorrhexis** (fragmentation of nucleus).

#### Electron microscope morphologic changes of cellular injury

- **Reversible injury:** Cellular blebs and small mitochondrial densities.
- **Irreversible injury:** Ruptured lysosomes, myelin figures (which indicate phospholipid precipitation), lysis of endoplasmic reticulum, and large calcium rich mitochondrial densities.

## CELL DEATH

**Overview:** There are two forms of cell death, **apoptosis** and **necrosis**. Apoptosis is controlled (programmed) breakdown of cells occurring in response to damage to DNA or as part of normal growth and development. Necrosis is uncontrolled breakdown of cells in response to injurious stimuli.

### APOPTOSIS

**Basic description:** Programmed cell death.

#### Patterns of occurrence of apoptosis

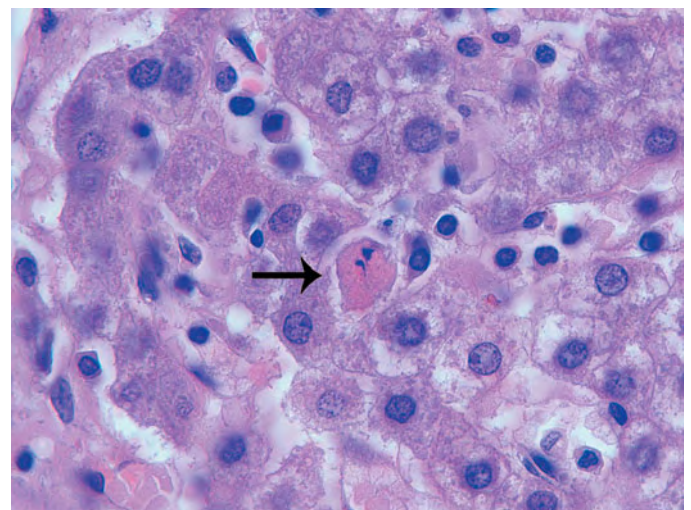
- During growth and development, some cells serve a function in the growth phase but need to be removed after their purpose is fulfilled. In neonates, a rapid cell growth rate is necessary; in adults, however, unrestrained cell growth can lead to cancer.
- When DNA sustains irreparable damage (e.g., after low-dose radiation exposure), the cell must be destroyed so mutations that have developed will not be propagated. In this manner, apoptosis serves as a safety step by removing damaged cells from the body.

#### Phases of apoptosis

- **Initiation** is the phase in which **caspases** (cysteine aspartic acid proteases) become catalytically active.
- **Execution** is the phase in which the action of caspases causes death of cell.

**Mechanism of apoptosis:** There are multiple pathways by which apoptosis is initiated, including the extracellular and intracellular pathways. Both pathways share similar endpoints, culminating with the use of caspases and prevention of inflammatory reaction.

- **Initiation of extracellular pathway:** In Fas-Fas ligand binding, the Fas ligand binds to a member of the tumor necrosis



**Figure 1-4.** Acidophil body in the liver. The acidophil body (arrow) represents apoptosis, or programmed cell death. The nucleus is condensed and fragmented, and no inflammatory reaction has been elicited. Hematoxylin and eosin, 1000×.

factor family known as the Fas receptor. The activated Fas receptor in turn activates FADD (*Fas-associated death domain*), which in turn activates caspases.

- **Initiation of intracellular pathway:** The mitochondria release cytochrome c, which combines with Apaf-1 (*apoptosis activating factor-1*) to activate caspases.
- Caspases, which cleave DNA, are activated. DNA is cleaved in a coordinated manner so the fragments, if analyzed on a gel, will form a ladder. In contrast, in necrosis (an uncoordinated breakdown of DNA), the gel will be a smear.
- Apoptosis does not generate an inflammatory reaction as necrosis does. Fragments of cells express phosphatidyl serine, which is recognized by macrophages; therefore, fragments can be engulfed without generating an inflammatory reaction.

**Morphology of apoptosis:** The key feature microscopically is chromatin condensation and fragmentation (Figure 1-4).

## NECROSIS

**Basic description:** Necrosis is a term used to describe uncontrolled death of cells due to one of the various causes of cellular injury.

**Gross morphology of necrosis:** Necrosis is typically manifested by softening and discoloration of the organ. Other processes can have a similar appearance, so the gross appearance of necrosis is not specific.

**Microscopic morphology of necrosis:** The two main types of necrosis are coagulative necrosis and liquefactive necrosis; however, there are several other variants.

### ■ Coagulative necrosis

**Basic description:** Coagulative necrosis is the type of necrosis in which protein denaturation is more prominent than enzymatic breakdown.

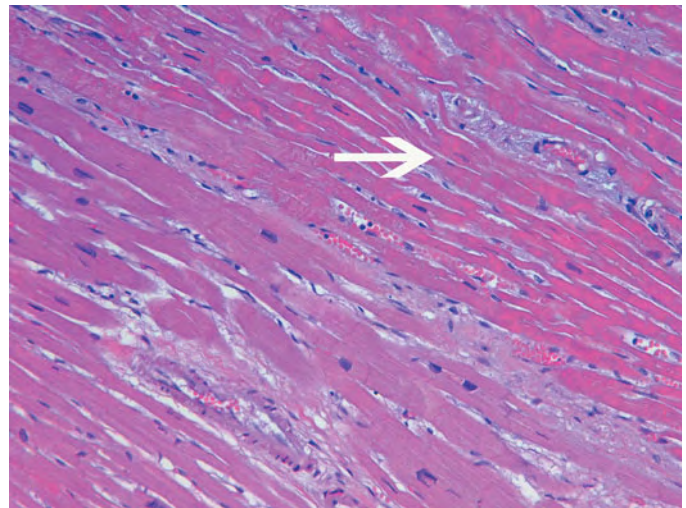
**Microscopic morphology of coagulative necrosis (Figure 1-5):** There is increased eosinophilia of the cytoplasm and decreased basophilia of the nucleus; both are associated with preservation of the general cellular architecture (the organ type is identifiable).

**Organs affected by coagulative necrosis:** Coagulative necrosis may occur in any organ. In organs with a high fat content, such as the brain, coagulative necrosis is followed rapidly by liquefactive necrosis.

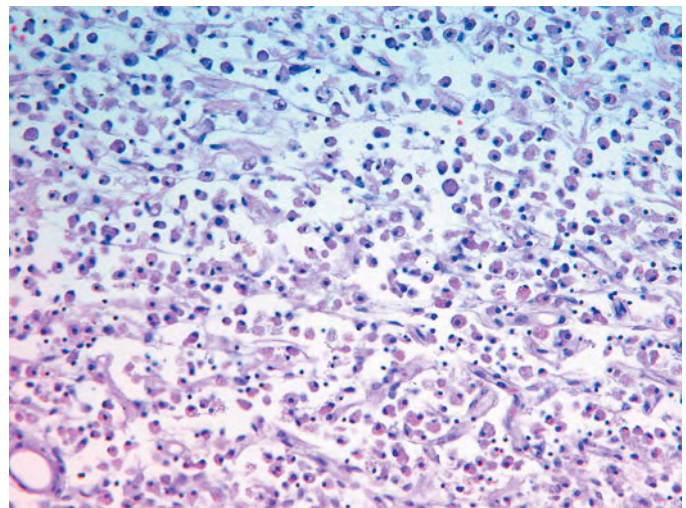
### ■ Liquefactive necrosis

**Basic description:** Liquefactive necrosis occurs in situations in which enzymatic breakdown is more prominent than protein denaturation or in organs that lack a substantial protein-rich matrix (e.g., lipid-rich organs such as the brain).

**Microscopic morphology of liquefactive necrosis (Figure 1-6):** There is loss of organ cellular architecture. In liquefactive necrosis of the brain, there are sheets of lipid-laden macrophages that replace the dead tissue.



**Figure 1-5.** Coagulative necrosis of the myocardium. In the right upper half of the image (*arrow*), the cellular architecture is preserved; however, the cells are necrotic. The cytoplasm is eosinophilic from loss of protein, which imparts basophilia, and karyolysis of the nuclei has occurred (few cardiac myocyte nuclei are visible). Compare these features to the cells in the left lower half of the figure, which represent non-necrotic cardiac myocytes. Hematoxylin and eosin, 200×



**Figure 1-6.** Liquefactive necrosis of the brain. The field contains sheets of foamy macrophages. In contrast to coagulative necrosis, the native tissue architecture has been lost. The foamy macrophages contain engulfed lipid-rich myelin and cellular debris. Liquefactive necrosis is common in tissues with relatively low protein content (e.g., the brain) or in situations where there is a high local concentration of proteolytic enzymes (e.g., abscesses; necrosis of pancreatic tissue). Hematoxylin and eosin, 200×



**Organs affected by liquefactive necrosis:** Liquefactive necrosis is most commonly associated with organs that have a high fat and low protein content (e.g., the brain), or those with a high enzymatic content (e.g., the pancreas).

■ **Fat necrosis:** Fat necrosis is a term applied to a change in adipose tissue due to trauma or the release of enzymes from adjacent organs (e.g., the pancreas). The trauma or enzymatic action causes a breakdown of lipid and a release of fatty acids, which combine with calcium to form chalky deposits.

■ **Caseous necrosis (Figure 1-7 A and B):** Caseous necrosis is a “cheesy-looking” necrosis associated with tuberculosis infections and other granulomatous disease processes. Granulomas are a form of chronic inflammation due to some infections (e.g., mycobacterial), foreign bodies, and other chronic stimuli.

#### Important points regarding necrosis

- The terms coagulative and liquefactive necrosis are not mutually exclusive. For example, the death of heart muscle begins as coagulative necrosis, but once neutrophils enter the tissue as part of an inflammatory reaction and release enzymes, cellular architecture is lost (more consistent with liquefactive necrosis).
- Cell death involves the release of intracellular enzymes into blood. These enzymes in the blood can be measured and used clinically to detect disease.
- Cell death affects morphology (the shape of the cell) and function. Morphologic changes (both gross and microscopic) can develop over a period of time, while loss of function may occur almost immediately. Because of this immediate loss of function, the clinical manifestations of cellular injury may be present before the morphologic changes occur.

## CELLULAR ACCUMULATIONS

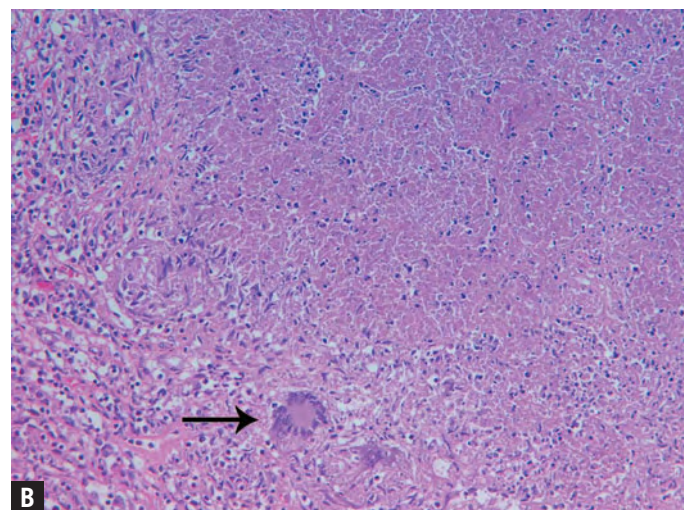
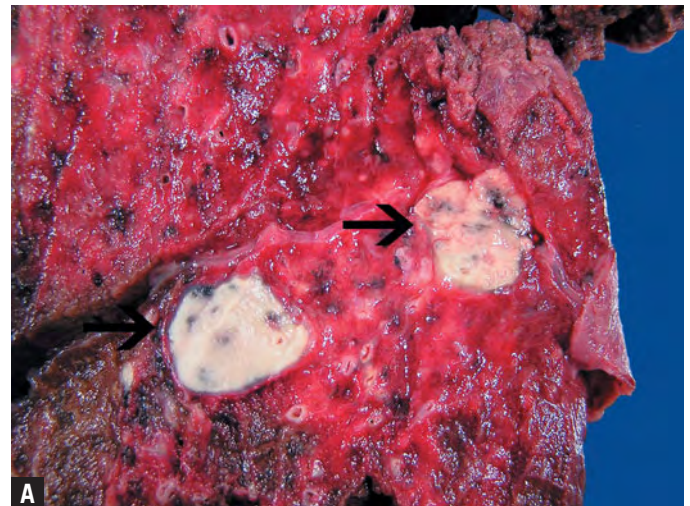
**Overview:** Substances can accumulate in cells as a result of damage to the cell, or they can accumulate in the cells as the result of an intrinsic abnormality in metabolic function (e.g., genetic disease). The accumulation of substances in a cell may or may not cause damage to the cell. Substances that commonly accumulate are **lipofuscin** (also referred to as wear-and-tear pigment), calcium, protein, iron, fat, cholesterol, glycogen, and pigments.

**General mechanisms of cellular accumulations:** Include acquired or hereditary enzymatic defects, deposition of exogenous substances, and decreased metabolism of substances, which then accumulate.

### LIPOFUSCIN

**Basic description:** Wear-and-tear pigment.

**Mechanism of formation:** Lipofuscin is a product of lipid peroxidation, which accumulates in lysosomes as the cell ages. The cell cannot rid itself of these lipofuscin-laden lysosomes.



**Figure 1-7.** Caseous necrosis of the lung due to pulmonary tuberculosis. **A**, Gross section. The soft, cheese-like nature of the process is apparent (arrows). **B**, Microscopic section. The right side of the section shows central necrosis, and the left side shows large, activated (“epithelioid”) histiocytes and a multinucleated giant cell (arrow). As in the case of liquefactive necrosis, tissue architecture is completely obliterated in foci of caseous necrosis. Hematoxylin and eosin, 200×.

**Organs with lipofuscin accumulation:** The most common organs where lipofuscin accumulates are the heart and liver.

**Gross morphology of lipofuscin accumulation:** Lipofuscin accumulation can impart brown discoloration to organ. Such organs may also be atrophic, giving rise to the term “**brown atrophy**.”

**Microscopic morphology of lipofuscin accumulation (Figure 1-8):** Finely granular, yellow-brown pigment, which often surrounds the nucleus.

### CALCIUM ACCUMULATION

**Two forms of calcium deposition:** Metastatic and dystrophic

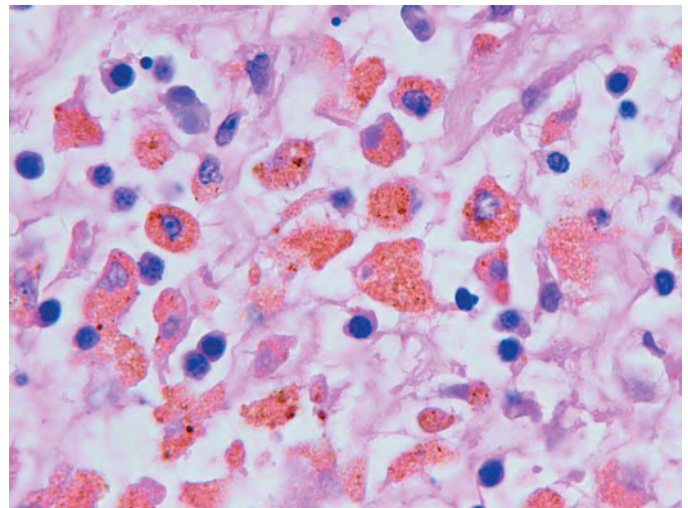
**Mechanism of metastatic calcification:** Patients who have hypercalcemia have deposition of the calcium within normal or abnormal tissue. Some causes of hypercalcemia include increased parathyroid hormone (PTH) by a parathyroid adenoma or parathyroid gland hyperplasia; destruction of bone by tumors, vitamin D intoxication, or renal failure; and **sarcoidosis**, where macrophages activate vitamin D precursor.

**Mechanism of dystrophic calcification:** Patients who have normal levels of calcium have deposition of the calcium only within abnormal tissue, such as necrotic tissue.

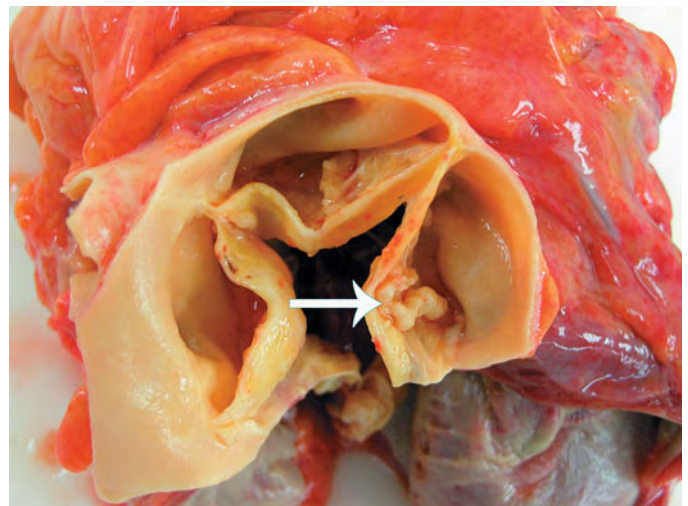
**Organs most commonly affected by calcium accumulation:** Vasculature, kidneys, and lungs.

**Gross morphology of calcium accumulation (Figure 1-9):** Hard yellow nodules.

**Microscopic morphology of calcium accumulation:** Chunky, smooth, purple granules.



**Figure 1-8.** Lipofuscin pigment in macrophages in the liver. Almost all the cells in the photomicrograph contain finely granular, yellow-brown pigment, which is lipofuscin. Lipofuscin is the product of lipid peroxidation and free radical injury (wear-and-tear pigment) and, therefore, accumulates as the cell ages. This patient had centrilobular necrosis of the liver (normal hepatocytes are *not* visible in this section). Centrilobular hepatocytes normally contain lipofuscin, and the death of the hepatocytes releases the pigment for engulfment by macrophages. Hematoxylin and eosin, 400 $\times$ .



**Figure 1-9.** Dystrophic calcification of a tricuspid aortic valve. Dystrophic calcification involves damaged tissue such as would occur in an abnormal aortic valve (e.g., a bicuspid aortic valve, necrotic tissue, or normal age-related wear and tear, such as the aortic valve in elderly patients). The cusp on the right side of the photograph has prominent nodules of calcium on the sinus side of the valve leaflets (*arrow*).



## PROTEIN ACCUMULATION

There are many different causes of protein accumulation. Accumulations often involve intermediate filaments; for example, **Mallory hyaline** in the liver ([Figure 1-10](#)) and neurofibrillary tangles seen in **Alzheimer disease**.

## IRON ACCUMULATION

**Two forms of iron accumulation: Hemosiderosis and hemochromatosis**

**Hemosiderosis:** Accumulation of iron in organs without resultant side effects. The iron pigment is frequently within macrophages. Hemosiderin is a term used for aggregates of ferritin micelles (it stains positive with a Prussian blue stain).

### Hemochromatosis

**Basic description:** Accumulation of iron in parenchymal cells resulting in side effects, including **congestive heart failure**, **diabetes mellitus** (from damage to the pancreas), and **cirrhosis**. Hemochromatosis can be acquired or hereditary.

**Organs affected by hemochromatosis:** Most common organs affected are the liver, skin, pancreas, and heart.

**Microscopic morphology of iron accumulation ([Figure 1-11](#)):** Chunky, yellow-brown granules.

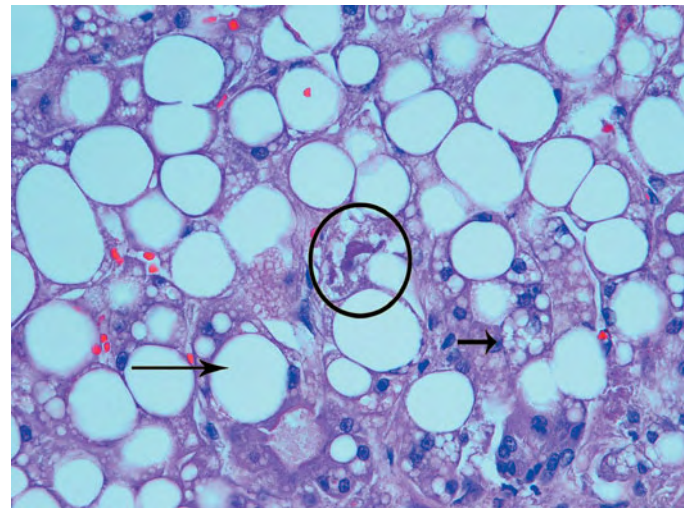
## FAT ACCUMULATION (STEATOSIS)

**Organs affected:** Most common organs affected are the liver, kidney, heart, and skeletal muscle.

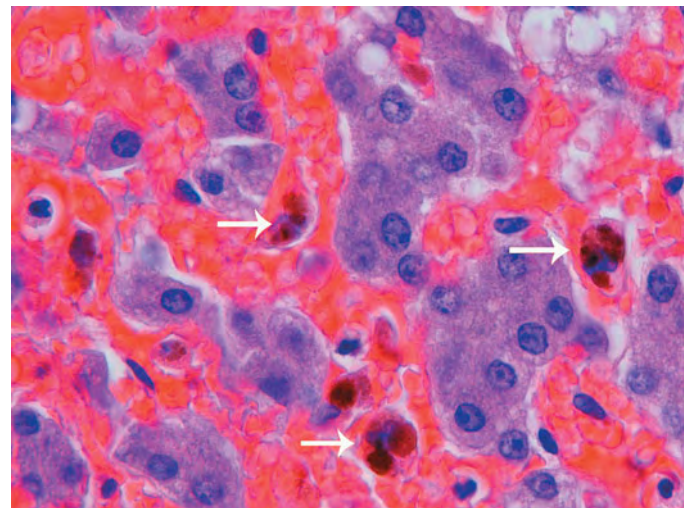
**Gross morphology of steatosis:** Yellow discoloration of an organ.

**Microscopic morphology of steatosis ([see Figure 1-10](#)):** One or several clear vacuoles within the cell.

**Important point regarding steatosis:** Steatosis can indicate reversible damage or may be the sign of an intrinsic abnormality in fat metabolism.



**Figure 1-10.** Fatty liver with Mallory hyaline. The hepatocytes in this photomicrograph show macrovesicular steatosis (one vacuole per cell) (*long arrow*) and microvesicular steatosis (many vacuoles per cell) (*short arrow*). The liver, along with the kidney and heart, are most commonly affected by fatty accumulations. In the center of the image is Mallory hyaline, the ropy, eosinophilic condensation within the cleared-out hepatocyte (*circle*). Mallory hyaline is a protein accumulation that is most commonly associated with alcohol use, and is composed of intermediate filaments. Hematoxylin and eosin, 200 $\times$ .



**Figure 1-11.** Hemosiderin within Kupffer cells in the liver. The hemosiderosis in this patient resulted from extravascular hemolysis. The hemosiderin represents iron accumulation from the breakdown of red blood cells. It has a characteristic chunky, yellow-brown appearance (*arrows*). Hematoxylin and eosin, 400 $\times$ .

### CHOLESTEROL ACCUMULATION

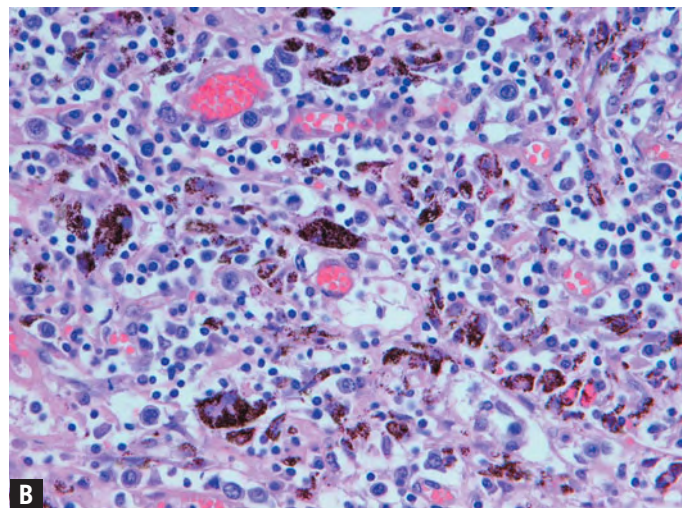
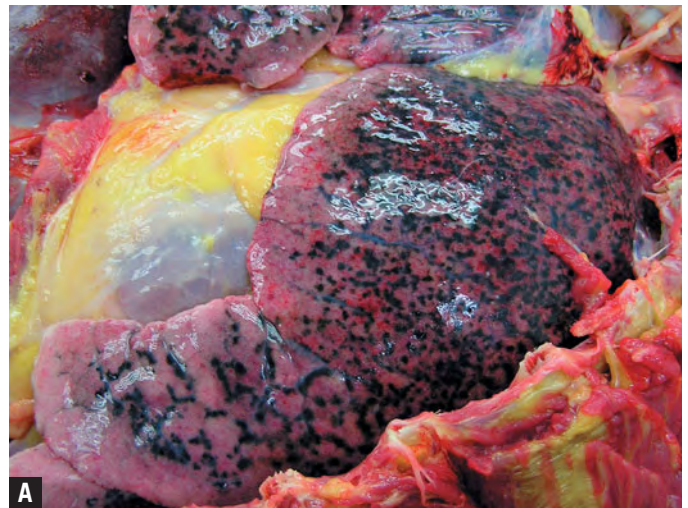**Organs affected:** Blood vessels (by the process of atherosclerosis) or at sites of hemorrhage. Cholesterol accumulates within phagocytic cells.

### GLYCOGEN ACCUMULATION

**Organs affected:** Glycogen accumulates as part of glycogen storage disorders (genetic diseases with a defect in enzymatic pathway of glycogen, such as **McArdle syndrome**). The most common organs affected are liver and skeletal muscle.

### PIGMENTS

- **Exogenous pigments:** Tattoos and anthracotic pigment, which is carbonaceous debris from urban dwelling or cigarette smoking (Figure 1-12 A and B).
- **Endogenous pigments:** Melanin; bilirubin (Figure 1-13 A and B).



**Figure 1-12.** Anthracosis of the lung. Anthracotic pigment is carbonaceous material that accumulates in the lungs of smokers, coal miners, and persons living in a polluted environment such as a large city. The black anthracotic pigment typically accumulates in the pleural lymphatics (**A**), and microscopically has a finely stippled black appearance, found in interstitial and alveolar macrophages (**B**). Hematoxylin and eosin, 200 $\times$ .



## CELLULAR AGING

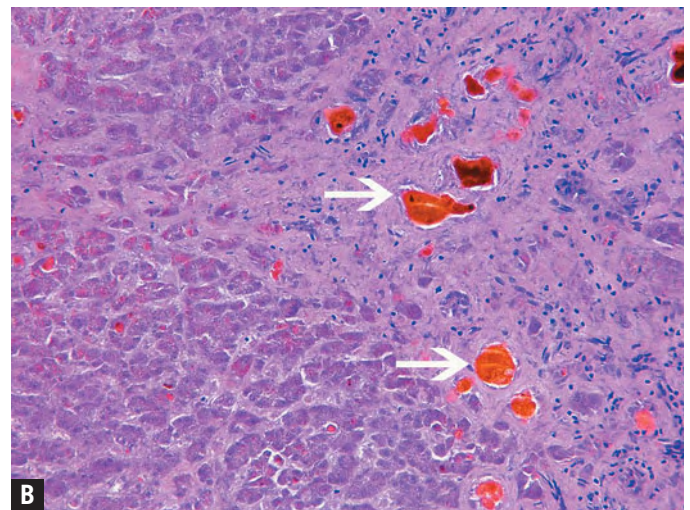
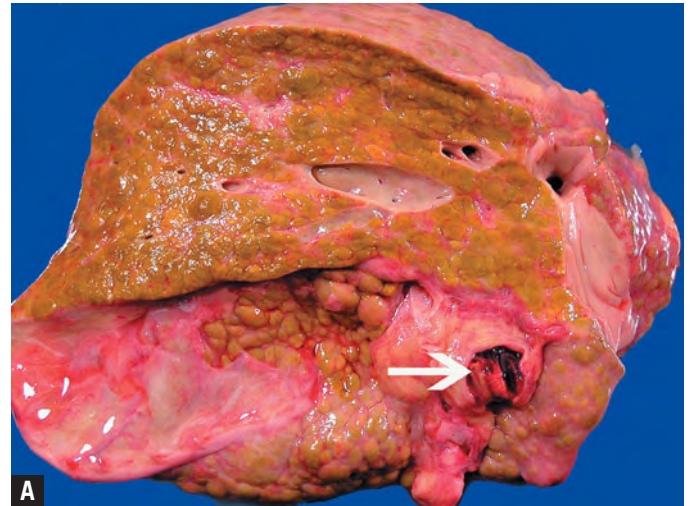
**Basic description:** Tissue cells have a fixed number of divisions, which they are capable of undergoing. Telomeres, or TTAGGG repeats, protect the ends of the chromosome, and they shorten with cell divisions. When the telomere is too short, the DNA is interpreted as broken.

**Immortal cells:** Telomerase (present in germ cells and stem cells) adds telomeres to the end of the chromosome, allowing the cell's lifespan to continue indefinitely.

## WERNER SYNDROME

**Manifestation:** Premature aging.

**Mutation:** Defective DNA helicase.



**Figure 1-13.** Cholestasis within a cirrhotic liver. Cholestasis is the accumulation of bile, an endogenous pigment produced by the liver. Its accumulation can result from many processes, including obstruction of the bile ducts. **A**, Grossly, cholestasis will result in a green discoloration of the liver. The arrow indicates a portal vein thrombus. **B**, Microscopically, bile is globular and yellow-green (right side of the slide, within the dilated bile ductules). The arrows indicate the accumulations of bile. Hematoxylin and eosin, 200 $\times$ .

*This page intentionally left blank*



## CHAPTER 2

# INFLAMMATION AND REPAIR

### OVERVIEW

**Inflammation** is the body's mechanism for coping with agents that could damage it. In other words, inflammation is a protective response to rid the body of the cause of cell injury and the resultant necrotic cells that cell injury produces. Although the processes of acute and chronic inflammation are an important protective mechanism used by the body to deal with potentially damaging agents, they are potentially damaging to the body and must be closely regulated. The basic steps in acute inflammation allow white blood cells to move from the blood to the tissue location where they are required. Acute inflammation can resolve completely if the inciting agent is removed, or it can have one of several other sequelae, including chronic inflammation. This chapter will discuss general concepts of acute and chronic inflammation, specific features of acute inflammation (including cardinal signs, causes, steps, and morphology and outcomes), specific features of chronic inflammation, and repair.

### GENERAL CONCEPTS OF ACUTE AND CHRONIC INFLAMMATION

**Overview:** The body must undergo changes locally through vasodilation and increased vascular permeability in the area of the agent inciting the inflammatory reaction to allow white blood cells to accumulate. The white blood cells must then leave the blood vessel, cross the basement membrane, and be drawn to the area where they are needed. The process by which white blood cells are drawn to the area where they are needed is referred to as **chemotaxis**. Acute inflammation has a rapid onset, lasts for minutes to days, and is characterized by exudation of fluid and protein from vessels and emigration of neutrophils. Acute inflammation is a protective process that is designed to rid the body of the inciting agent and set up the process of repair. Chronic inflammation has a longer time course (days to years) and involves different cell types than does acute inflammation (lymphocytes and macrophages versus neutrophils). Also, *in chronic inflammation, tissue repair coexists with tissue destruction.*

## ACUTE INFLAMMATION

**Cardinal signs of acute inflammation:** Rubor (red discoloration), calor (heat), dolor (pain), tumor (mass effect), and loss of function.

**Causes of acute inflammation:** Infection, trauma, physical and chemical agents, necrosis, foreign bodies, and immune reactions.

**Stages of acute inflammation** (Table 2-1)

- Vasodilation** (after a transient vasoconstriction)
  - **How:** Vasodilation occurs through release of mediators from cells. These mediators include histamine, prostacyclin ( $\text{PGI}_2$ ), and nitric oxide (NO).
  - **Why:** Vasodilation increases the hydrostatic pressure by causing slowing (sludging) of blood flow. Sludging of blood also causes margination of leukocytes along the wall of the blood vessel.
- Increased vascular permeability** (increased leakiness of vessels)
  - **How:** Increased vascular permeability occurs through release of mediators from cells. These mediators include histamine and leukotrienes  $\text{C}_4$ ,  $\text{D}_4$ , and  $\text{E}_4$ .
  - **Why:** Increased vascular permeability allows fluid to cross into the interstitial tissue, which increases protein levels in the interstitial tissue, thereby decreasing osmotic pressure in the blood and increasing osmotic pressure in the interstitial tissue. These changes cause fluid to flow out of the vessel, leading to edema of the interstitial tissue.
  - **Mechanisms of increased vascular permeability:** Several mechanisms increase vascular permeability, some of which are physiologic and some of which are pathologic.

**TABLE 2-1.** Mediators of Acute Inflammation

Effect Produced	Mediator Responsible
Vasodilation	Histamine, $\text{PGI}_2$ , NO
Increased vascular permeability	Histamine, bradykinin, TNF, IL-1 Leukotrienes $\text{C}_4$ , $\text{D}_4$ , and $\text{E}_4$
Rolling of white blood cells	Sialyl-Lewis-X on white blood cells E-selectin on endothelium
Pavementing of white blood cells	LFA-1 and Mac-1 on white blood cells ICAM-1 and VCAM-1 on endothelium
Transmigration	CD31 (PECAM) on white blood cells and endothelium
Chemotaxis—endogenous mediators	$\text{C5a}$ , $\text{LTB}_4$ , IL-8
Opsonins	IgG, $\text{C3b}$ , Collectins

$\text{PGI}_2$ , prostacyclin; NO, nitric oxide; TNF, tumor necrosis factor; IL, interleukin; LFA-1, leukocyte function-associated antigen-1; ICAM, intercellular adhesion molecule; VCAM, vascular cell adhesion molecule; PECAM, platelet endothelial cell adhesion molecule;  $\text{LTB}_4$ , leukotriene  $\text{B}_4$ .



Endothelial contraction and retraction are physiologic mechanisms and are due to mediators. Direct endothelial injury is a pathologic mechanism due to damaging agents not under the body's control.

- **Endothelial contraction** (referred to as immediate-transient response)
  - **Mediators:** Histamine, bradykinin, and leukotrienes.
  - **Vessels affected:** Postcapillary venules.
  - **Time course:** Immediate; short lived (up to 30 minutes).
- **Endothelial cell retraction**
  - **Mediators:** Tumor necrosis factor (TNF) and interleukins (e.g., IL-1).
  - **How:** Structural rearrangement of cytoskeleton.
  - **Time course:** 4–6 hours (referred to as delayed response); long lived.
- **Direct endothelial injury**
  - **Mediators:** Bacterial enzymes.
  - **Vessels affected:** All.
  - **How:** Endothelial cell necrosis.
  - **Time course:** Immediate (referred to as immediate-sustained response).
- **Delayed prolonged response**
  - Due to ultraviolet light, x-ray, and mild thermal injury.
  - Uncertain mechanism.
- **Leukocyte-mediated damage**

3. **Movement of white blood cells from blood vessels into soft tissue at the site of inflammation:** The steps required are **rolling**, **pavementing**, and **transmigration**. **Chemotaxis** is the process by which white blood cells are drawn to the site of acute inflammation.

#### Rolling

- **Basic description:** Loose, intermittent contact of white blood cells with endothelium, partially due to margination of white blood cells from stasis of blood.
- **Mediators:** Sialyl-Lewis X molecules on white blood cells bind with E-selectins on endothelial cells.

#### Pavementing

- **Basic description:** Tight, constant contact of white blood cells with endothelium.
- **Mediators:** Leukocyte function-associated antigen-1 (LFA-1) and Mac-1 on white blood cells bind with intercellular adhesion molecule 1 (ICAM-1) and vascular cell adhesion molecule 1 (VCAM-1) on endothelial cells.

#### Transmigration

- **Basic description:** White blood cells crossing through the endothelial layer.
- **Mediators:** CD31 or platelet endothelial cell adhesion molecule (PECAM) on both white blood cells and endothelial cells.

## CHEMOTAXIS

**Basic description:** Process by which white blood cells are drawn to the site of inflammation.

### Mediators

- **Exogenous mediators:** Bacterial polysaccharides.
- **Endogenous mediators:** C5a, leukotriene B<sub>4</sub> (LTB<sub>4</sub>), and IL-8. The endogenous mediators act through various mechanisms. With most, however, the activation of G-protein receptors ultimately results in activation of GTPases, which cause polymerization of actin.

### The role of leukocytes (see Table 2-1)

- White blood cells recognize foreign particles through mannose and scavenger receptors. Opsonins are particles that bind to foreign material and signal leukocytes to remove it. **Types of opsonins** include:
  1. IgG (recognized by Fc receptor on white blood cells).
  2. C3b (recognized by CR 1, 2, and 3 on leukocytes).
  3. Collectins (recognized by C1q on leukocytes).
- White blood cells engulf the foreign particles (most often bacteria) using the above-mentioned receptors.
- Killing and/or degradation of foreign substances occurs by one of several methods:
  - **Reduced nicotinamide adenine dinucleotide phosphate (NADPH) oxidase** (has membrane and cytoplasmic component). It uses two oxygen molecules to produce a superoxide radical ( $O_2^{\cdot-}$ ), and the superoxide radical converts to hydrogen peroxide.
  - **Myeloperoxidase:** Converts hydrogen peroxide and halogen ( $Cl^-$ ) to HOCl, which causes halogenation or lipid or protein peroxidation.
  - Other methods of bacterial killing include bactericidal permeability increasing protein, lysozyme, and major basic protein.

## DISEASES ASSOCIATED WITH IMPAIRED INFLAMMATORY RESPONSE

### CHRONIC GRANULOMATOUS DISEASE

**Basic description:** Loss of NADPH oxidase results in chronic granulomatous disease. NADPH oxidase has two components—membrane and cytoplasmic; both components must be brought together for the enzyme to function.

**Inheritance:** The mutation for the autosomal recessive form of chronic granulomatous disease results in a defective cytoplasmic component, and the mutation for the X-linked form of chronic granulomatous disease results in a defective membrane component.

**Effect of mutation:** Inability to form hydrogen peroxide.



**Important point regarding chronic granulomatous disease:** Many bacterial organisms produce hydrogen peroxide. The hydrogen peroxide produced by bacteria can be utilized by myeloperoxidase, thus bypassing the need for NADPH oxidase. However, many organisms produce catalase, which degrades the hydrogen peroxide they produce.

### CHÉDIAK-HIGASHI SYNDROME

**Inheritance of Chédiak-Higashi syndrome:** Autosomal recessive.

**Mutation:** A mutation occurs in a cytosolic protein, which plays a role in vesicle traffic.

**Effects of mutation:** Decreased cellular killing of bacteria because of reduced transfer of lysosomal enzymes to phagocytic vesicles. Other effects of mutation include albinism, nerve defects, and platelet disorders.

### MORPHOLOGY OF ACUTE INFLAMMATION

**Overview:** Types of acute inflammation include serous, fibrinous, and purulent; however, mixed forms with features of one or more of these types may be seen.

#### ■ Serous inflammation

- **Appearance:** Relatively clear, watery fluid.
- **Contents of fluid:** Few cells; most of the inflammation is fluid (i.e., a transudate; a protein-poor fluid with a specific gravity  $< 1.012$ ).
- **Seen in:** Viral infections and burns.

#### ■ Fibrinous inflammation

- **Appearance:** Finely particulate, thick fluid.
- **Contents of fluid:** Much more protein and cells than serous inflammation (i.e., an exudate; a protein-rich fluid with a specific gravity  $> 1.020$ ).
- **Seen in:** Uremic and postmyocardial infarct pericarditis.

#### ■ Purulent inflammation (Figure 2-1 A, B, and C)

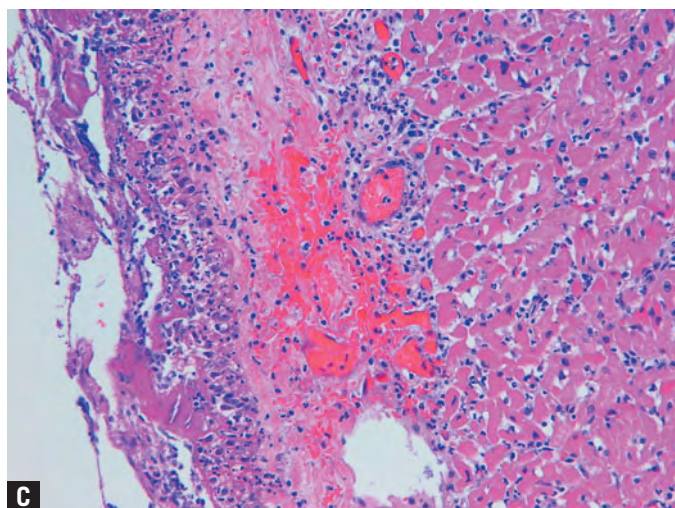
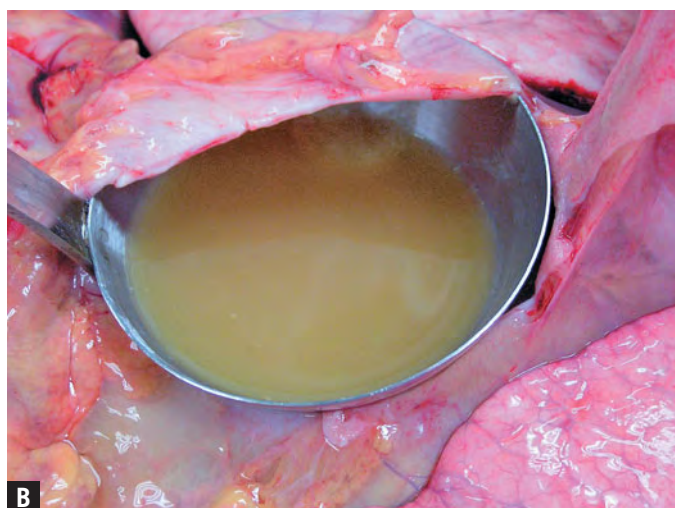
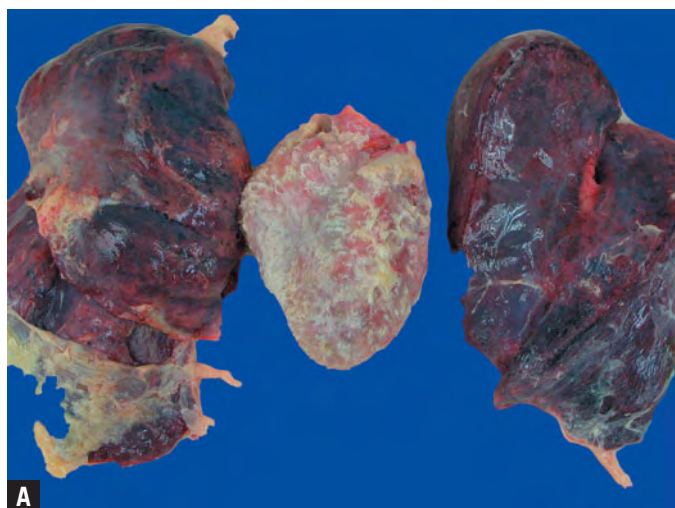
- **Appearance:** Pus (thick, white-yellow fluid).
- **Contents of fluid:** Neutrophils, protein, and necrotic cells (i.e., an exudate).
- **Seen in:** Bacterial and fungal infections.

### OUTCOMES OF ACUTE INFLAMMATION

**Overview:** Outcomes of acute inflammation include resolution, abscess formation, ulcers, fistula formation, chronic inflammation, and scar formation.

#### ■ Resolution

- **Basic description:** The inciting agent is removed, and all damage done by the inciting agent and inflammatory cells is repaired.
- **Requirements for resolution:** The organ affected must be capable of regeneration, and the body must be capable of completely dealing with the inciting agent.



**Figure 2-1.** Purulent pericarditis and purulent pleuritis. **A**, In the center of the photograph is a heart, with the respective lungs to the right and left side of it. Covering most of the epicardial surface of the heart and a patchy distribution of the visceral pleurae of the lungs is a thick, yellow-white fluid, which is pus. Pus (i.e., purulent fluid) is composed predominantly of neutrophils admixed with plasma proteins and cellular debris. The source of most purulent infections is often bacterial organisms. **B**, Pus within the pericardial sac. **C**, A photomicrograph of the epicardial surface of the heart. Note the thick layer of inflammatory cells, predominantly neutrophils on the left side of the image. Hematoxylin and eosin, 200 $\times$ .

- **Important point:** For epithelium to regenerate, the basement membrane must be intact because it serves as the guide upon which new cells are laid down. If the basement membrane is destroyed, the new cells can be laid down, but they are unorganized. For organs to regenerate, the framework (i.e., the connective tissue scaffold) of the organ must be intact.

#### ■ Abscess (Figure 2-2 A and B)

- **Basic description:** Walled off collection of pus (neutrophils and necrotic debris).
- **Requirements for abscess formation:** The body cannot rid itself of the inciting agent, or the process of repair and scarring is occurring more rapidly in the tissue around the site of the abscess.
- **Location:** Any organ in the body.
- **Complications of an abscess:** Pain, fever, rupture, and swelling.

#### ■ Ulcer (Figure 2-3)

- **Basic description:** Loss of the mucosa and deeper tissues. If only the mucosa is lost, the correct term is an **erosion**.
- **Requirements for ulcer formation:** The body cannot rid itself of the inciting agent.
- **Microscopic morphology of an ulcer:** The ulcer has four layers, which recapitulate steps from acute inflammation to repair. The layers, from superficial to deep, are fibrin, neutrophils, granulation tissue, and fibrosis.
- **Location:** Most commonly seen in the gastrointestinal tract.
- **Complications of an ulcer:** Pain; hemorrhage, if the ulcer involves a vessel; and perforation, resulting in hemorrhage within a cavity or the lumen of the gastrointestinal tract, or seeding of the peritoneal cavity with the contents of the gastrointestinal tract, causing peritonitis.

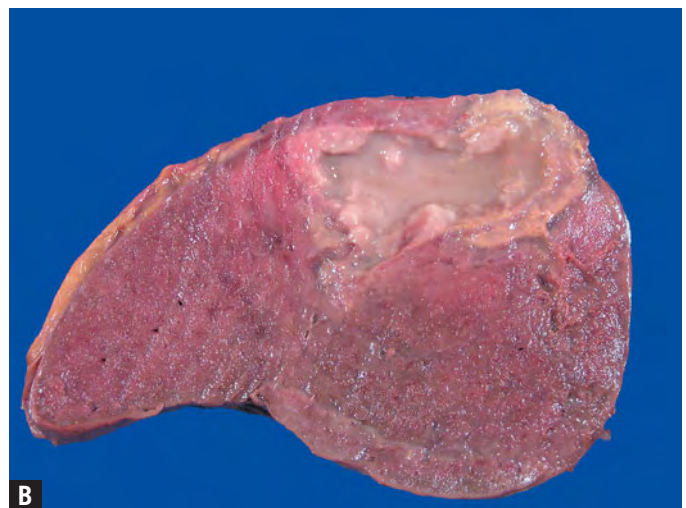
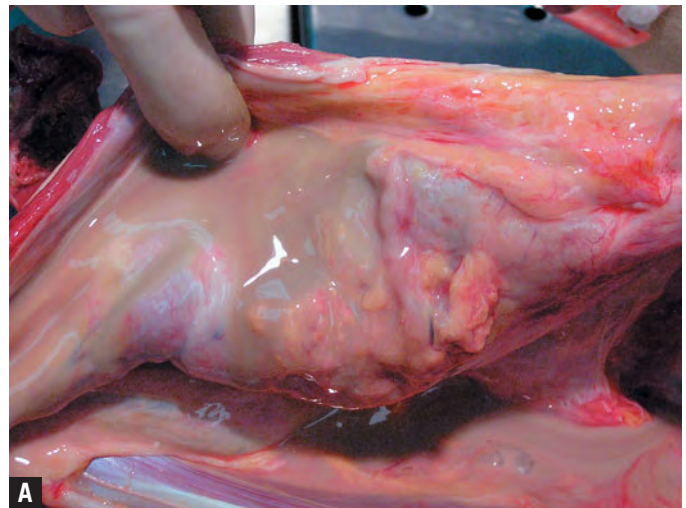
#### ■ Fistula (Figure 2-4 A, B, and C)

- **Basic description:** Anomalous patent connection between two organs; most commonly organs with a lumen.
- **Requirement for fistula formation:** Inflammatory process involving full thickness of the wall of an organ, duct, or blood vessel. The wall adheres to an adjacent wall, which is subsequently involved by the inflammatory process, allowing communication between the lumens.
- **Example:** Enterocutaneous fistula (skin to colon, occurring in colon cancer or inflammatory bowel disease).
- **Complications:** Depends upon the nature of the two organs involved. For example, the fistula can serve as a conduit by which infection can enter other organs or as a conduit between a vessel and an organ, resulting in massive hemorrhage.

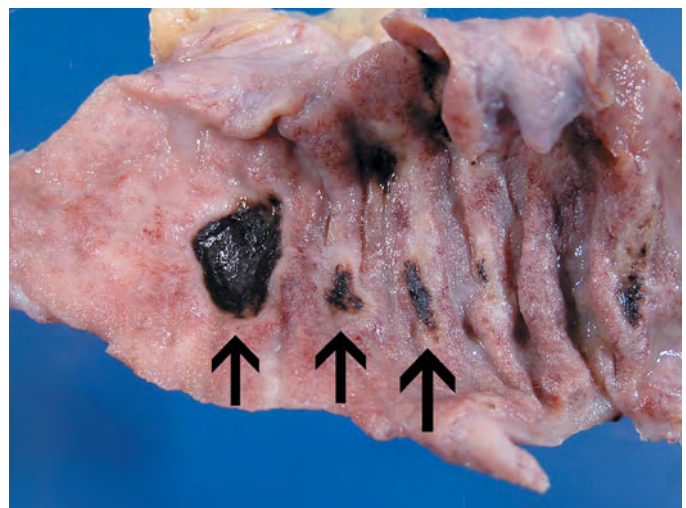
#### ■ Chronic inflammation

##### ■ Scar formation

- **Basic description:** Replacement of lost parenchyma with disorganized connective tissue (e.g., collagen).
- **Requirements for scar formation:** Loss of tissue in an organ not capable of regeneration or loss of basement membrane or other framework required for successful regeneration.
- **Complications:** Loss of function.



**Figure 2-2.** Abdominal wall and splenic abscesses. An abscess is a walled-off collection of pus. **A**, The abscess is in the right side of the abdominal wall. **B**, The abscess is in the spleen. Abscesses can rupture and release their contents (including bacteria) into body cavities and hollow organs, such as the gastrointestinal tract.



**Figure 2-3.** Duodenal ulcers. The arrows indicate superficial ulcers in the duodenum. Peptic ulcer disease is a chronic condition, often due to infection with *Helicobacter pylori*. Stress ulcers, as shown in the photograph, develop acutely, often due to burns, head injuries, or other forms of physical stress.



## CHRONIC INFLAMMATION

**Overview:** Prolonged inflammation consisting of active inflammation and tissue destruction and repair, all occurring simultaneously. Chronic inflammation can follow acute inflammation, but it can also occur as a low-grade, asymptomatic, prolonged response to an inciting agent.

**Causes of chronic inflammation:** Viral, persistent microbial infection, prolonged exposure to toxin, and autoimmune dysfunction.

**Cells involved in chronic inflammation:** Macrophages and lymphocytes (Figure 2-5).

### ■ Activated macrophages produce

- Proteases, IL-1, TNF, arachidonic acid metabolites, NO (IL-1 and TNF activate lymphocytes).
- Angiogenesis and growth factors, such as platelet-derived growth factor (PDGF) or fibroblast growth factor (FGF).

### ■ Activated lymphocytes produce

- FGF stimulates fibroblasts to produce collagen, which results in scarring.
- PDGF and transforming growth factor- $\beta$  (TGF- $\beta$ ).
- Interferon- $\gamma$  (activates macrophages).

**Important type of chronic inflammation: Granulomatous inflammation**

■ **Basic description of granuloma:** Collection of epithelioid histiocytes.

■ **Morphology of granuloma:** Collection of activated macrophages (i.e., epithelioid histiocytes); can have multinucleated giant cells (Figure 2-6).

■ **Causes:** Mycobacteria, fungi, foreign material, sarcoidosis, and silica.

## REPAIR

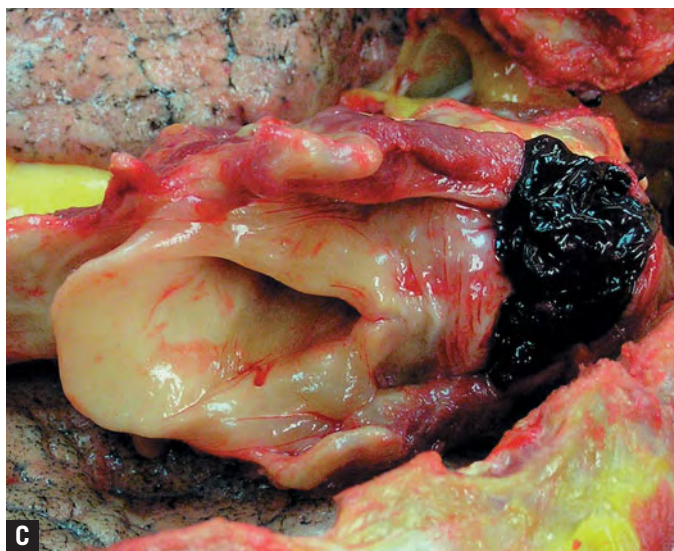
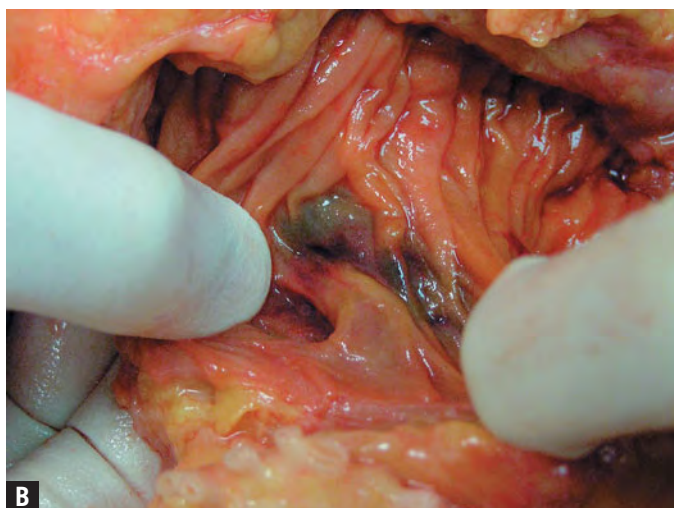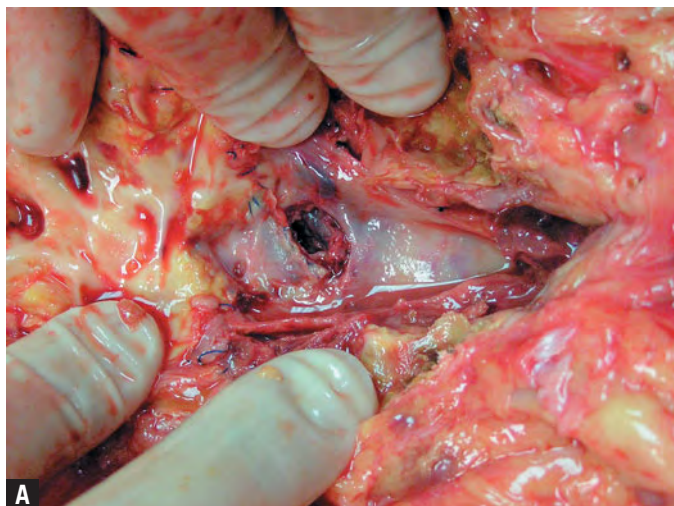
**Overview:** The process of repair begins very early. Repair involves regeneration of the parenchyma or replacement of damaged tissue with a scar if regeneration is not possible. The process of complete regeneration (i.e., resolution of acute inflammation) requires an organ that is composed of cells that can divide and an intact basement membrane and connective tissue scaffolding.

**Definitions: Healing versus regeneration**

■ **Regeneration** is complete replacement of damaged cells, with no scar formation.

- Can occur in renewing tissues (e.g., gastrointestinal tract and skin).
- Can occur in stable tissues (e.g., compensatory growth in the liver and kidney).
- Regeneration requires an intact connective tissue scaffold.

■ **Healing** is regeneration of cells combined with scarring and fibrosis.



**Figure 2-4.** Aortoduodenal fistula. This patient had an abdominal aortic aneurysm, which was repaired with a graft. The graft became infected and was surgically replaced with a neointimal saphenous vein graft, which also became infected. A tract developed between the neointimal graft and the duodenum. There is a defect in the neointimal aortic graft (A) (center of the photograph), which communicated with the duodenum (B) through a fistula, resulting in a massive amount of blood entering the gastrointestinal tract, which is visible in the esophagus of the patient (C).

### Important mediators in repair

- **Epidermal growth factor (EGF):** Stimulates granulation tissue formation.
- **Vascular endothelial growth factor (VEGF):** Induces blood vessel formation.
- **PDGF:** Promotes migration and proliferation of fibroblasts, smooth muscle cells, and monocytes.
- **FGF:** Stimulates blood vessel formation and wound repair through macrophages, fibroblasts, and endothelial cell migration.
- **TGF- $\beta$ :** Acts as growth inhibitor for epithelium.

### Components of healing

- Induction of inflammatory process to deal with the source of injury (cell injury is prequel to healing). The inflammatory process acts to contain damage, remove injuring substance, remove dead tissue, and start deposition of extracellular matrix.
- Formation of new blood vessels.
- Production of extracellular matrix, including collagen.
- Tissue remodeling.
- Wound contracture.
- Increasing wound strength.

**Replacement by scar:** The following four processes occur.

1. Formation of new blood vessels (i.e., **angiogenesis**).
2. Migration and proliferation of fibroblasts.
3. Deposition of extracellular matrix.
4. Maturation and reorganization of fibrous tissue. Tissue remodeling is a balance between extracellular matrix synthesis and degradation. Extracellular matrix is degraded by matrix metalloproteinases (e.g., collagenases, gelatinases).

### Time frame of scarring

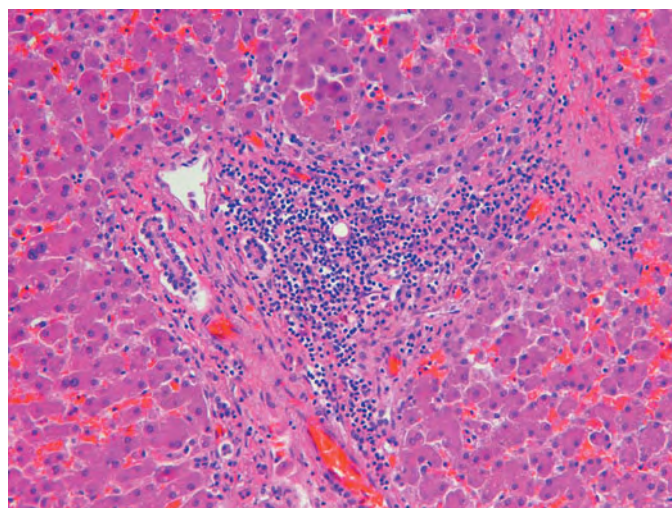
- Within 24 hours of onset of acute inflammation, the process of scarring begins.
- At 3–5 days, **granulation tissue** is formed. The term granulation tissue indicates a proliferation of fibroblasts, new thin-walled vessels, and loose extracellular matrix.
- During week 2, collagen continues to be deposited and edema and inflammatory cells are almost entirely absent.
- By 1 month, the inflammatory infiltrate is absent and the scar consists of collagen. The collagen strengthens over the next few months.
- **Important point:** Formation of the scar occurs via either first or second intention.

## HEALING BY FIRST INTENTION

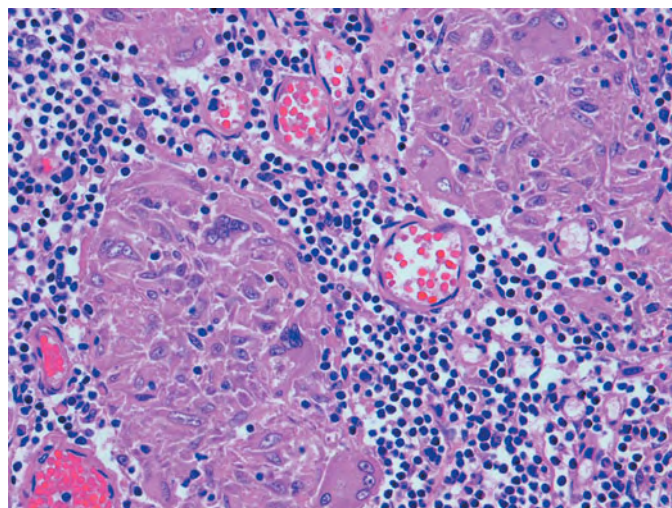
**Basic description:** Healing of a wound that has clean edges, close reapproximation of margins, and minimal tissue disruption.

**Example:** Healing of surgical incision.

**Result:** Small to nonexistent scar.



**Figure 2-5.** Chronic inflammation (chronic hepatitis). The portal tract in the center of the photomicrograph contains an increased number of lymphocytes. Lymphocytes and macrophages are the cell type most commonly present in chronic inflammation. Chronic inflammation is often due to an injurious stimulus that the body cannot remove from its tissue. In chronic hepatitis, that injurious stimulus is often an infection with hepatitis C virus. Hematoxylin and eosin, 200 $\times$ .



**Figure 2-6.** The photomicrograph shows granulomas in the left lower corner, left upper corner, and right upper corner. Granulomas are a collection of epithelioid histiocytes. Although multinucleated giant cells are often present, their presence is not required as a component of a granuloma. Granulomas are a specific form of chronic inflammation, most commonly associated with foreign bodies and some infections, including *Mycobacterium tuberculosis*. Hematoxylin and eosin, 200 $\times$ .



## HEALING BY SECOND INTENTION

**Basic description:** Healing of a wound that has unclear edges, extensive tissue disruption, and tissue necrosis.

**Example:** Healing of a cutaneous ulcer or a large laceration inflicted by a blow from a baseball bat.

**Result:** Larger, more prominent scar.

### Important points

- The wound has much more necrotic debris and fibrin clot, which must be removed before the wound can be repaired. Normal removal of this tissue as part of the repair process can result in more damage by release of mediators from cells summoned to remove the debris.
- More granulation tissue is formed to bridge the gap between the edges of the wound. More granulation tissue results in a larger scar.
- **Wound contraction** occurs, reducing the wound by 5–10% of its full size. Wound contraction may occur due to contraction of myofibroblasts.

## GENERAL WOUND HEALING

### Wound strength

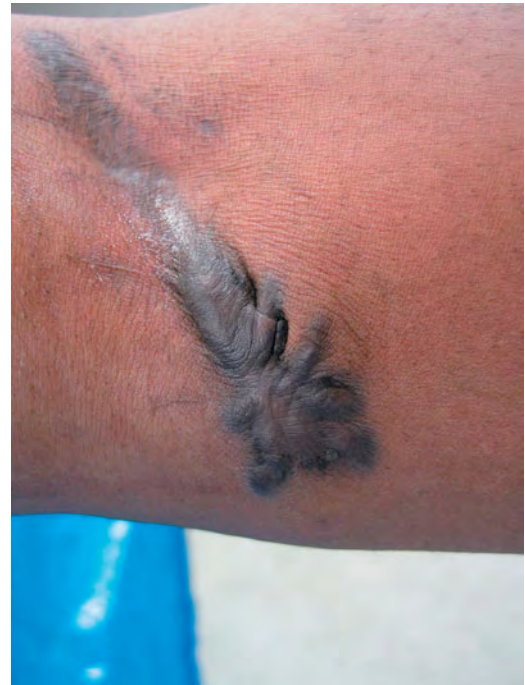- Is about 10% of that of normal skin at 1 week (with no sutures in place), increasing in amount of strength over the following month.
- After 2 or more months, the scar is fully healed, but still only has three fourths of the strength of normal skin.

### Factors that may impair the process of wound healing

- **General factors:** Infections, nutritional deficiency (e.g., vitamin C deficiency), and glucocorticoid therapy, which results in decreased fibrosis.
- **Mechanical factors: Dehiscence** is unintentional reopening of the wound, often due to pressure or torsion.
- **Poor perfusion:** Decreases amount of blood available for healing.

### Complications of cutaneous wound healing

- Inadequate healing, leading to dehiscence or ulceration.
- Excessive scar formation: **Hypertrophic scars** or **keloid scars**. Keloid scars involve tissue beyond the boundaries of the wound (Figure 2-7).
- Contractures.



**Figure 2-7.** Keloid scar. Keloid scars are a form of exuberant scarring in which the boundaries of the scar extend beyond the boundaries of the wound. The ability to form keloid scars frequently occurs within certain demographic populations, such as African Americans.

*This page intentionally left blank*



## CHAPTER 3

# PATHOLOGY OF THE IMMUNE SYSTEM

### OVERVIEW

Diseases of the immune system take many forms, including **hypersensitivity reactions**, **autoimmune disorders**, and **immunodeficiency states**. Hypersensitivity reactions occur as one of four types (types I–IV). Autoimmune diseases are the result of a failure in the immune system to recognize self-antigens, resulting in production of antibodies that react against normal components of cells. Most of the autoimmune diseases are associated with one or more specific antibodies, which can be identified by laboratory tests to aid in diagnosis. Immunodeficiency states can be hereditary or acquired. A major cause of acquired immunodeficiency is human immunodeficiency virus (HIV) infection. The concepts of immunity are also important in regard to transplantation efforts. This chapter will discuss hypersensitivity reactions, transplantation pathology, autoimmune diseases, amyloidosis, and both hereditary and acquired immunodeficiency.

### HYPERSENSITIVITY REACTIONS

**Overview:** There are four types of hypersensitivity reactions, each of which has a different mechanism. These four types of hypersensitivity reactions will be discussed below.

#### TYPE I HYPERSENSITIVITY REACTION

**Mechanism:** Exposure to an antigen results in the formation of IgE. The antigen reacts with CD4<sup>+</sup> cells, which differentiate to T<sub>H</sub>2 cells. T<sub>H</sub>2 cells release interleukin-3 (IL-3), IL-4, and IL-5. IL-5 stimulates eosinophils, and IL-4 activates IgE-producing B cells. The IgE binds to mast cells. Subsequent exposure to the same antigen results in binding of the antigen to IgE bound to mast cells, with the consequence of degranulation of the mast cells and release of mediators (e.g., histamine). The release of mediators causes increased vascular permeability, leading to edema and increased smooth muscle contraction and eventually to bronchoconstriction.

#### Sequence of events in type I hypersensitivity reaction

1. **Early phase** (occurs within 5–30 minutes of exposure to antigen): Characterized by vasodilation, increased vascular

permeability, and increased smooth muscle contraction. The early phase is due to binding of antigen to IgE bound to mast cells, with subsequent degranulation of the mast cells and release of mediators.

2. **Late phase** (occurs after 2–24 hours and lasts for days): Characterized by infiltration by neutrophils, eosinophils, basophils, and monocytes, and results in mucosal damage due to release of mediators by these recruited inflammatory cells.

#### Forms of type I hypersensitivity reactions

- **Systemic anaphylaxis:** Due to parenteral administration of antigen; for example, a bee sting or a reaction to penicillin.
- **Local reaction:** Urticaria (hives).

**Causes:** Penicillin, angiotensin-converting enzyme (ACE) inhibitors, intravenous (IV) contrast and other drugs, proteins (e.g., insect venoms), and food.

#### Clinical presentation of type I hypersensitivity reaction:

Symptoms and signs include abrupt onset (within 30 minutes of exposure to antigen) of rash, nausea and vomiting and facial swelling, wheezing and stridor, and hypotension and tachycardia. Serum tryptase is a marker of anaphylaxis.

**Complications of systemic anaphylaxis:** Death due to airway compromise from laryngeal edema.

### TYPE II HYPERSENSITIVITY REACTION

**Overview of general mechanism:** Antibodies directed against target antigens on cells or in extracellular matrix. The target antigens may be endogenous or absorbed exogenous antigens.

**Specific mechanisms:** There are three specific mechanisms by which type II hypersensitivity reactions occur. The three mechanisms are complement-dependent reactions, antibody-dependent cell-mediated cytotoxicity, and antibody-mediated cellular dysfunction.

#### ■ Complement-dependent reactions

- **Mechanism:** Antibody bound to antigen can fix complement and cause direct lysis of the cell through production of the membrane attack complex (MAC), or the complement can coat cells with C3b (an opsonin) and promote phagocytosis of the antigen.
- **Example:** Glomerulonephritis.

#### ■ Antibody-dependent cell-mediated cytotoxicity

- **Mechanism:** Cell types that bear receptors for the Fc portion of IgG, such as neutrophils, eosinophils, macrophages, and natural-killer (NK) cells, mediate removal of antigen.
- **Examples:** Transfusion reactions, **erythroblastosis fetalis**, and autoimmune hemolytic anemia.

#### ■ Antibody-mediated cellular dysfunction

- **Mechanism:** Antibodies themselves affect function of the antigen.
- **Examples:** **Graves disease** is due to an antibody that activates the thyroid-stimulating hormone (TSH) receptor,



resulting in hyperthyroidism. **Myasthenia gravis** is due to antibodies against the acetylcholine (ACh) receptor, impairing neuromuscular transmission.

### TYPE III HYPERSENSITIVITY REACTION

**Mechanism:** Antibodies bind to the antigen, forming an immune complex. The antigens can be exogenous (e.g., viral proteins) or endogenous (e.g., DNA). These immune complexes can form in situ, or they can form in the vasculature and subsequently be deposited in organs, where they cause damage. The immune complex causes activation of the complement cascade. Note that immune complexes are commonly formed for various reasons, but only under certain circumstances do they elicit an immune reaction.

**Examples:** Immune–complex-mediated vasculitis and forms of glomerulonephritis.

### TYPE IV HYPERSENSITIVITY REACTION

**General mechanism:** Mediated by sensitized T cells rather than by antibodies.

#### Specific mechanisms

- **Delayed form of type IV hypersensitivity reaction:** CD4<sup>+</sup> helper T cells (T<sub>H</sub>1 type) sensitized from previous exposure to an antigen secrete interferon- $\gamma$ , which activates macrophages. Activated macrophages secrete IL-12, which causes differentiation of T<sub>H</sub>1 cells.
  - **Microscopic morphology:** Stimulation of macrophages results in granulomas (i.e., collections of epithelioid histiocytes).
  - **Inciting agents:** Mycobacteria, fungi, and parasites.
  - **Examples:** Tuberculin reaction and contact dermatitis.
- **Cell-mediated cytotoxicity:** Sensitized CD8<sup>+</sup> cells kill antigen-bearing cells. The antigens are presented by class I major histocompatibility complex (MHC) molecules. There are two mechanisms by which this occurs: the perforin-granzyme system and the FAS-FAS ligand system.
  - **Perforin-granzyme system:** Perforin produces holes in the plasma membrane of cells, allowing granzyme to enter the cells. Granzyme then activates apoptosis through stimulation of caspase activity.
  - **FAS-FAS ligand system:** The sensitized T lymphocytes have FAS ligand, which binds to FAS on target cells, leading to apoptosis.

## TRANSPLANTATION PATHOLOGY

**Overview:** Rejection of transplanted organs may be cellular or humoral, with cellular rejection mediated by T cells, and humoral rejection mediated by antibodies. In addition, rejection may be classified based upon its timing following the transplant procedure. The rejection can be hyperacute, acute, or chronic.

## CELLULAR REJECTION

**Mechanism:** Cellular rejection is due to hypersensitivity of the recipient's CD4<sup>+</sup> cells, which results in killing of graft cells by CD8<sup>+</sup> cells that have matured into cytotoxic T lymphocytes. The cytotoxic T lymphocytes kill graft cells through the perforin-granzyme pathway or the FAS-FAS ligand pathway.

### Forms of cellular rejection

- **Direct:** The body recognizes MHC molecules on the surface of the antigen-presenting cells in the graft.
- **Indirect:** Antigens of the graft are presented by the recipient's cells.

## HUMORAL REJECTION

**Overview:** Humoral rejection is due to preformed antibodies or formation of antibodies against graft vasculature.

### CLASSIFICATION OF FORMS OF REJECTION BASED UPON TIMING OF REJECTION AFTER TRANSPLANTATION

#### Hyperacute rejection

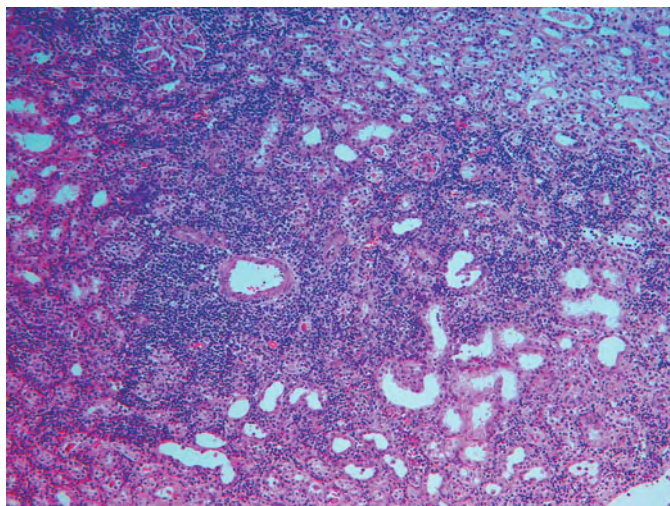
- **Mechanism:** Humoral reaction due to preformed antibodies to graft endothelium.
- **Time course:** Minutes following transplantation.
- **Morphology:** Grossly, there is cyanosis of the organ and a mottled parenchyma; microscopically, there is endothelial injury, neutrophils in arterioles, and infarcts of parenchyma.

#### Acute rejection

- **Mechanism:** Cellular or humoral reaction.
- **Time course:** Days to months to years following transplantation.
- **Microscopic morphology of acute cellular rejection (Figure 3-1):** Interstitial mononuclear infiltrate, edema, interstitial hemorrhage, and endothelialitis (i.e., swollen endothelial cells).
- **Microscopic morphology of acute humoral rejection:** Necrotizing vasculitis, neutrophilic infiltrate, and infarcts of parenchyma.
- **Important point:** An acute cellular rejection will respond to cyclosporine.

#### Chronic rejection

- **Mechanism:** Possibly, the indirect form of cellular rejection plays an important role.
- **Time course:** 4–6 months to years following the graft.
- **Microscopic morphology:** Vascular changes, interstitial fibrosis, interstitial mononuclear infiltrate, and ischemia with subsequent tissue loss.



**Figure 3-1.** Acute cellular rejection in the kidney. In this low-power view of a renal transplant, note the infiltrate of lymphocytes among the glomeruli and renal tubules. Hematoxylin and eosin, 100 $\times$ .

## HEMATOPOIETIC TRANSPLANTATIONS

### GRAFT VERSUS HOST DISEASE (GVHD)

**Basic description:** Immune competent cells in the graft recognize antigens in the host.

**Occurrence:** In bone marrow transplants; in solid organ transplants when the organ is rich in lymphocytes (e.g., liver); and in non-irradiated blood.

#### Forms of GVHD

##### ■ Acute GVHD

- **Time course:** Days to weeks.
- **Organs affected (and complications):** Skin (rash), bile ducts (jaundice), and gastrointestinal mucosa (bloody diarrhea).
- **Associated findings:** Acute GVHD results in immunodeficiency and thus patients can have secondary infections, including cytomegalovirus (CMV) pneumonia.

##### ■ Chronic GVHD

- **Organs affected (and complications):** Dermis and skin appendages (fibrosis), bile ducts (cholestatic jaundice), and esophagus (strictures).
- **Associated findings:** Chronic GVHD results in immunodeficiency; thus patients can have secondary infections, including CMV pneumonia.

## AUTOIMMUNE DISEASES

**Overview:** Autoimmune disease results from a failure of self-tolerance. In self-tolerance, the body inactivates its immune response against antigens, which are present on and in its own cells. Autoimmune diseases can be organ specific or systemic, and are often associated with a specific antibody (Table 3-1).

**General mechanism:** Loss of self-tolerance. Contributing factors include susceptibility genes (e.g., certain HLA types such as B27 in **ankylosing spondylitis**) and infections. Infections may upregulate expression of costimulatory proteins on antigen-presenting cells, or microbes can have antigens that are similar in structure to self-antigens. Antibodies against these foreign antigens then cross-react with self-antigens.

**TABLE 3-1.** Autoimmune Diseases and Their Associated Antibodies

Disease	Associated Antibodies
Systemic lupus erythematosus	Anti-dsDNA, anti-Smith
Drug-induced lupus	Antihistone
Rheumatoid arthritis	IgM versus Fc portion of Ig
Sjögren syndrome	Anti-SSA and anti-SSB
CREST syndrome	Anti-centromere
Diffuse scleroderma	Anti-scl70

CREST, calcinosis, Raynaud phenomenon, esophageal dysfunction, sclerodactyly, telangiectasis.

## SPECIFIC SYSTEMIC AUTOIMMUNE DISEASES

**Overview:** There are many different autoimmune diseases; however, five common systemic autoimmune disorders (systemic lupus erythematosus, rheumatoid arthritis, Sjögren syndrome, systemic sclerosis, and mixed connective tissue disorder) are discussed below.

### 1. Systemic lupus erythematosus (SLE)

**Epidemiology:** Individuals aged 20–40 years (i.e., those of child-bearing age). Of the general population, SLE occurs in 1 in 2500 individuals, with a 9:1 male to female ratio. In children and older adults, the male to female ratio is more equal. SLE is more common in African Americans.

#### Clinical presentation of SLE

- Skin rash (malar, photosensitivity, discoid).
- Arthralgias: Arthralgia, myalgia, and arthritis are often the first complaint of patients diagnosed with SLE.
- Pericarditis.
- Renal dysfunction (proteinuria  $> 0.5$  g/dL; cellular casts).
- Neurologic disorder (seizures, psychosis).
- Hematologic disorder (hemolytic anemia, leukopenia, lymphopenia, thrombocytopenia).
- Immunologic disorder (anti-dsDNA antibody, anti-Smith antibody, or antiphospholipid antibodies): The presence of antiphospholipid antibodies is detected by a positive lupus anticoagulant test, an abnormal level of IgG or IgM anticardiolipin, or a false-positive test for syphilis. Cardiolipin is a constituent of material used in a syphilis test.
- Antinuclear antibodies.

**Associated antibodies:** Anti-dsDNA, anti-Smith.

**Mechanism of injury of SLE:** Type III hypersensitivity reaction (i.e., due to deposition of immune complex and subsequent activation of the complement cascade).

**Risk factors for SLE:** Genetics and environment.

**Important point:** Opportunistic infections are the most common cause of death of patients with SLE. Renal and central nervous system (CNS) diseases are the second most common cause of death.

#### Morphology of SLE

- **Gross:** Some findings include malar rash, serositis, and **Libman-Sacks endocarditis** (1–3 mm nonbacterial vegetations on either surface of the leaflet—this is now seen less because of the advent of corticosteroid therapy).
- **Microscopic:** A general feature of SLE is the lupus erythematosus (LE) cells in tissue, which are neutrophils containing phagocytized nuclei. A specific feature of SLE is renal disease, which has five classes.
  - Class I: No disease.
  - Class II: Mesangial—increase in mesangial matrix, with deposition of immune complexes.



- Class III: Focal proliferative glomerulonephritis—a few glomeruli have proliferation of endothelial and mesangial cells; associated with an increased number of neutrophils and possibly fibrinoid necrosis (Figure 3-2).
- Class IV: Diffuse proliferative glomerulonephritis—most if not all glomeruli have the changes described in Class III.
- Class V: Membranous glomerulonephropathy—glomeruli have thickened basement membranes, producing a “wire-loop” pattern.

**Associated conditions:** Two conditions often associated with SLE are antiphospholipid antibody syndrome and drug-induced lupus.

#### Antiphospholipid antibody syndrome

■ **Basic description:** This condition is due to an antibody that delays clotting in vitro; in vivo, it induces a hypercoagulable state.

■ **Complications of antiphospholipid antibody syndrome:** Arterial and venous thrombi, spontaneous abortions, and focal cerebral and ocular ischemia. *The classic clinical triad is thrombosis, thrombocytopenia, and recurrent abortions.*

#### ■ Forms of antiphospholipid antibody syndrome

- **Primary:** Occurs as a sole entity and is *not* associated with SLE.
- **Secondary:** Occurs in patients with a diagnosis of SLE.

#### Drug-induced lupus

■ **Basic description:** Disease associated with certain drugs (e.g., hydralazine, procainamide, or D-penicillamine) that can cause symptoms similar to SLE, such as arthralgia, fever, and serositis. Renal and CNS manifestations are rare, however.

■ **Associated antibody:** Antihistone antibodies.

■ **Important point:** The disease remits with removal of the drug.

### 2. Rheumatoid arthritis

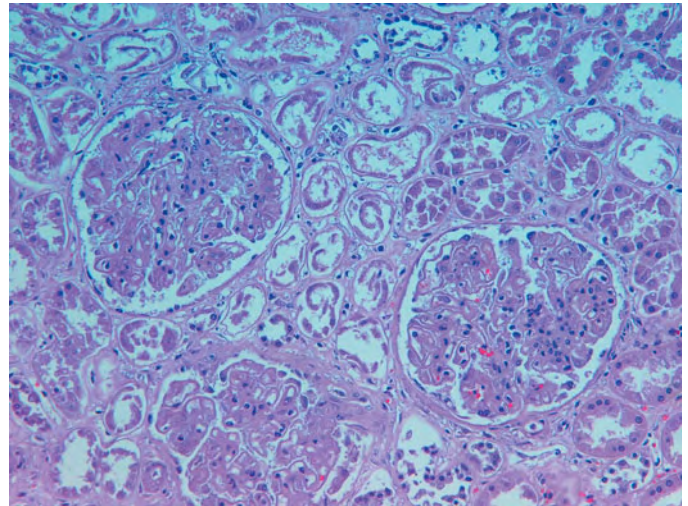
**Epidemiology:** Rheumatoid arthritis is more common in women than in men.

**Clinical presentation of rheumatoid arthritis:** Arthritis (non-suppurative, proliferative arthritis), sometimes with extra-articular symptoms due to involvement of skin, heart, blood vessels, and lungs. The arthritis is characterized by warmth, swelling, and tenderness in the joints, usually bilaterally and most commonly in the hands. The classic presentation is morning stiffness > 1 hour duration. Signs include a boutonnière deformity of the distal interphalangeal joint (DIP), a swan neck deformity of the proximal interphalangeal joint (PIP), Baker cysts, and rheumatoid nodules.

**Associated antibodies:** Rheumatoid factor (IgM antibody against the Fc portion of IgG) in 70–80% of the patients.

**Mechanism of injury:** Type III hypersensitivity reaction.

**Microscopic morphology of rheumatoid arthritis:** In the joint, a **pannus** forms. A pannus is proliferating synovial cells mixed with inflammatory cells and granulation tissue. Pannus formation can lead to fibrosis and calcification of the joint space (i.e.,



**Figure 3-2.** Focal proliferative glomerulonephritis in a patient with systemic lupus erythematosus. Of the three glomeruli shown in the photomicrograph, only the one on the far right shows any pathologic changes. Focally, there is an increased number of cells within the glomerular tuft (at the 3-o'clock position). Hematoxylin and eosin, 200×.

ankylosis). **Rheumatoid nodules** have a central fibrinoid necrosis surrounded by palisading macrophages, with an outer rim of lymphocytes and plasma cells (Figure 3-3 A and B).

### 3. Sjögren syndrome

**Epidemiology:** Usually occurs in women between the ages of 50 and 60 years.

**Clinical presentation of Sjögren syndrome:** Triad of dry mouth, dry eyes, and an autoimmune disorder (usually rheumatoid arthritis).

#### Associated antibodies

- Anti-SSA (anti-ribonucleoprotein); patients with a high titer of anti-SSA are more likely to have systemic manifestations.
- Anti-SSB (anti-ribonucleoprotein).

**Microscopic morphology:** Lymphocytic and plasmacytic infiltrate of salivary and lacrimal glands, which is associated with ductal damage (Figure 3-4).

**Complications of Sjögren syndrome:** **MALToma** (neoplasm of mucosa-associated lymphoid tissue); patients can also have extraglandular involvement producing synovitis, pulmonary fibrosis, and neuropathy.

### 4. Systemic sclerosis (scleroderma)

**Basic description:** Autoimmune condition associated with fibrosis of organs involved.

**Epidemiology:** Usually occurs in individuals 50 to 60 years of age and older; the ratio of occurrence is 3:1 female to male.

#### Clinical presentation

- **Limited scleroderma** (also called **CREST syndrome**): **C**alcinosis, **R**aynaud phenomenon, **E**sophageal dysfunction, **S**clerodactyly, and **T**elangiectasia.
- **Diffuse scleroderma:** Widespread skin and visceral involvement, including pulmonary fibrosis resulting in hypertension and renal involvement resulting in oliguric renal crises.

#### Associated antibodies

- CREST syndrome: Anticentromere.
- Diffuse scleroderma: Anti-Scl70 (against DNA topoisomerase I).

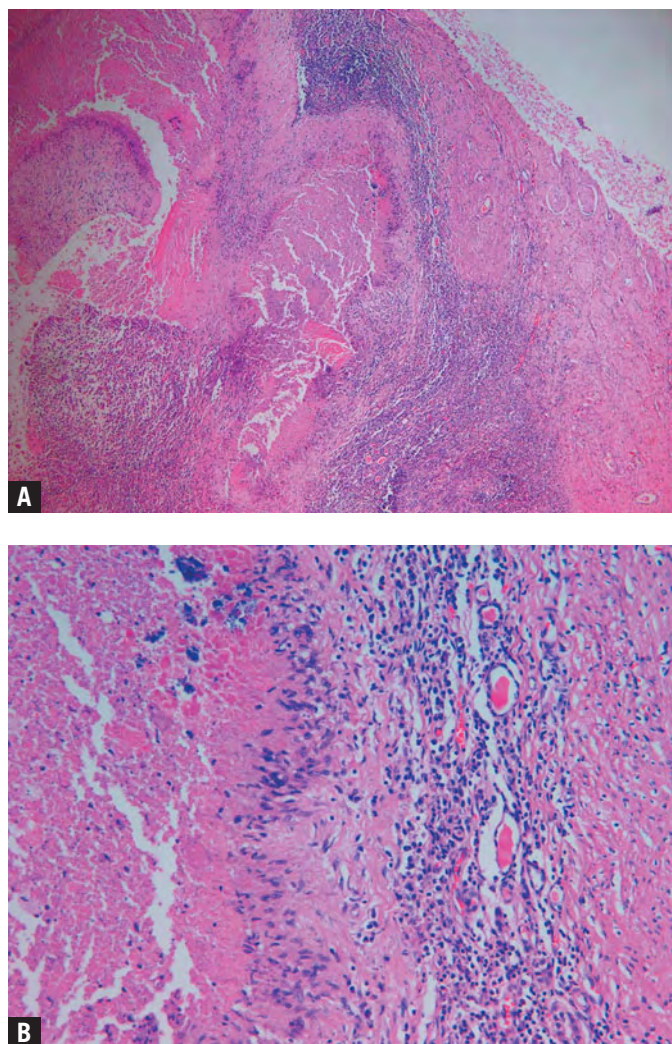
**Microscopic morphology of systemic sclerosis:** Fibrosis involving dermis, muscularis of gastrointestinal tract, and alveolar septae in the lung and interlobular arteries in the kidney and heart.

### 5. Mixed connective tissue disorder

**Clinical presentation:** Findings suggestive of SLE, polymyositis, rheumatoid arthritis, and systemic sclerosis.

**Associated antibodies:** To ribonucleoprotein (RNP) particle containing U1.

**Important points:** Patients have little or no renal disease and respond well to treatment with corticosteroids.



**Figure 3-3.** **A**, A low-power view of a rheumatoid nodule. **B**, A closer view showing the central necrosis on the left side of the photomicrograph, with successive layers of palisading macrophages and lymphocytes (to the right of the necrosis). Hematoxylin and eosin, A, 40 $\times$ ; B, 400 $\times$ .



## AMYLOIDOSIS

**Overview:** Amyloidosis is due to abnormal production and deposition of protein. Within tissues of the body, there are several types of amyloid, each of which is composed of a different protein and is associated with certain diseases (Table 3-2).

### Microscopic morphology of amyloidosis

■ **Light microscope:** Amorphous, hyaline deposition that has apple-green birefringence upon polarization after Congo red staining (Figure 3-5).

■ **Electron microscope:** Most forms of amyloid are 7.5 to 10-nanometer fibrils in a  $\beta$ -pleated sheet configuration.

**Some organs affected by amyloidosis:** Kidney, spleen, liver, and heart.

**Clinical presentation:** Diastolic heart failure, macroglossia, carpal tunnel syndrome, and chronic renal disease. Amyloidosis is one of four causes of chronic renal disease associated with enlarged kidneys; the other three causes are diabetes mellitus, polycystic kidney disease, and HIV nephropathy.

## HEREDITARY IMMUNODEFICIENCY STATES

**Overview:** There are many hereditary causes of immunodeficiency. Major points regarding six of the more common forms (X-linked agammaglobulinemia of Bruton, common variable immunodeficiency, isolated IgA deficiency, hyper-IgM syndrome, severe combined immunodeficiency disease [SCID], and Wiskott-Aldrich syndrome) are discussed below.

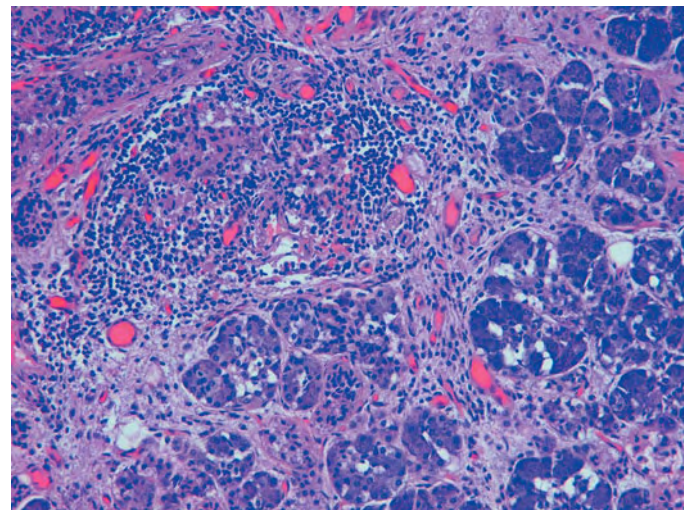
### X-LINKED AGAMMAGLOBULINEMIA OF BRUTON

**Inheritance pattern:** X-linked recessive.

**Mutated gene:** Gene for B cell tyrosine kinase.

**Mechanism:** Failure of maturation of B cells. The B cells undergo heavy chain rearrangement and then stop maturing.

**Epidemiology:** Manifest by the age of 6 months. The delay in manifestations is because of the presence of maternal IgG.



**Figure 3-4.** Salivary gland in a patient with Sjögren syndrome. This section of submandibular salivary gland has a lymphocytic infiltrate (in the left upper corner of the photomicrograph), associated with some disruption of the glandular parenchyma. With such destruction of salivary gland tissue, the inability to produce saliva is impaired; hence, the dry mouth associated with Sjögren syndrome. Hematoxylin and eosin, 200 $\times$ .

**TABLE 3-2.** Amyloidosis: Types, Constituent Protein, and Associated Diseases

Forms of Amyloidosis	Type of Amyloid	Protein	Associated Disease
Systemic amyloidosis	AL	Ig light chain	Multiple myeloma
	AA	Serum amyloid-associated protein	Chronic inflammatory conditions; hereditary amyloidosis
	ATTR	Transthyretin	Systemic senile amyloidosis
Localized amyloidosis	A $\beta$	Amyloid precursor protein	Alzheimer disease
	A Cal	Calcitonin	Medullary thyroid carcinoma

**Manifestations of X-linked agammaglobulinemia of Bruton:**

Recurrent infections are bacterial (e.g., *Haemophilus influenzae*, *Streptococcus pneumoniae*, *Staphylococcus aureus*), some viral (e.g., enteroviruses), and some parasitic (e.g., *Giardia lamblia*). Patients have hypoplasia of tonsils and adenoids and very low immunoglobulin levels.

**Microscopic morphology:** Underdeveloped germinal centers in lymphoid organs.

**COMMON VARIABLE IMMUNODEFICIENCY**

**Inheritance pattern:** No one mode of inheritance.

**Mechanism:** B cells proliferate in response to antigen but cannot produce Ig.

**Epidemiology:** Affects males and females equally; presents during later childhood and adolescence.

**Manifestations of common variable immunodeficiency:** Same as X-linked agammaglobulinemia of Bruton.

**Microscopic morphology:** Lymphoid follicular hyperplasia.

**ISOLATED IGA DEFICIENCY**

**Mechanism:** Defect in differentiation of B lymphocytes to IgA-producing cells. Can be familial or acquired due to toxoplasmosis or measles infections.

**Epidemiology:** 1 in 600 births; much more common in whites than in African Americans and Asians.

**Manifestations of isolated IgA deficiency:** Recurrent sinopulmonary infections, diarrhea, and increased incidence of autoimmune diseases. Also, patients can develop an anaphylactic reaction to blood transfusions.

**HYPER-IGM SYNDROME**

**Mutation:** Gene at Xq26—protein product is CD40L. This mutation is found in 70% of patients; other patients have a mutation of CD40.

**Inheritance pattern:** With the mutation of CD40L, inheritance is X-linked recessive; with the mutation of CD40, it is autosomal recessive.

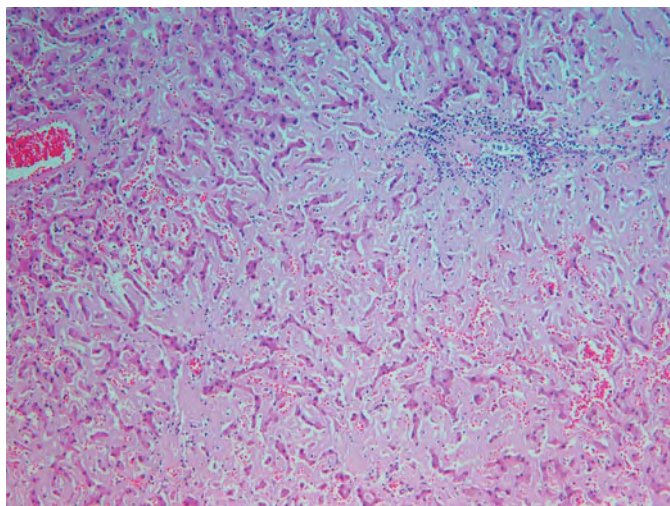
**Mechanism:** T cells fail to stimulate B cells to produce antibody other than IgM.

**Manifestations of hyper-IgM syndrome:** Recurrent pyogenic infections and *Pneumocystis pneumonia*.

**SEVERE COMBINED IMMUNODEFICIENCY DISEASE (SCID)****Inheritance patterns**

■ **X-linked recessive** (50–60% of cases)

- **Mutation:** Gene for common  $\gamma$  chain subunit of cytokine receptors.



**Figure 3-5.** Amyloidosis of the liver. This low-power view of the liver shows sinusoids that are markedly expanded by a waxy, pale eosinophilic, acellular material. This material is amyloid and would show apple-green birefringence upon polarization after staining with Congo red. Hematoxylin and eosin, 100 $\times$ .



- **Mechanism:** A defect in the cytokine receptor for IL-7 is most important in causing the effects of the disease, since IL-7 is required for proliferation of lymphocytes.
- **Epidemiology:** Male predominance.

#### ■ Autosomal recessive

- **Mutation:** Gene for adenosine deaminase.
- **Mechanism:** Causes accumulation of deoxy-ATP, which is toxic to lymphocytes.

**Manifestations of SCID:** Recurrent infections before the age of 6 months by a wide range of pathogens, including *Candida*, various bacteria (e.g., *Pseudomonas*), and viruses (e.g., CMV, varicella).

### WISKOTT-ALDRICH SYNDROME

**Inheritance pattern:** X-linked recessive.

**Manifestations:** Thrombocytopenia with resultant bleeding at the circumcision site; eczema and recurrent infections.

### ACQUIRED IMMUNODEFICIENCY SYNDROME (AIDS)

**Cause:** Infection with human immunodeficiency virus (HIV), an RNA retrovirus.

#### Mechanism of transmission

- Sexual: Virus is in semen (extracellular and in monocytes) and enters the patient through tears in the mucosa.
- Parenteral (e.g., IV drug abuse).
- Mother-to-infant: Transmission can occur in utero, transplacental, or intrapartum (during delivery).

#### Types

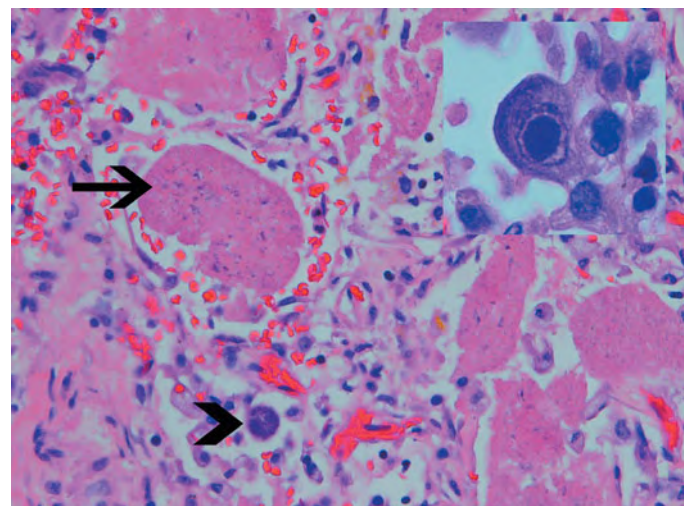
- HIV-1: Found in individuals in the United States, Europe, and Central Africa.
- HIV-2: Found in individuals in West Africa.

#### Major proteins, genes, and their functions

- gp120 and gp41.
- p24 major capsid protein.
- *gag* gene encodes p24.
- *pol* gene encodes reverse transcriptase.

#### Mechanism of HIV infection

- gp120 binds to CD4, which exposes the site for CXCR4 on T cells and for CCR5 on macrophages. Then, gp41 undergoes a change, which allows it to insert into the target membrane, allowing viral-cell fusion.
- Viral core enters the cell; the viral genome then undergoes reverse transcription. In dividing cells, the cDNA enters the nucleus and integrates into the viral genome.
- When the infected cell is activated, proviral transcription occurs, which results in lysis of cells.
- HIV colonizes the lymphoid organs.



**Figure 3-6.** *Pneumocystis* pneumonia and cytomegalovirus (CMV) pneumonia. This HIV-positive patient had a pneumonia caused by both *Pneumocystis* and CMV. *Pneumocystis* pneumonia produces a “fluffy pink” exudate in the alveolar spaces (arrow). The arrowhead indicates a CMV-infected cell. The inset in the right upper corner of the photomicrograph better illustrates the characteristic intranuclear inclusion produced in CMV-infected cells. Hematoxylin and eosin, 400× (main image) and 1000× (inset).

**Important point:** HIV is infection with the virus; AIDS is a syndrome characterized by certain “AIDS-defining illnesses”—in other words, *all people infected with HIV do not have AIDS*.

**Clinical features:** Patients with AIDS are at risk for opportunistic infections and certain neoplasms, and have characteristic CNS and renal findings.

### 1. Opportunistic infections

Cryptosporidiosis (causes enteritis).

*Pneumocystis pneumonia* (Figure 3-6).

■ **Risk factor for *Pneumocystis* pneumonia:** CD4<sup>+</sup> count < 200 cells/μL.

■ **Clinical presentation:** Fever, nonproductive cough, dyspnea, increased level of lactate dehydrogenase (LDH), and diffuse interstitial (“ground-glass”) pattern seen on a chest radiograph. Hypoxemia is usually present and may be severe.

Toxoplasmosis (pneumonia or infection of CNS).

Cryptococcosis (causes meningitis).

Disseminated histoplasmosis.

Mycobacterium (infections with *M tuberculosis* or *M avium-intracellulare*).

CMV (see Figure 3-6).

Bacillary angiomatosis (*Bartonella henselae*).

Candida esophagitis.

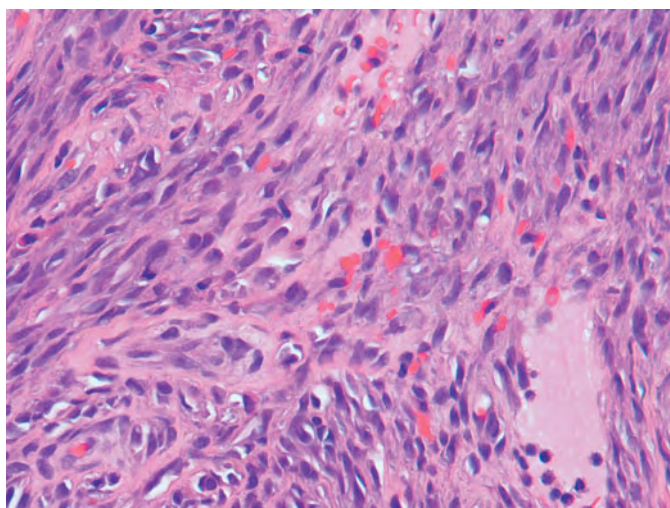
### 2. Neoplasms

■ **Kaposi sarcoma** (related to HHV-8) (Figure 3-7).

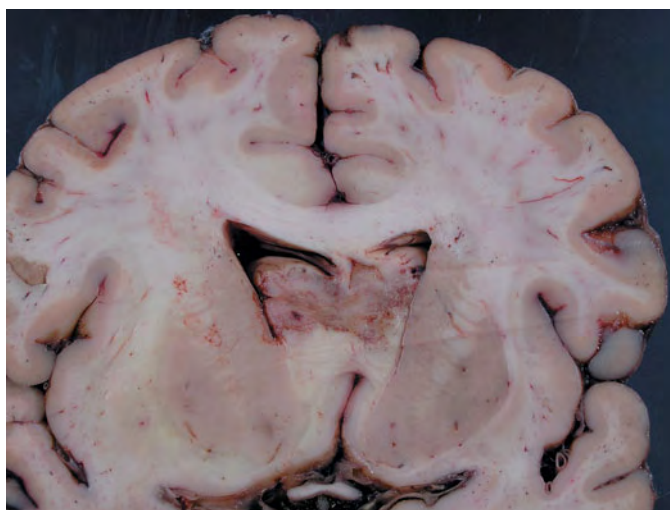
■ **Non-Hodgkin lymphoma** (B-cell lymphomas of the brain) (Figure 3-8).

3. **CNS involvement:** Encephalitis characterized by giant cells; also, **vacuolar myelopathy** and AIDS dementia.

4. **Renal involvement:** HIV nephropathy, focal segmental glomerulosclerosis, and chronic renal disease characterized by enlarged kidneys.



**Figure 3-7.** Kaposi sarcoma. Kaposi sarcoma is a malignancy derived from blood vessels and is found in patients with AIDS. The histologic appearance of Kaposi sarcoma is a spindle cell neoplasm with extravasated red blood cells. Hematoxylin and eosin, 200×.



**Figure 3-8.** B-cell lymphoma of the brain in a patient with AIDS. The non-Hodgkin B-cell lymphoma in this patient is centered on the septum pellucidum and fornix. Non-Hodgkin B-cell lymphomas of the brain occur with a higher frequency among patients with AIDS when compared with a control population of non-HIV-infected individuals.

# CHAPTER 4

## NEOPLASIA

### OVERVIEW

**Neoplasia** is new growth. The terms **benign** and **malignant** correlate to the course of the neoplasm. Benign neoplasms stay localized in one place; *malignant neoplasms invade surrounding tissue and, in most cases, can metastasize to distant organs*. To become neoplastic, a normal cell must develop mutations that allow it to no longer obey boundaries of adjacent cells, thus allowing for uncontrolled growth, and the neoplasm must be able to produce its own blood supply. If the neoplasm is malignant, the cells must also gain the ability to invade the basement membrane and surrounding tissue, enter the blood stream, and spread to and grow within distant organs.

This chapter will discuss the basic terms associated with neoplasia, features used to distinguish benign neoplasms from malignant neoplasms, epidemiology and etiology of neoplasms, effects of tumors (including paraneoplastic syndromes), basic carcinogenesis (including proto-oncogenes and tumor suppressor genes), diagnosis (including tumor markers and immunohistochemistry), and basic grading and staging.

### TERMINOLOGY OF NEOPLASIA

**Overview:** The terms **tumor**, **nodule**, and **mass** are nonspecific terms that refer to an abnormal proliferation of cells. The term **neoplasm** means new growth and *does not* imply benign or malignant (i.e., there are benign neoplasms, and there are malignant neoplasms).

#### Nomenclature for general categories of neoplasms

- **Adenoma:** Benign neoplasm derived from glandular cells.
- **Carcinoma:** Malignant neoplasm derived from epithelial cells ([Figures 4-1](#) and [4-2](#)).
- **Sarcoma:** Malignant neoplasm derived from mesenchymal cells (e.g., fat, muscle).
- **Lymphoma:** Malignant neoplasm derived from lymphocytes.
- **Melanoma:** Malignant neoplasm derived from melanocytes.
- **Germ cell tumor:** Malignant neoplasm derived from germ cells.



### Nomenclature for benign neoplasms

In general, the name of a benign neoplasm often ends with **-oma**.

■ **Examples:** Adenoma (benign neoplasm of glandular epithelium), fibroadenoma (benign neoplasm of the breast), and leiomyoma (benign neoplasm of smooth muscle).

■ **Some exceptions:** Hepatoma (malignant neoplasm of liver), melanoma (malignant neoplasm of melanocytes), mesothelioma (malignant neoplasm of mesothelial cells), and seminoma (malignant germ cell neoplasm of testis).

### Nomenclature for malignant neoplasms

In general, the name of a malignant neoplasm often ends with **-carcinoma** or **-sarcoma**.

■ **Examples:** Adenocarcinoma (malignant neoplasm of glandular tissue), rhabdomyosarcoma (malignant neoplasm of skeletal muscle), and leiomyosarcoma (malignant neoplasm of smooth muscle).

### Terminology related to microscopic appearance of neoplasms

■ **Differentiation:** How histologically similar to the normal tissue the neoplasm is (i.e., how analogous the neoplastic cells look to the tissue type from which they arose)—terms used are well differentiated, moderately differentiated, or poorly differentiated (Figures 4-3 and 4-4). Differentiation is a subjective determination made by the pathologist.

■ **Anaplasia:** Lack of differentiation.

■ **Dysplasia:** Disordered growth of epithelium. There is a loss of cellular uniformity and architectural orientation. The cells may have an increased number of mitotic figures. Dysplasia does not necessarily form a mass or tumor. In many cases, dysplasia is a precursor of malignancy, but dysplasia does not always progress to malignancy. Dysplasia can be reversible, if the inciting agent is removed (Figure 4-5).

■ **Carcinoma in situ:** Full-thickness dysplasia of the epithelium.

### Miscellaneous terminology related to neoplasms

■ **Hamartoma:** A disorganized collection of tissue, with the tissue composing the mass being tissue that is normally found in the organ in which the mass occurred; a hamartoma is *not* a neoplasm.

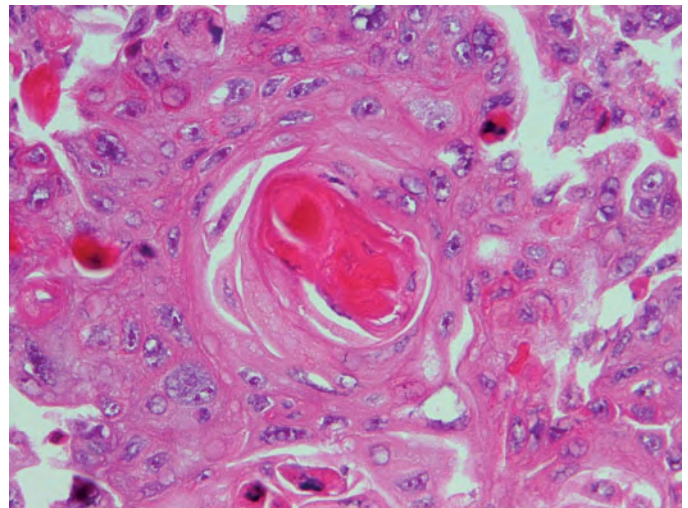
■ **Choristoma:** A mass composed of ectopic tissue (i.e., otherwise fairly normal tissue located at a site where it normally is not found). A choristoma is *not* a neoplasm.

■ **Polyp:** Mass projecting from a mucosal surface. A polyp is a descriptive term; the mass causing the polyp may or may not be a neoplasm.

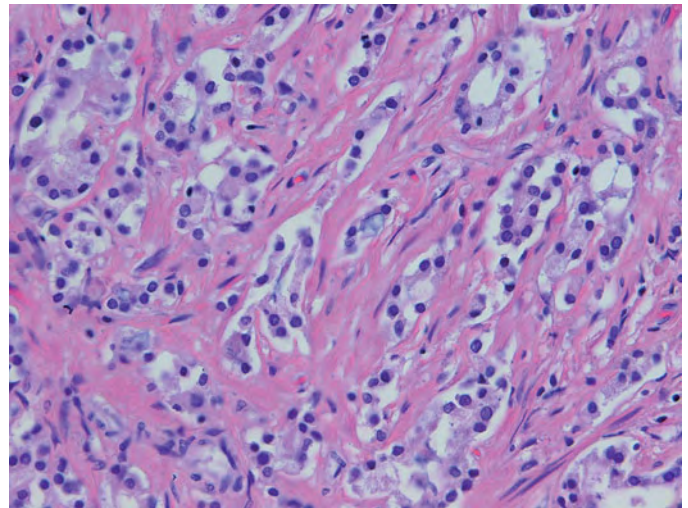
## FEATURES USED TO DISTINGUISH BENIGN NEOPLASMS FROM MALIGNANT NEOPLASMS

### Histologic features of malignancy

Histologic features are reliable indicators of malignancy in many organs, although in some sites (e.g., the endocrine



**Figure 4-1.** Squamous cell carcinoma. Squamous cell carcinoma is one of the major forms of carcinoma, occurring within many organs including the mouth, upper respiratory tract, and lungs. In the center of the photomicrograph is a keratin pearl, a characteristic feature of a well or moderately differentiated squamous cell carcinoma. Hematoxylin and eosin, 400 $\times$ .



**Figure 4-2.** Prostatic adenocarcinoma. Adenocarcinoma is one of the major forms of carcinoma. In well and moderately differentiated forms, the glandular histology is readily apparent (as in this section). Hematoxylin and eosin, 400 $\times$ .



system), histologic features do not always distinguish benign neoplasms from malignant neoplasms (Figures 4-6 and 4-7). The histologic features of malignancy are listed below.

- **Pleomorphism:** Variation in nuclear and cytoplasmic shape between cells.
- **Abnormal mitotic figures** and increased numbers of mitotic figures.
- **Hyperchromasia:** Increased basophilia of the nucleus.
- **Hypercellularity**, with a loss of normal polarity.

#### Rate of growth

- Benign neoplasms tend to grow slower; malignant neoplasms tend to grow more quickly, often at a rate corresponding to their degree of anaplasia.
- **Growth fraction:** The proportion of neoplastic cells in the proliferative phase. At the point when most malignant tumors are clinically detected, the growth fraction is usually less than 20% (i.e., most neoplasms have their most rapid rate of growth prior to detection).

#### Invasion and metastases (Figures 4-8 and 4-9)

- Histologic features and rate of growth alone cannot always distinguish between benign and malignant neoplasms. The two features that reliably distinguish benign from malignant neoplasms are (1) invasion, or the infiltration of tumor cells into surrounding organs; and (2) metastases, or the spread of tumor cells to distant organs through the blood, which is characteristic of sarcomas, or through the lymphatics, which is characteristic of carcinomas (Figure 4-10).
- Some malignancies do not metastasize (e.g., gliomas and basal cell carcinoma of the skin), but they do invade.
- Overall, 30% of malignant solid tumors have metastases at the time they are clinically detected.

## CANCER STEM CELLS

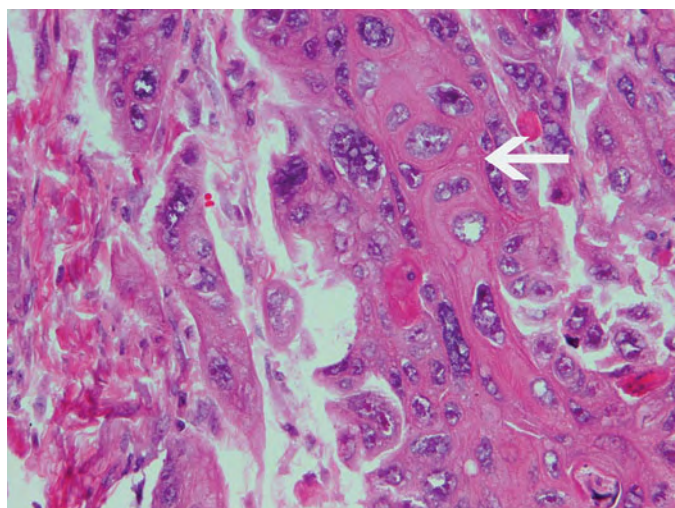
**Basic description:** Cells that initiate and sustain a neoplasm.

#### Important points

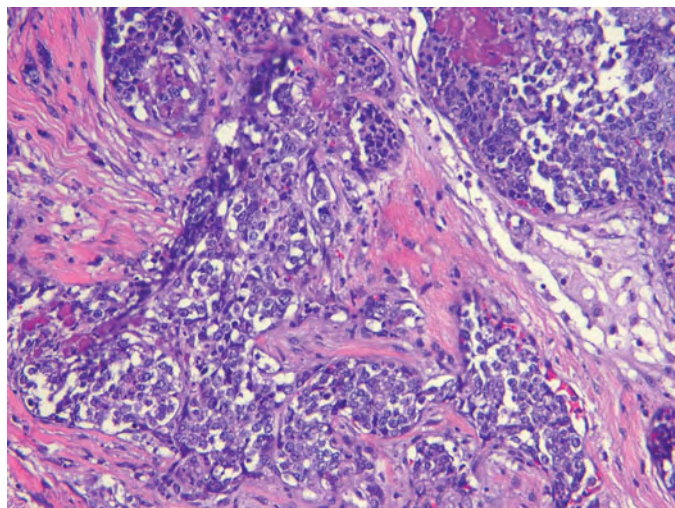
- Eradication of the neoplasm requires removal of the stem cells.
- Stem cells must have the *BMI1* gene—the protein product of the *BMI1* gene inhibits p16INK4a and p14ARF. p16INK4a and p14ARF normally function to inhibit the cell cycle.

## EPIDEMIOLOGY AND ETIOLOGY OF CANCER

**Overview:** In descending order of frequency, the most frequently diagnosed neoplasms (i.e., incidence) in males are carcinomas of the prostate, lung, and colon. In females, the most frequently diagnosed neoplasms are carcinomas of the breast, lung, and colon. Mortality due to neoplasms varies slightly from the incidence, with carcinomas of the lung accounting for the most frequent cause of cancer deaths in males and females, followed by prostatic and colonic neoplasms in males and breast and colonic carcinomas in females.



**Figure 4-3.** Well to moderately differentiated squamous cell carcinoma. The cell of origin for this tumor (squamous cell) can be determined from the histologic appearance of the tumor. The arrow indicates the interconnecting nature of the cells. Keratin pearls and intercellular bridges are characteristic of well to moderately differentiated squamous cell carcinoma. Hematoxylin and eosin, 400X.



**Figure 4-4.** Poorly differentiated squamous cell carcinoma. Unlike the neoplasm illustrated in Figure 4-3, the cell of origin for this tumor cannot be adequately determined from the histologic appearance alone. No keratin pearls or intercellular bridges are apparent. Hematoxylin and eosin, 200X.

Although the development of many neoplasms is a sporadic event, certain heritable conditions predispose to the development of malignancy. These hereditary causes of neoplasms may be grouped into autosomal dominant neoplasia syndromes (Table 4-1) and defective DNA repair syndromes (Table 4-2), most of which are autosomal recessive. Importantly, although certain mutations are associated with the development of certain malignancies, *one mutation alone is NOT enough to result in the development of a neoplasm*.

Although there are familial neoplasms associated with specific inherited mutations, most familial neoplasms have no identifiable inherited mutation. A familial neoplasm is defined as a neoplasm seen in many generations in the same family. The features of familial neoplasms include early onset, tumors in two or more close relatives, and multiple or bilateral tumors. Examples include breast, ovarian, and colon cancers. The risk for these neoplasms can be increased in families, most times with no well-defined hereditary condition. For example, the mutations of the *BRCA-1* and *BRCA-2* genes are associated with breast carcinoma; however, only 2–4% of families with familial breast cancer have an identified mutation in either of these two genes.

In addition to familial neoplasms, both with and without an identifiable inheritable mutation, certain preneoplastic conditions (Table 4-3), exogenous toxins (i.e., carcinogens) (Table 4-4), and viral infections also predispose to the development of neoplasms.

#### Viruses associated with neoplasms

##### 1. Human T-cell leukemia virus type 1 (HTLV-1)

- **Associated neoplasm:** Adult T-cell leukemia/lymphoma.
- **Mechanism:** *TAX* gene of HTLV-1 can activate transcription of host cell genes, including *c-fos* and interleukin-2 (IL-2), which are both important in the proliferation and differentiation of T cells.

##### 2. Human papillomavirus (HPV)

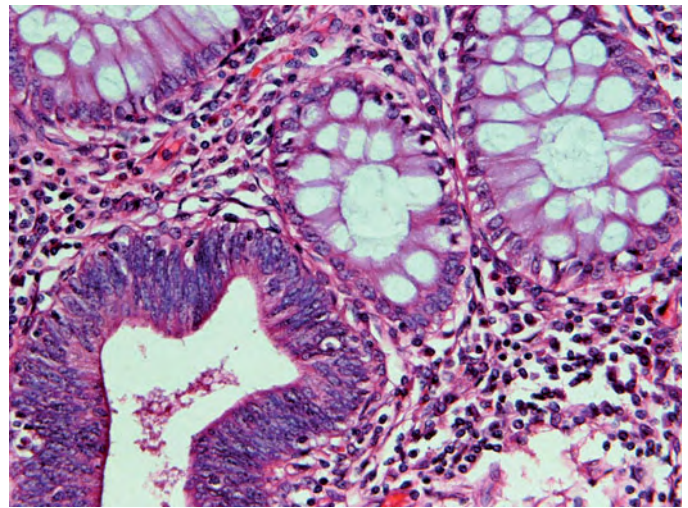
- **Associated neoplasm:** Squamous cell carcinoma of the cervix (Figure 4-11).
- **Mechanism:** Production of viral E6 and E7 proteins, which interfere with the function of p53 and RB, respectively.

##### 3. Epstein-Barr virus (EBV)

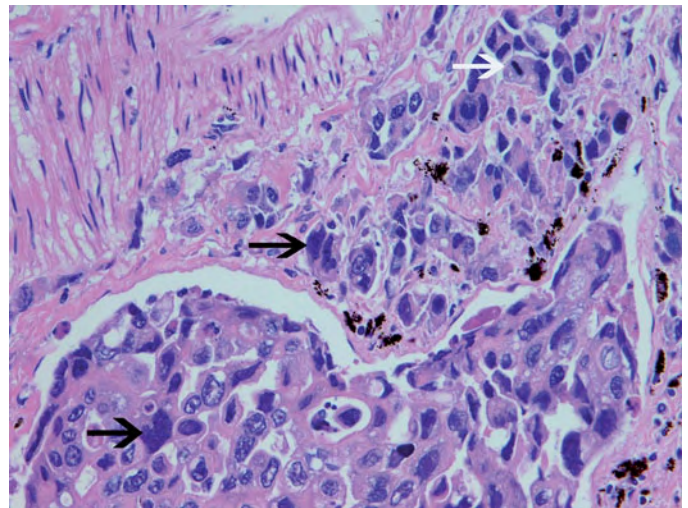
- **Associated neoplasms:** Burkitt lymphoma, post-transplantation lymphoproliferative disorder, B-cell lymphomas in AIDS patients, nasopharyngeal carcinoma, and some cases of Hodgkin lymphoma.
- **Mechanism:** EBV enters B cells through binding with CD21. EBV viral genes activate the transcription of latent membrane protein-1 (LMP-1), which activates nuclear factor- $\kappa$ B (NF- $\kappa$ B and JAK/STAT (Janus kinase/signal transducers and activation of transcription) signaling pathway. Activation of the JAK/STAT pathway promotes B cell survival.

##### 4. Hepatitis B virus (HBV)

- **Associated neoplasm:** Hepatocellular carcinoma.
- **Mechanism:** Through chronic inflammation; also because HBV protein binds p53, interfering with its function.



**Figure 4-5.** Dysplasia. This photomicrograph illustrates colonic dysplasia in a tubular adenoma. The gland in the left lower corner is dysplastic. The epithelial cells have features of neoplasia (i.e., increased cellularity, hyperchromatic nuclei, and mitotic figures). The remainder of the glands shown in the photomicrograph are histologically normal. Dysplasia is often a precursor of malignancy. Hematoxylin and eosin, 400 $\times$ .



**Figure 4-6.** Cellular features of malignancy. The photomicrograph illustrates an anaplastic neoplasm with hypercellularity, nuclear hyperchromasia (black arrows), and mitotic figures (white arrow). However, in most cases, cellular features alone cannot distinguish a benign neoplasm from a malignant neoplasm. Hematoxylin and eosin, 400 $\times$ .



5. ***Helicobacter pylori***: MALTomas of the stomach (neoplasm of mucosa-associated lymphoid tissue).
6. **Human herpesvirus 8 (HHV-8)**: Primary effusion lymphoma and Kaposi sarcoma.

## EFFECTS OF TUMORS

**Overview:** The effects of tumors are often based upon the location of the tumor; however, neoplasms and their products can also have more systemic effects, such as cachexia and paraneoplastic syndromes.

**Effects of tumors based upon location** (Figures 4-12 and 4-13): Consider the location of the tumor to determine the effects. The following list is an extensive, but not exhaustive, list of various effects neoplasms may have based upon their location.

- A 2.0-cm tumor in the brainstem may kill a patient; a 2.0-cm tumor in the leg may not even be noticed.
- A space-occupying lesion can obliterate bone marrow causing pancytopenia, impinge upon the brain leading to herniations, or it can block a cardiac valve orifice.
- Growth of a mass can impinge upon vasculature and can cause ischemia and infarction of tissue (with arterial compression) or congestion and infarction of tissue (with venous compression).
- Invasion of a blood vessel can lead to hemorrhage within a cavity (e.g., pleural or peritoneal) or hemorrhage into an organ, causing symptoms of hemoptysis or blood in the urine or feces.
- Invasion of a nerve can lead to neurologic deficits or pain.
- A mass can cause ulceration of overlying mucosa.
- A mass in the brain can serve as a focus for seizures or other neurologic deficits.
- A mass can obstruct the colon causing constipation; obstruct the bile duct causing jaundice; or obstruct the bronchus causing pneumonia or bronchiectasis.
- Bone destruction can lead to fracture (i.e., pathologic fracture).

### Cachexia

- **Basic description:** Loss of body fat and muscle; weakness and anorexia associated with a neoplasm.
- **Mechanism:** Caused by cytokines produced by the tumor (possibly tumor necrosis factor) and by host response to the tumor.

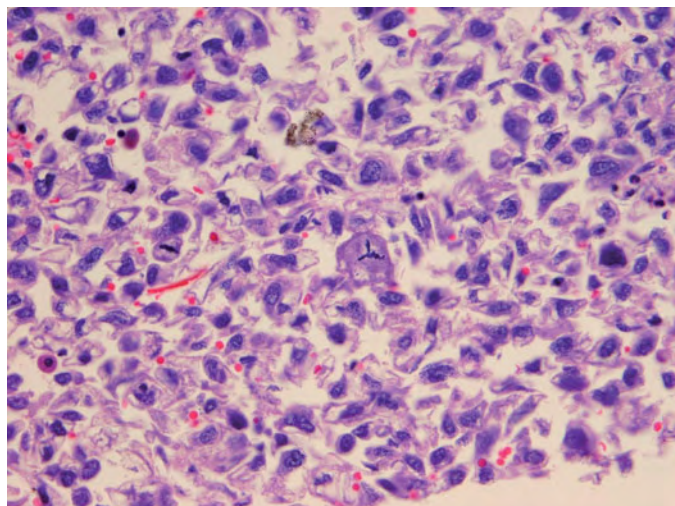
### Paraneoplastic syndromes

- **Basic description:** Side effects of a neoplasm not attributable to functions normally associated with the cell type of origin or by the location of the tumor.

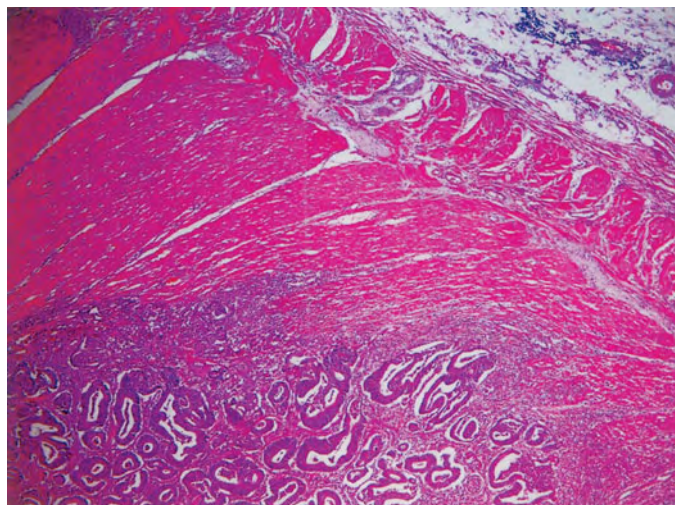
**Types of paraneoplastic syndromes**, including production of hormone-like proteins and nerve and muscle syndromes, are listed below.

#### 1. Hormone production

- **Parathyroid hormone (PTH)-like protein:** Produced by squamous cell carcinoma of the lung, breast carcinoma, and renal cell carcinomas; results in hypercalcemia.



**Figure 4-7.** Abnormal mitotic figure. In the center of this photomicrograph is a neoplastic cell with a tripolar mitotic figure. Although increased numbers of mitotic figures can be seen in non-neoplastic cells (e.g., normal epithelial cells and reactive processes), abnormal mitotic figures usually indicate a neoplastic process, and most often a malignant process. Hematoxylin and eosin, 400 $\times$ .



**Figure 4-8.** Colonic adenocarcinoma with invasion into the muscularis propria. This low-power photomicrograph of the colonic muscularis propria illustrates invasion into the wall by a colonic adenocarcinoma. Invasion as well as metastases is a definite indicator of a malignant neoplasm. Hematoxylin and eosin, 40 $\times$ .

- **Adrenocorticotrophic hormone (ACTH)-like protein:** Produced by small cell lung carcinoma and pancreatic carcinoma; results in **Cushing syndrome**.
  - **Syndrome of inappropriate antidiuretic hormone (SIADH):** Produced by small cell carcinoma of the lung and cerebral neoplasms; results in retention of water.
  - **Erythropoietin:** Produced by renal cell carcinoma, hepatocellular carcinoma, and cerebellar hemangioblastoma; results in polycythemia.
2. **Nerve and muscle syndromes, including Lambert-Eaton syndrome,** which is a myasthenia gravis-like syndrome produced by small cell carcinoma of the lung and is due to antibodies against presynaptic  $\text{Ca}^{2+}$  channels at the neuromuscular junction.

## CARCINOGENESIS

**Overview:** For a cell to change from a normal cell to a malignant cell, it must follow several steps.

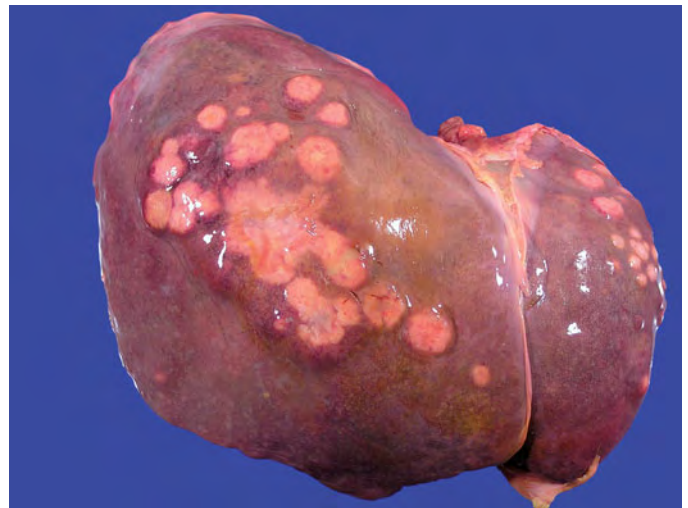
1. Acquire self-sufficiency in growth signals and ignore growth-inhibitory signals.
2. Evade apoptosis, since apoptosis is the body's mechanism to rid itself of cells with genetic damage so they cannot propagate that damage.
3. Acquire defects in DNA repair.
4. Acquire the ability to divide an unlimited number of times.
5. Promote angiogenesis.
6. Invade surrounding tissue, passing through the basement membrane and spreading to distant organs (i.e., metastasize).

### Process of carcinogenesis

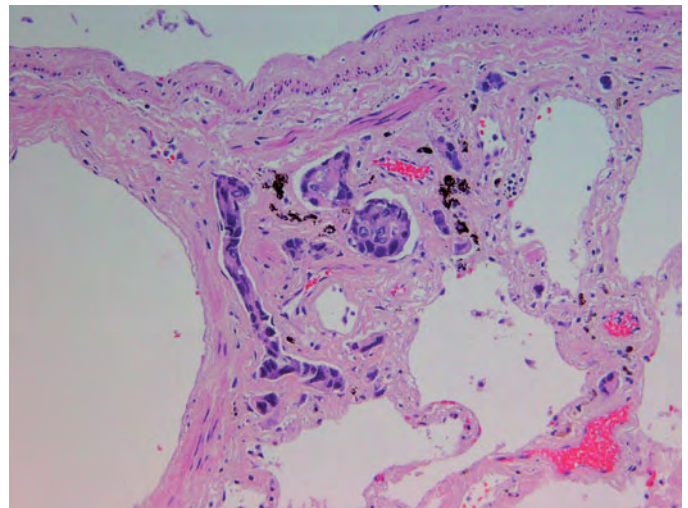
- The cell acquires mutations, which are nonlethal, so the cell can survive to divide and thus propagate the mutations. Mutations are acquired through damage caused by **initiators**. **Promoters** cause cell growth through promotion of the cell cycle and thus cause the propagation of mutations induced by initiators. Neither an initiator nor a promoter acting on its own can cause neoplasia; both must act on the cells.

### Genes most commonly affected during carcinogenesis

- **Proto-oncogenes:** Proto-oncogenes are genes commonly used during normal growth and development; without control, they have the potential to produce neoplasms through their uncontrolled expression. Oncogenes are genes that have made the transition and are now capable of producing neoplasms. Most commonly, oncogenes cause unregulated cell growth through promotion of cellular division, which results in further mutations.
- **Tumor suppressor genes:** Genes that function to help control cell growth; their loss thus results in uncontrolled cell growth through loss of regulation of division.
- **Apoptosis genes.**
- **DNA repair genes.**



**Figure 4-9.** Colonic adenocarcinoma metastases to the liver. The tan-yellow nodules in the left and right lobes of this liver are metastases from a colonic adenocarcinoma. Metastasis as well as invasion is a definite indicator of a malignant neoplasm. The most common malignant neoplasm of the liver is a metastasis; however, the most common malignancy that metastasizes to the liver is a pulmonary neoplasm.



**Figure 4-10.** Lymphatic invasion by a carcinoma. The clusters of neoplastic cells in the center of this photomicrograph represent lymphatic invasion by a carcinoma (the lymphatics are within the lung). Malignant neoplasms most commonly metastasize via lymphatic or hematogenous routes. Lymphatic metastases are most commonly associated with carcinomas, and hematogenous metastases are most commonly associated with sarcomas. Hematoxylin and eosin, 400 $\times$ .



**TABLE 4-1.** Autosomal Dominant Neoplasia Syndromes

Syndrome	Gene	Chromosome Location	Associated Neoplasm(s)
Familial retinoblastoma	<i>RB</i>	13q14	Retinoblastoma, osteosarcoma
FAP	<i>APC</i>	5q21	Colonic adenocarcinoma
Li-Fraumeni	<i>p53</i>	17p13.1	Sarcomas, breast carcinoma
MEN 1	<i>MEN1</i> (menin)	11q13	Pituitary adenomas, parathyroid hyperplasia, pancreatic endocrine neoplasms
MEN 2a	<i>RET</i>	10q11.2	Medullary thyroid carcinoma, pheochromocytoma
VHL	<i>VHL</i>	3p25	Cerebellar hemangioblastoma, renal cell carcinoma

RB, retinoblastoma; FAP, familial adenomatous polyposis; APC, adenomatous polyposis coli; MEN, multiple endocrine neoplasia; RET, rearranged during transfection; VHL, von Hippel-Lindau.

**Table 4-2.** Defective DNA Repair Syndromes

Syndrome	Inheritance Pattern	Gene	Associated Neoplasm(s)
Xeroderma pigmentosum	Autosomal recessive	One of several for nucleotide excision repair	Skin cancer
Ataxia-telangiectasia*	Autosomal recessive	<i>ATM</i>	Lymphoid malignancies
Hereditary nonpolyposis colon cancer	Autosomal dominant	<i>MSH2</i> , <i>MLH1</i> , <i>MSH6</i>	Colonic adenocarcinoma

ATM, ataxia-telangiectasia mutated.

\*Ataxia-telangiectasia is also associated with cerebellar ataxia.

**Table 4-3.** Preneoplastic Conditions\*

Condition	Example
Persistent regeneration and repair	Hepatocellular carcinoma arising in cirrhosis
Hyperplastic process	Endometrial carcinoma arising in endometrial hyperplasia
Dysplastic process	SCC of cervix arising in CIN; colonic adenocarcinoma arising in adenomatous polyp
Chronic inflammation	Gastric adenocarcinoma arising in atrophic gastritis; colonic adenocarcinoma arising in ulcerative colitis

SCC, squamous cell carcinoma; CIN, cervical intraepithelial neoplasia.

\*Although this table lists non-neoplastic processes that have the potential to promote a neoplastic process, not all forms of the listed preneoplastic conditions have the potential for development of a neoplastic process. For example, most forms of chronic pancreatitis are not thought to predispose to the development of pancreatic adenocarcinoma.

### Important points regarding genes involved with carcinogenesis

- No one mutation will result in a malignant neoplasm; malignant neoplasms result from the survival of cells that have accumulated multiple mutations.
- Conversion of one of the two allelic genes from a proto-oncogene to an oncogene is sufficient to promote neoplasia. However, it requires loss of both tumor suppressor genes to promote neoplasia, as one of the two genes is sufficient to produce enough product to inhibit neoplasia.

### Methods of conversion of proto-oncogene to oncogene

- Overexpression of the gene.
- Amplification of the gene.
- Point mutation in the gene.
- Translocation of the gene to another region with resultant overexpression of the gene, or resultant production of protein with oncogenic activity.

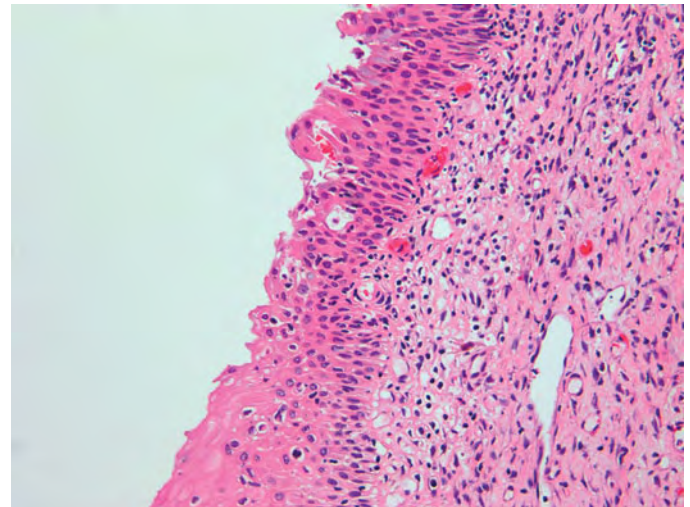
### Role of oncogenes

**Overview:** Once converted from proto-oncogenes, oncogenes function by synthesizing growth factors, growth factor receptors, signal-transducing proteins, and nuclear transcription factors, or by promoting loss of regulation of cyclins and cyclin-dependent kinases.

1. **Synthesize growth factors** to which the neoplastic cell is also responsive. For example, glioblastomas produce platelet-derived growth factor (PDGF).
2. **Synthesize growth factor receptors.** For example,
  - RET receptor for glial cell line-derived neurotrophic factor—in medullary and papillary thyroid carcinoma (MEN syndrome).
  - ERB B1, an epidermal growth factor (EGF) receptor, is overexpressed in squamous cell carcinoma of the lung.
  - ERB B2, an EGF receptor, is overexpressed in 25% of breast carcinomas.
3. **Synthesize signal-transducing proteins:** An example of a specific gene is the **RAS** gene.
  - Incidence of mutations in RAS gene: Mutations of the RAS gene are in 30% of all malignant neoplasms and in 90% of pancreatic adenocarcinomas.
  - Role of normal RAS gene: The RAS gene codes for protein that is associated with a growth factor receptor. When stimulated by a growth factor, RAS binds guanosine triphosphate (GTP) and activates the mitogen-activated protein (MAP) kinase pathway, which results in activation of transcription. The RAS protein is controlled by its GTPase activity; it cleaves the GTP bound to it to guanosine diphosphate (GDP), which inactivates the RAS protein.
  - Effects of mutations in the RAS gene: The RAS protein loses its GTPase activity, so it remains activated, resulting in continual promotion of transcription.
4. **Synthesize nuclear transcription factors:** An example of a specific gene is the **MYC** gene.

**Table 4-4.** Select Carcinogens and Their Associated Neoplasms

Carcinogen	Associated Neoplasm(s)
Aflatoxin	Hepatocellular carcinoma
Thorotrast	Angiosarcoma of the liver
Vinyl chloride	Angiosarcoma of the liver
Asbestos	Mesothelioma, bronchogenic carcinoma
Arsenic	Squamous cell carcinoma of the liver
Aniline dyes	Transitional cell carcinoma of the bladder
Nitrosamines	Gastric adenocarcinoma
Polycyclic hydrocarbons	Bronchogenic carcinoma



**Figure 4-11.** Cervical dysplasia. Those cells lining the top half of the cervix shown in the photomicrograph are dysplastic (increased cellularity, loss of polarity, increased nuclear hyperchromasia, and increased numbers of mitotic figures). Those lining the lower half of the cervix shown in the photomicrograph are more histologically normal in appearance. Cervical dysplasia is a precursor to cervical squamous cell carcinoma, and is a result of infection with human papillomavirus. Hematoxylin and eosin, 200 $\times$ .

- Neoplasms associated with mutations of the *MYC* gene: Burkitt lymphoma; also amplified in breast, lung, and colon cancers.
- Role of normal *MYC* gene: *MYC* protein binds to DNA and activates transcription of several genes, including cyclin-dependent kinases (CDK). CDK proteins help drive the cell through the cell cycle.
- Effect of activation to oncogene: Overexpression of *MYC* results in overpromotion of the cell cycle.

## 5. Loss of regulation of cyclins and cyclin-dependent kinases.

### Mutations in tumor suppressor genes

**Important point:** The **two-hit hypothesis** implies that with many hereditary neoplasms a tumor suppressor gene is involved. The protein product from one gene is enough to prevent neoplasms from developing; however, individuals born with a mutation of one gene are one step closer to the development of a neoplasm than those born with two normal genes.

**Select tumor suppressor genes:** Within neoplasms, the most common tumor suppressor genes with mutations are retinoblastoma and *p53*.

#### 1. Retinoblastoma (*RB*) gene

- **Associated neoplasms:** Familial retinoblastoma and osteosarcoma; breast cancer and small cell lung carcinoma.
- **Role of normal *RB* gene:** Retinoblastoma binds E2F transcription factor, which is needed for the cell to move from the G1 phase of the cell cycle to the S phase. When retinoblastoma is phosphorylated, the E2F is released and the cell moves through the cell cycle.
- **Effect of mutations of *RB* gene:** Can affect retinoblastoma or the proteins that phosphorylate retinoblastoma, resulting in hyperphosphorylation of RB.

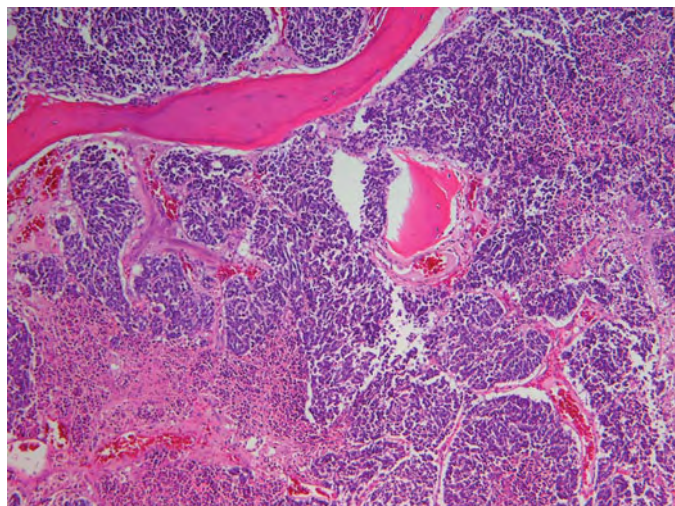
#### 2. *p53* gene

- **Incidence:** Mutations of the *p53* gene are found in more than 70% of tumors.
- **Role of normal *p53* gene**
  - Activated by DNA damage.
  - *p53* arrests the cell cycle by transcription of CDK1 (p21), which inhibits cyclin/CDK complexes and prevents phosphorylation of RB.
  - *p53* promotes production of GADD45, which helps repair the cell.
  - If cellular damage is not repaired, *p53* promotes induction of the *Bax* gene, which in turn promotes apoptosis.

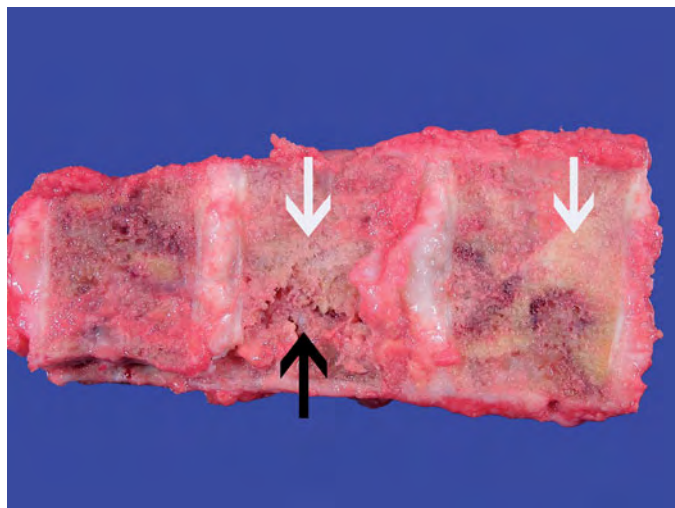
#### 3. Other tumor suppressor genes include *APC*/ $\beta$ -catenin, *INK4a*/*ARF*, *TGF- $\beta$* , *NF-1*, *VHL*, and *PTEN*, as described below.

##### *APC*/ $\beta$ -catenin

- **Normal function of protein product:** APC protein down-regulates  $\beta$ -catenin.
- **Effect of mutation:** Elevated levels of  $\beta$ -catenin result in interaction with TCF, which results in increased levels of c-MYC and cyclin D1.



**Figure 4-12.** Carcinoma metastatic to the bone marrow. The normal hematopoietic cells have been replaced by neoplastic cells. Only the bony trabeculae are still visible in the section. The effects of such a metastatic neoplasm would be related to the loss of normal hematopoietic cells (e.g., anemia, increased risk for infections, bleeding disorder). Hematoxylin and eosin, 20 $\times$ .



**Figure 4-13.** Carcinoma metastatic to the vertebral column. This vertebral column has metastases (white arrows). The effects of such metastases (i.e., to the bone) would be the weakened structural integrity of the bone and predisposition to fractures (black arrow). When fractures of the bone are due to an underlying process, such as a malignant neoplasm, they are referred to as pathologic fractures.

- **Incidence:** Found in 70–80% of nonfamilial colon carcinomas; also found in 50% of hepatoblastomas and 20% of hepatocellular carcinomas.

#### **INK4a/ARF**

- **Normal function of protein product:** Blocks cyclin D-CDK4 activity in the cell cycle.
- **Incidence:** 20% of familial melanomas, 50% of pancreatic adenocarcinomas, and squamous cell carcinomas of the esophagus.

#### **TGF- $\beta$ (transforming growth factor beta)**

- **Incidence:** Inactivated in more than 70% of colon cancers in patients with hereditary nonpolyposis colon cancer (HNPCC) and in patients with sporadic colon cancer with microsatellite instability.
- **Associated mutation:** **SMAD4** (originally termed **DPC4** [deleted in pancreatic cancer]). *SMAD4* encodes part of the TGF- $\beta$  growth inhibitory pathway. Mutations of *SMAD4* are seen in 50% of cases of pancreatic adenocarcinomas.

#### **NF-1**

- **Normal function of protein product:** Neurofibromin is a GTPase-activating enzyme.
- **Effect of mutation:** RAS is trapped in an active form.
- **Associated neoplasms:** Neurofibromas and malignant peripheral nerve sheath tumors.

#### **VHL**

- **Normal function of protein product:** VHL protein is a ubiquitin ligase whose substrate includes HIF-1, which regulates vascular endothelial growth factor (VEGF).
- **Associated neoplasms:** Nonfamilial renal cell carcinomas.

#### **PTEN (phosphatase and tensin homologue)**

- **Normal function of protein product:** Blocks the cell cycle by increased transcription of *p27*.
- **Effect of mutation:** Cells are allowed to easily progress into the cell cycle.
- **Incidence:** Frequently found in endometrial carcinomas and glioblastomas; associated with **Cowden syndrome**.

#### **Apoptosis genes**

##### **1. Bcl-2**

- **Normal function:** Inhibitor of apoptosis.
- **Method of activation:** Often a translocation of *bcl-2* gene adjacent to a more heavily used gene, such as the immunoglobulin (Ig) heavy chain gene.
- **Consequence of activation:** Increased production of bcl-2, resulting in inhibition of apoptosis.
- **Associated neoplasm:** Follicular lymphoma.

##### **2. p53**

- **Normal function:** Promotes production of *Bax* (a pro-apoptotic gene).
- **Consequence of mutation:** Less p53 results in less Bax, which indirectly causes inhibition of apoptosis.

**Table 4-5.** Select Tumor Markers and Their Associated Neoplasm

Tumor Marker	Associated Neoplasm(s)
Prostate-specific antigen	Prostatic adenocarcinoma
Carcinoembryonic antigen	Colonic and pancreatic adenocarcinoma
$\alpha$ -Fetoprotein (AFP)	Hepatocellular carcinoma, yolk sac tumors
$\beta$ -Human chorionic gonadotropin ( $\beta$ -hCG)	Choriocarcinoma
Tartrate resistant acid phosphatase	Hairy cell leukemia
CA-125	Ovarian carcinoma
S-100	Melanoma
Alkaline phosphatase	Bony metastases



## DNA repair defects

### Basic descriptions

- **Microsatellites:** Repeats of 1–6 nucleotides in the genome; these are fixed and do not change.
- **Microsatellite instability:** Changes in microsatellites, indicative of a DNA repair defect.

DNA repair defects occur in one of three systems: Recombination repair, mismatch repair, or nucleotide excision.

### Development of ability to invade and metastasize

1. Detachment of cells (example method: down regulation of e-cadherin seen in colon and breast carcinomas).
2. Attachment to matrix (general method: expression of increased numbers of laminin and fibronectin receptors).
3. Degradation of extracellular matrix (general method: production of metalloproteinases).
4. Migration of tumor cells (general method: increased expression of CD44 adhesion molecule, which is used by T lymphocytes to migrate to lymph nodes).

## GENERAL MORPHOLOGY OF CANCER DEVELOPMENT IN EPITHELIAL CELLS

**Overview:** Normal cells progress through hyperplasia (increase in the number of normal cells) to dysplasia (disorganized cell growth, with cells having hyperchromasia, mitotic figures, and increased nuclear to cytoplasmic ratio) to in situ carcinoma (dysplastic changes throughout the full thickness of the epithelium with no evidence of invasion), to invasive carcinoma (tumor cells invading through basement membrane), and finally to metastatic carcinoma (tumor cells spreading to distant organs).

## TUMOR ANTIGENS

**Basic description:** Antigens specific for the tumor, which can provoke an inflammatory response.

### Mechanisms of production

- Product of mutated oncogene or tumor suppressor gene.
- Protein produced by oncogenic virus.
- Altered cell surface glycoprotein/glycolipid.
- Overexpressed protein.
- Oncofetal antigens.
- Cell-type-specific differentiated antigen (such as expression of CD10).

### Methods of evading detection by immune system

- Growth of antigen-negative variant.
- Apoptosis of cytotoxic T cells through production of FAS ligand.
- Immunosuppression.
- Loss of MHC molecule.

**Table 4-6.** Select Immunohistochemical Stains

Immunohistochemical Stain	Neoplasms that Stain Positive
Cytokeratin	Carcinomas
Desmin	Benign and malignant neoplasms of smooth and skeletal muscle
Glial fibrillary acidic protein (GFAP)	Astrocytomas
HMB-45	Melanoma
$\alpha$ -Fetoprotein (AFP)	Hepatocellular carcinoma, yolk sac tumor
Chromogranin A	Small cell carcinoma

## DIAGNOSIS OF NEOPLASMS

**Overview:** Noninvasive methods to detect neoplasms at an early point in their development are crucial to improving prognosis. Tumor markers are proteins secreted into the blood by neoplasms, allowing for diagnosis of the tumor or for monitoring of the tumor following treatment (Table 4-5). Metastatic nodules and poorly differentiated neoplasms, as well as those sharing histologic features, may be difficult to diagnose microscopically; and, in the case of metastatic nodules, determining the site of origin is crucial for patient care. Immunohistochemistry is a specialized form of histology employing antibodies to identify specific proteins within the tumor to allow for better differentiation of tumor type (Table 4-6).

## GRADE AND STAGE

**Grade** is the differentiation of a tumor as determined by the pathologist (i.e., subjective evaluation). Differentiation is how similar the tumor cells look when compared with the cell type of origin. For example, well-differentiated squamous cell carcinoma looks very similar to stratum corneum, and poorly differentiated squamous cell carcinoma may be difficult to determine without immunohistochemical stains directed against squamous cell-specific proteins.

**Stage** is the extent of the tumor based upon both objective pathologic and objective clinical criteria. The most common system used is TNM (T = tumor characteristics, N=lymph node status, and M = metastases). The stage of the tumor has good prognostic value.

# CHAPTER 5

## ENVIRONMENTAL AND NUTRITIONAL PATHOLOGY

### OVERVIEW

The list of toxins the human body can be exposed to is extensive. Since the list of toxins and their pathologic effects is so numerous, only some of the major toxins and their effects will be discussed in this chapter. Of these, by far the two most commonly encountered toxins are tobacco smoke and alcohol. In addition to a few major toxins, this chapter will also discuss very basic physical trauma and nutritional deficiencies.

The metabolism of xenobiotics (i.e., mechanism for removal of foreign substances such as drugs from the body) occurs via two phases. Phase I reactions involve attachment of polar functional groups to the substance, and phase II reactions involve conjugation of the substance. One important point concerning therapeutic implications is the concept that genetic variations in levels of cytochrome P-450 isozymes produce both “rapid metabolizers” and “slow metabolizers” and can result in toxic levels of medication in a patient on an otherwise normal therapeutic dose.

### SOME SELECTED TOXIC SUBSTANCES

#### CIGARETTE SMOKE

**Constituents:** Polycyclic aromatic hydrocarbons, arsenic, nickel, carbon monoxide, hydrogen cyanide, nicotine.

**Effects of nicotine:** Increased heart rate, increased blood pressure.

#### Important points

- About 30% of all cancer deaths and 90% of all lung cancer deaths are related to smoking.
- Pregnant females who smoke 10 or more cigarettes a day can induce hypoxia in their fetuses, which leads to complications that include decreased fetal weight and prematurity and to **premature rupture of membranes** and **placental abruption** at the time of delivery.



## ETHANOL

### Toxic levels

- Naïve users: 0.3 to 0.4 mg/dL can result in coma or death.
- Tolerant users: Can develop levels up to 0.7 mg/dL.

### Complications of ethanol use by organ system

- **Liver:** Fatty change; hepatitis due to direct toxic effect of ethanol on hepatocytes; and cirrhosis, which occurs in only 10–15% of chronic alcoholics.
- **Central nervous system (CNS):** Thiamine deficiency, which may present as **Wernicke encephalopathy** (Figure 5-1) or **Korsakoff syndrome** (amnesia and confabulation). Morphologic features of thiamine deficiency include periventricular hemorrhage and petechiae of the mammillary bodies and cerebellar atrophy. Complications of ethanol use include alcohol withdrawal and associated delirium tremens.
- **Cardiovascular:** Dilated cardiomyopathy, hypertension.
- **Gastrointestinal:** Gastritis, pancreatitis.
- **Reproductive:** **Fetal alcohol syndrome** is associated with mental retardation, microcephaly, maxillary hypoplasia, smooth philtrum, short palpebral fissure, and atrial septal defects.

## ALCOHOL WITHDRAWAL

**Mechanism:** Chronic alcohol use causes depression of  $\alpha$ -receptors and  $\beta$ -receptors and enhances  $\gamma$ -aminobutyric acid (GABA), which serve as a stimulus to increase baseline neuronal activity. Therefore, when alcohol is withdrawn, patients have a sudden excited state of CNS activity because the depressive effect of the alcohol is removed.

**Clinical presentation:** Tachycardia, hypertension, tremulousness, and hyperreflexia.

**Complications of alcohol withdrawal:** Seizures (10%); hallucinations, usually visual (25%); and delirium tremens (5%). Severe alcohol withdrawal is life threatening, causing dehydration, hyperthermia, and electrolyte imbalances. A cardiac dysrhythmia can occur due to hypokalemia or hypomagnesemia.

- **Delirium tremens:** Confusion, disorientation, tactile hallucinations (often of bugs on skin), and marked tremor.

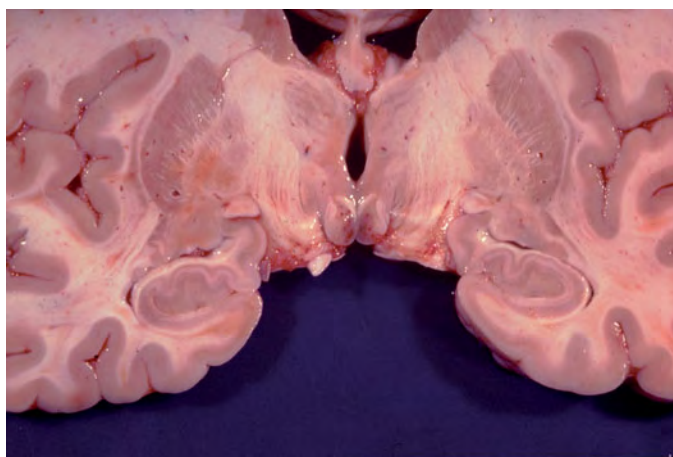
**Treatment of alcohol withdrawal:** Benzodiazepines; treatment of dehydration and electrolyte disturbances.

## COCAINE

### Mechanism

- Blocks reuptake of dopamine, activating reward centers in the CNS.
- Blocks reuptake of norepinephrine and epinephrine, leading to vascular constriction.

**Complications:** Sudden cardiac death, atherosclerosis, cardiac hypertrophy, intracerebral hemorrhage, rhabdomyolysis, placental abruption.



**Figure 5-1.** Wernicke encephalopathy. Note the punctate hemorrhages in the mammillary bodies. Wernicke encephalopathy is a complication of chronic alcohol abuse due to an accompanying thiamine deficiency.

## LEAD

### Source

- **Occupational:** Painting, foundry work, mining.
- **Nonoccupational:** Children eating lead-based paint chips.

**Complications:** Anemia; chronic renal tubulointerstitial disease; in children, bone defects.

**Clinical presentation:** In children, abdominal pain is a common complaint. Findings include microcytic hypochromic anemia with basophilic stippling of red blood cells and lead lines on the gingivae and in long bones seen on plain films. Encephalopathy is seen in severe cases. Saturnine gout is characterized by the triad of lead nephropathy, gout, and hypertension, and is associated with homemade “moonshine” produced in lead-containing stills.

## CYANIDE

**Mechanism:** Colorless gas with the odor of almonds. It binds and inactivates cytochromes of the electron transport chain, thus inhibiting the biochemical pathway of respiration.

**Clinical presentation:** Commonly seen with smoke inhalation; occasionally seen with nitroprusside toxicity. Patients have rapid onset of weakness, shortness of breath, convulsions, and coma. Patients present with cherry red skin due to impaired extraction of oxygen from hemoglobin.

## CARBON MONOXIDE

**Mechanism:** Hemoglobin has 200 times more affinity for carbon monoxide than for oxygen. Carboxyhemoglobin binds oxygen more avidly, resulting in impaired delivery of oxygen to tissues.

**Presentation:** Common in smoke inhalation, enclosed exposure to automobile exhaust, or in the wintertime with home furnaces. Patients present with cherry red skin (classic), flu-like symptoms, headache, and neurologic symptoms (Figure 5-2).

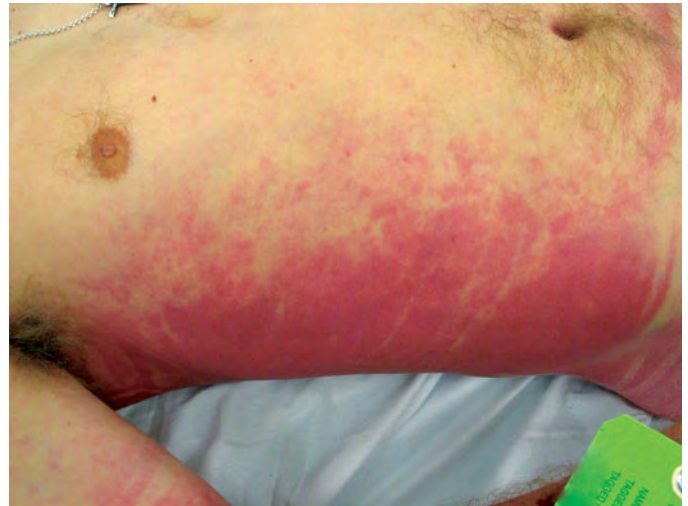## IONIZING RADIATION

**Acute disease:** Features include atrophy of bone marrow, erythema of skin, edema and ulcers of the gastrointestinal tract, and edema and necrosis of the brain.

**Delayed disease:** Features include leukemia, atrophy of the epidermis, and fibrosis of the dermis (600–1000 times increased risk of skin cancer), ulcers and fibrosis of the stomach, and white matter gliosis.

**Severity of disease is based upon roentgen-equivalent-man (REM) exposure.** For example,

- < 200 REM: Subclinical effects.
- 200–600 REM: Hematologic effects predominantly with decreased neutrophils and lymphocytes.
- 600–1000 REM: The above listed hematologic effects plus gastrointestinal effects of pronounced nausea, vomiting, and diarrhea.



**Figure 5-2.** Cherry-red lividity due to carbon monoxide poisoning. This man committed suicide by remaining in a car with the windows closed and the engine running. Carbon monoxide produces a bright red discoloration of the blood. In this case, the lividity (post-mortem change due to settling of the blood in dependent regions of the body) is cherry red in color instead of the usual red-purple, due to the carbon monoxide, which is irreversibly bound to the hemoglobin.

- 1000 REM: The above listed hematologic and gastrointestinal effects plus CNS effects of confusion, convulsions, and coma.

**Complication of ultraviolet radiation:** Increased risk of skin cancer.

## PHYSICAL TRAUMA

**Basic descriptions** (Figures 5-3 and 5-4)

- Abrasion:** Forceful removal of epidermis.
- Contusion:** Hemorrhage into soft tissue due to forceful rupturing of blood vessels.
- Laceration:** Splitting of skin due to blunt force. Unlike an incision, lacerations have nerves, vessels, and strands of soft tissue, which bridge the wound.
- Incised wound:** Sharp force injury; the wound is longer than it is deep and has no bridging.
- Stab wound:** Sharp force injury; wound is deeper than it is long.
- Gunshot wound** (Figure 5-5): Important point for determination of distance—when the projectile leaves the barrel, soot (burned gunpowder), unburned gunpowder, and hot air also leave the barrel and can produce changes on the skin. Soot will travel up to 6 to 8 inches. Unburned gunpowder will travel up to 1 to 3 feet and strike the skin, causing small abrasions (i.e., stippling).

## THERMAL BURNS

**Basic descriptions**

- Full-thickness burn:** Involvement of epidermis, dermis, and dermal appendages.
- Partial thickness burn:** Involvement of epidermis and potentially the superficial dermis.
- Important point:** Involvement of > 50% of the total body surface area is serious (i.e., potentially lethal).

**Complications of thermal burns**

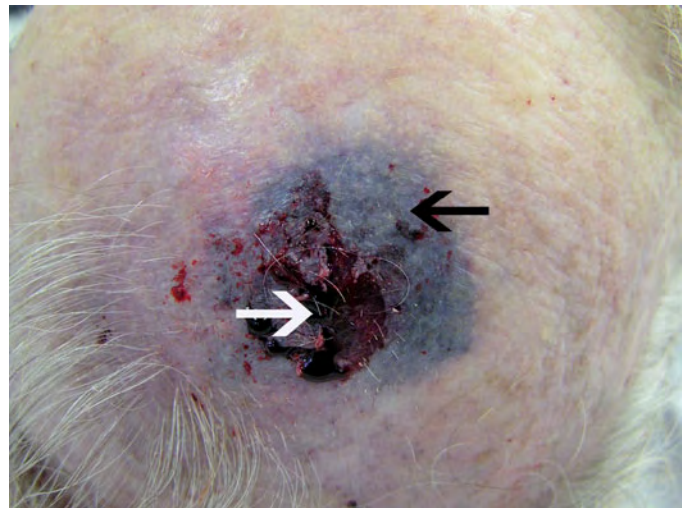- Edema, due to loss of protein.
- Electrolyte imbalances.
- Infections—particularly *Pseudomonas*.
- Increased heat loss, which induces a hypermetabolic state that requires increased nutrition.

## HYPERTHERMIA

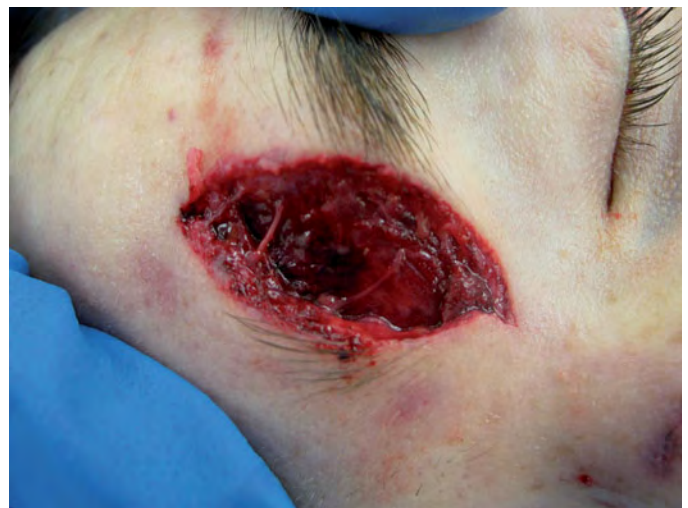**Forms of environmental hyperthermia:** Heat cramps, heat exhaustion, heat stroke.

**Heat cramps**

- Mechanism:** Loss of electrolytes through sweating.
- Manifestations:** Muscle cramps.



**Figure 5-3.** Contused abrasion of the scalp. This lesion on the scalp features components of both a contusion (*black arrow*) and an abrasion (*white arrow*).



**Figure 5-4.** Laceration. Within the depths of this wound, note the vessels crossing perpendicular to the defect. This feature is bridging. The presence of bridging will distinguish a laceration from an incised wound. Incised wounds do not have tissue bridging.



**Heat exhaustion**

- **Mechanism:** Failure of the cardiovascular system to compensate for hypovolemia, which is secondary to water depletion.
- **Manifestations:** Sudden prostration and collapse.

**Heat stroke**

- **Mechanism:** Generalized peripheral vasodilation.
- **Complications:** Necrosis of skeletal and cardiac muscle.
- **Important point:** If the rectal temperature is  $> 41^{\circ}\text{C}$  ( $> 106^{\circ}\text{F}$ ), patients have a high mortality rate (i.e., 50% chance of death).

**Other forms of hyperthermia**

- **Malignant hyperthermia:** Idiosyncratic reaction to succinylcholine and halogenated anesthetics characterized by muscle rigidity, hyperthermia, and hypertension.
- **Neuroleptic malignant syndrome:** Reaction associated with use of neuroleptic drugs.

**HYPOTHERMIA**

**Mechanism of injury:** Crystallization of water; vasoconstriction can contribute to ischemia.

**Important points:** If body temperature is  $< 32^{\circ}\text{C}$  ( $< 90^{\circ}\text{F}$ ), a patient can lose consciousness and develop bradycardia or atrial fibrillation. Osborne waves on the electrocardiogram are classic.

**NUTRITIONAL PATHOLOGY****MARASMUS**

**Basic description:** Malnutrition due to inadequate calories.

**Manifestations:** Growth retardation, decreased muscle mass.

**Important point:** Albumin level is normal.

**KWASHIORKOR**

**Basic description:** Malnutrition due to protein deprivation, which is out of proportion to the total reduction in calories.

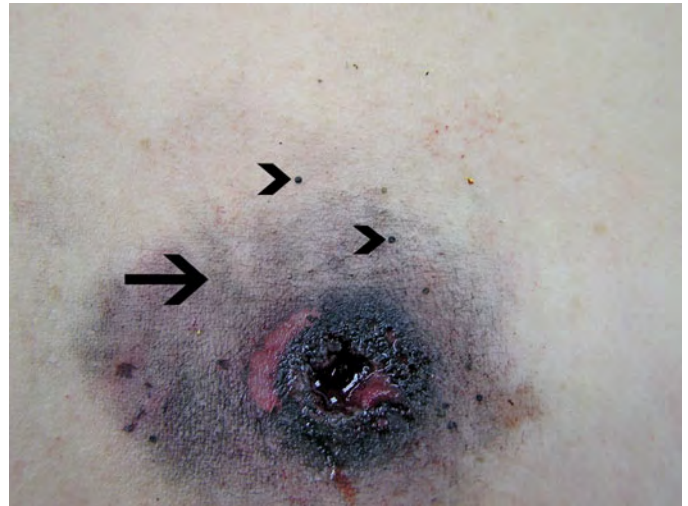**Manifestations:** Edema due to hypoalbuminemia; fatty liver.

**ANOREXIA**

**Basic description:** Self-induced starvation.

**Effects of anorexia**

- Decreased levels of gonadotropin-releasing hormone (GnRH), leading to amenorrhea.
- Decreased levels of thyroid hormone leading to cold intolerance, bradycardia, and other signs and symptoms of hypothyroidism.
- Cardiac arrhythmias due to hypokalemia.



**Figure 5-5.** Gunshot wound, close range. Surrounding this entrance-type gunshot wound is a wide rim of soot (*arrow*). Also adherent to the skin are several pellets of gunpowder (*arrowheads*). When gunpowder particles strike the skin, they cause punctate abrasions, referred to as stippling. If only stippling and no soot are present around the gunshot wound, it is considered intermediate range.

## BULIMIA

**Basic description:** Binge eating followed by purging (i.e., vomiting).

**Effects of bulimia:** Cardiac arrhythmias due to hypokalemia, pulmonary aspiration of gastric contents, esophageal rupture.

**Important point:** Enlargement of the parotid gland and abrasions on the dorsal aspect of fingers from inducing vomiting are commonly seen.

## VITAMIN DEFICIENCIES (TABLE 5-1)

### Vitamin B<sub>1</sub> (thiamine) deficiency

- Wernicke encephalopathy: Clinical presentation includes ataxia, delirium, ophthalmoplegia, and horizontal nystagmus.
- Korsakoff syndrome: Clinical presentation includes amnesia and confabulation.
- Periventricular hemorrhage and necrosis in the brain and petechiae of the mammillary bodies.
- **Dry beriberi:** General term for the effects of thiamine deficiency in the CNS; covers both Wernicke encephalopathy and Korsakoff syndrome.
- **Wet beriberi:** High output cardiac failure.

**Vitamin B<sub>2</sub> (riboflavin) deficiency:** Cheilosis, stomatitis, seborrheic dermatitis, anemia, weakness.

**Vitamin B<sub>3</sub> (niacin) deficiency:** Causes **pellagra**, the triad of diarrhea, dementia, and dermatitis.

**Vitamin B<sub>6</sub> (pyridoxine) deficiency:** Glossitis, cheilosis.

### Vitamin B<sub>12</sub> deficiency

- **Causes:** Strict vegetarians; pernicious anemia, which results in decreased levels of intrinsic factor; *Diphyllobothrium latum* infection, which impairs absorption of vitamin B<sub>12</sub> in the terminal ileum.
- **Clinical presentation:** Megaloblastic anemia, peripheral neuropathy, and subacute combined degeneration.
- **Laboratory findings:** Anemia with high mean corpuscular volume (MCV), hypersegmented neutrophils, elevated homocysteine and methylmalonic acid levels, and abnormal Schilling test, depending on the cause of deficiency.

### Folate deficiency

- **Causes:** Pregnancy; diet low in fresh vegetables.
- **Clinical presentation:** Megaloblastic anemia with hypersegmented neutrophils. A peripheral neuropathy is *not* seen.

### Vitamin A deficiency

- **Causes:** Fat malabsorption, laxative abuse, and alcohol use.
- **Clinical presentation:** Night blindness (earliest manifestation); xerosis and corneal ulceration.

**TABLE 5-1.** Complications of Vitamin Deficiency

Vitamin	Complication
B <sub>1</sub> (thiamine)	Wernicke encephalopathy, Korsakoff syndrome, wet beriberi
B <sub>2</sub> (riboflavin)	Cheilosis, stomatitis, seborrheic dermatitis
B <sub>3</sub> (niacin)	Pellagra (diarrhea, dementia and dermatitis)
B <sub>6</sub>	Glossitis, cheilosis
B <sub>12</sub>	Megaloblastic anemia
C	Coagulopathy, poor wound healing
Folate	Megaloblastic anemia
A	Night-blindness, xerosis, corneal ulcer
D	Rickets in children; osteomalacia in adults
E	Gait disturbances, ophthalmoplegia
K	Coagulopathy

**Vitamin C deficiency (scurvy)**

■ **Cause:** Malnourishment.

■ **Clinical presentation:** Bleeding gums, ecchymoses on extremities, poor wound healing, and classic “corkscrew hairs.”

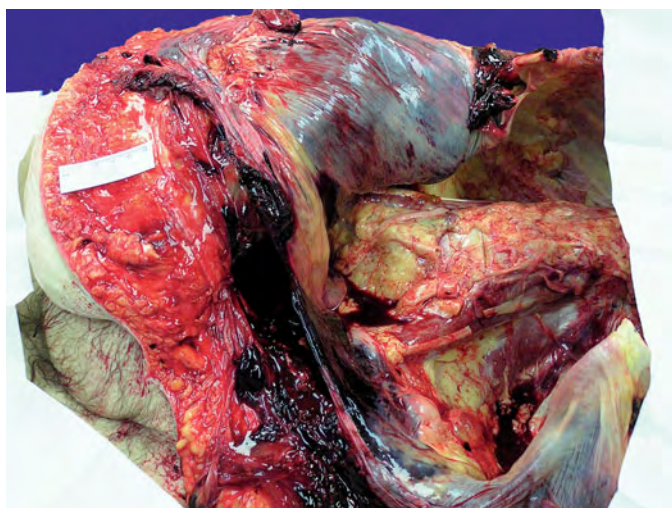
**Vitamin D deficiency:** Rickets in children and osteomalacia in adults.

**Vitamin E deficiency:** Gait disturbances, ophthalmoplegia, and hyperreflexia.

**Vitamin K deficiency**

■ **Causes:** Fat malabsorption and use of warfarin, which is a competitive inhibitor of vitamin K ([Figure 5-6](#)).

■ **Features:** Bleeding; prolonged prothrombin time.



**Figure 5-6.** Abdominal wall hemorrhage due to warfarin therapy. In this photograph, the body has been opened and the thoracic and abdominal organs removed. For orientation, the pelvis is on the left side of the photograph and the ribs are on the right side. Note the extensive hemorrhage in the abdominal wall. In the lower half of the image, the clotted blood is easily visible, whereas in the upper half, the clotted blood appears as a blue-purple discoloration through the intact peritoneum. Warfarin is a competitive inhibitor of vitamin K and, thus, patients on warfarin therapy hemorrhage more easily after even minor trauma.



*This page intentionally left blank*



# CHAPTER 6

## GENETIC DISORDERS

### OVERVIEW

There are three major types of mutations: (1) genome mutations, which involve loss or gain of an entire chromosome; (2) chromosomal mutations, which involve alterations in one or more chromosomes that are usually identifiable by karyotyping; and (3) gene mutations, which are partial or complete deletion of the gene or alteration of the base. Genome mutations usually result in death of the fetus, or death during infancy or early childhood.

Many diseases have a genetic component, albeit without a specific identifiable gene mutation. Such conditions are said to have a multifactorial inheritance pattern. Examples of such diseases include coronary artery disease, hypertension, gout, and diabetes mellitus.

When discussing genetic diseases, some definitions are important to remember: (1) **hereditary or familial**, a condition derived from parents (i.e., a condition that is transmitted in the germ line); and (2) **congenital**, a condition that is present at birth. Not all hereditary conditions are congenital, and not all congenital conditions are hereditary. Some hereditary conditions are manifested at the time of birth or shortly thereafter, and many manifest later in life.

The overall effects of the mutation of a single gene include (1) an enzyme defect; (2) defects in membrane receptors and/or transport system; (3) alterations in structure, function, or quantity of nonenzymatic protein; or (4) mutations resulting in unusual reactions to drugs. An enzyme defect can cause accumulation of substrate, a metabolic block resulting in a decreased amount of needed end product, or failure to inactivate a tissue-damaging substrate.

### AUTOSOMAL DOMINANT DISORDERS

**Overview:** In general, autosomal dominant disorders have reduced penetrance and variable expressivity. They usually do not encode enzymes because a loss of up to 50% of an enzyme's activity can be compensated for by activity of the enzyme encoded by the normal allele ([Table 6-1](#)).

### FAMILIAL HYPERCHOLESTEROLEMIA

**Mutation:** Low-density lipoprotein receptor gene (*LDL*); there are more than 100 known mutations.

**Mechanism:** The LDL receptor recognizes apolipoprotein B100 or apolipoprotein E; therefore, a mutation of the receptor results in impaired uptake of cholesterol into cells.

#### Manifestations of familial hypercholesterolemia

- Elevated cholesterol level: Heterozygotes have half the normal amount of LDL receptors and two to three times the normal level of cholesterol; homozygotes have five or more times the normal level of cholesterol.
- Tendon sheath xanthomas, corneal arcus, and xanthelasma.
- Early atherosclerosis and its consequences; homozygotes usually die of cardiovascular disease before the age of 30 years.

### FAMILIAL POLYPOSIS COLI (FAMILIAL ADENOMATOUS POLYPOSIS, OR FAP)

**Mutation:** *APC* gene on chromosome 5q21.

**Mechanism:** The APC (adenomatous polyposis coli) protein degrades  $\beta$ -catenin (accumulated  $\beta$ -catenin activates transcription of genes such as *MYC* and *cyclin D1*)—therefore, by allowing  $\beta$ -catenin to accumulate, a mutation of the *APC* gene promotes cell proliferation.

**Manifestations of FAP:** Multiple (> 100) colonic polyps and congenital hypertrophy of the retinal pigment epithelia. A subset of patients with FAP develops various extraintestinal manifestations such as osteomas and soft tissue tumors (Figure 6-1).

**Complications:** Development of invasive colonic adenocarcinoma in all patients by the fifth decade of life.

### HEREDITARY SPHEROCYTOSIS

**Inheritance pattern:** Can be autosomal dominant or autosomal recessive; the autosomal recessive form is more severe, however.

**Mutation:** Gene for ankyrin, spectrin, band 4.1, or band 3.

#### Manifestations of hereditary spherocytosis

- Anemia, due to extravascular hemolysis because affected red blood cells do not deform well in transit through the spleen.
- Splenomegaly due to sequestration of abnormal red blood cells in the spleen.
- Cholelithiasis caused by increased production of bile pigments from hemolysis of red blood cells.

**Laboratory testing:** Increased osmotic fragility.

**Treatment of hereditary spherocytosis:** Splenectomy.

### MARFAN SYNDROME

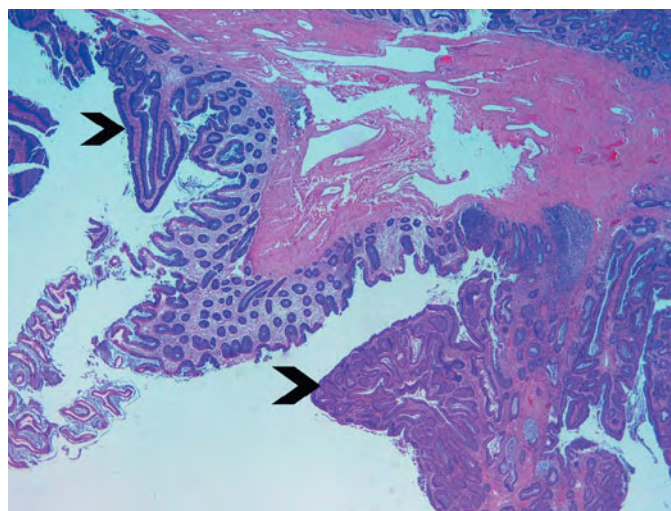
**Mutation:** Fibrillin-1 gene on chromosome 15q21.

**Mechanism:** Fibrillin provides support for deposition of tropoelastin and production of elastic fibers.

**TABLE 6-1.** Autosomal Dominant Genetic Disorders

Disorder	Protein Involved
Familial hypercholesterolemia	LDL receptor
Familial adenomatous polyposis	APC protein
Hereditary spherocytosis	Ankyrin, spectrin, band 4.1, or band 3
Marfan syndrome	Fibrillin-1
Neurofibromatosis, type 1	Neurofibromin
Neurofibromatosis, type 2	Merlin
Tuberous sclerosis	Hamartin, tuberin

LDL, low-density lipoprotein; APC, adenomatous polyposis coli.



**Figure 6-1.** Familial adenomatous polyposis. Patients with this hereditary condition develop hundreds of adenomas in their colon, and eventually develop invasive colonic adenocarcinoma. This low-power view of the colon shows two tubular adenomas (arrowheads) with intervening normal colonic mucosa. Hematoxylin and eosin, 20 $\times$ .



### Manifestations of Marfan syndrome by organ system

- **Skeletal:** Long arms and legs and long fingers (**arachnodactyly**).
- **Eye:** Bilateral dislocation of the lens (**ectopia lentis**).
- **Cardiovascular**
  - Aortic root dilation, leading to aortic insufficiency.
  - Myxomatous mitral valve.
  - Ascending thoracic aortic aneurysms.
  - Aortic dissection associated with cystic medial degeneration.

## NEUROFIBROMATOSIS (NF): TYPES 1 AND 2

### NF-1

**Mutation:** *NF-1* gene on 17q11.2; there is a high rate of spontaneous mutations (occurring in roughly 50% of new cases of NF-1).

**Mechanism:** The *NF-1* gene product, neurofibromin, is a guanosine triphosphatase (GTPase)-activating protein that influences normal Schwann cell proliferation and differentiation. Although its role remains incompletely understood, it is thought to act as a tumor suppressor protein.

**Incidence:** 1 in 3000 individuals in the general population.

### Manifestations of NF-1 (Figure 6-2)

- **Neurofibromas** (proliferation of Schwann cells, perineurial cells, and fibroblasts): The three types of neurofibromas are cutaneous, subcutaneous, and plexiform.
- **Café-au-lait spots** (pigmented cutaneous macules).
- **Lisch nodules** (iris hamartomas).
- Optic gliomas (e.g., pilocytic astrocytomas).

**Important points regarding NF-1:** Plexiform neurofibromas can transform into malignant peripheral nerve sheath tumors; in contrast, malignant transformation of superficial neurofibromas is extremely rare (Figure 6-3).

### NF-2

**Mutation:** *NF-2* gene on chromosome 22q12.

**Mechanism:** The *NF-2* gene product merlin is a protein that binds to cellular membranes and cytoskeletal components (particularly actin) and plays a role in regulating contact inhibition and proliferation of Schwann cells. Like the *NF-1* gene, the *NF-2* gene is thought to act as a tumor suppressor gene.

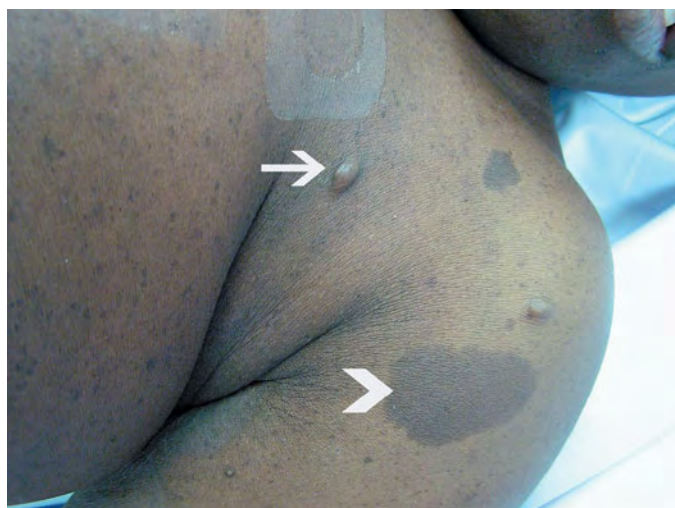**Incidence:** 1 in 40,000 to 50,000 in the general population.

**Manifestations of NF-2:** Bilateral acoustic schwannomas, multiple meningiomas.

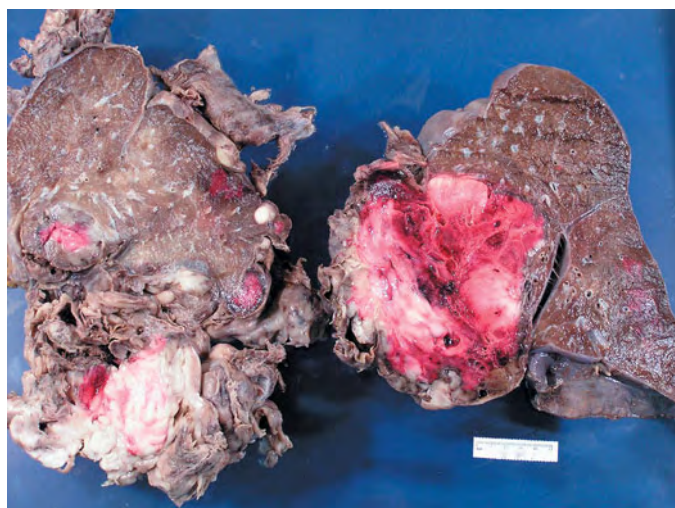## VON HIPPEL-LINDAU (VHL) DISEASE

**Mutation:** *VHL* gene on chromosome 3p25.

**Associated neoplasms:** Renal cell carcinoma, pheochromocytomas, hemangioblastomas of the central nervous system, and retinal angiomas.



**Figure 6-2.** This patient had type 1 neurofibromatosis. Note the cutaneous neurofibromas (arrow) and café-au-lait spots (arrow-head).



**Figure 6-3.** Malignant peripheral nerve sheath tumor. This patient had type 1 neurofibromatosis. A plexiform neurofibroma in the pleural cavity underwent malignant degeneration, resulting in a malignant peripheral nerve sheath tumor. The tumor encased the left lung and heart, with only a small focus of invasion into the pulmonary parenchyma (not in the photograph). The photograph shows a bisected left lung with the tumor at its periphery.

## TUBEROUS SCLEROSIS

**Mutation:** Gene for hamartin on chromosome 9 or tuberin on chromosome 16.

### Manifestations

- Cerebral cortical hamartomas (**tubers**).
- Subependymal giant cell astrocytomas ([Figure 6-4](#)).
- Seizures and mental retardation.
- Cardiac rhabdomyomas.
- Renal angiomyolipomas.
- Localized leathery thickenings of the skin (i.e., **shagreen patches**).
- Hypopigmented regions of skin (i.e., **ash-leaf patches**).
- **Adenoma sebaceum**.

## MYOTONIC DYSTROPHY TYPE 1

**Mutation:** Expanded CTG trinucleotide repeats on chromosome 19q13.2-13.3, which affects mRNA for DMPK (dystrophica myotonia-protein kinase); normal individuals have less than 30 repeats. The more repeats, the more severely affected a patient will be.

### Manifestations of myotonic dystrophy type 1

- The classic hallmark for clinical presentation is the inability to relax the muscles after stimulation. Patients often describe inability to release a handshake.
- Weakness is common.
- Atrophy of facial muscles (“hatchet-shaped facies”).
- Cataracts, gonadal atrophy, and cardiac problems (especially conduction defects and arrhythmias).

## AUTOSOMAL RECESSIVE DISORDERS

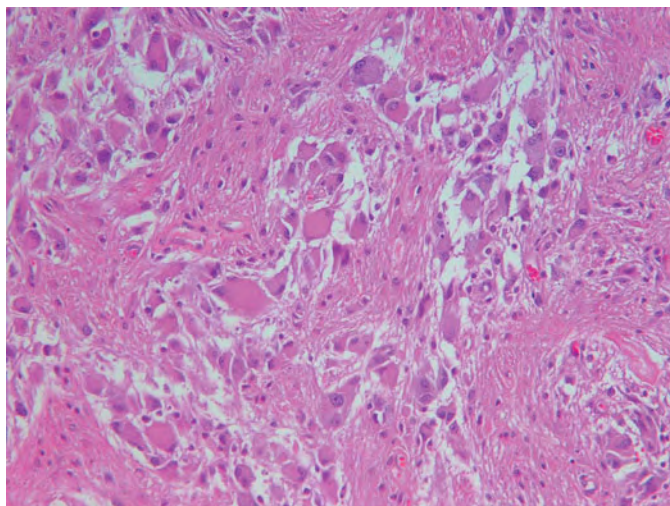
**Overview:** Patients with autosomal recessive disorders usually have complete penetrance and more uniform expression of the disease when compared to patients with autosomal dominant disorders. Autosomal recessive disorders often involve enzymes ([Table 6-2](#)).

### $\alpha_1$ -ANTITRYPSIN (AAT) DEFICIENCY

**Genetic abnormality:** The gene associated with this condition is found on chromosome 14; the normal allele is PiMM. Patients with PiZZ alleles have circulating levels of AAT that are only 10% of normal.

### Manifestations

- Panacinar emphysema, which is dramatically accelerated by cigarette smoking.
- Cirrhosis—only 10% or more of individuals with PiZZ alleles develop cirrhosis, most likely because they have decreased protein degradation via the ubiquitin-proteasome pathway. Liver biopsy shows periodic acid–Schiff (PAS) positive and diastase-resistant granules, which represent accumulations of an abnormal AAT.



**Figure 6-4.** Subependymal giant cell astrocytoma. A subependymal giant cell astrocytoma (SEGA) is one of the characteristic features of tuberous sclerosis. Hematoxylin and eosin, 200 $\times$ .

**TABLE 6-2.** Autosomal Recessive Genetic Disorders

Disorder	Protein Involved
Cystic fibrosis	Cystic fibrosis transmembrane conductance regulator
Galactosemia	Galactose-1-phosphate uridylyltransferase
Hereditary hemochromatosis	HFE protein
Phenylketonuria	Phenylalanine hydroxylase
Wilson disease	ATP-dependent Cu <sup>2+</sup> transporter
Alkaptonuria	Homogentisic oxidase
Maple syrup urine disease	Branched chain ketoacid dehydrogenase
Hurler disease	$\alpha$ -L-iduronidase
Hunter disease	Iduronate-2 sulfatase
Tay-Sachs disease	$\alpha$ -subunit of GM <sub>2</sub> gangliosidase
Gaucher disease	Glucocerebrosidase
Niemann-Pick, types A and B	Sphingomyelinase

## CYSTIC FIBROSIS

**Mutation:** Cystic fibrosis transmembrane conductance regulator (*CFTR*) gene on chromosome 7.

**Epidemiology:** 1 in 3500 live births; whites predominantly; uncommon in Asians and African Americans.

**Mechanism:** Impaired resorption of chloride from lumen of the sweat ducts, with resultant impaired absorption of sodium; impaired secretion of chloride into the airways, pancreatic ducts, and the gastrointestinal tract, resulting in less secretion of sodium and water and, therefore, viscid secretions.

### Manifestations of cystic fibrosis

- Fibrosis of pancreas.
- Recurrent pulmonary infections with *Pseudomonas aeruginosa*, *Staphylococcus aureus*, and *Burkholderia cepacia*. Patients with cystic fibrosis can harbor a very mucoid strain of *Pseudomonas*.
- Chronic bronchitis, bronchiectasis.
- Meconium ileus.
- Biliary cirrhosis, leading to impaired absorption of the fat-soluble vitamins A, D, E, and K.
- Infertility in males secondary to absence of vas deferens.

**Laboratory studies:** Increased concentration of chloride in sweat (i.e., positive sweat chloride test).



### GALACTOSEMIA

**Mutation:** Gene for galactose-1-phosphate uridylyltransferase (GALT), which is required to convert galactose to glucose.

#### Manifestations of galactosemia

- Cirrhosis.
- Opacification of the lens (cataracts)—due to accumulation of galactitol, the lens absorbs water and swells.
- Mental retardation.
- Aminoaciduria due to accumulation of galactose in the kidney, which impairs amino acid transport.

**Diagnosis:** Positive urinary-reducing substance.

### HEREDITARY HEMOCHROMATOSIS

**Mutation:** *HFE* gene on chromosome 6p21.3.

**Epidemiology:** 1 in 250 individuals of European descent are homozygous; incidence is higher in males than in females.

**Mechanism:** Increased intestinal absorption of iron leads to iron buildup in organs.

#### Manifestations of hereditary hemochromatosis

- Bronze skin discoloration due to iron deposition.
- Diabetes mellitus due to pancreatic fibrosis.
- Cirrhosis of the liver.
- Dilated or restrictive cardiomyopathy.

**Clinical presentation:** The classic triad of symptoms is arthralgia or arthritis, impotence, and fatigue.

**Laboratory studies:** Elevated transferrin saturation and ferritin concentration; the definitive test is a liver biopsy or DNA testing.

**Treatment:** Regular removal of blood (phlebotomy).

### PHENYLKETONURIA (PKU)

**Mutation:** Gene for phenylalanine hydroxylase.

**Mechanism:** Changes are the result of hyperphenylalaninemia, due to inability to breakdown phenylalanine.

#### Manifestations of PKU

- Impairment of brain development due to high levels of phenylalanine and relatively low tyrosine levels with resultant microcephaly, severe mental retardation, and seizures. Patients may develop motor abnormalities later in life.
- Affected infants have fair hair and skin, blue eyes, and a “mousy odor.”

**Treatment:** Phenylalanine-free diet, especially during infancy and childhood because of vital neurologic development occurring at that time. Because this disease has significant morbidity and is easily treated by dietary restrictions, most neonates are tested.

**Important point regarding PKU:** Adults can follow a less restrictive diet; however pregnant patients must return to a phenylalanine-free diet as phenylalanine will cross the placenta and affect the fetus.

### WILSON DISEASE (HEPATOLENTICULAR DEGENERATION)

**Mutation:** Adenosine triphosphate (ATP)-dependent copper transporter gene on chromosome 13, which is expressed at highest levels in the liver and brain.

**Mechanism:** Failure to export copper from cells normally, with resultant increased copper accumulation in the liver and brain. Defective copper export in turn is associated with decreased excretion of copper into bile, which is the primary route for copper excretion.

**Laboratory studies:** Decreased serum ceruloplasmin, increased hepatic copper content (determined by liver biopsy), and increased urinary excretion of copper.

#### Manifestations of Wilson disease

- Liver damage (e.g., fatty change, acute hepatitis, chronic hepatitis, and cirrhosis).
- Neurologic abnormalities appearing after adolescence include tremor, speech abnormalities (dysarthria), painful muscle spasms, and dementia. Examination of the brain will reveal atrophy, hyperpigmentation, and cavitation of the putamen. Other basal ganglia nuclei (i.e., caudate and globus pallidus) and the thalamus and brainstem may also be affected.
- **Kayser-Fleischer rings** (i.e., green copper deposits in Descemet membrane at the limbus of the cornea).

### ALKAPTONURIA

**Mutation:** Gene for homogentisic oxidase (3q21).

**Mechanism:** Inadequate breakdown of homogentisic acid.

**Manifestations:** Homogentisic acid accumulates in connective tissue, tendons, and cartilage, causing blue-black pigmentation (i.e., **ochronosis**) and making cartilage lose its resilience and become brittle, resulting in degenerative arthropathy. Classically, the urine turns black if allowed to sit, secondary to oxidation.

### MAPLE SYRUP URINE DISEASE

**Mutation:** Gene for branched-chain ketoacid dehydrogenase.

**Incidence:** 1 in 180,000 births.

**Mechanism:** Accumulation of the branched-chain amino acids, leucine, valine, and isoleucine, causes neurologic symptoms and “maple syrup” odor of urine.

**Manifestations:** Alternating hypotonia and hypertonia, hypoglycemia, acidosis, and convulsions.

## MUCOPOLYSACCHARIDOSES (MPS)

**Mutation:** Genes for lysosomal enzymes required to break down glycosaminoglycans.

**Mechanism:** Lysosomal storage of heparin and dermatan sulfates; excretion of excess glycosaminoglycans (GAGs) in urine.

**Two main types of mucopolysaccharidoses**

**Hurler disease**, MPS type I: Autosomal recessive deficiency of  $\alpha$ -L-iduronidase.

**Hunter disease**, MPS type II: X-linked deficiency of iduronate-2-sulfatase.

**Manifestations:** Mental retardation, coarse facial features, joint stiffness, corneal clouding, and urinary excretion of dermatan and heparan sulfate.

## LYSOSOMAL STORAGE DISORDERS

**Overview:** Most lysosomal storage disorders are due to the absence of an enzyme. With the absence of the enzyme, its substrate builds up and accumulates within lysosomes instead of being degraded. Most of the lysosomal storage disorders result in accumulations of the substrate within macrophages; thus, the spleen and liver, as well as lymph nodes, are often enlarged. Lysosomal storage diseases have an autosomal recessive inheritance pattern. The three more common forms of lysosomal storage disorders that are discussed below are Gaucher disease, Tay-Sachs disease, and Niemann-Pick disease.

### GAUCHER DISEASE

**Mutation:** Gene for glucocerebrosidase.

**Mechanism:** Accumulation of glucocerebroside in organs with a high concentration of phagocytic cells (e.g., spleen, liver, lymph nodes).

**Microscopic morphology of Gaucher disease:** “Tissue-paper” cells.

**Types of Gaucher disease:** All three types have a different mutation of the glucocerebrosidase gene.

#### 1. Type I: Chronic non-neuronopathic form

**Epidemiology:** Type I represents 99% of cases of Gaucher disease. Type I Gaucher disease presents in later childhood or early adulthood. The disease is compatible with a long life.

**Manifestations of type I Gaucher disease**

- Hepatosplenomegaly.
- Marrow replacement resulting in deformities and pathologic fractures.
- “Erlenmeyer flask deformity” of distal femur.
- No central nervous system (CNS) involvement.

#### 2. Type II: Acute neuronopathic form

**Epidemiology:** Type II Gaucher disease presents in infants.

**Manifestations:** Hepatosplenomegaly, severe CNS involvement, and death at an early age (by 2 years).



### 3. Type III: Juvenile form

**Epidemiology:** Type III Gaucher disease presents in juveniles.

**Manifestations:** Hepatosplenomegaly; CNS involvement is less severe than in type II.

## TAY-SACHS DISEASE

**Mutation:** Gene for  $\alpha$ -subunit of GM<sub>2</sub>-gangliosidase.

**Epidemiology:** 1 in 30 Jews of Ashkenazic (Eastern European) origin are carriers.

### Manifestations of Tay-Sachs disease

- Ballooned neurons leading to progressive neurologic (motor and mental) deterioration.
- Involvement of ganglion cells in the retina causing a cherry-red spot.
- Signs and symptoms develop by the age of 6 months; death usually occurs by the age of 2 to 3 years.

## NIEMANN-PICK DISEASE

**Mutation:** Gene for sphingomyelinase (in types A and B); *NPC-1* gene in type C.

**Mechanism:** Accumulation of sphingomyelin in phagocytic cells in types A and B.

### Types of Niemann-Pick disease

1. **Type A:** Features are extensive neurologic involvement and visceral organ accumulations; death occurs by the age of 3 years.
2. **Type B:** Features are organomegaly and cherry-red spot in the retina. There is no CNS involvement. Patients survive to adulthood.
3. **Type C**
  - **Mutation:** *NPC-1* gene plays a role in cholesterol trafficking.
  - **Mechanism:** Cholesterol accumulation.
  - **Manifestations:** Ataxia, supranuclear palsy, and hepatosplenomegaly.

## GLYCOGEN STORAGE DISORDERS

**Overview:** There are many different glycogen storage disorders, each of which is due to a mutation in a different enzyme responsible for the metabolism of glycogen. Because of the location of the enzyme, most glycogen storage diseases can be grouped into hepatic or myopathic forms.

### HEPATIC FORMS OF GLYCOGEN STORAGE DISEASE

**Characteristic condition: von-Gierke disease** (due to deficiency of glucose-6-phosphatase).

**Manifestations:** Hepatic enlargement and hypoglycemia.

### MYOPATHIC FORMS OF GLYCOGEN STORAGE DISEASE

**Characteristic condition:** **McArdle disease** (due to deficiency of muscle phosphorylase).

**Manifestations:** Cramps with exercise; no exercise-induced increase in lactate.

### MISCELLANEOUS FORMS OF GLYCOGEN STORAGE DISEASE

**Overview:** Some forms of glycogen storage disease may have less conspicuous liver involvement, although skeletal muscle abnormalities are often present, along with cardiac involvement.

**Characteristic condition:** **Pompe disease** is due to a deficiency of acid maltase; all organs have increased glycogen accumulation associated with increased lysosomal activity. Cardiac involvement is the most prominent feature of infantile onset cases. Skeletal muscle weakness is conspicuous in adult-onset cases, with increased lysosomal glycogen accumulation (Figure 6-5).

## GENETIC CONDITIONS WITH X-LINKED INHERITANCE PATTERN

### DUCHENNE MUSCULAR DYSTROPHY

**Epidemiology:** 1 in 3000 infants; profound male predominance; female carriers of the disease are often asymptomatic.

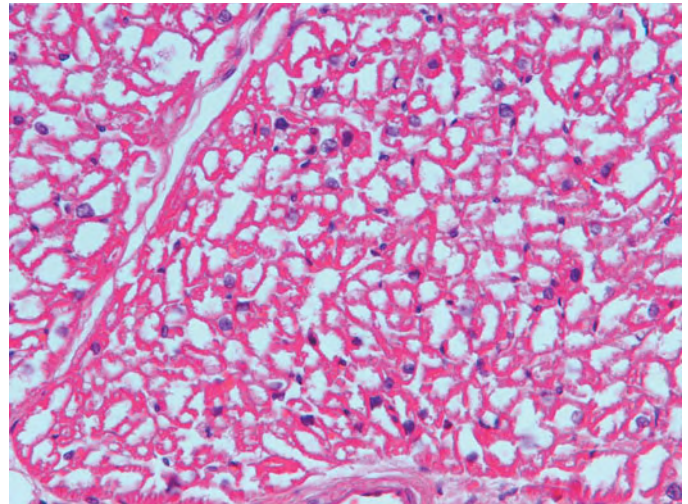
**Mutations:** Dystrophin gene at Xp21.

**Mechanism:** Dystrophin is believed to help transfer the force of muscular contraction to connective tissue. In dystrophin deficiency, the cell membrane of the muscle fiber is damaged when the muscle contracts. Dystrophin is also expressed in organs other than skeletal muscle, including the brain and myocardium. Therefore, dystrophin abnormalities may also be associated with cardiac and neurologic defects.

#### Clinical presentation of Duchenne muscular dystrophy

- **Clinical course:** Disease manifests by the age of 5 years. The associated muscular weakness leads to immobility by the early teens and usually death by the early twenties. Cardiomyopathy and nonprogressive cognitive abnormalities are also fairly common.
- **Signs and symptoms:** Weakness of pelvis first, with delayed ability to walk; **pseudohypertrophy** (i.e., enlargement of calf muscles due to replacement with fat). Patients use their hands to rise to a standing position (Gower maneuver). Muscle atrophy and weakness progress relentlessly, with most patients becoming wheelchair-bound by the second decade. In most cases, death occurs by the end of the second decade, usually due to some combination of respiratory insufficiency and cardiac failure.

**Microscopic morphology of Duchenne muscular dystrophy:** By immunohistochemical staining, most fibers show an absence of dystrophin, although a few dystrophin-positive fibers (so-called “revertant fibers”) are usually present. In symptomatic cases, there is marked variation in muscle fiber size, accompanied



**Figure 6-5.** Pompe disease. Pompe disease is one of the glycogen storage disorders that affects heart and skeletal muscle. The myocardial cells have a central, fairly well-defined, cleared-out region representing sites of abnormal glycogen accumulation. Hematoxylin and eosin, 200×.

by muscle fiber degeneration, regeneration, and increased amounts of connective tissue. In advanced cases, the muscle is mostly replaced by adipose and connective tissue.

### BECKER MUSCULAR DYSTROPHY

**Mutation:** Dystrophin gene on Xp21. Patients have decreased levels of dystrophin compared to normal individuals, or they may produce a mutant, defective form of dystrophin.

**Clinical presentation of Becker muscular dystrophy:** Variable. Some patients may follow a course indistinguishable from Duchenne muscular dystrophy, but most affected individuals present roughly a decade later than patients with Duchenne muscular dystrophy and remain ambulatory for several decades. In very mild cases, patients can have a nearly normal life span. Cardiac abnormalities may predominate in some cases.

## GENETIC CONDITIONS WITH MIXED INHERITANCE PATTERNS

### EHLERS-DANLOS SYNDROME

**Mutation:** Ehlers-Danlos syndrome occurs as one of many types. In each type, one of the multiple genes involved in collagen synthesis is affected. Depending upon which gene is involved, the inheritance pattern can be autosomal dominant, autosomal recessive, or X-linked recessive.

#### Types of Ehlers-Danlos syndrome

##### 1. Kyphoscoliosis type

**Mutated gene:** Lysyl hydroxylase.

**Manifestations:** Hypotonia, joint laxity, and scoliosis.

##### 2. Vascular type

**Mutated gene:** *COL3A1* gene of type III collagen.

**Features:** Thin skin; arterial rupture.

**Manifestations:** Hyperelasticity of the skin with hypermobile joints.

## ADDITIONAL GENETIC ABNORMALITIES

**Overview:** Genome mutations (trisomies 21, 18 and 13) and chromosomal mutations (22q11.2 deletion and Cri-du-chat) are discussed below.

### TRISOMY 21 (DOWN SYNDROME)

**Epidemiology:** 1 in 700 live births (1 in 1550 if the mother is younger than 20 years of age, and 1 in 25 if the mother is older than 45 years of age).

#### Cause

■ Approximately 95% of cases of Down syndrome are due to maternal meiotic nondisjunction. Nondisjunction is a failure of separation of chromosome pairs in anaphase I or failure of separation of chromosome pairs into chromatids in anaphase II.

- Approximately 4% of cases of Down syndrome are due to a Robertsonian translocation, which is a translocation of the long arm (q) of chromosome 21 to the q arm of another acrocentric chromosome, such as 14 or 22. A Robertsonian translocation does not result in loss of genetic material; it results in loss of the p arm of 21 and the p arm of 14 or 22. However, in acrocentric chromosomes, loss of the p arm is silent. The carrier of a Robertsonian translocation is 45,XX or 45,XY.
- Approximately 1% of cases of Down syndrome are mosaics.

#### Manifestations of Down syndrome

- Mental retardation.
- Flat facial profile and epicanthal folds.
- Congenital heart defects, which are often endocardial cushion defects such as ostium primum atrial septal defect (most common cardiac defect in Down syndrome), atrioventricular defects, or ventricular septal defects (Figure 6-6).
- Duodenal atresia.
- Early development of Alzheimer disease.
- Increased risk of leukemia—10 to 20 times increased risk for acute lymphoblastic leukemia (ALL) in children with Down syndrome. Also, acute megakaryoblastic leukemia is most commonly associated with patients with Down syndrome.
- Atlantoaxial instability.
- Brushfield spots on iris.

**Laboratory studies:** Mothers will have an elevated  $\beta$ -human chorionic gonadotropin ( $\beta$ -hCG) and decreased levels of  $\alpha$ -fetoprotein.

### TRISOMY 18 (EDWARD SYNDROME)

**Incidence:** 1 in 8000 live births.

#### Manifestations

- Prominent occiput, low-set ears, small jaw, mental retardation, cerebellar and brainstem abnormalities, congenital heart disease, and rocker bottom feet.
- Almost all patients die of apnea in the first year of life.

### TRISOMY 13 (PATAU SYNDROME)

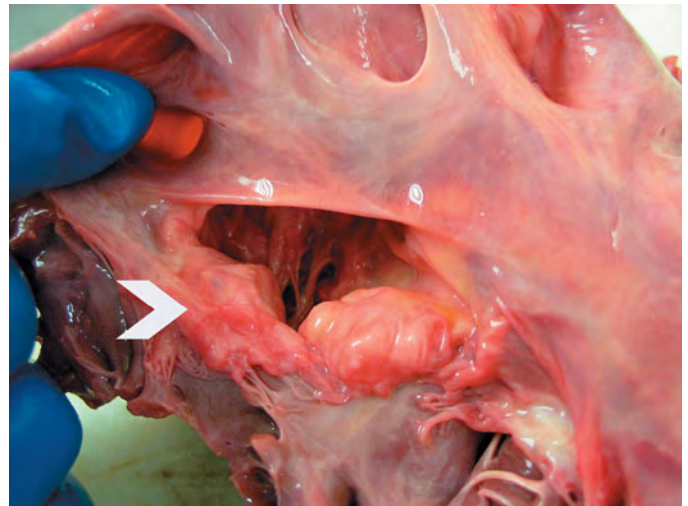
**Incidence:** 1 in 15,000 live births.

#### Manifestations

- Microphthalmia, holoprosencephaly, mental retardation, microcephaly, polydactyly, congenital heart disease (ventricular septal defect commonly), and rocker bottom feet.
- Almost all patients die in the first year of life.

### 22q11.2 DELETION

**Two forms:** **DiGeorge syndrome**, which has predominantly thymus, parathyroid, and cardiac pathology, and **velocardiofacial syndrome**, which has predominantly palate, facial, and cardiac abnormalities.



**Figure 6-6.** Common atrioventricular canal. Patients with Down syndrome commonly have congenital heart disease, and the congenital heart disease often originates from a defect in the endocardial cushions. This defect may manifest as a common atrioventricular canal, a primum atrial septal defect, or a ventricular septal defect. The photograph illustrates a common atrioventricular canal. The defect involves the lower portion of the interatrial septum and the upper portion of the interventricular septum. The arrowhead indicates the cleft anterior leaflet of the mitral valve, a feature that is commonly seen in patients who have this congenital heart defect.



**Mutation:** Unknown gene.

**Incidence:** 1 in 4000 live births.

**Manifestations:** Congenital heart disease, abnormal palate, facial dysmorphism, developmental delay, variable T-cell immunodeficiency due to thymic aplasia, and hypocalcemia due to parathyroid gland aplasia; increased incidence of schizophrenia and bipolar disorder. Patients have absent thymic shadow on chest x-ray.

**Diagnosis:** Requires fluorescent in situ hybridization (FISH).

### CRI-DU-CHAT SYNDROME

**Mutation:** Deletion of 5p.

**Features:** Microcephaly, mental retardation, high-pitched crying.

## SEX CHROMOSOME ABNORMALITIES

### KLINEFELTER SYNDROME

**Genetic abnormality:** A male hypogonadism due to the presence of two or more X chromosomes and one or more Y chromosomes (82% of cases are 47,XXY).

**Incidence:** 1 in 500 live births.

**Mechanism:** Increased level of follicle-stimulating hormone (FSH) and decreased level of testosterone.

#### Manifestations of Klinefelter syndrome

- Hypogonadism (atrophic testes and small penis) and sterility.
- Tall stature due to increase in length between sole and pubic bone (long legs).
- Reduced body hair.
- Most have normal intelligence.
- 20 times increased risk for breast carcinoma.
- Barr body (inactive X chromosome).

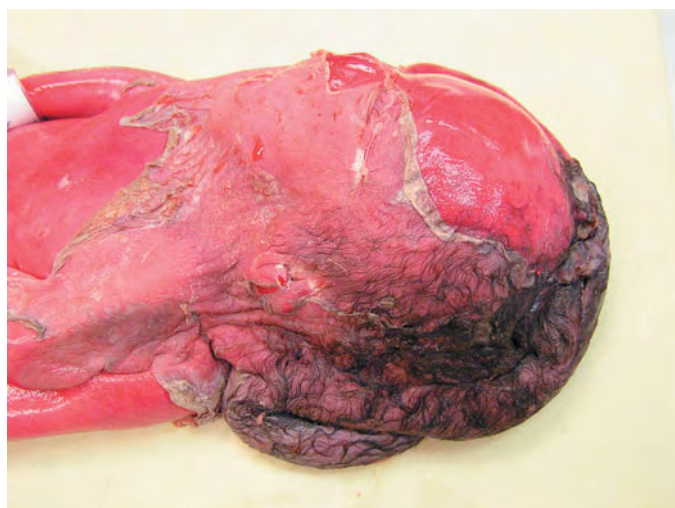### TURNER SYNDROME

**Genetic abnormality:** A female hypogonadism due to the presence of an XO karyotype (57% of cases are XO; 14% have structural abnormality of X chromosomes; 29% are mosaics)—*SHOX* gene involved.

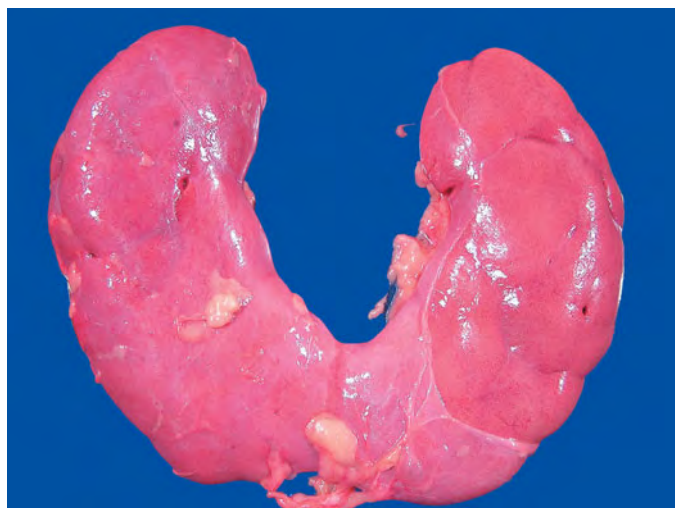
**Incidence:** 1 in 2000 live births (99% of fetuses with an XO karyotype do not survive gestation).

#### Manifestations of Turner syndrome

- Short stature and widely spaced nipples.
- Cystic hygromas, webbed neck (Figure 6-7).
- Accelerated loss of oocytes leads to streaked ovaries by the age of 2 years and resultant primary amenorrhea.
- Horseshoe kidney (Figure 6-8).
- Coarctation of the aorta and bicuspid aortic valve.



**Figure 6-7.** Cystic hygroma. The photograph depicts a stillborn fetus with Turner syndrome. The skin slippage and red discoloration of the skin is a feature of stillbirth; however, the redundancy (i.e., folds) of the posterior neck represents a cystic hygroma. Oftentimes, pregnancies involving a fetus with Turner syndrome end with a non-therapeutic abortion.



**Figure 6-8.** Horseshoe kidney. Although horseshoe kidneys are not specific for Turner syndrome, they represent one abnormality that is commonly associated with the syndrome.

### FRAGILE X SYNDROME

**Genetic abnormality:** Trinucleotide (CGG) repeats on the X chromosome; affects *FMR1* gene (Xq27.3).

**Manifestations:** Long face with large mandible; large testicles; mental retardation.

**Important points regarding Fragile X syndrome**

- Normal individuals have about 30 repeats; affected individuals have 230+ repeats.
- Individuals with 50 to 230 repeats are referred to as premutations.
- Premutations can expand the number of repeats during oogenesis, but not during spermatogenesis. Therefore, fathers with premutations cannot pass the disease to sons, but repeats will amplify in his daughters and affect his grandsons and granddaughters. Understanding of this potential by parents produces the anticipation effect.
- Fragile X is the most common inherited genetic cause of mental retardation.

### DISEASES OF GENOMIC IMPRINTING

#### PRADER-WILLI AND ANGELMAN SYNDROMES

**Genetic abnormality:** The gene involved in these disorders is on chromosome 15q—deletion of paternal-derived 15q12 leads to Prader-Willi syndrome, and deletion of maternal-derived 15q12 leads to Angelman syndrome. In other words, a child must receive the paternally derived gene at 15q12 to *not* develop Prader-Willi syndrome, and must receive the maternally derived gene at 15q12 to *not* develop Angelman syndrome.

**Manifestations of Prader-Willi syndrome:** Include mental retardation, extreme hyperphagia, short stature, obesity, and hypogonadism. Most patients die from complications of obesity.

**Manifestations of Angelman (“happy puppet”) syndrome:** Include ataxic gait, seizures, and inappropriate laughter.

### SEXUAL DIFFERENTIATION DISORDERS

#### TRUE HERMAPHRODITE

**Basic description:** Possession of both testicular and ovarian tissue.

**Mechanism:** Possible translocation of *SRY* gene; most cases are 46,XX, but some are mosaics.

#### FEMALE PSEUDOHERMAPHRODITE

**Basic description:** Female internal genitalia with ambiguous external genitalia.

**Mechanism:** Excessive androgens during gestation; common cause is congenital adrenal hyperplasia.

### MALE PSEUDOHERMAPHRODITE

**Basic description:** Male internal genitalia with ambiguous external genitalia.

**Mechanism:** Many causes; most commonly due to defect in androgen synthesis.

**Specific forms (testicular feminization and 5 $\alpha$ -reductase deficiency)**

1. **Testicular feminization** (also referred to as **androgen insensitivity syndrome**) is the most common form of male pseudohermaphroditism, which is due to a mutation in the androgen receptor gene on Xq11-12. Laboratory findings include increased levels of testosterone, estrogen, and luteinizing hormone (LH).

2. **5 $\alpha$ -reductase deficiency**

■ **Mechanism:** 5 $\alpha$ -reductase is normally required for conversion of testosterone to dihydrotestosterone.

■ **Effects of deficiency:** Patients have ambiguous genitalia until puberty; then, at puberty, increased levels of testosterone cause masculinization of the genitalia.

### FETAL ALCOHOL SYNDROME

**Epidemiology:** Affects more than 1200 children per year. It is the most common form of preventable mental retardation in the United States.

**Mechanism:** Potentially due to acetaldehyde crossing the placenta and damaging the fetal brain.

**Manifestations:** Microcephaly, malformations of the brain, mental retardation, and facial malformations (e.g., short palpebral fissures, maxillary hypoplasia, and smooth philtrum, or upper lip).

*This page intentionally left blank*





# CHAPTER 7

## PEDIATRIC PATHOLOGY

### OVERVIEW

Although many conditions that affect adults also affect children, pediatric pathology includes many conditions found only in patients younger than 18 years of age. This chapter will address many of these conditions.

One group of conditions involving the infant population is congenital anomalies. Several terms are important to remember when discussing congenital anomalies. A **malformation** is a congenital anomaly due to an intrinsic defect in development. A **disruption** occurs when a normally developing organ is secondarily damaged by another process. For example, in **amniotic band syndrome**, a fragment of the amniotic membrane wraps around a portion of the body and damages or amputates it. A **deformation** is an abnormal development of an organ due to an extrinsic process. A **sequence** is a collection of several anomalies, all of which are due to one malformation, disruption, or deformation. For example, **Potter sequence** is due to oligohydramnios and includes flat facies, small chest, hypoplastic lungs, club foot (**talipes equinovarus**), and nodules in the amniotic sac. Finally, a **syndrome** is a group of related anomalies. Common congenital anomalies include clubfoot, patent ductus arteriosus, ventricular septal defect, and cleft lip or cleft palate. Although most congenital anomalies are diagnosed during infancy, they are present and can cause complications into adulthood.

This chapter will discuss causes of congenital anomalies and major congenital anomalies by organ system. Also discussed are conditions diagnosed in the pediatric population such as prematurity, perinatal infections, hydrops fetalis, sudden infant death syndrome (SIDS), and select pediatric tumors, including neuroblastoma and Wilms tumor.

### CAUSES OF CONGENITAL ANOMALIES

**Overview:** The causes of congenital anomalies are genetic, environmental, and multifactorial; however, the etiology of many congenital anomalies is unknown. Two common environmental causes of congenital anomalies are nicotine and maternal diabetes mellitus.

- **Nicotine:** Use of nicotine when pregnant predisposes the mother to a high risk for spontaneous abortion, placental abruption, premature labor, or placental abnormalities.

- **Maternal diabetes mellitus:** Predisposes to a large-for-gestational-age fetus, neural tube defects, and neonatal hypoglycemia. The most common associated anomalies are cardiac. The most severe associated disorder is **caudal regression syndrome** (also referred to as “**mermaid syndrome**”), which causes fused, malformed lower extremities and sacral agenesis.

## MAJOR CONGENITAL ANOMALIES BY ORGAN SYSTEM

### Cardiac anomalies

**Ventricular septal defect, atrial septal defect, patent ductus arteriosus, and tetralogy of Fallot** are only a few of many cardiac congenital anomalies (see Chapter 10).

**Central nervous system anomalies: Anencephaly and holoprosencephaly** are only two of many congenital anomalies of the central nervous system (see Chapter 11).

**Respiratory system congenital anomalies:** Although there are other congenital anomalies of the respiratory system, only pulmonary sequestration and foregut cysts will be discussed below.

### Pulmonary sequestration

- **Basic description:** Discrete region of lung tissue that has no connection to the airway.
- **Forms**
  - **Extralobar sequestration:** Discrete mass of lung tissue occurring outside the lungs. Infants can present with a mass lesion.
  - **Intralobar sequestration:** Discrete mass of lung tissue occurring within one of the lung lobes, yet has no connection to the airway. Patients can present with symptoms of bronchopneumonia or bronchiectasis.

### Foregut cysts

- **Basic description:** Cyst derived from an abnormally detached portion of the foregut that can arise within the mediastinum or pulmonary hilum.
- **Clinical presentation:** Can be asymptomatic or present because of mass effects or because it has become infected.

### Gastrointestinal tract and pancreatic congenital anomalies:

Although there are many congenital anomalies of the gastrointestinal tract and pancreas, four of the more common anomalies are tracheo-esophageal fistula, omphalocele, gastroschisis, and pancreas divisum, which are discussed below.

### Tracheo-esophageal fistula

- **Basic description:** Condition associated with an atretic esophagus with a fistulous connection to the trachea. The most common variant is a blind-ended proximal esophagus with a distal esophagus that connects to the trachea.
- **Clinical presentation:** Aspiration of food with potential for suffocation or development of pneumonia.

**Omphalocele:** Infants have herniated abdominal organs in a membranous sac composed of amnion and peritoneum. The condition is due to failure of formation of the abdominal wall musculature. The umbilical cord arises from the dome of the membranous sac.

**Gastroschisis:** Infants have failure of formation of the abdominal wall with the resultant evisceration of abdominal organs. The abdominal organs are present outside the peritoneal cavity, just to the right of the umbilical cord, and are not covered by a membranous sac (Figure 7-1).

**Pancreas divisum:** Pancreas divisum is due to failure of the dorsal and ventral pancreatic ducts to fuse, resulting in drainage of most of the organ through the dorsal pancreatic duct (Santorini) and smaller minor papilla. This congenital anomaly can lead to stenosis of the duct and resultant chronic pancreatitis.

**Renal congenital anomalies:** Although there are many congenital anomalies involving the kidneys, only agenesis of the kidney, ectopic kidney, and horseshoe kidney will be discussed below.

**Agenesis of the kidney:** Bilateral renal agenesis (i.e., failure of formation of both kidneys) will cause the death of an infant; unilateral agenesis is compatible with life.

**Ectopic kidney:** The kidney is abnormally located near the pelvic brim or within the pelvis. Abnormal location can lead to kinking of the urethra and predispose to pyelonephritis.

**Horseshoe kidney:** While commonly associated with Turner syndrome, horseshoe kidneys (usually with fusion of the lower poles of both kidneys) are a relatively common sporadic renal congenital anomaly.

#### Male genital tract anomalies

**Hypospadias and epispadias:** In hypospadias, the urethral opening is abnormally located on the ventral surface of the penis; in epispadias, the urethral opening is located on the dorsal surface of the penis. The anomaly can be associated with other anomalies of the genitourinary tract, and can predispose to sterility and to urinary tract infections.

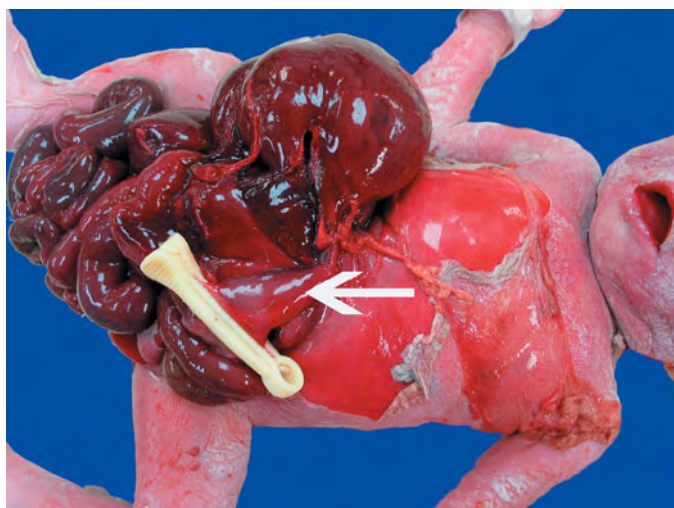
**Phimosis:** A small foreskin orifice prevents its normal retraction. If the foreskin is forcibly retracted, constriction of the glans penis can occur, causing pain and urethral constriction (termed **paraphimosis**).

## PREMATURITY AND ITS COMPLICATIONS

**Basic description of prematurity:** Age at delivery is less than 37 weeks' gestation (for singleton pregnancy).

**Risk factors for prematurity:** Premature rupture of membranes, infections such as chorioamnionitis, maternal genitourinary abnormalities, twin or multiple gestation pregnancies, and preeclampsia.

**Causes of prematurity:** The causes of prematurity can be grouped into fetal, placental, and maternal categories.



**Figure 7-1.** Gastroschisis. This infant had extrusion of the liver, small intestine, and large intestine through a defect in the abdominal wall. Note that the extruded abdominal contents are not covered by a thin membranous sac, and that they exit the abdominal wall to the right of the umbilicus (arrow).



### 1. Fetal causes of prematurity

- **Specific fetal cause of prematurity:** Chorioamnionitis.
- **Result of fetal cause of prematurity:** Small-for-gestational-age infant with **symmetric growth retardation** (also called **proportionate fetal growth restriction** because the entire body is small).

### 2. Placental causes of prematurity

- **Specific placental causes of prematurity:** Uteroplacental insufficiency, such as occurs with a single umbilical artery, placental infarction, and placenta previa.
- **Result of placental cause of prematurity:** Small-for-gestational-age infant with **asymmetric growth retardation** (also called **disproportionate growth restriction**). The head is normal size and the body is small; the head receives a disproportionate amount of oxygen and nutrients to preserve its development.

### 3. Maternal causes of prematurity

- **Specific maternal causes of prematurity:** Preeclampsia, maternal hypertension, alcohol and nicotine use, and maternal malnutrition.
- **Result of maternal cause of prematurity:** Small-for-gestational-age infant.

**Complications of prematurity:** The three main complications of prematurity are hyaline membrane disease, necrotizing enterocolitis, and germinal matrix hemorrhage.

#### 1. Hyaline membrane disease

**Basic description:** Condition due to deficiency of pulmonary surfactant, which occurs because fetal lungs are not fully developed.

**Pathogenesis:** Decreased surfactant leads to atelectasis, which causes hypoxemia and carbon dioxide retention. Hypoxemia and carbon dioxide retention lead to acidosis, which contributes to hypoperfusion of the pulmonary parenchyma and eventually to endothelial and epithelial damage.

#### Morphology of hyaline membrane disease

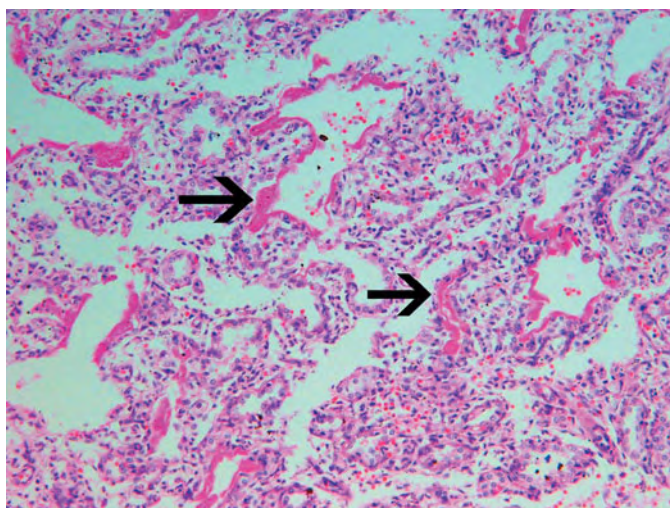
- Gross: Firm lungs.
- Microscopic: Hyaline membranes lining alveolar septae (Figure 7-2).

**Treatment:** Surfactant and oxygen therapy.

**Clinical presentation of hyaline membrane disease:** Manifests as tachypnea, cyanosis, and grunting within the first few hours of life. The pattern seen on a chest radiograph is classic with infants having diffuse reticulonodular (“ground-glass”) infiltrates. Pretreatment with corticosteroid therapy 24–48 hours prior to birth can improve surfactant production and decrease the incidence of hyaline membrane disease in at risk fetuses.

#### Complications of treatment of hyaline membrane disease

- **Retrolental fibroplasia**, which is retinal vessel proliferation that occurs because hypoxemia induces vascular endothelial growth factor (VEGF). This disorder is caused by the administration of high concentrations of oxygen over long periods of time.



**Figure 7-2.** Hyaline membrane disease. The alveolar septae are focally lined by acellular, proteinaceous membranes (arrows). The presence of these membranes impairs ventilation. Hyaline membrane disease is a complication of prematurity. Hematoxylin and eosin, 200×.



■ **Bronchopulmonary dysplasia** is a clinical rather than a pathologic diagnosis, and is defined as supplemental oxygen requirements beyond 28 days of life. Histologic examination of the lungs of infants with bronchopulmonary dysplasia reveals alveolar hypoplasia and, depending upon the timing of the condition, alveolar septal fibrosis, squamous metaplasia, and hyperplasia of epithelial cells.

## 2. Necrotizing enterocolitis

**Basic description:** Necrosis of the intestinal tract.

**Pathogenesis:** Most likely multifactorial.

### Morphology

■ **Gross:** Can see air within the wall of the intestine; intestinal lumen is dilated and the wall is friable (i.e., easily tears apart) (Figure 7-3).

■ **Microscopic:** Ischemic changes of the intestine.

**Clinical presentation of necrotizing enterocolitis:** Signs and symptoms are due to bowel ischemia and are characterized by abdominal distention, bloody diarrhea, temperature instability, acidosis, and sepsis and shock. The classic radiologic finding is air within the bowel wall, known as “**pneumatosis intestinalis.**”

## 3. Germinal matrix (intraventricular) hemorrhage

**Basic description:** Hemorrhage into the germinal matrix, usually with extension into the ventricles, and potential compression and necrosis of periventricular white matter and gray matter (Figure 7-4).

**Pathogenesis:** The germinal matrix has many immature neurons and extensive vasculature and, because of prematurity, the vasculature is fragile and bleeds easily.

**Clinical presentation of germinal matrix hemorrhage:** Lethargy, poor feeding, and bulging fontanelle. Germinal matrix hemorrhages are diagnosed with the use of cranial ultrasound.

## PERINATAL INFECTIONS

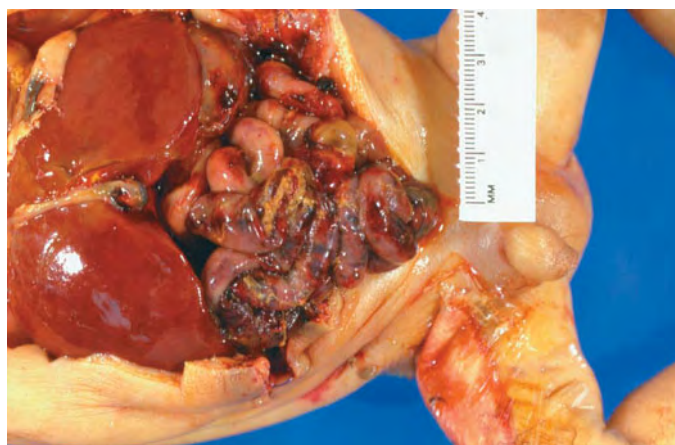**General routes of acquisition:** Transcervical (acquired by inhaling infected amniotic fluid or during delivery), and transplacental (organisms can cross through the placenta to infect the fetus). Transplacental infections are notably caused by Parvovirus and TORCH organisms (*toxoplasmosis, other agents, rubella, cytomegalovirus, and herpes simplex*).

### Specific perinatal infections

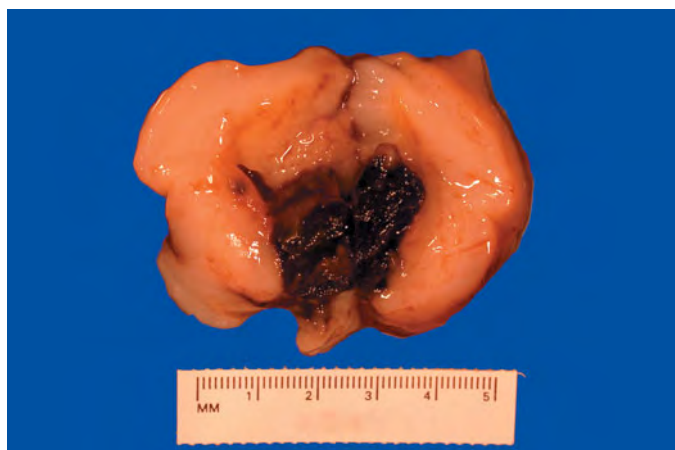#### 1. Congenital herpes simplex virus (HSV) infection

**Route of acquisition:** Usually occurs during delivery (transcervical). The risk of transmission to the fetus is highest with a maternal primary outbreak. In secondary outbreaks (i.e., chronic relapsing genital HSV), preformed maternal antibodies confer some protection to the fetus.

**Features:** Include cutaneous disease with classic vesicular lesions, encephalitis, and disseminated disease presenting similar to that of sepsis.



**Figure 7-3.** Necrotizing enterocolitis. This premature infant developed necrotizing enterocolitis. The small intestine is focally ischemic (red discoloration).



**Figure 7-4.** Germinal matrix hemorrhage. This premature infant had blood in the cerebral ventricles, which resulted from a germinal matrix hemorrhage. The grade (and thus severity) of a germinal matrix hemorrhage is partially dependent upon the degree of filling and distension of the cerebral ventricles. A grade IV germinal matrix hemorrhage (the most severe form) has necrosis of the surrounding cerebral parenchyma.

## 2. Cytomegalovirus (CMV) infection

### Routes of acquisition

- Can be congenital due to newly acquired infection in the mother. The highest risk of congenital infection is when maternal infection occurs during the second trimester.
- Can be perinatal due to cervical or vaginal secretions or from milk.

**Features of congenital CMV infection:** Include intrauterine growth retardation, hepatosplenomegaly, hemolytic anemia, encephalitis, and microcephaly. Periventricular calcifications are classic findings identified on CT scan. Congenital CMV infection can produce a purpura similar to the “blueberry muffin baby” seen in congenital rubella.

## 3. Congenital rubella

**Route of acquisition:** Transplacental.

**Time period:** Fetus is at risk up to week 16 of gestation.

**Features of congenital rubella infection:** Tetrad of cataracts, heart defect (e.g., patent ductus arteriosus, pulmonary stenosis), deafness, and mental retardation. “Blueberry muffin” purpura caused by extramedullary hematopoiesis is a classic finding.

## 4. Congenital syphilis

**Route of acquisition:** Transplacental.

**Time period:** Maternal transmission to fetus occurs during primary or secondary syphilis.

### Features of congenital syphilis

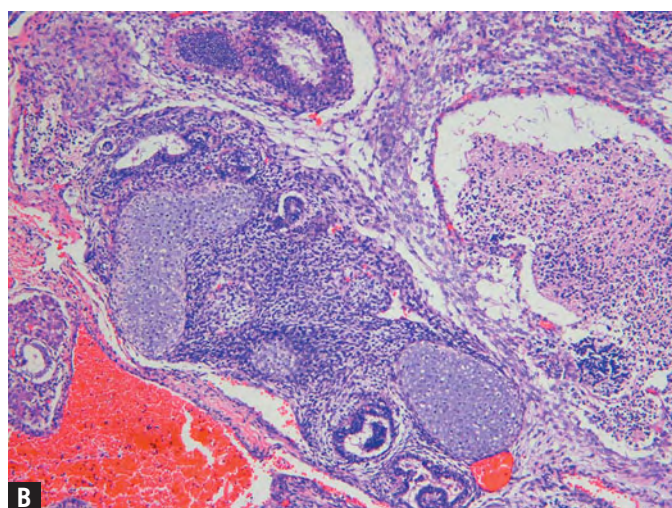
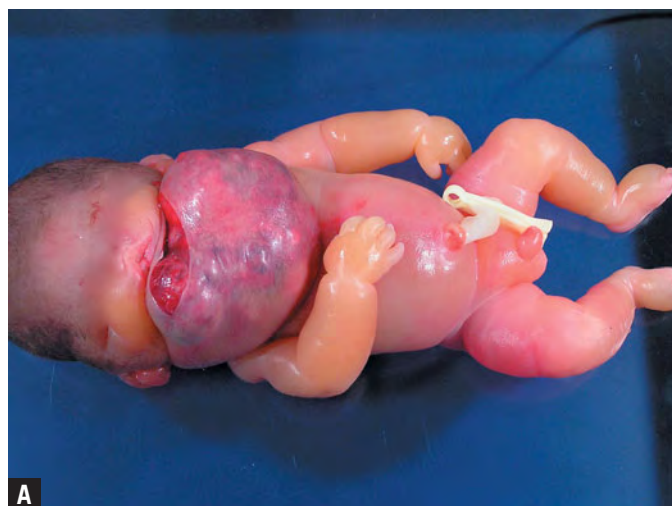- **Early manifestations:** Nasal discharge (“snuffles”) and congestion; desquamative rash.
- **Late manifestations:** Notched central incisors (“Hutchinson teeth”), interstitial keratitis with blindness, saddle nose, saber shins, and deafness.

### Features of syphilis in adults

- **Primary stage:** Firm, painless, ulcerated lesion (**chancre**).
- **Secondary stage:** Occurs 2–10 weeks after primary infection and consists of maculopapular scaly or pustular rash (classically on soles and palms); **condyloma lata** are broad-based plaques on moist skin.
- **Tertiary stage:** Occurs 5 or more years after secondary stage. Manifestations include progressive “bark-like” dilation of aortic root (“**luetic aneurysm**”), **tabes dorsalis**, **Argyll-Robertson pupils**, and general paresis. Tabes dorsalis is caused by degeneration of the dorsal columns of the spinal cord, and patients present with broad-based gait, loss of proprioception, and lightning-like pains in the lower extremities. Argyll-Robertson pupils are small and irregular and react to accommodation but not to light.

## FETAL HYDROPS

**Basic description:** Edema occurring during gestation (Figure 7-5 A and B).



**Figure 7-5.** Fetal hydrops due to congenital cervical teratoma. **A**, This infant is diffusely and markedly edematous. The fetal hydrops was the result of the large mass in the neck and its pressure on adjacent vessels. **B**, The mass is a congenital cervical teratoma. Note the cartilage interspersed between clusters of immature cells. The most common teratoma associated with a fetus is a sacrococcygeal teratoma. A sacrococcygeal teratoma can impair the birth process by obstructing the transit of the fetus through the birth canal. Hematoxylin and eosin, 200 $\times$ .

### Immune causes of fetal hydrops

- Most commonly due to Rh incompatibility. In most cases, it is due to an Rh-negative mother giving birth to her second Rh-positive child.
- Occasionally occurs with ABO blood groups and other red blood cell antigens.

### Nonimmune causes of fetal hydrops

- Cardiovascular malformations.
- Chromosomal anomalies (e.g., Turner syndrome).
- Fetal anemia (such as occurs in Parvovirus infection).

## SUDDEN INFANT DEATH SYNDROME (SIDS)

**Basic description:** The death of an infant that is unexplained after complete investigation, including autopsy.

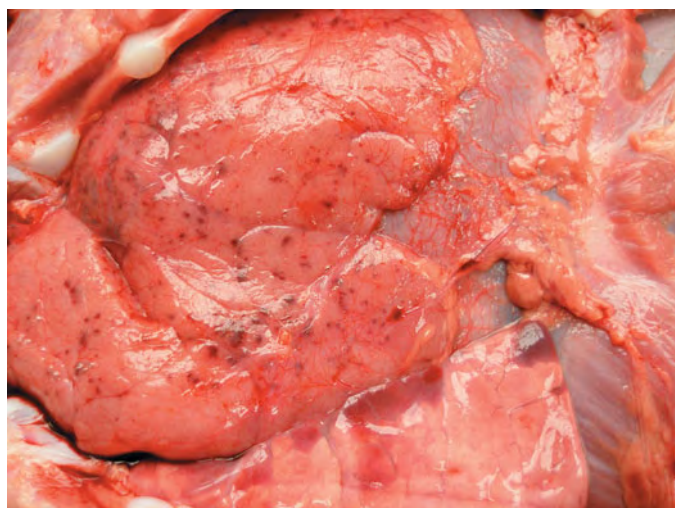
**Epidemiology:** Infant is older than 1 month and younger than 1 year of age, and most commonly between 2 to 4 months of age.

### Risk factors for SIDS

- **Parental risk factors:** Younger than 20 years of age; maternal cigarette smoking during pregnancy.
- **Infant risk factors:** Male gender; prematurity.
- **Environmental risk factors:** Prone sleeping position; exposure to second-hand smoke.

**Other possible causes of sudden unexpected death at younger than 1 year of age:** Myocarditis, suffocation (accidental or homicidal), long QT syndrome, and fatty acid oxidation disorders such as medium chain acyl CoA dehydrogenase deficiency (MCAD).

**Morphology of SIDS:** Thymic and pleural petechiae (not specific for SIDS) (Figure 7-6).



**Figure 7-6.** Thymic petechiae. The numerous pinpoint hemorrhages (petechiae) were identified in the thymus of this infant who died as a result of sudden infant death syndrome (SIDS). Although thymic petechiae are often identified in infants who have died as a result of SIDS, they are not specific for the condition.

## PEDIATRIC NEOPLASMS

**Common pediatric neoplasms:** Leukemia, neuroblastoma, Wilms tumor, hepatoblastoma, retinoblastoma, and rhabdomyosarcoma.

**Small round cell tumors:** General term used to describe many pediatric tumors. The histologic appearance of the neoplastic cells is often not distinctive; hence the generalized name of small round cell tumors. Correct diagnosis is based upon location of the tumor and other ancillary studies, including immunohistochemistry and chromosomal analysis (Table 7-1). Small round cell tumors to be discussed below include Ewing sarcoma and primitive neuroectodermal tumor, rhabdomyosarcoma, Burkitt lymphoma, medulloblastoma, neuroblastoma, and Wilms tumor. Ewing sarcoma is discussed in more detail in Chapter 19, Pathology of the Bones and Joints. Burkitt lymphoma is discussed in more detail in Chapter 12, Hematopathology. Medulloblastoma is discussed in more detail in Chapter 11, Neuropathology.



**TABLE 7-1.** Small Round Cell Tumors

Neoplasm	Genetic Abnormality	Immunostain
Ewing sarcoma and PNET	t(11;22)	CD99 positivity
Rhabdomyosarcoma	t(2;13), t(1;13)	MyoD1
Burkitt lymphoma	t(8;14), t(2;8), t(8;22)	CD10, CD19 positivity
Medulloblastoma	17p deletion	GFAP, synaptophysin positivity
Neuroblastoma	N-MYC	Neuron-specific enolase positivity
Wilms tumor	11p13 deletion	

GFAP, glial fibrillary acidic protein; PNET, primitive neuroectodermal tumor.

#### **Ewing sarcoma and primitive neuroectodermal tumor (PNET):**

Ewing sarcoma and PNET are positive with a CD99 (MIC2) immunostain, and their characteristic chromosomal abnormality is a t(11;22) translocation.

**Rhabdomyosarcoma:** Rhabdomyosarcoma is positive with a MyoD1 immunostain, and their characteristic chromosomal abnormality is a t(2;13) translocation.

**Burkitt lymphoma:** Burkitt lymphoma cells are positive for CD10, CD19 and CD20, and their characteristic chromosomal abnormality is a t(8;14) translocation.

**Medulloblastoma:** Medulloblastoma is positive for either synaptophysin or glial fibrillary acidic protein (GFAP) immunostain, and their characteristic chromosomal abnormality is a 17p deletion or isochromosome 17q.

### **NEUROBLASTOMA**

**Epidemiology:** Neuroblastomas represent about 7–10% of all pediatric malignancies; the average age at diagnosis is 2 years. The tumor has a male predominance, and is more common in whites than in African Americans.

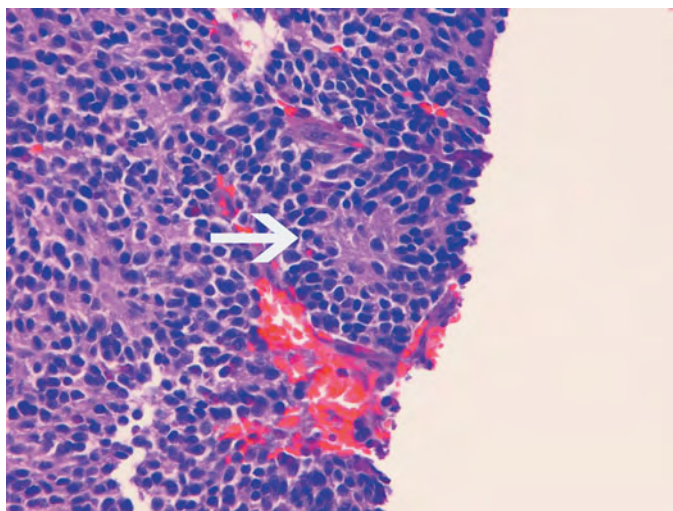
**Location:** About 40% are in the adrenal medulla; others occur in the sympathetic chain.

#### **Morphology of neuroblastoma**

■ **Gross:** Soft, gray-tan mass.

■ **Microscopic:** Small round blue cells with background of neuropil. The neoplastic cells are positive for neuron-specific enolase immunostain, and can form **Homer-Wright rosettes** (a circle of neoplastic cells around a space with neuropil) (see Figure 7-7).

**Clinical Course:** Some neuroblastomas are asymptomatic, and some spontaneously mature to become a ganglioneuroblastoma (neuroblastoma cells admixed with mature ganglion cells) and further mature to a ganglioneuroma (mature ganglion cells admixed with Schwannian stroma).



**Figure 7-7.** Neuroblastoma. Neuroblastoma is one of the small round cell tumors of childhood and frequently arises within the adrenal gland. The arrow indicates a Homer-Wright rosette, a histologic feature that is characteristic of a neuroblastoma. Hematoxylin and eosin, 400×.



### Prognostic factors for neuroblastoma

- **Age:** If diagnosed at younger than 1 year of age, the patient has an excellent prognosis. Children diagnosed between 1 and 5 years of age have an intermediate prognosis.
- **N-MYC amplification:** Presence of N-MYC amplification is a poor prognostic indicator, while absence of N-MYC amplification is a good prognostic indicator.
- **Histology**
  - **Good prognosis:** Schwannian stroma, calcification, and low mitotic rate.
  - **Poor prognosis:** No Schwannian stroma, no calcification, and high mitotic rate.
- **Other prognostic factors**
  - Hyperdiploid or near triploid is a good prognostic indicator, whereas diploid or near diploid is a poor prognostic indicator.
  - Stage.

**Laboratory studies:** About 85% of these tumors secrete catecholamines into the blood. Urinalysis reveals elevated levels of vanillylmandelic acid (VMA) and homovanillic acid (HVA).

**Clinical presentation of neuroblastoma:** Neuroblastomas usually present before age 5. The classic clinical signs include **opso-clonus-myoclonus syndrome** (“dancing eyes-dancing feet”), which is present in only 2% of patients, and periorbital ecchymoses (“raccoon eyes”) secondary to metastasis to the orbits.

## WILMS TUMOR

**Epidemiology of Wilms tumor:** Average age at diagnosis is between 2 to 5 years of age.

**Location of Wilms tumor:** Kidney; 5–10% of cases have involvement of both kidneys, either synchronous (at same time) or metasynchronous (one after the other).

**Precursor lesion:** Nephrogenic rests.

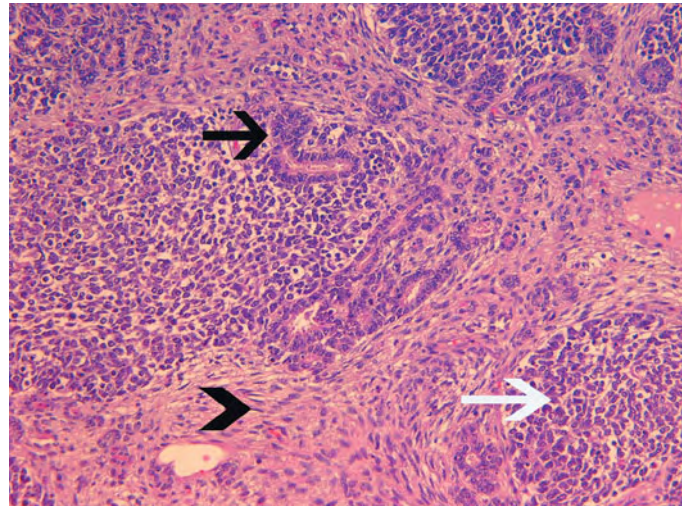
### Morphology of Wilms tumor

- **Gross:** Soft, tan mass.
- **Microscopic:** Triphasic (epithelial, stromal, and blastemal). Triphasic Wilms tumors are fairly readily diagnosed histologically; however, Wilms tumor can be monophasic, with only one of the three above listed histologic architectures. A blastemal Wilms tumor can be difficult to distinguish from other small round cell tumors (see Figure 7-8).

### Associated conditions with high risk for Wilms tumor

#### 1. WAGR syndrome

- **Features:** Wilms tumor, aniridia, genital anomalies, mental retardation.
- **Gene involved:** 11p13 del (*WT1*).



**Figure 7-8.** Wilms tumor. This photomicrograph illustrates the characteristic triphasic histologic appearance of Wilms tumor. Epithelial (black arrow), stromal (black arrowhead), and blastemal (white arrow) components are all readily identified. A monophasic Wilms tumor, composed only of blastemal cellular architecture, can easily be confused histologically with some of the other small round cell tumors of childhood. Hematoxylin and eosin, 200×.

## 2. Denys-Drash syndrome

- **Features:** Gonadal dysgenesis (male pseudohermaphrodite); nephropathy.
- **Gene involved:** *WT1*.

## 3. Beckwith-Wiedemann syndrome

- **Features:** Organomegaly, macroglossia, hemihypertrophy.
- **Gene involved:** 11p15.5 (*WT2*).



## CHAPTER 8

# HEMODYNAMICS

### OVERVIEW

In general terms, the topic of hemodynamics deals with flow and distribution of blood and fluids within the body. To maintain the correct amount of intravascular and extravascular volumes, the body must maintain both **hydrostatic pressure** and **osmotic pressure**. In vessels, hydrostatic pressure refers to the pressure pushing fluid out into the interstitial tissue. In interstitial tissue, hydrostatic pressure pushes fluid into the vessels. Osmotic pressure, which is imparted by the presence of dissolved solutes, pulls fluid into the vessels and into the interstitial tissue. An imbalance in either of these two pressures results in an abnormal distribution of fluid in the cells or interstitial tissues. The term used to describe excessive amounts of fluid within the interstitial tissues or within cells is **edema**.

The integrity of vessel walls plays a critical role in maintaining normal distribution of fluid in the vessels and interstitial tissues. The process of **coagulation** serves to maintain the integrity of the vasculature in the event of disruption of the vascular wall. Inappropriate coagulation can have deleterious consequences, however. For example, abnormal coagulation can result in vessel occlusion; thus the process must be closely controlled. An adequate supply of blood to the tissues is vital because it provides oxygen and nutrients to the cells and removes toxic metabolites from the cells. An inadequate amount of blood flow to an organ is termed **ischemia**. Ischemia is an important cause of cellular dysfunction and, if severe, often leads to cell death. The resultant area of necrotic cells is termed an **infarct**. In addition to localized ischemia due to occlusion of blood vessels, a more generalized ischemia can occur due to widespread hypoperfusion of the body. This generalized hypoperfusion of the organs and resultant organ damage is called **shock**. Shock can result from a decreased amount of blood (i.e., **hypovolemic shock**), failure of the heart to effectively pump the blood (i.e., **cardiogenic shock**), or generalized dilation of the vasculature system secondary to infection (i.e., **septic shock**). This chapter will discuss edema, hyperemia and congestion, hemorrhage, thrombi, emboli, infarcts, and shock.



## EDEMA

**Basic description:** Accumulation of fluid within the cells, interstitial tissue, and body cavities.

**Mechanisms of edema formation:** Include increased vascular hydrostatic pressure, decreased plasma osmotic pressure, lymphatic obstruction, and inflammation. Increased vascular hydrostatic pressure is usually due to impaired venous return or arteriolar dilation.

### Causes of increased vascular hydrostatic pressure

- **Heart failure:** The heart is not pumping blood as effectively as it should, so there is a back up of blood into the veins.
- **Cirrhosis:** Fibrous scarring of the liver that impairs return of blood through the portal vein, thereby increasing venous pressure in portal vein tributaries and causing fluid to leak into the peritoneal cavity.
- **Venous obstruction:** For example, a tumor pushing on a vein will cause back up of blood, eventually with leakage of fluid into the interstitium.

### Causes of decreased plasma osmotic pressure

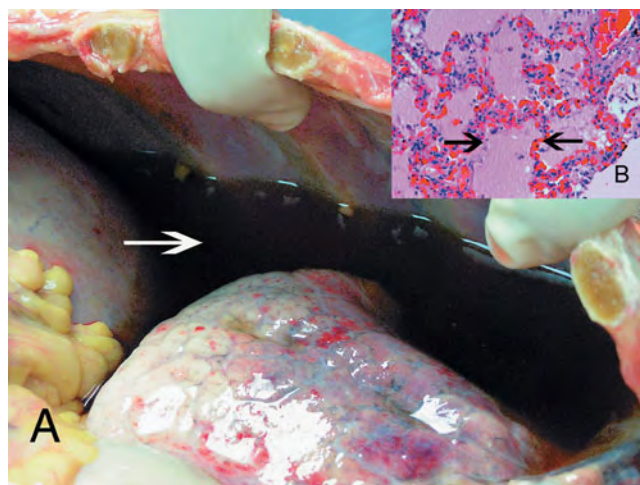
- **Decreased production of albumin by the liver** (e.g., in cirrhosis or other forms of generalized liver damage). A decreased level of albumin results in edema through decreased plasma osmotic pressure. Also, the decreased intravascular volume that accompanies edema stimulates an elevated level of aldosterone. The elevated level of aldosterone, along with several complex changes within the kidney, promotes sodium and water retention. However, because the patient with cirrhosis is hypoalbuminemic, the retained water enters the interstitial space, further contributing to the formation of edema.
- **Increased loss of protein by the kidney** (e.g., certain glomerular diseases) **or in the gut** (e.g., protein-losing gastroenteropathy).
- **Malnutrition.**

**Causes of lymphatic obstruction:** Lymphoma compressing the thoracic duct or lymphatic channels; certain parasitic infestations, such as elephantiasis.

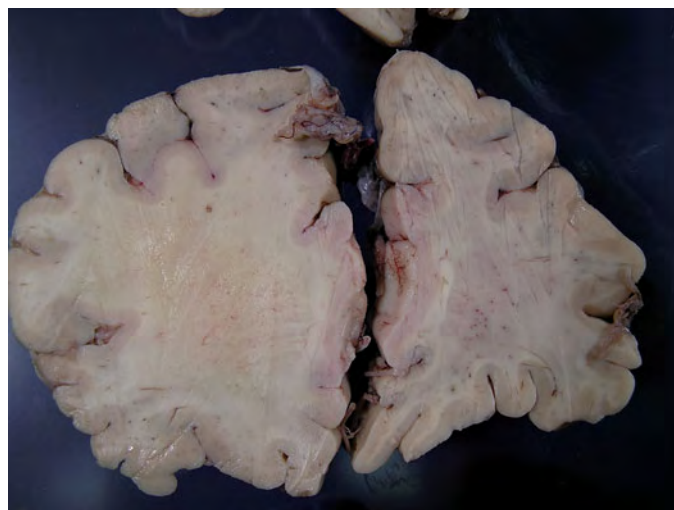
**Inflammation:** An important component of acute inflammation is increased vascular permeability, which causes edema.

### Effects of edema depend upon organ involved

- **In soft tissues of the extremities:** Edema usually produces no clinically significant damage. Over time, edema can cause changes in skin, but these are usually only cosmetic.
- **In the lungs:** Edema fluid fills the alveoli and pleural cavities, impairing the ability of the lung to oxygenate the red blood cells (Figure 8-1 A and B).
- **In the brain:** The brain is in a rigid compartment; edema causes the brain to swell, producing **increased intracranial pressure** (Figure 8-2). When the brain swells, there are only a few places into which it can expand. These expansions of the brain through available spaces are called **herniations**. Types of herniation include subfalcine, uncal, and cerebellar tonsillar (see Chapter 11 for further discussion of herniation).



**Figure 8-1.** Pleural effusion with pulmonary edema. **A**, Accumulation of fluid in the pleural cavities, or pleural effusions (arrow), may cause respiratory problems by limiting expansion of the lungs. **B**, Microscopic section from a patient with pulmonary edema. The edema fluid (arrows) stains light pink in this hematoxylin and eosin stained section and fills the alveolar spaces. The presence of fluid within the alveoli interferes with proper oxygenation of blood in the alveolar capillaries. Hematoxylin and eosin, 200 $\times$ .



**Figure 8-2.** Cerebral edema. This patient had a neoplasm on the left side of the brain. The edema of the brain was confined to the left cerebral hemisphere (the site of the tumor), and serves to illustrate the appearance of an edematous versus nonedematous brain. Expansion of the cerebral parenchyma, as seen in the section on the left side of the image, displaces the nonedematous right hemisphere in this case. Various herniation patterns may also occur in this condition. Note the flattening of the crests of the cortical gyri, caused by pressure on the brain from the inner surface of the skull.



### Important concepts and terms

- **Transudate:** Protein and cell-poor fluid that has a specific gravity  $< 1.012$ . Cardiac failure or decreased protein levels cause a transudate.
- **Exudate:** Protein and cell-rich fluid that has a specific gravity  $> 1.020$ . Inflammation causes an exudate.
- **Dependent edema:** Occurs in the extremities and areas of the body where accumulation of fluid is dependent upon gravity. Dependent edema is most commonly associated with heart failure.
- **Pitting edema:** When the skin and underlying soft tissues of a leg with edema are compressed with fingers, the impressions remain. This type of edema is most commonly associated with heart failure and is usually a transudate (Figure 8-3 A and B).
- **Anasarca:** Generalized edema of the entire body that is most commonly associated with glomerular protein loss by the kidneys.

## HYPEREMIA AND CONGESTION

### Basic descriptions

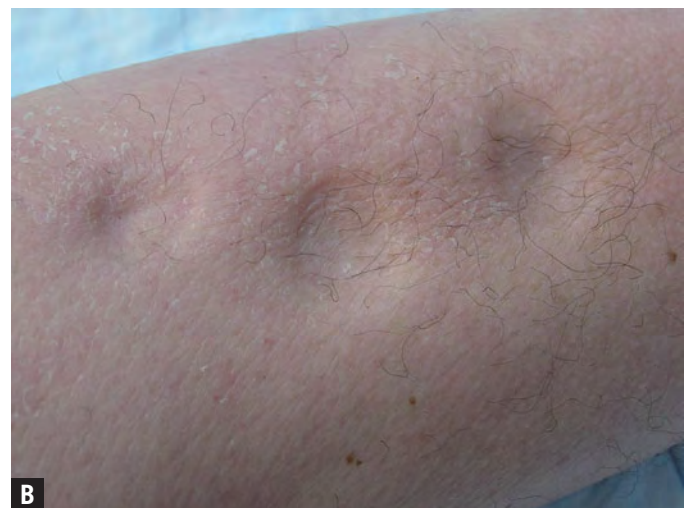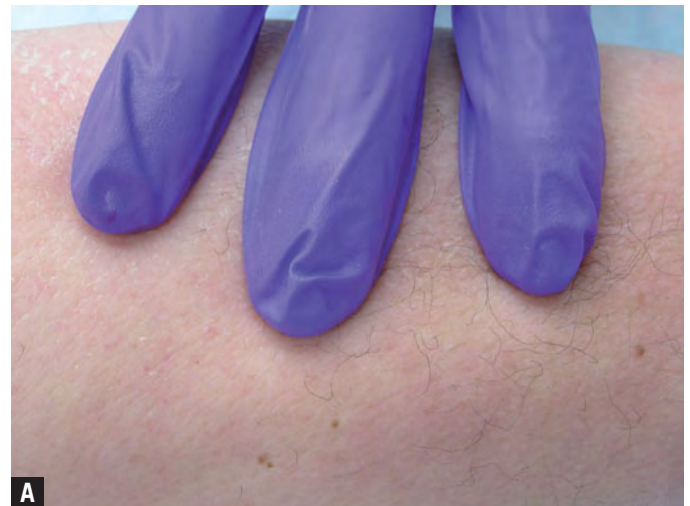- **Hyperemia:** Active accumulation of blood within vessels, such as would occur in vasodilation due to acute inflammation.
- **Congestion:** Passive accumulation of blood within vessels, such as would occur in the lungs due to left-sided heart failure, or in the liver and extremities due to right-sided heart failure.
- **Acute passive congestion:** Passive congestion that developed recently.
- **Chronic passive congestion:** Passive congestion that has been occurring over time and is often associated with hemosiderin-laden macrophages and organ damage.

### Morphology of hyperemia and congestion

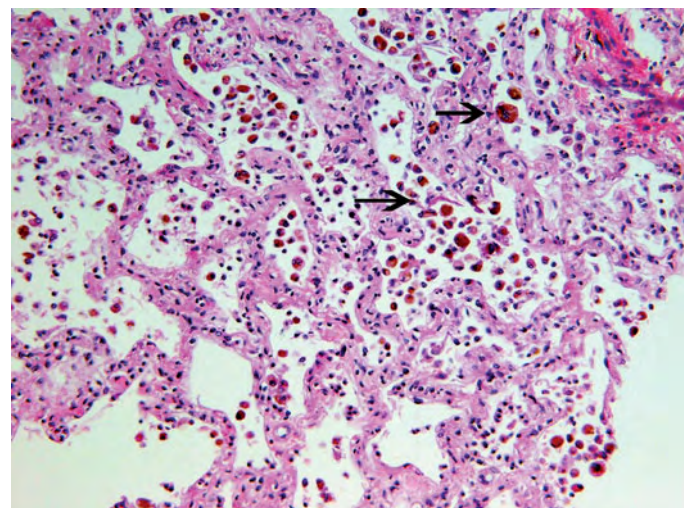
- **Hyperemia and acute passive congestion:** Blood vessels are dilated by red blood cells; to differentiate the two would require knowledge of the scenario in which it is occurring.
- **Chronic passive congestion:** A condition due to multiple episodes of acute passive congestion. Red blood cells break down, leaving hemosiderin and stimulate mild inflammation, which results in scarring.

### Chronic passive congestion of the lung

- **Cause:** Left-sided heart failure, which causes blood to back up into the lungs because the left ventricle is not pumping the blood out as quickly or as efficiently as it should.
- **Gross morphology of chronic passive congestion of the lung:** Darkly pigmented, heavy and firm lungs.
- **Microscopic morphology of chronic passive congestion of the lung:** Hemosiderin in macrophages (“heart failure cells”) and fibrosis of the alveolar septae (Figure 8-4).



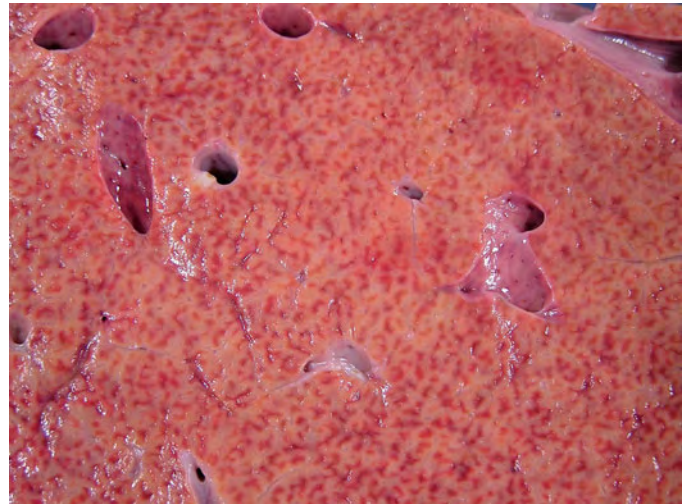
**Figure 8-3.** Pitting edema. Compression of the tissue with fingertips (A) leads to temporary impressions (B). This form of edema is commonly associated with left-sided congestive heart failure and occurs most often in the lower extremities.



**Figure 8-4.** Chronic passive congestion of the lung. The section illustrates the two features of chronic passive congestion of the lung, alveolar septal fibrosis and hemosiderin-laden macrophages (arrows), also called “heart-failure cells.” Hematoxylin and eosin, 200 $\times$ .

### Chronic passive congestion of the liver

- **Cause:** Right-sided heart failure, which causes blood to back up into the liver because the right ventricle is not pumping the blood out as quickly or as efficiently as it should.
- **Mechanism of chronic passive congestion of the liver:** In this condition, passive congestion of the blood with sinusoidal dilation is associated with a component of hypoxic injury. The sinusoidal dilation and hypoxic injury lead to atrophy and sometimes necrosis of the centrilobular hepatocytes.
- **Gross morphology of chronic passive congestion of the liver:** **Nutmeg liver** (shrunken and congested centrilobular areas with raised, tan portal areas) (Figure 8-5).
- **Microscopic morphology of chronic passive congestion of the liver:** Atrophy of the centrilobular hepatocytes associated with sinusoidal dilation. Fibrosis may be present around the central veins. In cases of severe heart failure or shock caused by other conditions, the centrilobular hepatocytes are frankly necrotic.



**Figure 8-5.** Chronic passive congestion of the liver. Shrunken and congested centrilobular areas impart the characteristic “nutmeg” appearance to the liver. This finding is most commonly associated with right-sided congestive heart failure.

## HEMORRHAGE

**Basic description:** Leakage of blood from vessels.

### Types of hemorrhage

#### 1. Petechiae

- **Gross morphology:** Pinpoint hemorrhages.
- **Causes:** Include platelet dysfunction and increased vascular pressure (Figure 8-6).

#### 2. Purpura

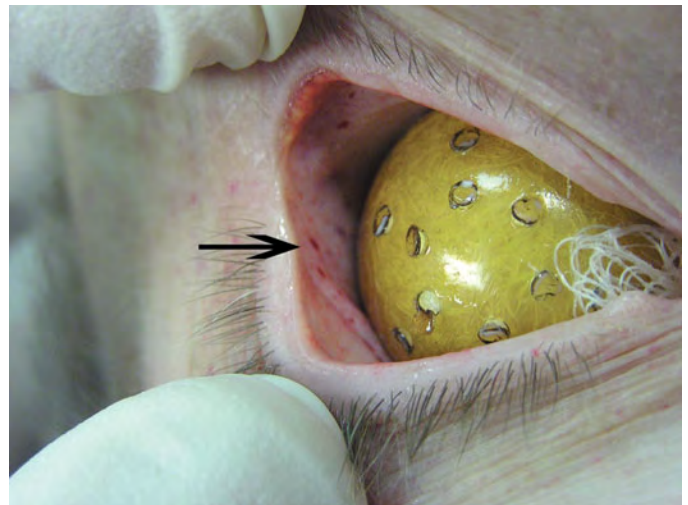
- **Gross morphology:** Larger than petechiae and usually raised.
- **Causes:** Commonly associated with vasculitis.

#### 3. Ecchymoses

- **Gross morphology:** Larger than purpura ( $> 1.0$  cm).
- **Causes:** Trauma.

### Complications of hemorrhage

- **Important point:** To understand the complications of hemorrhage, think about the location of the hemorrhage. For example, a cut in the skin that causes 250 mL of blood loss is usually not clinically significant (the average blood donation is about 450 mL), but a 5-mL hemorrhage in the brainstem can be fatal. To die solely from just the amount of the hemorrhage itself, an individual must lose 40% or more of their blood volume, or about 2000 mL.



**Figure 8-6.** Petechial hemorrhages. The pinpoint hemorrhages (arrow) in the palpebral conjunctivae are petechiae. Petechiae are commonly the result of platelet dysfunction or increased vascular pressures. The clear yellow plastic cap and underlying fibrous material were placed after removal of the cornea for transplantation purposes.



### ADDITIONAL BASIC TERMINOLOGY ASSOCIATED WITH HEMORRHAGE

**Hematoma:** A space-occupying hemorrhage.

**Hemothorax, hemopericardium, and hemoperitoneum:** Hemorrhage within the pleural cavity, the pericardial sac, or the peritoneal cavity, respectively (Figure 8-7 A and B).

### HEMOSTASIS AND THROMBOSIS

**Basic description of hemostasis:** Physiologic coagulation of blood with the purpose of preventing bleeding.

**Basic description of thrombosis:** Pathologic coagulation of blood resulting in the formation of a solid mass within a chamber of the heart or within a blood vessel.

### THROMBUS

**Factors predisposing to thrombus formation (i.e., Virchow triad)**

- **Stasis of blood** (e.g., due to congestive heart failure, obesity, immobilization). Stasis is a particularly common predisposing condition in patients who develop **venous** thrombi.
- **Hypercoagulability:** Hypercoagulable states may contribute to the development of thrombi in any location, and include hereditary conditions as well as various acquired states.
- **Endothelial damage:** Endothelial damage plays a major role in many **arterial** thrombi.

**Important hereditary conditions predisposing to thrombosis (i.e., primary hypercoagulable states)**

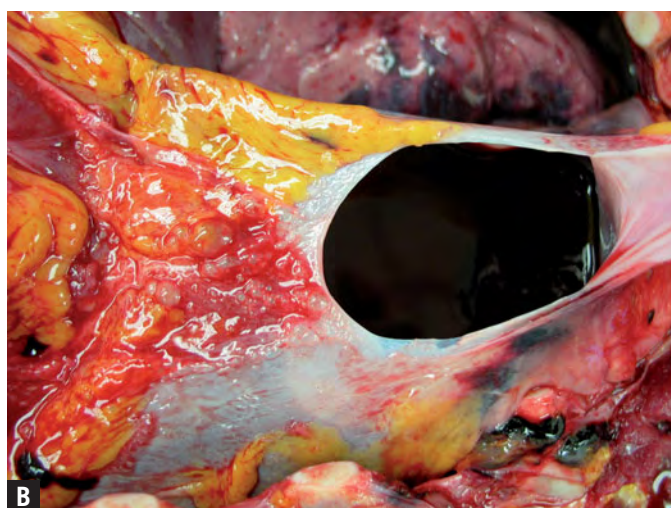
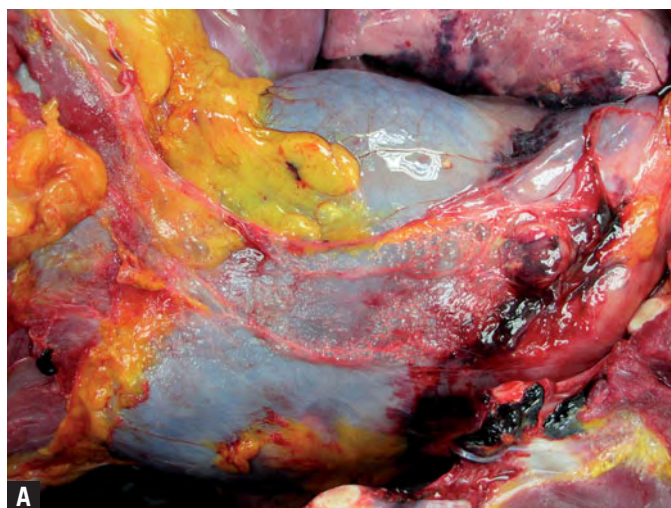
- **Factor V Leiden mutation:** A mutation in the factor V gene removes the cleavage site for protein C from factor V; therefore, protein C is no longer able to cleave activated factor V. The incidence of factor V Leiden mutations is 2–15% of the Caucasian population.
- **Prothrombin gene mutation:** Causes an elevated level of prothrombin. Patients with the prothrombin gene mutation have a threefold risk of having venous thromboses. The incidence is 1–2% of the general population.

**Acquired states predisposing to thrombosis (i.e., secondary hypercoagulable states)**

- Myocardial infarct, tissue damage (e.g., surgery, trauma, burns), cancer, prosthetic cardiac valves, disseminated intravascular coagulation (DIC), heparin-induced thrombocytopenia, and anti-phospholipid antibody syndrome.

**Fates of thrombi:** Propagation, organization, recanalization, dissolution, and embolization.

**Complications of thrombi:** Occlusion of the blood vessel, which leads to ischemia. Ischemia causes cell injury and cell death (necrosis). The region of necrotic cells is referred to as an **infarct**.



**Figure 8-7.** Hemopericardium. The decedent sustained a transected aorta after a motor vehicle collision, causing a hemopericardium. In (A), the pericardial sac is intact (the sternum has been removed), and the blue discoloration visible through it is blood within the pericardial sac. A small amount of blood (200–300 mL) in this location is potentially lethal because of its impairment of the ability of the heart to fill with blood during diastole. In (B), the pericardial sac has been opened, revealing the blood within.

### Morphology of recent thrombi

- **Gross morphology:** Solid red to red-tan mass occluding or partially occluding the lumen of the blood vessel or lining the wall of a cardiac chamber.
- **Microscopic morphology:** Have **Lines of Zahn**, which are alternating layers of red blood cells, platelets, and fibrin within the thrombus (Figure 8-8).

## EMBOLUS

**Overview:** An embolus is a substance that forms within or enters the vascular system at one site and is carried through the blood stream to another area of the body, where it lodges in a blood vessel and produces its effects (usually infarcts). If a thrombus breaks free from where it forms and goes to another part of the body, it becomes a thromboembolus. Substances besides thrombi, such as cardiac valvular vegetations, foreign bodies, fat, and air, can also embolize.

### Types of emboli

#### 1. Pulmonary thromboembolus (Figure 8-9)

**Source:** Deep venous thrombi.

**Risk factors for formation of deep venous thrombi:** Immobility due to obesity, injury, or recent surgery; hereditary hypercoagulable states such as factor V Leiden; oral contraceptives; and neoplasms.

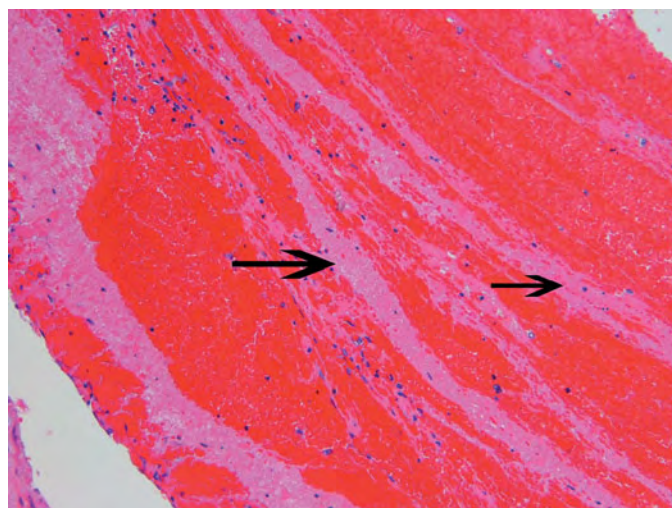
#### Complications of pulmonary thromboemboli

- **Sudden death:** If a pulmonary thromboembolus obstructs more than 60% of the pulmonary vasculature (most often a saddle embolus at the bifurcation of the pulmonary trunk), sudden death of the patient can result.
- **Pulmonary infarct:** Due to occlusion of the blood vessel and resultant ischemic injury of the lung parenchyma. Pulmonary infarcts typically occur when a patient has a thromboembolus in combination with a condition that compromises the bronchial circulation (e.g., congestive heart failure) or in combination with pneumonia (Figure 8-10). The classic radiologic finding of “**Hampton hump**,” a wedge-shaped pleural infiltrate in the lower lobes, is rarely seen.
- **Pulmonary hypertension:** Obstructive lesions compromising a significant percentage (usually > 60%) of the pulmonary arterial circulation increase the work of the right ventricle, leading to pulmonary hypertension.

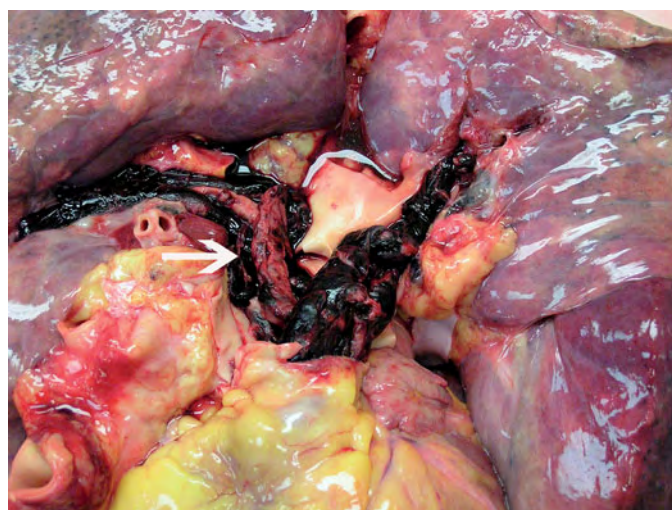
**Gross morphology of pulmonary thromboembolus:** Branching thrombi within the pulmonary vasculature. The branching represents a cast of the vein in which the thrombus formed.

#### Clinical presentation of a pulmonary thromboembolus

- **Symptoms and signs:** Sudden onset of chest pain and dyspnea; tachypnea; cough with or without hemoptysis is present in 50% of cases; and hypoxia (arterial  $pO_2$  is < 80%), respiratory alkalosis, and A-a gradient > 45. The most common electrocardiogram finding is tachycardia. The classic deep S wave in lead I, Q wave, and inverted T wave in lead III (S1-Q3-T3) is uncommon.



**Figure 8-8.** Lines of Zahn. Lamellae of platelets and fibrin (arrows) separated by red blood cells are indicative of a thrombus and are not seen in postmortem “clots.” Hematoxylin and eosin, 200 $\times$ .



**Figure 8-9.** Pulmonary thromboembolus. The pulmonary trunk and proximal right and left pulmonary artery have been opened, revealing a tangled, branching red-tan mass within (arrow). A thromboembolus at this location (a “saddle” thromboembolus) is still a relatively common and often undiagnosed cause of sudden death in a patient in the hospital.



■ **Diagnosis:** Determined by history and physical examination, blood gases, ventilation-perfusion scan of the lung, pulmonary angiography, and spiral CT scans.

## 2. Fat embolus

**Source:** Bone marrow; adipose tissue.

**Risk factors for formation of fat embolus:** Most commonly associated with long bone fractures after motor vehicle accidents and with orthopedic procedures.

**Complications of fat emboli:** High mortality rate.

**Microscopic morphology of fat embolus:** Cleared spaces (vacuoles) in blood vessels that stain positive with an oil-red-O stain for fat in frozen sections (Figure 8-11).

### Clinical presentation of fat embolus (clinical triad)

- Axillary petechiae from emboli lodging in cutaneous vasculature and causing extravasation of blood.
- Altered mental status from emboli to the brain.
- Dyspnea from emboli filling the pulmonary vasculature and impairing the oxygenation of red blood cells.

## 3. Amniotic fluid embolus

**Source:** Amniotic fluid.

**Risk factors for development of amniotic fluid embolus:** Pregnancy causes dilation and distension of pelvic veins. During delivery, these veins can tear, allowing amniotic fluid to enter them.

**Complications of amniotic fluid embolus:** About 80% mortality rate due to development of shock and DIC.

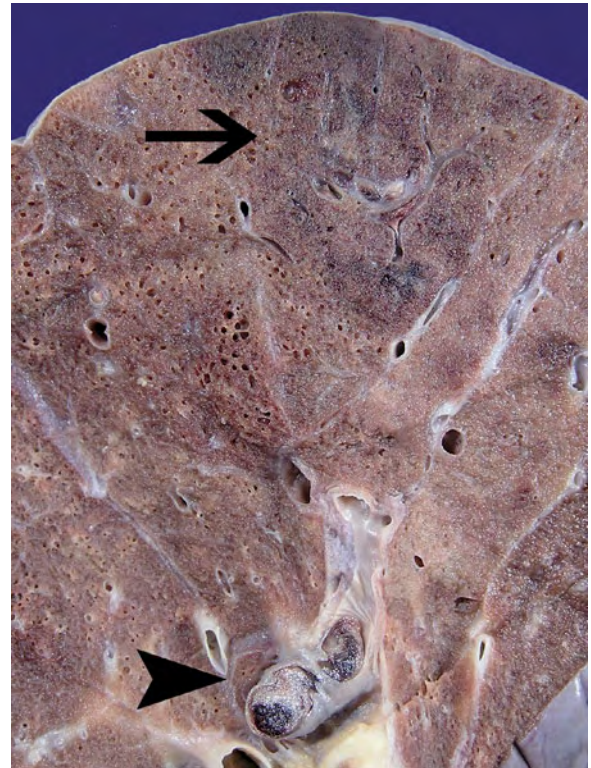
**Microscopic morphology of amniotic fluid embolus:** Anucleate squamous cells in the maternal vasculature.

## 4. Air embolus

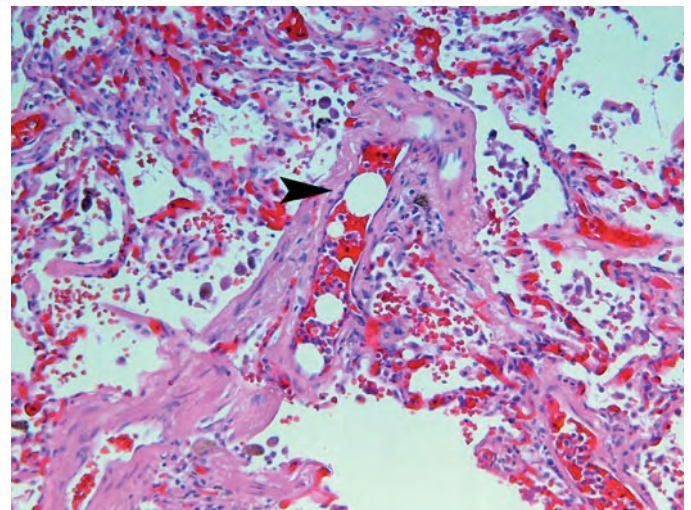
**Source:** A small amount of air injected into the arteries (1–2 mL) can cause complications. For example, if air enters the coronary arteries, even a small amount can cause an infarct of the heart. If air is injected into the veins, a larger amount is required to cause complications (100–200 mL).

**Risk factors for formation of air embolus:** Iatrogenic (medically induced) or traumatic injuries of arteries or veins (e.g., incised wound of the neck).

**Complications:** Infarcts, death.



**Figure 8-10.** Pulmonary thromboembolus causing red “hemorrhagic” infarct. This superior- to inferior-oriented cross-section of the lung reveals a wedge-shaped pulmonary infarct in the upper lobe (arrow) and a thromboembolus near the hilum (arrowhead).



**Figure 8-11.** Fat embolus. The vessel in the center of this section has several well-defined clear spaces within the blood (arrowhead), which are fat emboli. As is evident from the photomicrograph, patients with fatty emboli have dyspnea as well as mental status changes and axillary petechial hemorrhages. Hematoxylin and eosin, 200×.

## INFARCTS

**Basic description:** A localized area of dead (necrotic) cells within an organ. An infarct is the pathologic finding; an infarction is the process.

**Mechanisms of infarct formation:** Hypoxia and ischemia are the two main mechanisms that result in infarction of organs. Hypoxia is lack of oxygen to an organ, and ischemia is lack of blood flow to an organ.

**Important point:** Ischemia is more damaging than hypoxia, since in ischemia, decreased blood flow results in both decreased oxygen delivery and decreased delivery of nutrients to the tissue and, in addition, there is no way to remove the toxic metabolites of cellular metabolism.

### Causes of infarcts

- **Obstruction of vessel:** Due to atherosclerosis, thrombi, emboli, damage to vasculature (e.g., trauma, neoplasms and cytomegalovirus infection), or external compression of an artery or vein (e.g., torsion of organ).
- **Generalized hypotension:** As occurs in forms of shock.

**Types of infarcts:** The two general types of infarcts are red and white infarcts.

#### 1. Red (“hemorrhagic”) infarct

**Organs affected:** Most red infarcts occur due to obstruction of an artery supplying an organ that has a dual blood supply or an organ that has loose parenchyma, such as the lung, which allows for leakage of blood into damaged tissue.

#### Other mechanisms that produce a red infarct

- **Venous infarcts:** Although the vein is obstructed, the artery is still delivering blood to the tissue, which gives the infarct a red appearance. However, even though some blood is being delivered to the tissue, oxygen delivery is impaired because of pooling of red blood cells.
- **Reperfusion:** In an infarct, the parenchyma and supporting structures of the organ (e.g., vessels, nerves) are damaged. When blood flow is returned to the organ, blood leaks out of damaged vessels, giving the infarct a red appearance.

#### Morphology of red infarct

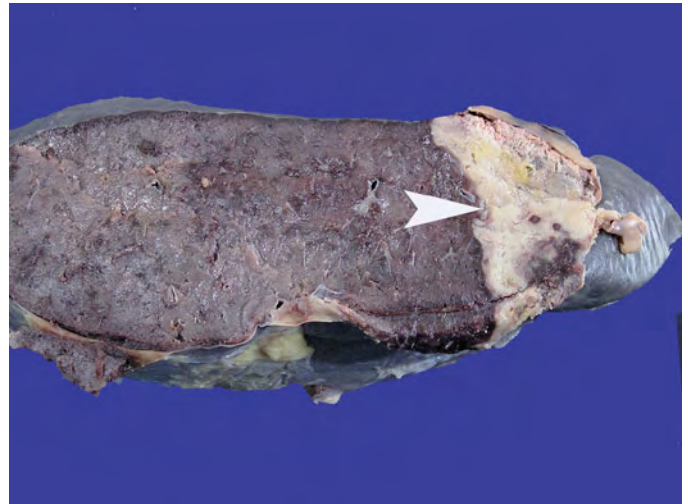
- **Gross:** Soft, red area of tissue (see Figure 8-10).
- **Microscopic:** Coagulative necrosis and numerous extravasated red blood cells.

#### 2. White (“anemic”) infarct

**Organs affected:** Organs with single blood supply and organs with solid parenchyma (e.g., heart, liver, spleen).

#### Morphology of white infarct

- **Gross:** Soft, pale area of tissue (Figure 8-12).
- **Microscopic:** Coagulative necrosis.



**Figure 8-12.** White splenic infarct. This spleen has a white (“anemic”) infarct (arrowhead). White infarcts often occur in solid organs with a single blood supply, such as the spleen.

**Complications of an infarct:** Variable, depending on location and size. As with hemorrhage, think of location of infarct. A 2.0-cm infarct of the liver might not be noticed, but a 2.0-cm infarct of the brainstem would most likely cause death.

## SHOCK

**Basic description:** Generalized hypoperfusion of the body (i.e., not enough blood is being circulated to supply the organs with the oxygen they require). The three main types of shock are cardiogenic, hypovolemic, and septic.

### CARDIOGENIC SHOCK

**Basic description:** Failure of the heart as a pump.

#### Examples of causes of cardiogenic shock

- A large myocardial infarct—damages so much myocardium that the heart cannot pump effectively.
- Acute mitral regurgitation—the heart is pumping enough blood, but much of it is leaking back into the left atrium instead of being propelled out into the aorta.

**Clinical presentation of cardiogenic shock:** As with other types of shock, cardiogenic shock is characterized by low blood pressure. However, depending on the underlying cause, the heart rate may be increased (e.g., in pulmonary embolism, cardiac tamponade) or decreased (e.g., in complete atrioventricular block). The skin is cool, jugular venous distention may be present, and there is poor perfusion to the vital organs.

### HYPOVOLEMIC SHOCK

**Basic description:** Lack of enough blood (due to loss) to properly perfuse the body—most commonly due to trauma.

#### Clinical presentation of hypovolemic shock

- If less than 20% of the body's total blood volume is lost: Cool and clammy skin with increased heart rate.
- If 20–40% of the body's total blood volume is lost: Increased respiratory rate, orthostasis, and possibly confusion.
- If more than 40% of the body's total blood volume is lost: Hypotension, oliguria, and obtundation.

**Important point regarding hypovolemic shock:** Preexisting heart disease may exacerbate the effects of hypovolemic shock.

### SEPTIC SHOCK

**Basic description:** Generalized vascular dilation caused by an infectious organism, usually due to lipopolysaccharides (LPS) in the cell wall of gram-negative bacterial organisms such as *Escherichia coli*, *Pseudomonas*, and *Klebsiella*. Blood pools in the venous system and peripheral vasculature and not enough returns to the heart to be pumped out.

**Incidence of septic shock:** 200,000 deaths annually (25–50% mortality rate); at-risk patients include diabetics and immunocompromised.



**Mechanism of septic shock:** Free LPS (released by degraded bacteria) binds to LPS-binding protein, which then binds to CD14 (on monocytes and macrophages), leading to activation of monocytes via the Toll-like receptor. The activation of macrophages results in increased levels of interleukin-1 (IL-1) and tumor necrosis factor (TNF) and eventually of IL-6 and IL-8. In a localized reaction, this mechanism is useful to the inflammatory reaction. However, in a more generalized reaction involving most if not all of the body, this mechanism is harmful and potentially lethal because it results in systemic vasodilation, diminished myocardial contractility, and widespread endothelial injury (leading to diffuse alveolar damage) and activation of the coagulation system (leading to DIC).

**Superantigens** (e.g., toxic shock syndrome toxin-1): Bacterial toxins, which, by themselves, induce septic shock by causing widespread nonspecific activation of T cells.

**Clinical presentation of septic shock:** Increased respiratory rate, increased heart rate, low blood pressure, fever, chills, oliguria, warm skin, and confusion.

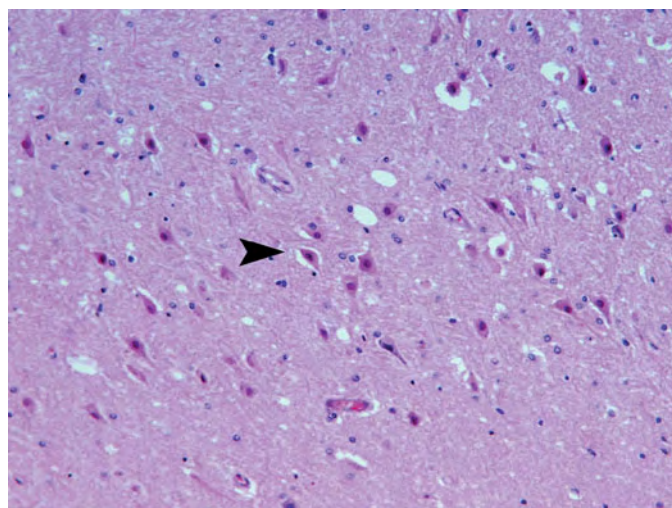
### ADDITIONAL TYPES OF SHOCK

**Neurogenic shock:** Defect in the central nervous system control of vascular tone results in generalized dilation of vessels and consequent pooling of blood.

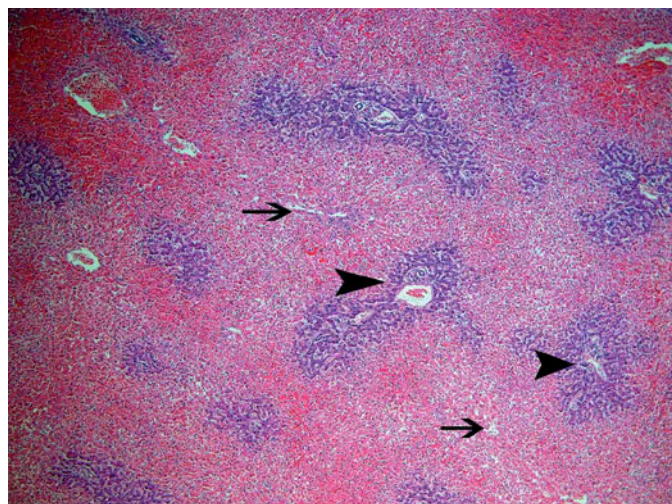
**Anaphylactic shock:** Due to a type I hypersensitivity reaction (see Chapter 3).

**Features and complications of shock:** Generalized hypoperfusion of organs leads to cell injury and death.

- In the brain: **Global hypoxic-ischemic encephalopathy** has the microscopic morphology of “red” neurons (i.e., dead neurons that have red cytoplasm and pyknotic nuclei) (Figure 8-13). Red neurons occur in areas most prone to ischemic injury. Such areas in the adult brain include the borderzone (the area between the distribution of two major cerebral arteries), hippocampus, and cerebellum.
- In the heart: **Subendocardial contraction band necrosis** has the microscopic morphology of cardiac myocytes traversed by darkly eosinophilic bands.
- In the lungs: **Diffuse alveolar damage** has the microscopic morphology of proteinaceous exudates in the alveoli and hyaline membranes (i.e., eosinophilic “membranes” composed of protein and cellular debris on the surface of the alveolar septae).
- In the liver: **Centrilobular necrosis** occurs because blood enters the portal tract through the hepatic artery and portal vein; thus, centrilobular hepatocytes are last to receive oxygenated blood and most prone to injury from shock. Centrilobular necrosis has the gross morphology of a nutmeg appearance, similar to the gross appearance of chronic passive congestion, and a microscopic morphology of coagulative necrosis of centrilobular hepatocytes (Figure 8-14).
- In the kidney: **Acute tubular necrosis** has the microscopic morphology of coagulative necrosis of tubular epithelial cells and dilation of tubules. It is commonly associated with the



**Figure 8-13.** Red neurons. This section of the hippocampus demonstrates “red” neurons (*arrowhead*). Indicative of ischemic injury, such as occurs in shock, these neurons have a shrunken pyknotic nucleus, an eosinophilic cytoplasm, and a rounded cellular outline. Hematoxylin and eosin, 200 $\times$ .



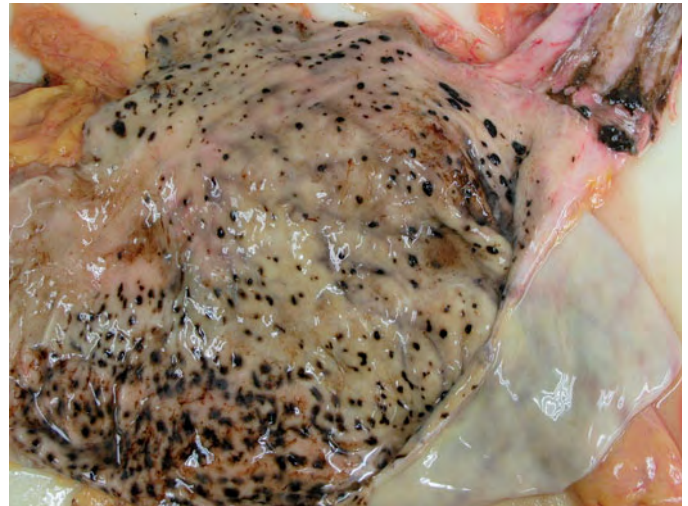**Figure 8-14.** Centrilobular necrosis. This section demonstrates the changes of centrilobular necrosis, preservation of hepatocytes around the portal tracts (*arrowheads*), and necrosis of hepatocytes around the central veins (*arrows*). The centrilobular hepatocytes are the last hepatocytes to receive oxygenated blood; thus, these cells are at most risk for injury following decreased perfusion of the liver, as occurs in shock. Hematoxylin and eosin, 40 $\times$ .

presence of nucleated cells in adjacent renal vessels (i.e., in the vasa recta).

- In the adrenal gland: **Corticomedullary hemorrhage.**
- In the gastrointestinal system: **Acute gastric petechial hemorrhages** and **ulcers** (Figure 8-15). Also, intestinal ischemia occurs at borderzone areas between the distribution of major vessels, commonly in the regions of the cecum and splenic flexure.

#### Stages of shock

- **Compensated:** Although the organs are hypoperfused, they are still able to maintain homeostasis without injury.
- **Progressive:** Organs can no longer maintain homeostasis, and organ damage begins to occur.
- **Irreversible:** Irreversible organ damage has occurred. Even if the source of the shock is corrected (e.g., a transfusion to correct blood loss secondary to trauma), the organs cannot repair themselves.



**Figure 8-15.** Shock-induced injury of the stomach. The stomach in this photograph has been opened, revealing the gastric mucosa. The gastroesophageal junction and distal esophagus are in the right upper corner. The innumerable punctate hemorrhages of the gastric mucosa (red-black spots) are due to shock.

*This page intentionally left blank*





## CHAPTER 9

# VASCULAR PATHOLOGY

### OVERVIEW

Vessels are the conduits by which blood is distributed to and from the organs. Obstruction or occlusion of vessels leads to ischemia of the organs, which causes cell death (necrosis). The most common cause of obstruction or occlusion of vessels is **arteriosclerosis** (“hardening of the arteries”).

Pressure within the vessels is determined by a combination of contraction of cardiac muscle and resistance created by the vessels themselves. Changes in this system (e.g., increased vascular resistance) can lead to hypertension, which can cause irreversible damage of the vessels. Examples of structural changes include narrowing of the lumen and dilations of vessels (i.e., aneurysms). Other disorders (e.g., vasculitis) as well as hypertension can cause vascular injury. This chapter will discuss arteriosclerosis and atherosclerosis, systemic hypertension, aortic dissection, pulmonary hypertension, aneurysms, vasculitis, and vascular proliferations.

### ARTERIOSCLEROSIS

**Overview:** Arteriosclerosis is also known as “hardening” or sclerosis of the arteries and occurs in three main forms, Mönckeberg medial calcification, arteriolosclerosis, and atherosclerosis.

**Mönckeberg medial calcification:** A condition of little clinical significance because the changes are nonstenotic. It is characterized by medial calcification (“pipestem rigidity”) of the muscular arteries (often radial and ulnar arteries) in elderly men.

**Arteriolosclerosis:** Thickening of arterioles (see the discussion below on systemic hypertension).

### ATHEROSCLEROSIS

#### Pathogenesis of atherosclerosis

1. Chronic endothelial cell injury by hyperlipidemia, hypertension, toxins in cigarette smoke, elevated levels of homocysteine, and hemodynamic forces (e.g., turbulent blood flow) leads to endothelial cell dysfunction.

2. Endothelial cells regulate vasodilation and constriction, promote hemostasis, and otherwise prevent thrombosis. Endothelial dysfunction promotes thrombosis and increased permeability as well as allows monocytes and lymphocytes to adhere to the surface and migrate into the intima.
3. Low-density lipoproteins (LDL) can move into and out of the intima; however, the presence of macrophages (derived from blood monocytes) results in production of enzymes that oxidize LDL. Oxidized LDL is engulfed by macrophages through scavenger receptors.
4. Finally, smooth muscle cells migrate into the intima: The smooth muscle cells convert from a contractile role in the media to a secretory role in the intima, where they produce extracellular matrix. Smooth muscle cells secrete extracellular matrix components (e.g., collagen) that contribute to the development of plaque. Smooth muscle cells, like macrophages, are capable of engulfing oxidized LDL.

#### Important points regarding atherosclerosis

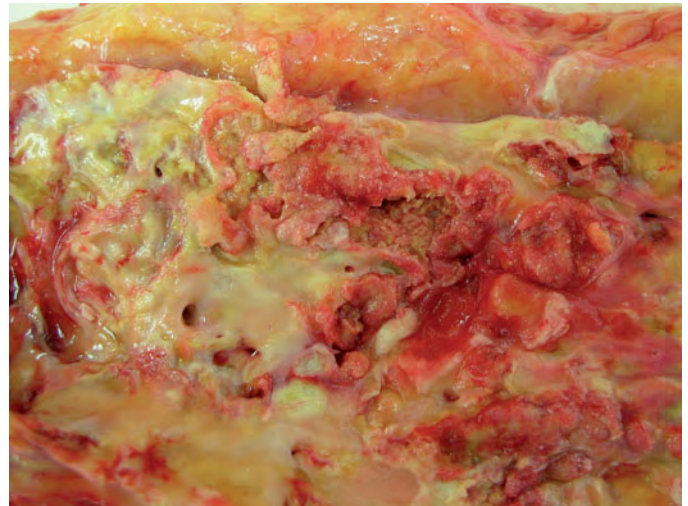
- Atherosclerosis begins as an intimal process; the changes in the media occur secondary to changes in the intima.
- Macrophages that engulf LDL die and release oxidized LDL, causing intracellular and extracellular lipid to accumulate within plaque.
- Elevated levels of high-density lipoproteins (HDL) are protective. HDL removes LDL from the wall of the vessel. Moderate alcohol consumption and exercise have been demonstrated to increase HDL levels.

#### Risk factors for atherosclerosis

- **Major and modifiable risk factors** (i.e., modifiable through changes in lifestyle): Smoking, diabetes mellitus, hypertension, and hyperlipidemia. The term “**metabolic syndrome**” describes a group of metabolic risk factors that includes insulin-resistance hyperlipidemia, hypertension, and abdominal obesity.
- **Major and nonmodifiable risk factors:** Male gender (after menopause, female risk for atherosclerosis is the same as that of males), advanced age, and family history, which is usually polygenic in origin.
- **Other risk factors:** *Chlamydia pneumoniae* infection, elevated levels of homocysteine, and elevated levels of lipoprotein-a ( $Lp_a$ ).  $Lp_a$  is similar in shape to plasminogen and thus interferes with the generation of plasmin, predisposing to thrombosis.

#### Vessels affected by atherosclerosis

- Elastic and medium-sized muscular arteries, most severely at ostia where laminar flow is disrupted. Laminar flow protects vessels from the development of atherosclerosis.
- In general, there is a descending order of prominence of vascular involvement: abdominal aorta (Figure 9-1), coronary arteries, popliteal arteries, internal carotid arteries, and circle of Willis. However, patients with severe coronary artery atherosclerosis can have a relatively disease-free aorta.



**Figure 9-1.** Aortic atherosclerosis. This close-up of the intimal surface of the longitudinally opened aorta reveals severe atherosclerosis. The roughened surface of the aorta is due to innumerable atherosclerotic plaques, which are hemorrhagic and friable. Within the blood stream, a portion of these friable plaques can break free and embolize farther down the vasculature, sometimes producing infarcts.



## COMPLICATIONS OF ATHEROSCLEROSIS

**Overview:** The first three complications listed below—occlusion of vessel, disruption of plaque, and emboli—can lead to ischemia and infarcts of organs. Aneurysms can lead to rupture of the vessel and resultant hemorrhage. Peripheral vascular disease is a specific condition with characteristic symptoms related to atherosclerosis of the arteries in the lower extremities.

1. **Occlusion of vessel:** Symptoms, signs, and results depend upon organ supplied.
2. **Disruption of plaque:** Hemorrhage within plaque or rupture or ulceration of plaque (with exposure of the thrombogenic components) can result in thrombus formation.
3. **Emboli:** Plaque can break free and be carried in the blood stream farther down the vessel.
4. **Aneurysm:** Atherosclerosis begins as an intimal process, but over time the thickened intima puts pressure on and causes atrophy of the media, often resulting in an aneurysm (i.e., dilation or saccular outpouching of the vessel).
5. **Peripheral vascular disease**
  - **Clinical presentation: Claudication**, which is characterized by ache or cramping in the extremities with exertion that is relieved by standing still. Patients also have cool extremities, diminished distal pulses, and shiny, hairless skin. Patients with severe peripheral vascular disease have pain at rest. Ischemic ulcerations are a common cause of morbidity.
  - **Cause:** Atherosclerosis of vessels of the lower extremities.

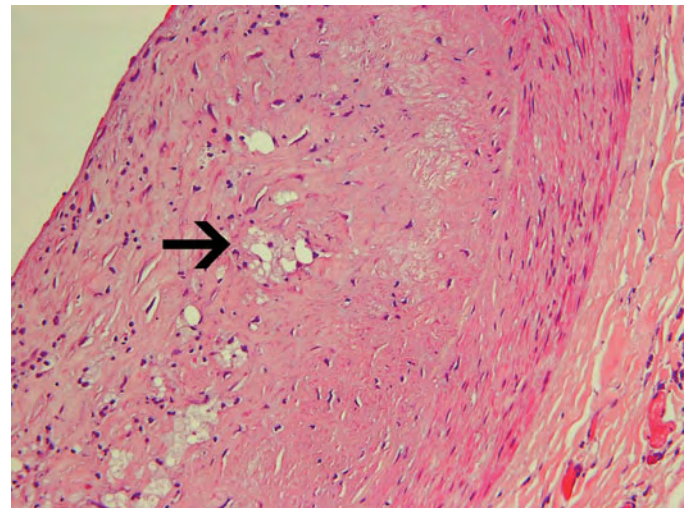
## MORPHOLOGY OF ATHEROSCLEROSIS

**General morphology:** Grossly recognizable atherosclerosis begins as a fatty streak and progresses to a fibroatheroma.

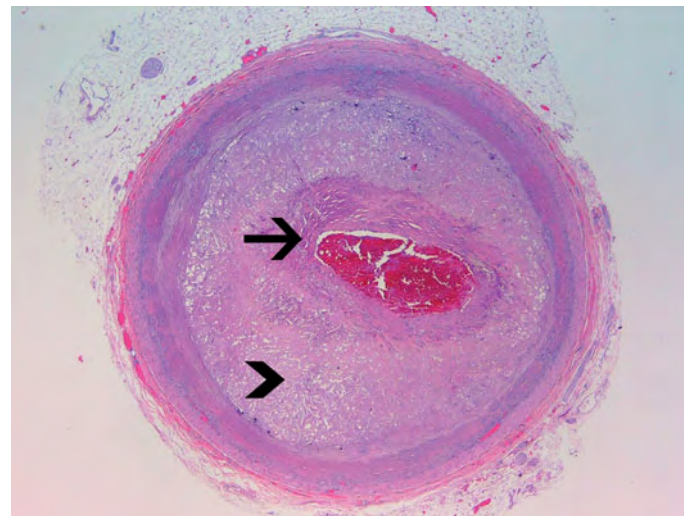
- **Fatty streak:** Intimal accumulation of foam cells (Figure 9-2).
- **Atheroma:** Intimal accumulation of foam cells and extracellular lipid.
- **Fibroatheroma:** Atheroma with development of a fibrous cap.

**Microscopic morphology of a fibroatheroma:** There are three main components of a fibroatheroma (Figure 9-3).

1. **Fibrous cap:** A thick fibrous cap is more stable and less likely to develop complications (e.g., hemorrhage or rupture). The fibrous cap is composed of smooth muscle cells and extracellular matrix (e.g., collagen).
2. **Atheromatous core:** Contains extracellular lipid, macrophages with intracellular lipid, and necrotic tissue.
3. **Shoulder of plaque:** Has macrophages, leukocytes, and blood vessels.



**Figure 9-2.** Atherosclerosis, fatty streak. The intima of this vessel has a few collections of lipid-laden macrophages and some collections of extracellular lipid (arrow). Hematoxylin and eosin, 200 $\times$ .



**Figure 9-3.** Atherosclerosis, coronary artery. The cross-section of this coronary artery reveals a large atherosclerotic plaque with a thin fibrous cap (arrow) and thick atheromatous core (arrowhead). Currently, the plaque is producing more than 75% stenosis of the lumen of the vessel and most likely resultant ischemia of tissue downstream from the obstruction. Also, atherosclerotic plaques with a thin fibrous cap are prone to rupture, with potential resultant thrombus formation. Hematoxylin and eosin, 20 $\times$ .



## SYSTEMIC HYPERTENSION

**Basic description:** Elevated systemic blood pressure (systolic pressure  $\geq 140$  mm Hg or diastolic pressure  $\geq 90$  mm Hg).

**Epidemiology:** Hypertension occurs in 15–30% of adults. The incidence increases with age (60% of people older than age 65 have hypertension). It is more common in males and in African Americans.

**Types of systemic hypertension:** Hypertension may be primary (essential), with no underlying cause, or secondary, with an underlying cause. In addition, hypertension can be classified as benign or malignant, depending upon its clinical course and symptoms.

**Primary (essential) hypertension:** Hypertension not associated with an underlying disease. It represents 90–95% of cases of systemic hypertension.

**Secondary hypertension:** Hypertension due to another disease process. Causes of secondary hypertension are usually renal, endocrine, cardiac, neurologic, or stress-induced in origin (Table 9-1).

■ **Renal causes:** Often due to activation of the renin-angiotensin-aldosterone system and can be parenchymal and vascular in origin. Renal parenchymal causes include chronic renal failure, acute glomerulonephritis, and renin-producing tumors. Renal vascular causes include renal artery stenosis caused by atherosclerosis or another process (e.g., fibrous dysplasia).

■ **Endocrine causes:** Cushing syndrome, Conn syndrome (aldosterone-secreting tumor), acromegaly, pheochromocytoma, hyperthyroidism, and hypothyroidism.

■ **Cardiovascular causes:** Coarctation of the aorta, polyarteritis nodosa, increased intravascular volume, and increased cardiac output.

■ **Neurologic causes:** Increased intracranial pressure, sleep apnea, acute stress, and brain tumors.

■ **Stress-induced causes:** Pain, anxiety, and hypoglycemia.

**TABLE 9-1.** Secondary Causes of Hypertension

Source of Cause of Hypertension by Organ System	Specific Causes
Renal	Chronic renal failure, acute glomerulonephritis, and renal artery stenosis due to atherosclerosis or fibrous dysplasia
Endocrine	Both Cushing and Conn syndromes, acromegaly, pheochromocytoma, hyperthyroidism, and hypothyroidism
Cardiovascular	Coarctation of the aorta, polyarteritis nodosa
Neurologic	Increased intracranial pressure, sleep apnea, brain tumors

**Idiopathic (“benign”) hypertension:** Has a slow clinical course. Patients can survive with the disease for 10–20 years or more. Note, that despite the designation of “benign,” all forms of hypertension are associated with increased morbidity and mortality.

**Malignant hypertension:** Has a rapid clinical course. Death occurs within 1 to 3 years. Patients have retinal hemorrhage, papilledema, and renal failure. Malignant hypertension can arise in the background of “benign” hypertension, or it can arise *de novo*.

#### Classification of hypertension occurring during pregnancy

- **Chronic hypertension:** Defined as hypertension present prior to 20 weeks’ gestation.
- **Gestational hypertension:** Defined as hypertension occurring after 20 weeks’ gestation, which resolves within 2 weeks of termination of the pregnancy.
- **Preeclampsia (toxemia):** Hypertension occurring during the second half of gestation in association with significant ( $> 300$  mg/24 h) proteinuria. Edema is common but is no longer considered a diagnostic criterion. Hyperuricemia is frequently present.
- **Severe preeclampsia:** Meets the diagnostic criteria for preeclampsia, plus patients have evidence of end-organ dysfunction. Signs and symptoms of severe preeclampsia include oliguria, severe headache, abdominal pain, elevated liver enzymes, thrombocytopenia, and pulmonary and cerebral edema.
- **Eclampsia:** Meets the diagnostic criteria for severe preeclampsia; also, patients have seizures.
- **HELLP syndrome:** Form of severe preeclampsia characterized by hemolysis, elevated liver enzymes, and low platelet count (thrombocytopenia).

#### Pathogenesis of hypertension

- **Primary hypertension:** The pathogenesis of primary (essential) hypertension is complex and the result of many factors. The two main components determining blood pressure are cardiac output and total peripheral resistance. Total peripheral resistance is a balance between vasoconstricting forces (including angiotensin II and catecholamines) and vasodilating forces (including prostaglandins and nitric oxide). Many other factors play a role in primary hypertension, including low pH and hypoxia in certain organs (e.g., kidney).
- **Secondary hypertension:** The pathogenesis is usually more straightforward than in essential hypertension. For example, if the patient has a pheochromocytoma (tumor of the adrenal medulla), the hypertension results from the elevated level of catecholamines. In renal artery stenosis, hypertension results from the elevated level of renin produced by the kidney because of a perceived low volume state, with an ultimate increase in angiotensin II and aldosterone.

#### Complications of hypertension

- **Atherosclerosis:** Hypertension is one of the four major modifiable risk factors.

- **Cardiac hypertrophy:** Predisposes to sudden death and congestive heart failure. Hypertrophy is a compensatory mechanism, but compensation may ultimately be inadequate to sustain effective cardiac output, resulting in congestive heart failure.
- **Intracerebral hemorrhage:** Often centered on basal ganglia or thalamus.
- **Arteriosclerosis:** Can lead to organ ischemia and most commonly to renal failure.
- **Aortic dissection:** (see discussion of aortic dissection below).
- **Retinopathy.**

#### Morphology of hypertension

- **Gross:** Enlarged heart due to concentric hypertrophy.
- **Microscopic**
  - **Hyaline arteriolosclerosis:** Associated with benign hypertension. It is eosinophilic, acellular thickening of the wall of arterioles (Figure 9-4).
  - **Hyperplastic arteriolosclerosis:** Associated with malignant hypertension. It is a concentric, cellular thickening (i.e., onion-skinning) of the wall associated with fibrinoid necrosis (Figure 9-5).

### AORTIC DISSECTION

**Basic description:** Separation of the aortic media by blood entering the wall through an intimal tear (Figure 9-6).

#### Types of aortic dissection

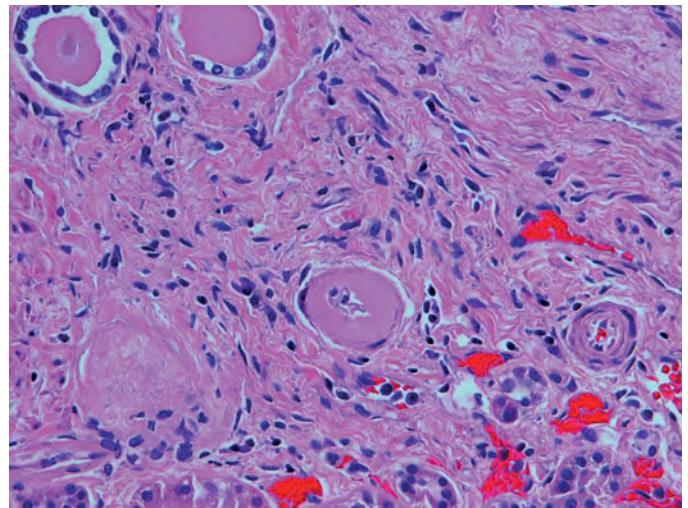
- Types I and II (also called type A): Involve the aortic arch and are the most severe type of dissection because of their ability to cause a hemopericardium or acute aortic insufficiency.
- Type III (also called type B): Involve the distal aorta.

#### Risk factors for an aortic dissection

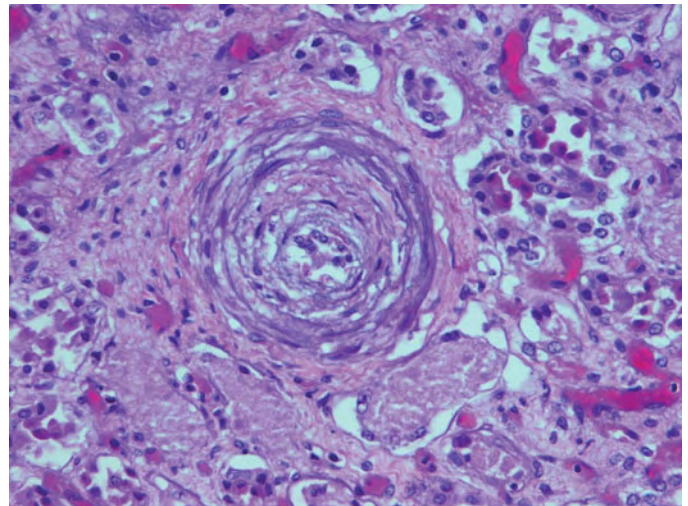
- **Hypertension:** Most aortic dissections are due to systemic hypertension.
- **Connective tissue disorders:** Most commonly Marfan syndrome.

**Complications of an aortic dissection:** Once the blood dissects into the aortic media through a tear in the intima, it may produce a second tear in another location, or the hematoma may secondarily involve another structure.

- **If the second tear is in the intima in another location:** Results in a “double-barrel” aorta, the most benign complication of an aortic dissection.
- **If the second tear is in the pericardial sac:** Results in hemopericardium and possible cardiac tamponade.
- **With involvement of the aortic valve ring:** Disrupts stability of the valve, leading to aortic insufficiency (Figure 9-7).
- **If the second tear is into the pleural cavity:** Results in hemothorax.



**Figure 9-4.** Hyaline arteriolosclerosis. The vessel in the center of this photomicrograph has a wall that is thick, acellular, and eosinophilic (hyaline). This histologic change is characteristic of benign hypertension. The histologic changes in the vessel wall are secondary to the accumulation of plasma proteins. Similar histologic changes (due to a different mechanism) can be seen in patients with diabetes mellitus. Hematoxylin and eosin, 400×.



**Figure 9-5.** Hyperplastic arteriolosclerosis. The vessel in the center of this photomicrograph has a wall that is thickened by concentric, cellular layers. This histologic change is characteristic of malignant hypertension. Hematoxylin and eosin, 400×.



- **If the second tear is into the retroperitoneum:** Results in retroperitoneal hemorrhage.
- **With involvement of the coronary arteries:** As blood dissects through the media, branch vessels can be compressed or the vessels themselves may dissect, resulting in infarction of the downstream organ.

### Morphology of an aortic dissection

- **Gross:** Separation of media by a layer of blood.
- **Microscopic**
  - Hemorrhage in the wall.
  - In hypertension and Marfan syndrome, the aorta may undergo cystic medial degeneration, in which the elastic fibers in the wall become separated by acellular myxoid material (Figure 9-8). Cystic medial degeneration is most commonly seen in patients with Marfan syndrome.

### Clinical presentation of an aortic dissection

- **Symptoms:** Patients describe severe, sharp, “tearing” pain that radiates to the back (interscapular area).
- **Signs:** Asymmetrical pulses; murmur, if aortic insufficiency is present.

## PULMONARY HYPERTENSION

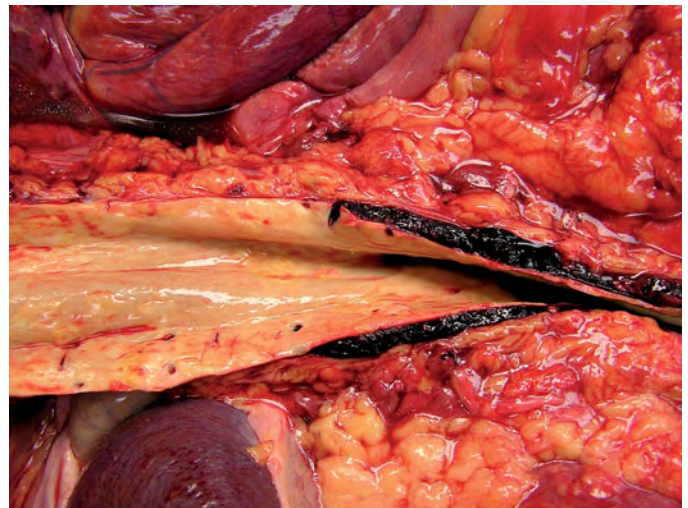**Basic description:** Elevated pulmonary arterial pressure (normal is 15–30 mm Hg).

### Mechanisms of pulmonary hypertension and their specific causes

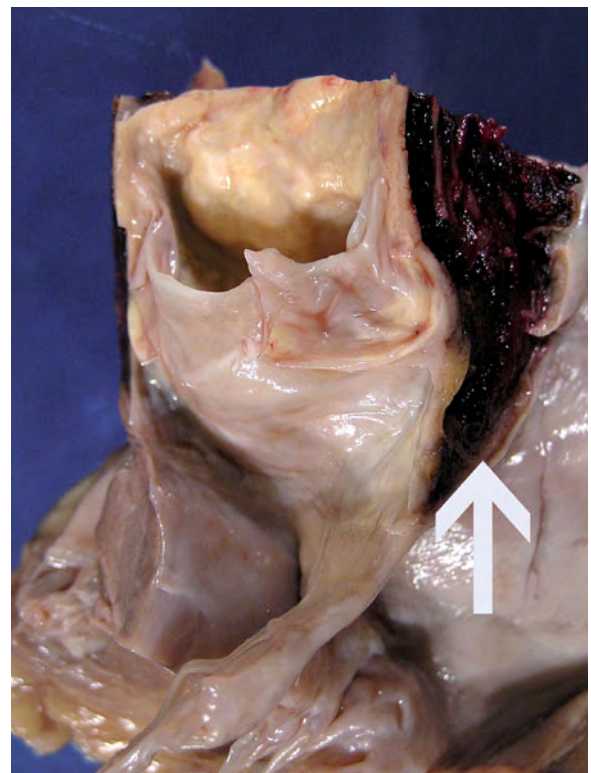
- Increased pulmonary flow as occurs in atrial and ventricular septal defects or a patent ductus arteriosus.
- Elevated pulmonary venous pressure as occurs in left ventricular failure or mitral stenosis or regurgitation.
- Chronic pulmonary vasoconstriction in reaction to hypoxia, which is commonly seen in chronic obstructive pulmonary disease and obstructive sleep apnea.
- Abnormalities of the pulmonary arteries, including pulmonary embolic disease and parenchymal lung disease (fibrosis).

### Primary pulmonary hypertension

- **Basic description:** Pulmonary hypertension that occurs in a patient with no identifiable risk factors for its development.
- **Epidemiology:** Third or fourth decades; female predominance.
- **Pathogenesis of primary pulmonary hypertension:** Most cases are sporadic, but 5% are familial and associated with a mutation in bone morphogenetic protein receptor type 2 (BMPR2). BMPR2 inhibits proliferation of vascular smooth muscle and promotes apoptosis; therefore, an absence of this protein receptor can lead to proliferation of vascular smooth muscle.



**Figure 9-6.** Aortic dissection. The wall of this aorta is split by a hematoma, representing an aortic dissection.



**Figure 9-7.** Aortic dissection involving the aortic valve. This dissection has extended proximally, to the aortic valve (arrow). The dissection disrupts the stability of the valve, producing aortic insufficiency.

### Microscopic morphology of pulmonary hypertension

- Grade 1: Medial hypertrophy.
- Grade 2: Intimal and medial hypertrophy.
- Grade 3: “Pipestem” fibrosis of arteries.
- Grade 4: Plexiform lesions.
- Grade 5: Fibrinoid necrosis.

**Clinical presentation of pulmonary hypertension:** Exertional dyspnea (60% of patients) and weakness (19% of patients), cyanosis, digital clubbing, jugular venous distention, and chest pain. Pulmonary hypertension of grades I–III is potentially reversible.

## ANEURYSMS

**Basic description of a true aneurysm:** Dilation of the wall of a blood vessel involving all layers. The three types of true aneurysms are saccular, fusiform, and mycotic.

### Types of true aneurysms

- **Saccular aneurysm:** Saccular outpouching from one side of the affected vessel.
- **Fusiform aneurysm:** Generalized dilation of the entire circumference of the affected vessel.
- **Mycotic aneurysm:** An aneurysm that occurs as the result of an infection from septic emboli or an aneurysm that has subsequently become infected. A mycotic abdominal aortic aneurysm is commonly due to *Salmonella* infection from gastroenteritis.

**Basic description of a false aneurysm (i.e., pseudoaneurysm):** A defect in the wall allows blood to escape the vessel or organ (e.g., the heart) and accumulate outside the wall. If the extravasated blood is contained, it appears like a saccular dilation but it is not. False aneurysms can result from trauma or rupture of a vessel.

## PATHOGENESIS OF AN ANEURYSM

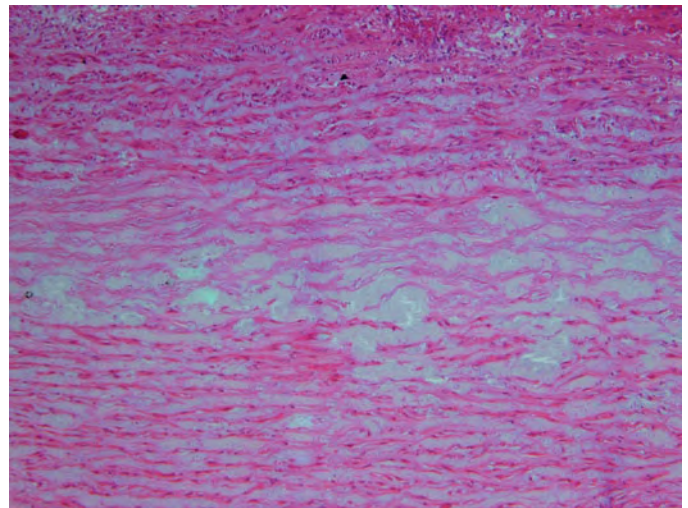
Aneurysms can have several etiologies, including atherosclerosis, cystic medial degeneration, and tertiary syphilis.

- The primary intimal changes of atherosclerosis weaken the media and can result in an aneurysm. Atherosclerosis is the most common cause of aneurysms, and such aneurysms most commonly occur in the abdominal aorta (Figure 9-9). Atherosclerosis also causes thoracic aortic aneurysms and aneurysms of other vessels. Contributing factors are matrix metalloproteinases that are secreted by macrophages and contribute to damage of the wall. Aneurysms have a decreased level of tissue inhibitors of metalloproteinases (TIMP).

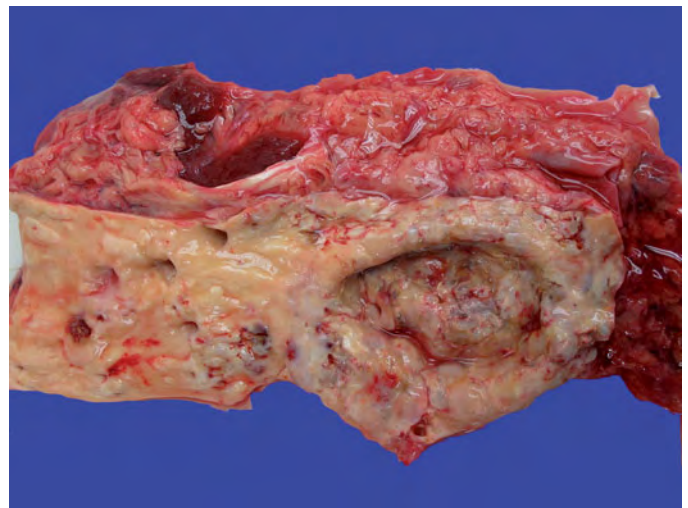
- Cystic medial degeneration can lead to true aneurysms as well as to the previously described aortic dissection.

### Luetic aortic aneurysm of tertiary syphilis

**Mechanism:** Syphilis causes obliterative endarteritis of the vasa vasorum, which results in ischemia of the vessel’s media. The ischemia of the media leads to scarring and loss of elastic recoil, so the vessel dilates.



**Figure 9-8.** Cystic medial degeneration. The acellular, myxoid (blue) material dividing the collagen fibers in the media of this aorta is cystic medial degeneration. Cystic medial degeneration is commonly seen in patients with Marfan syndrome, but can be seen in the aorta of patients with hypertension. The changes produced by cystic medial degeneration may predispose individuals to develop an aortic dissection. Hematoxylin and eosin, 100×.



**Figure 9-9.** Abdominal aortic aneurysm. This photograph of an aorta opened longitudinally (proximal end at left side of image, and distal end at right side of image) illustrates an aortic aneurysm, just distal to the ostia of the renal arteries.

**Location:** Thoracic aorta (aortic root and arch).

#### Complications of syphilitic aortitis

- Aortic insufficiency as a result of dilation of the aortic valve annulus, which can cause congestive heart failure.
- Compression of the lungs and airways, causing respiratory difficulties.
- Compression of the esophagus, causing dysphagia.
- Compression of the recurrent laryngeal nerve, causing cough.
- Rupture: Not common; the wall is scarred, and scars do not tear easily.

#### Morphology of syphilitic aortitis

- **Gross:** “Tree-barking” of the intima is a result of irregular scarring of the media, causing contraction of intima.
- **Microscopic: Obliterative endarteritis** is obliteration of the vasa vasorum by intimal changes and scarring. The wall of the vessel has a variably dense plasma cell infiltrate.

■ **Others causes of aneurysms:** Congenital weakness of the wall (e.g., berry aneurysms), trauma.

#### Complications of aneurysms

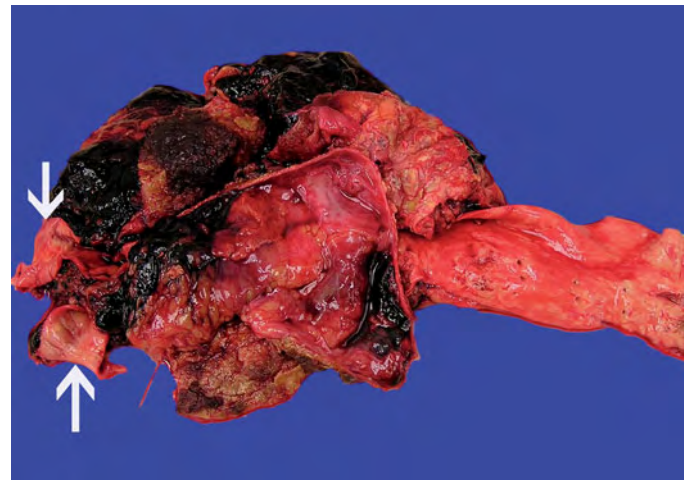
- Emboli from atherosclerotic plaques that form within the aneurysm.
- Thrombosis: Aneurysm allows for stagnation of blood and formation of thrombi, with or without resultant emboli.
- Rupture of aneurysm with resultant hemorrhage (Figure 9-10).
- Obstruction of branch vessels.
- Impingement on neighboring structures.

**Gross morphology of aneurysms:** Outpouching of the vessel wall (i.e., saccular), or generalized dilation of the vessel wall (i.e., fusiform).

**Clinical presentation of aneurysm:** Presentation as a pulsatile mass. Abdominal aortic aneurysms may be palpated by physical examination.

#### Clinical presentation of ruptured aneurysm

- **Triad:** Abdominal pain, hypotension, and pulsatile abdominal mass.
- **Important point:** Abdominal aortic aneurysms larger than 5 cm have a greatly increased risk of rupture (10% per year). Abdominal aneurysms larger than 4.0 cm and thoracic aneurysms larger than 6.0 cm should be considered for repair.



**Figure 9-10.** Ruptured abdominal aortic aneurysm. This photograph shows an aorta with a large (> 6.0 cm) abdominal aortic aneurysm. The proximal aorta is located at the right side of the image and has been opened longitudinally. The arrows indicate the left and right iliac arteries (also opened longitudinally). The aneurysm has been previously opened for examination and folded closed for the photograph. The hemorrhage in the retroperitoneal tissue, which resulted from the rupture of the aneurysm, is easily identifiable.

## ARTERIOVENOUS FISTULA

**Basic description:** Abnormal connection between an artery and a vein.

**Pathogenesis:** Can be developmental and can develop after trauma.

**Complications:** High-output cardiac failure; rupture with hemorrhage.



## VASCULITIS

**Overview:** Vasculitis is inflammation of the vessels, which most commonly has an infectious or immune-mediated cause. Infectious causes of vasculitis include *Neisseria*, *Rickettsiae*, and syphilis. Immune-mediated vasculitis occurs due to one of three mechanisms include immune-complex deposition, ANCA-mediated, or direct antibody interaction, and will be discussed below. In many cases, the pathogenesis of vasculitis is unknown, but most likely it is an immune-mediated mechanism.

### IMMUNE COMPLEX DEPOSITION–MEDIATED VASCULITIS

**Mechanism:** Antibodies induced by the disease process bind antigens. This interaction forms a complex that deposits within the vessel wall. The immune complex causes vasculitis through activation of complement.

**Diseases associated with immune complex deposition–mediated vasculitis:** Patients with hepatitis B and hepatitis C infections and systemic lupus erythematosus can develop an immune complex deposition–mediated vasculitis. Drug-induced vasculitis, which often involves the skin, is due to immune-complex deposition.

### ANCA-MEDIATED VASCULITIS

**Basic description:** ANCAs are antineutrophil cytoplasmic antibodies.

**Mechanism:** Unknown for certain; however, one possible explanation is that ANCAs cause degranulation of neutrophils. The degranulation of the neutrophils releases substances that have toxic effects on vessels and surrounding tissue.

#### Two types of ANCA

- **c-ANCA:** Antibody against PR-3.
- **p-ANCA:** Antibody against myeloperoxidase.

**Disease associations:** Patients with Wegener granulomatosis can have c-ANCA. Patients with microscopic polyarteritis and Churg-Strauss syndrome can have p-ANCA.

### DIRECT ANTIBODY INTERACTION–MEDIATED VASCULITIS

**Mechanism:** Antibodies bind directly to the antigens in the target organ.

**Disease associations:** Goodpasture syndrome, which is caused by antibodies to the glomerular basement membrane, and Kawasaki syndrome, which has antiendothelial antibodies.

## MAJOR VASCULITIDES (TABLE 9-2)

**Overview:** The major forms of vasculitis, which will be discussed below, are giant cell arteritis, Takayasu arteritis, polyarteritis nodosa, Wegener granulomatosis, Buerger disease, Kawasaki disease, microscopic polyarteritis, and Churg-Strauss syndrome.

**TABLE 9-2.** Important Points Regarding Specific Vasculitides

Disorder	Vessels Affected	Important Points
Giant cell arteritis	Branches of carotid artery and aorta	Affects females >50 years of age; causes headaches; diagnosis determined with biopsy; treatment is steroid therapy
Takayasu arteritis	Aorta	Affects females <50 years of age; causes weak pulses in upper extremities
Polyarteritis nodosa	Small and medium-sized arteries; spares pulmonary arteries	Histologic lesions are temporally heterogeneous; patients present with multitude of symptoms
Wegener granulomatosis	Small vessels	Classic clinical triad of chronic sinusitis, pneumonitis, and renal disease; patients are positive for c-ANCA
Kawasaki disease	Coronary arteries	Causes coronary artery aneurysms
Buerger disease	Small and medium-sized arteries	Associated with tobacco use; patients develop ulcers of fingers and toes

### GIANT CELL ARTERITIS (TEMPORAL ARTERITIS)

**Vessels affected:** Aorta and branches of the carotid arteries (ophthalmic, temporal).

**Complications:** Thoracic aortic aneurysms.

**Epidemiology:** Women older than 50 years of age.

**Microscopic morphology:** Granulomatous inflammation of vessel wall with disruption of elastic lamellae (Figure 9-11).

**Clinical presentation of giant cell arteritis:** Includes visual disturbances (e.g., diplopia and visual loss) and unilateral temporal headache and jaw claudication. Patients can have an elevated erythrocyte sedimentation rate.

**Diagnosis:** Definitive diagnosis requires biopsy.

**Treatment of giant cell arteritis:** Steroid therapy.

### TAKAYASU ARTERITIS

**Vessels affected:** Aorta, branch vessels to upper extremities, and pulmonary arteries. The condition is also called “pulseless disease.”

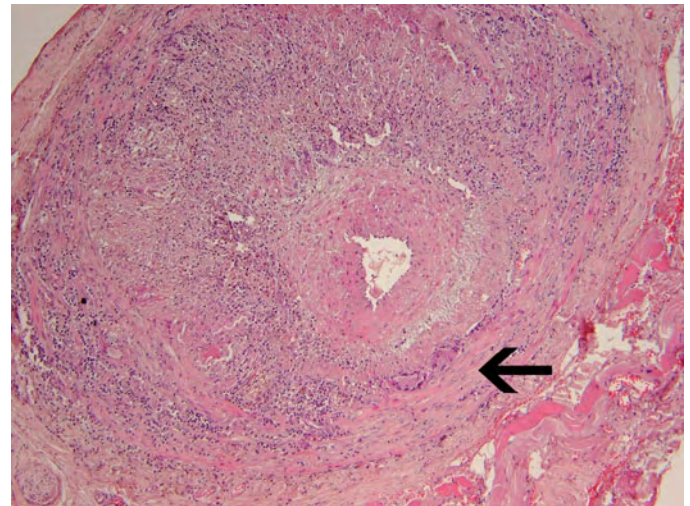
**Complications:** Thoracic aortic aneurysms.

**Epidemiology:** Women younger than 50 years of age; Asians.

#### Morphology of Takayasu arteritis

■ **Gross:** Vessel wall with near occlusion of lumen by thick intima.

■ **Microscopic:** Varies from a mononuclear inflammatory infiltrate to granulomatous inflammation. Intimal proliferation and fibrosis is present.



**Figure 9-11.** Temporal arteritis. This temporal artery has a wall that is thickened by an inflammatory infiltrate. The inflammatory infiltrate includes giant cell formation (arrow). Hematoxylin and eosin, 200×.

**Clinical presentation of Takayasu arteritis:** Weak pulses in upper extremities; arthralgias, myalgias, night sweats, visual disturbances, and fever. Patients can have an elevated erythrocyte sedimentation rate.

**Important point:** Because giant cell arteritis and Takayasu arteritis can have similar microscopic and gross features, the diagnosis is based largely upon epidemiology. Some texts use the term giant cell arteritis to designate both temporal arteritis and Takayasu arteritis, with the two conditions separated by epidemiology and symptoms (Figure 9-12).

### POLYARTERITIS NODOSA

**Vessels affected:** Small or medium-sized muscular arteries. Polyarteritis nodosa does not involve the smaller vessels (i.e., venules, capillaries, or arterioles) or pulmonary arteries. Commonly involved vessels are the renal and visceral arteries.

**Epidemiology:** Usually young adults.

**Important point:** About 30% of cases are associated with hepatitis B infection. Polyarteritis nodosa is also associated with hepatitis C infection.

#### Morphology of polyarteritis nodosa

- **Microscopic:** Transmural inflammation of vessels in combination with fibrinoid necrosis (i.e., smudgy, pink degeneration of wall), which leads to scarring (Figure 9-13).
- **Important point:** Patients have lesions in various stages (i.e., some inflammation, some scarring); in other words, the lesions are of different ages (referred to as **temporally heterogeneous**).

#### Clinical presentation of polyarteritis nodosa

- Polyarteritis nodosa presents a challenging clinical diagnosis since a multitude of symptoms are possible. Hypertension and abdominal pain are common. Arthritis and myalgias are present in more than 60% of cases.
- Polyarteritis nodosa is not associated with glomerulonephritis; however, renal artery involvement is usually prominent and often the cause of death.
- There is no association with ANCA.

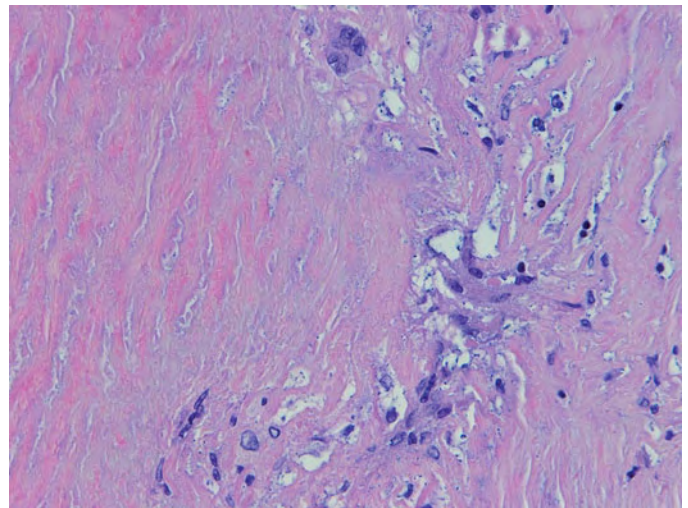
### WEGENER GRANULOMATOSIS

**Vessels affected:** Small vessels in upper and lower respiratory tract and kidney.

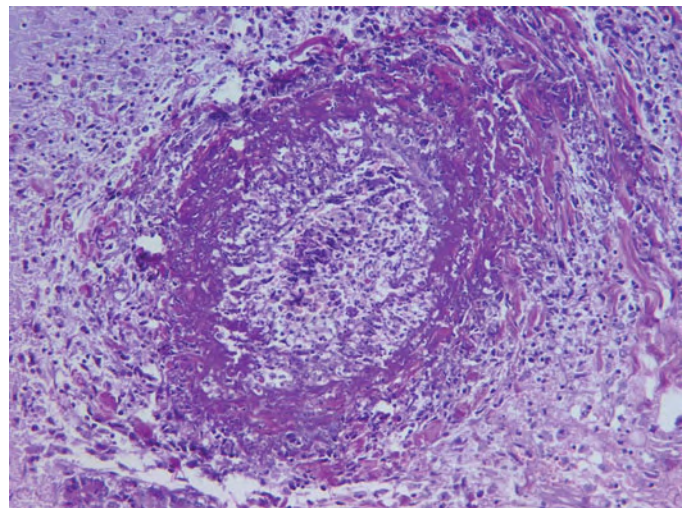
**Microscopic morphology:** Granulomatous inflammation.

#### Clinical presentation of Wegener granulomatosis

- Acute necrotizing granulomas of the upper and lower respiratory tract, causing chronic sinusitis.
- Necrotizing and granulomatous vasculitis of organs: Most prominently involve the lungs, forming nodules and infiltrates and causing pneumonitis.
- Focal necrotizing or crescentic glomerulonephritis, causing renal disease.



**Figure 9-12.** Giant cell aortitis. This patient had a thoracic aortic aneurysm. Histologic examination of the aneurysm revealed fibrosis (left side of image) and giant cell formation. Both temporal arteritis and Takayasu arteritis can affect the aorta, producing similar histologic changes. The separation of the two disorders, when only the aorta is involved, is based primarily upon age of the patient. Hematoxylin and eosin, 400 $\times$ .



**Figure 9-13.** Polyarteritis nodosa. Note the prominent fibrinoid necrosis (smudgy eosinophilic changes) of the wall of this vessel and the accompanying inflammatory infiltrate. Polyarteritis nodosa can affect many different medium-sized vessels (with the exception of the pulmonary vasculature) and, thus, patients can present with a wide variety of signs and symptoms. Hematoxylin and eosin, 200 $\times$ .



**Important point regarding Wegener granulomatosis:** In addition to the above described classic clinical triad, Wegener granulomatosis is also associated with c-ANCA.

### **BUERGER DISEASE (THROMBOANGIITIS OBLITERANS)**

**Vessels affected:** Small and medium-sized arteries, most commonly radial and tibial arteries.

**Epidemiology:** More common in Israel, India, and Japan than in the United States. Almost completely limited to cigarette smokers.

**Pathogenesis of Buerger disease:** Unknown, but possibly due to the direct toxic effects of tobacco on vessels or a hypersensitivity reaction to the tobacco products. Increased prevalence of HLA-A9 and HLA-B5 is identified in patients with Buerger disease.

**Microscopic morphology:** Segmental acute and chronic vasculitis; can have thrombosis of the lumen; thrombus can contain microabscesses.

**Complications of Buerger disease:** Ulcers of toes, feet, or fingers.

**Clinical presentation:** Severe pain with activity or rest, most likely due to neural involvement and digital ulceration.

### **KAWASAKI DISEASE (MUCOCUTANEOUS LYMPH NODE SYNDROME)**

**Vessels affected:** Most important is involvement of the coronary arteries.

**Complications of Kawasaki disease:** Includes aneurysms of the coronary arteries and myocardial infarction. These are late complications occurring many years after acute disease.

**Microscopic morphology:** Similar to polyarteritis nodosa but with less prominent fibrinoid necrosis.

**Clinical presentation of acute disease:** Kawasaki disease classically presents in children younger than 5 years of age who present with a high fever (up to 40°C, or 104°F) for more than 5 days; with conjunctivitis, strawberry tongue, cervical lymphadenopathy; and with peeling erythematous rash of lips, palms, and soles of feet.

### **MICROSCOPIC POLYARTERITIS**

**Vessels affected:** Smaller vessels than those that are affected by polyarteritis nodosa.

**Organs involved:** Skin, kidney (causing glomerulonephritis), and lungs (causing pulmonary capillaritis).

**Microscopic morphology of microscopic polyarteritis:** Temporally homogeneous lesions.

**Clinical presentation:** Associated with p-ANCA.

### CHURG-STRAUSS SYNDROME

**Vessels affected:** Small to medium-sized arteries.

**Microscopic morphology:** Granulomatous vasculitis.

**Clinical presentation:** Asthma, eosinophilia, and pulmonary infiltrates.

## VASCULAR TUMORS

**Overview:** Vascular proliferations range from the benign hemangioma, to Kaposi sarcoma and other tumors of borderline malignancy, to angiosarcoma, which is a highly malignant and aggressive neoplasm.

### HEMANGIOMA

**Basic description:** Benign proliferation of blood vessels.

#### Complications

- Usually none—many hemangiomas that occur in childhood completely or nearly completely regress.
- Hemangiomas can sequester platelets, which results in thrombocytopenia (called **Kasabach-Merritt syndrome**).
- Hemorrhage due to rupture of tumor.

**Microscopic morphology:** Two types, capillary and cavernous.

1. **Capillary:** Small, back to back, capillary-like vessels.
  - **Outcome:** Tend to regress.
  - **Age:** More common in children.
  - **Portion of body affected:** Skin and subcutaneous tissues.
2. **Cavernous:** Large, blood-filled spaces.
  - **Outcome:** Do not tend to regress.
  - **Age:** More common in adults.
  - **Portion of body affected:** Deeper structures (e.g., liver).

### KAPOSI SARCOMA

**Basic description:** Malignant tumor of blood vessels.

#### Four variants of Kaposi sarcoma

1. Classic variant occurs in men of Mediterranean descent, is low grade, and affects the arms and legs.
2. Kaposi sarcoma variant occurs in patients who are HIV positive.
3. Lymphadenopathic variant occurs in Africa.
4. Kaposi sarcoma variant is associated with transplantation.

**Pathogenesis:** Kaposi sarcoma is associated with infection with human herpes virus 8 (HHV-8), which, in developed countries, is thought to be primarily sexually transmitted.

**Morphology of Kaposi sarcoma**

- **Gross:** Patches progress to raised plaques, which progress to nodules.
- **Microscopic:** Spindled cells; extravasated red blood cells.

**ANGIOSARCOMA**

**Basic description:** High-grade malignant tumor of the blood vessels.

**Risk factors for development of angiosarcoma**

- In hepatic angiosarcoma: Polyvinyl chloride use; exposure to arsenic and Thorotrast.
- Radiation.
- Lymphedema: Most commonly after axillary tail dissection in patients with breast cancer.

**MISCELLANEOUS VASCULAR CONDITIONS****RAYNAUD DISEASE (PRIMARY RAYNAUD PHENOMENON)**

**Basic description:** Pallor and cyanosis of the digits due to cold-induced vasoconstriction.

**Epidemiology:** Young adult females.

**Complications of Raynaud disease:** None; the disease is usually benign.

**RAYNAUD PHENOMENON (SECONDARY RAYNAUD DISEASE)**

**Basic description:** Pallor and cyanosis of the digits due to cold-induced vasospasm.

**Epidemiology:** Older males.

**Disease associations:** Systemic lupus erythematosus, Sjögren syndrome, atherosclerosis.

**Complications of Raynaud phenomenon:** Ulcers, gangrene.



*This page intentionally left blank*

# CHAPTER 10

## CARDIAC PATHOLOGY

### OVERVIEW

Diseases of the heart fit into several general categories: congenital heart disease, ischemic heart disease, valvular diseases, and diseases of the myocardium (i.e., cardiomyopathies). Pericardial diseases and cardiac tumors are an additional small subset of conditions affecting the heart. A common manifestation of many different forms of heart disease is **congestive heart failure** (CHF). In general terms, congestive heart failure is the inability of the heart to pump enough blood to supply the body's oxygen requirements. It can represent failure of cellular adaptation (e.g., decompensated hypertrophy due to hypertension or chamber dilation due to regurgitant valves) or the outcome of myocardial damage caused by other diseases (e.g., scarring due to ischemic injury, inflammation, or accumulation of iron in hemochromatosis).

Classic symptoms of heart disease are chest pain or discomfort, **dyspnea** (including **orthopnea** and **paroxysmal nocturnal dyspnea**), palpitations, syncope, and edema. Dyspnea is an uncomfortable awareness of breathing. Orthopnea is dyspnea when in the recumbent position due to increased venous return and increased pulmonary venous pressure. Patients with orthopnea sleep upright on pillows to avoid becoming short of breath. Paroxysmal nocturnal dyspnea is when patients awaken with dyspnea 2–4 hours after falling asleep (due to central redistribution of peripheral edema).

An understanding of heart sounds is important in the clinical evaluation of heart disease. The  $S_1$  sound is caused by closing of the mitral and tricuspid valves, and the  $S_2$  sound is caused by closing of the aortic and pulmonary valves. In a patient with hypertension (systemic or pulmonary), closing of the associated valve (aortic or pulmonic) is accentuated (louder); in a patient with stenosis, the closing is diminished in strength (softer sound).  $S_2$  is physiologically split during inspiration (aortic,  $A_2$ , first and pulmonic,  $P_2$  second)—increased venous return to the right side of the heart delays closure of the pulmonic valve and decreased return to the left side speeds closure of the aortic valve. Wide splitting of  $S_2$  is caused by a greater than normal delay in pulmonic closure (e.g., right bundle branch block, pulmonic stenosis) or earlier aortic valve closure due to decreased left ventricular volume (e.g., mitral regurgitation, ventricular septal defect). Paradoxical splitting ( $P_2$  first and  $A_2$  second) occurs with delayed closure of the aortic valve

(e.g., left bundle branch block, aortic stenosis). A pathologic  $S_3$  occurs with ventricular systolic dysfunction during the rapid filling phase of diastole or from impact of the left ventricle against the chest wall. It is particularly common in the setting of CHF.  $S_4$  is from ejection of blood from the atrium into a non-compliant ventricle, as might be encountered in the setting of ventricular hypertrophy related to systemic hypertension, or in the setting of an acute myocardial infarct.

This chapter will discuss congenital heart disease, ischemic heart disease, hypertensive cardiovascular disease, congestive heart failure, valvular heart disease, cardiomyopathies, myocarditis, pericardial disease, and cardiac tumors.

## CONGENITAL HEART DISEASE

**Overview:** There are three main categories of congenital heart disease: conditions causing a right-to-left shunt; conditions causing a left-to-right shunt; and conditions causing obstruction. In a **right-to-left shunt**, deoxygenated blood from the right side of the heart goes to the left side; thus, deoxygenated blood is delivered to the body. This type of shunt usually results in cyanosis at the time of birth. A **left-to-right shunt** increases the amount of blood delivered to the right side of the heart and will result in hypertrophy and dilation of the right atrium or right ventricle (or both), depending upon the type of shunt. Eventually, the pressure in the right side of the heart increases and surpasses that in the left side of the heart, resulting in a reversal of the shunt from left-to-right to a right-to-left shunt. This change is called **Eisenmenger syndrome**. With **obstruction**, an abnormally formed valve or vessel leads to pressure overload of the involved atrium or ventricle.

### RIGHT-TO-LEFT SHUNT

#### Causes of right-to-left shunt

1. Tetralogy of Fallot

#### Morphology of tetralogy of Fallot

- Pulmonary stenosis.
- Right ventricular hypertrophy (as a result of the pulmonary stenosis).
- A ventricular septal defect shunts blood to the left side of the heart.
- The aorta overrides the ventricular septal defect.

**Important points:** Tetralogy of Fallot is the most common cause of a right-to-left shunt in newborns.

**Complications of tetralogy of Fallot:** Erythrocytosis, **paradoxical emboli** (through ventricular septal defect), endocarditis, and ventricular arrhythmias.

**Clinical presentation of tetralogy of Fallot:** Cyanosis and failure to thrive; patients squat to alleviate symptoms by increasing venous return. The classic pattern seen on chest radiograph is the boot-shaped heart. Patients often have paroxysms of cyanosis (“tet fits”) associated with states of increased cardiac output that increase right-to-left shunting such as crying, exercise, and hot baths.

2. **Tricuspid atresia:** The **gross morphology** of tricuspid atresia is an atretic tricuspid valve that obstructs the flow of blood



from the right atrium to the right ventricle. A ventricular septal defect or atrial septal defect is usually present. Approximately 75% of infants with tricuspid atresia are cyanotic within the first week of life.

3. **Truncus arteriosus:** The **gross morphology** of truncus arteriosus is caused by abnormal development of the ventricular outflow tracts, resulting in the presence of a common arterial conduit that receives a mixture of blood from the left and right ventricles. These patients present with symptoms initially due to left-to-right shunting, and they become cyanotic within 3 to 4 months because of progressive pulmonary vascular resistance.
4. **Totally anomalous pulmonary venous return:** The **gross morphology** is that the pulmonary veins do not return to the left atrium as normal, but rather drain abnormally into a left innominate vein or coronary sinus. Pulmonary venous blood ultimately reaches the left atrium through an atrial septal defect or patent foramen ovale.
5. **Transposition of the great vessels:** The **gross morphology** is that the aorta arises from the right ventricle and the pulmonary trunk arises from the left ventricle, producing two completely separate circuits. One circuit is the right ventricle → body → right atrium, and the other is the left ventricle → lungs → left atrium. Transposition of the great vessels must be combined with a ventricular septal defect, patent ductus arteriosus, or patent foramen ovale, which the patient needs to mix blood for any survival period to be possible after delivery.

### LEFT-TO-RIGHT SHUNT

#### Causes of left-to-right shunt

##### 1. Ventricular septal defect (VSD)

**Gross morphology:** Defect in the interventricular septum. Most VSDs are in the membranous septum (90%). Many close spontaneously, and particularly those limited to the muscular septum (Figures 10-1 and 10-2).

**Incidence:** VSD is present in 30–60% of all patients with a congenital heart defect, making it the most common congenital heart defect and the most common cause of a left-to-right shunt.

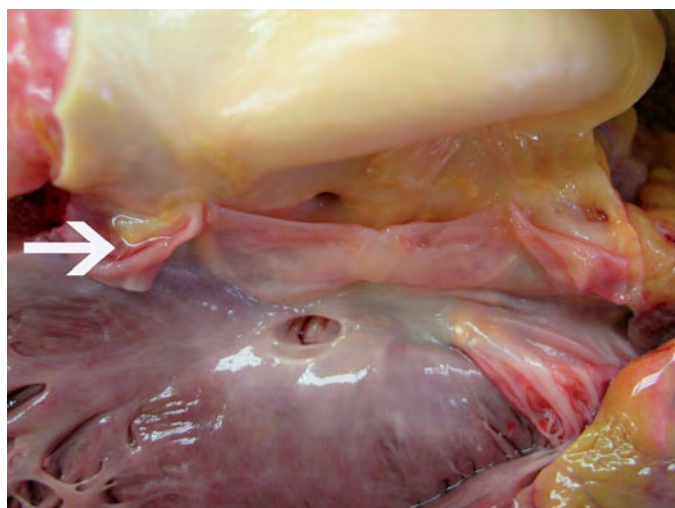
#### Complications of VSDs

- Endocarditis
- Left-to-right shunt with increased flow of blood to the right ventricle, leading to hypertrophy and dilation and eventually to Eisenmenger syndrome (see above).
- **Paradoxical embolus:** An embolus passes into the right ventricle and then into the left ventricle through the VSD. From the left ventricle, the embolus travels via the aorta to the systemic arteries.

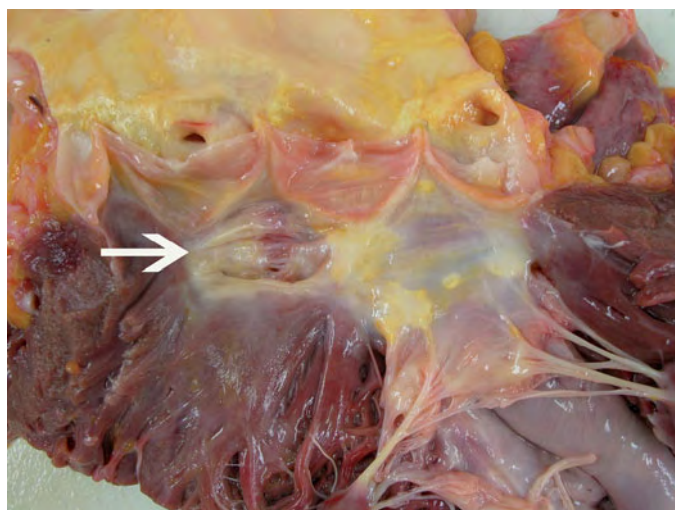
**Clinical presentation of VSD:** Wide physiologic splitting of S<sub>2</sub> and holosystolic murmur. Spontaneous closure of VSD occurs in up to 50% of patients.

##### 2. Atrial septal defect (ASD)

**Gross morphology:** Defect in the interatrial septum.



**Figure 10-1.** Ventricular septal defect and bicuspid aortic valve. The ventricular septal defect is in the membranous septum. The bicuspid aortic valve has one large cusp (above the membranous ventricular septal defect) with a midline raphe and a smaller cusp. During dissection, the smaller cusp was divided (arrow). Courtesy of Dr. Sheila Spotswood, Dallas County Medical Examiner's Office, Dallas, TX.



**Figure 10-2.** Healed ventricular septal defect. This patient had a membranous ventricular septal defect, which, like most, spontaneously closed. In this case, closure was due to the anterior leaflet of the tricuspid valve adhering to the region of the defect. This view shows the closed ventricular septal defect from the aortic aspect (arrow).

### Three types of ASDs based upon location

- At the fossa ovalis (secundum-type): Most common (Figure 10-3).
- Below the fossa ovalis (primum-type): Second most common.
- Near the superior vena cava (sinus venosus type): Rare.

**Incidence:** Second most common cause of left-to-right shunt. Up to 50% of all patients with congenital heart defects have an ASD.

### Complications of ASDs

- Left-to-right shunt with increased flow of blood to the right atrium. Secondary pulmonary hypertension is less common than with VSDs because of the low pressure flow of the left-to-right shunt.
- Paradoxical embolus.
- Endocarditis.

**Clinical presentation of ASDs:** Widely split and fixed S<sub>2</sub> because of increased venous pressure and delayed closure of pulmonic valve.

### 3. Patent ductus arteriosus (PDA)

**Gross morphology:** Retention of the patency of the duct between the aorta and pulmonary trunk. The ductus arteriosus, along with the foramen ovale, shunts blood around the lungs in the fetus because the lungs are not needed to oxygenate the blood during fetal development.

### Clinical presentation of PDA

- In the normal neonate, spontaneous closure of the ductus arteriosus in response to an increase in PaO<sub>2</sub> associated with breathing normally occurs within the first 12 hours of life.
- The classic sign of a persistent PDA is a continuous “machine-like” murmur.
- Use of prostaglandin E will keep the shunt open. Use of indomethacin will close a PDA.

### 4. Atrioventricular septal defect

#### Types of atrioventricular septal defects

- **Partial:** Primum atrial septal defect combined with cleft mitral valve.
- **Complete:** Common atrioventricular canal.

**Important point:** Associated with Down syndrome.

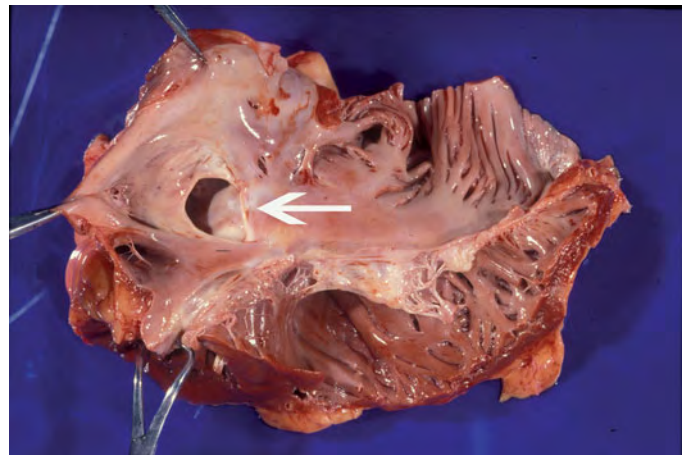
## OBSTRUCTION

### Causes of obstruction as pathophysiologic mechanism of congenital heart disease

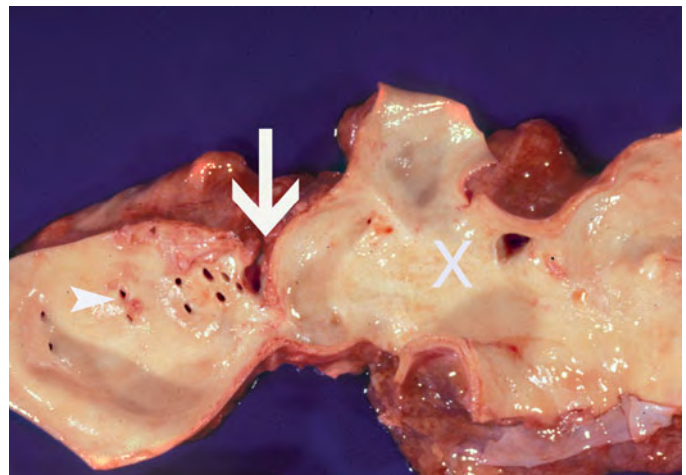
1. Aortic stenosis
2. Pulmonary stenosis
3. **Coarctation of the aorta** (Figure 10-4)

**Types of aortic coarctation** (based upon location in relationship to the ligamentum arteriosum)

- **Preductal:** Present with symptoms early; identified in infancy.
- **Postductal:** Present with symptoms later; identified in early adulthood.



**Figure 10-3.** Atrial septal defect, secundum-type. This 32-year-old patient had an undiagnosed secundum-type atrial septal defect (arrow). The right atrium is also dilated, as would be expected in a patient with a long-standing unrepaired atrial septal defect (from increased blood flow to the right side of the heart).



**Figure 10-4.** Coarctation of the aorta. This 40-year-old man had an undiagnosed coarctation of the aorta (arrow). For orientation, the arrowheads indicate ostia of the intercostal arteries, and the large white X marks the site of the aortic arch. Associated with this coarctation was a true bicuspid valve (i.e., two cusps of equal size). The patient also had cardiac hypertrophy caused by pressure overload induced by the coarctation of the aorta.

- The presence or absence of a PDA is also important in the classification of a coarctation of the aorta.

#### Conditions associated with coarctation of the aorta

- About 25% of patients with coarctation of the aorta have a bicuspid aortic valve.
- Intracranial saccular (berry) aneurysms.
- Coarctation of the aorta is present in up to one third of patients with Turner syndrome.

#### Clinical presentation of coarctation of the aorta

- In coarctation of the aorta associated with a PDA, patients have cyanosis at birth, usually of the lower half of the body.
- In coarctation of the aorta without an associated PDA, patients present with systemic hypertension with lower blood pressure in the arms than in the legs. Notching of ribs is seen on chest radiograph; the notching is caused by dilated collateral vessels supplying the lower part of the body.

## ISCHEMIC HEART DISEASE

**Overview:** The term **ischemic heart disease** refers to inadequate perfusion of the myocardium, most commonly due to atherosclerosis of the coronary arteries. Ischemia causes functional disturbances of the heart, including (1) impaired relaxation, which occurs first, causing diastolic dysfunction; (2) impaired contraction, which occurs second, causing systolic dysfunction; (3) myocardial stunning, a prolonged (hours to days) but reversible dysfunction after an acute ischemic event; and (4) myocardial hibernation, which occurs when oxygenation is adequate to maintain viability of the myocardium but cannot support normal function. If the ischemia lasts long enough, death of myocardial cells ensues.

Clinically, decreased blood flow to the myocardium causes chest pain (**angina**). The nature of the obstruction to blood flow determines the disease type and outcome. A fixed obstruction (70% or greater stenosis) will cause ischemia of the myocardium when the demand for oxygen is increased (such as during exercise), but at rest, flow is adequate (therefore there is no pain when the patient is at rest). Chest pain due to a fixed obstruction is called stable angina.

Myocardial necrosis does not occur during classic episodes of stable angina. In a patient with coronary atherosclerosis, changes in the coronary artery plaque morphology, such as rupture or hemorrhage, may occur suddenly and may cause acute myocardial ischemia; if prolonged, such acute ischemic episodes may cause necrosis (**myocardial infarction**). **Unstable angina, non-STEMI** (non-ST elevation myocardial infarct), and **STEMI** are clinical terms that designate, in increasing order of severity, possible consequences of a change in the plaque morphology, depending upon the length of obstruction. The signs of myocardial ischemia include ST depression on the electrocardiogram (ECG) and an  $S_4$  on physical examination, with the  $S_4$  due to decreased ventricular compliance.



### CLINICAL SYNDROMES ASSOCIATED WITH ISCHEMIC HEART DISEASE

**Overview:** The four clinical syndromes are stable angina, unstable angina, variant angina, and myocardial infarct, the first three of which will be described below. Unstable angina and myocardial infarcts (both non-STEMI and STEMI) can be further subdivided as acute coronary syndromes, which will be described after this section.

#### 1. Stable angina

**Basic description:** Chest pain due to fixed obstruction of the coronary arteries. The chest pain occurs predictably with exercise and ceases with rest.

**Mechanism of stable angina:** Stable angina is produced by a fixed plaque causing stenosis of 70% or more of the vessel lumen (Figures 10-5 and 10-6). At rest, the heart can get a sufficient amount of blood around a site with this degree of stenosis to supply the heart (there is no ischemia; therefore, there is no chest pain). With exercise, myocardial oxygen requirements increase, but the heart cannot pump enough blood past the blockage to meet the metabolic demands of the myocytes. The myocytes become ischemic and chest pain occurs. With increased myocardial oxygen requirements, normal coronary vessels dilate. Atherosclerotic vessels are unable to dilate appropriately in this setting, however. With cessation of exercise, myocardial needs decrease and ischemia stops. The symptoms are consistent (i.e., a set amount of exercise triggers the chest pain in a predictable fashion).

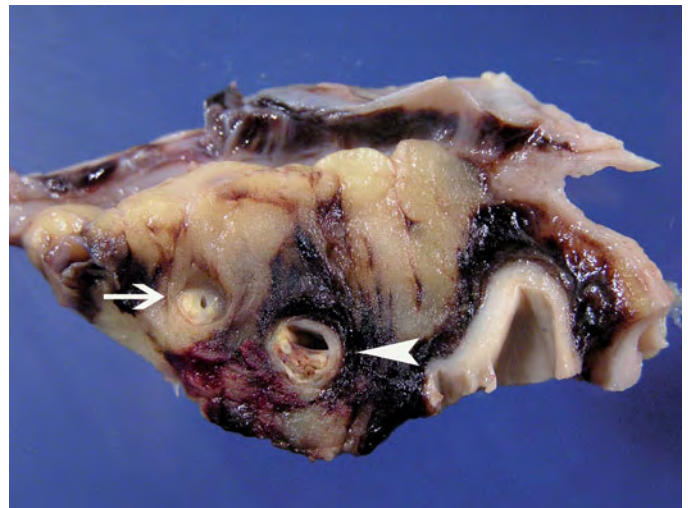
#### Clinical presentation of stable angina

- **Description of pain:** The chest pain is described as squeezing or pressure, such as a heavy weight.
- **Location:** Retrosternal; commonly mistaken for “indigestion.”
- **Radiation of pain:** To the neck, epigastrium, jaw, and ulnar aspect of the left arm.
- **Duration of pain:** Less than 2 to 10 minutes.
- **Context:** Triggered by stress, either physical or emotional. Generally alleviated by rest or nitroglycerin.
- **Other symptoms occurring along with chest pain:** Nausea and vomiting, diaphoresis, shortness of breath, and fatigue. In older patients and diabetics, shortness of breath may be the only symptom of angina.


#### 2. Unstable angina

**Basic description:** Chest pain that falls into one of several patterns; namely, chest pain that is more severe, prolonged, or frequent in a patient with previous stable angina (“crescendo” angina); chest pain occurring at rest or with minimal exertion; or chest pain of new onset associated with minimal exertion.

**General mechanism of unstable angina:** Unstable angina is produced by a change in the plaque. Usually the change is acute



**Figure 10-5.** Atherosclerosis seen in a cross-section of the proximal left anterior descending coronary removed from the heart. This patient has mild to moderate atherosclerosis of the coronary arteries. The vessel at the arrowhead is about 50–60% stenotic. This patient would not be expected to have chest pain associated with this lesion. The vessel at the tip of the arrow is about 75–85% stenotic. This patient would be expected to have stable angina associated with this lesion.



**Figure 10-6.** Atherosclerosis of the coronary artery. The sections at the arrows have mild to moderate atherosclerosis, with approximately 55–70% stenosis of the lumen. These changes would not likely cause chest pain. The vessel at the arrowhead has severe stenosis due to atherosclerosis (90–95%), with only a slit-like vessel lumen remaining. This patient would be expected to have, at the least, stable angina.

(Figure 10-7), although a stable plaque causing 90% or greater stenosis could cause angina when at rest. In unstable angina, acute changes in plaque morphology abruptly deprive the myocytes of sufficient oxygen and ischemia occurs. Unstable angina has also been called **preinfarction angina**, because this form of chest pain is often a prelude to a myocardial infarct. Ischemia leads to infarction if the precipitating event is not corrected.

**Specific mechanisms of plaque change:** Atherosclerotic plaques with a fairly thin fibrous cap are more likely to develop acute changes than those with a thick fibrous cap. Acute plaque change can be due to hemorrhage into the plaque, rupture of the plaque, or erosion or ulceration of the plaque.

■ **Hemorrhage** into the plaque: Plaques have blood vessels. Hemorrhage can lead to an increase in the size of the plaque, with resultant increased stenosis of the vessel, or the hemorrhage can lead to rupture of the fibrous cap and intraluminal thrombus formation.

■ **Rupture** of the plaque with resultant intraluminal mural thrombus.

■ **Erosion** or ulcer: The fibrous cap can erode or ulcerate. This change results in hemorrhage and sometimes exposure of the atheromatous core, which can result in intraluminal thrombus formation.

**Cellular basis of plaque disruption:** Cells die, releasing lipid. Activated macrophages and mast cells release metalloproteinase enzymes, which break down matrix proteins. T lymphocytes in the plaque produce cytokines, which block production of collagen. Other factors, such as mechanical and hemodynamic stresses, may also contribute to plaque disruption.

**Clinical presentation of unstable angina:** Characteristic symptoms of unstable angina are the same as stable angina, but duration may be longer and chest pain occurs with rest or increasing frequency. (Refer to the basic description and mechanism of unstable angina.) *All new onset cases of angina are considered to be unstable angina until proven otherwise.*

### 3. Variant angina

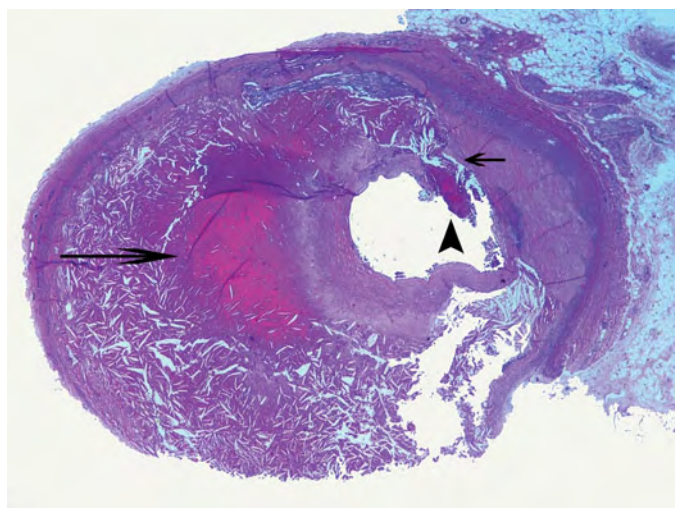
**Basic description:** Angina occurring unpredictably with rest. There are two forms: **Prinzmetal angina** and **pure vasospastic angina**.

■ **Prinzmetal angina:** Dynamic (vasospastic) angina that occurs at the site of an existing atherosclerotic plaque. It often occurs at rest, and may be triggered by use of  $\beta$  blockers or hyperventilation. Unlike classic angina, which is associated with ST depression, Prinzmetal angina is characterized by a profound ST elevation, although progression to myocardial infarction is rare. Prinzmetal angina usually responds to nitrates or calcium channel blockers.

■ **Pure vasospastic angina:** Associated with normal coronary arteries (i.e., no atherosclerosis).

**Mechanism of variant angina:** Coronary artery vasospasm.

**Complications of variant angina:** Can cause ischemia and, therefore, precipitate ventricular arrhythmias and sudden cardiac death. Uncommonly, myocardial infarcts may occur.



**Figure 10-7.** Intraplaque hemorrhage with resultant rupture of plaque and thrombus formation. This patient had a hemorrhage within an atherosclerotic plaque (*long arrow*) that has caused rupture of the thin fibrous cap (*short arrow*) and thrombus formation (*arrowhead*). This patient would be expected to have unstable angina (because of the recent change in the plaque), which may progress to frank myocardial infarction, depending upon the degree and duration of occlusion. Hematoxylin and eosin, 40 $\times$ .

## ACUTE CORONARY SYNDROMES

**Types:** Unstable angina, NSTEMI, and STEMI.

**Mechanism:** Rupture of unstable atherosclerotic plaque (or similar sudden change) associated with vasospasm and thrombus formation.

### Differentiation of acute coronary syndromes

- If blood flow is restored within 20 minutes, no necrosis occurs: this is **unstable angina**.
- If the blood flow is not restored within 20–40 minutes, necrosis can occur: this is an **acute myocardial infarct**.

## MYOCARDIAL INFARCTS

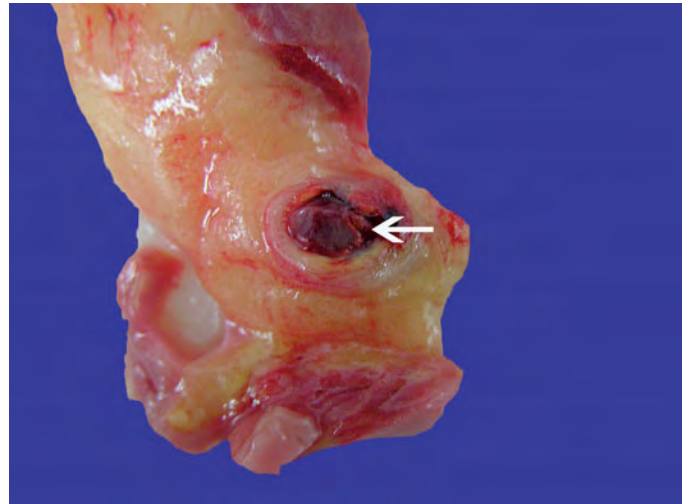
**Basic description:** Death of a segment of myocardium due to prolonged ischemia, usually due to obstruction of a coronary artery.

### Two types of myocardial infarcts

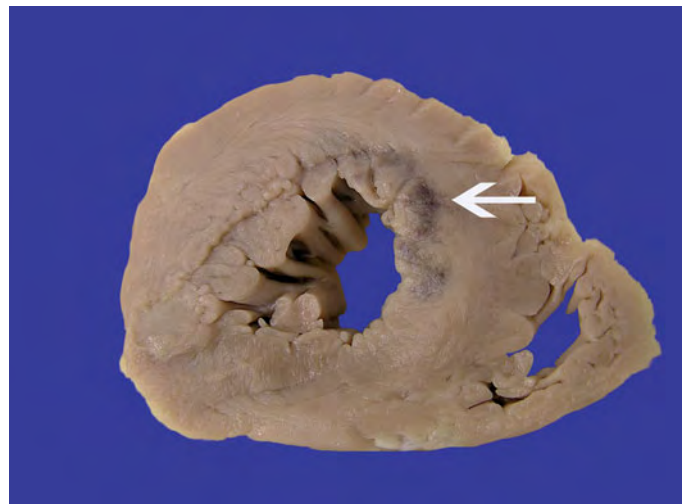
- **STEMI** (previously called **transmural** or **Q wave infarct**): The full thickness of the wall of the ventricle is affected. The mechanism of an STEMI infarct is complete occlusion of the coronary artery (100% stenosis with no blood flow) for more than 2–4 hours, which is the length of time required for all the myocytes throughout the entire thickness of the wall to die (Figure 10-8).
- **NSTEMI** (previously called **subendocardial** or **non-Q wave infarct**): The full thickness of the wall is not affected; only the subendocardial myocytes are affected (Figure 10-9). The mechanism of NSTEMIs is deprivation of the wall of the ventricle of oxygen for enough time to cause necrosis, but not enough time to cause full thickness necrosis. Since the last myocytes to receive blood are those nearest the endocardium and because blood comes into the wall from the epicardial surface, subendocardial myocytes are the most prone to injury from decreased blood flow. NSTEMIs of this region (i.e., subendocardial in location) almost always result from one of three conditions.
  1. Complete occlusion of the vessel by a thrombus, which lyses prior to full development of a transmural infarct (i.e., the thrombus breaks up before 2 hours).
  2. A sudden change in the plaque occurs, which significantly narrows the lumen but does not completely occlude it. For example, if stenosis rapidly goes from 50% to 90%.
  3. Generalized poor perfusion of the heart because of shock.

### Clinical diagnosis of unstable angina and NSTEMI infarct

- **ECG changes:** Both cause ST depression; Q waves *do not* develop.
- **Cardiac enzyme testing:** Unstable angina *does not* cause an elevation in cardiac enzymes (see clinical diagnosis of STEMI infarct). NSTEMI infarcts do cause an elevation in cardiac enzymes.
- **Clinical presentation:** Symptoms include retrosternal, substernal, or epigastric chest discomfort, which can radiate to



**Figure 10-8.** Minimal coronary artery atherosclerosis with acute thrombus. This patient had mild coronary artery atherosclerosis. The thin rim of yellow is the plaque, which causes no more than 10% stenosis of the lumen of the vessel. Yet, despite its small size, the plaque ruptured and an occlusive thrombus formed (*arrow*). The patient most likely will develop an ST elevation myocardial infarct (STEMI), with full thickness involvement of the myocardium in the area supplied by the vessel.



**Figure 10-9.** Non-ST elevation myocardial infarct (NSTEMI) with reperfusion. This patient had a subendocardial infarct in the anteroseptal wall of the left ventricle (*arrow*). The hemorrhage is from reperfusion.



the arm. This chest discomfort is often associated with dyspnea, nausea, and/or diaphoresis.

### Important points

- Unstable angina and NSTEMI can present with similar clinical and ECG findings. Enzyme testing will distinguish the two (see clinical diagnosis of STEMI infarct).
- About 15% of patients with unstable angina will progress to myocardial infarction.

## CLINICAL DIAGNOSIS OF STEMI INFARCT

**Basic description:** Death of cardiac myocytes releases enzymes into the blood (e.g., CK-MB and troponin I), which can then be detected.

### Monitoring CK-MB and troponin I

1. **CK-MB:** Isoform of creatine kinase (other isoforms include –MM and –BB). In the heart, most of the CK is CK-MB; therefore, *if the ratio of CK-MB to total CK is high, it is consistent with damage to the heart*. The level of CK-MB rises quickly after a myocardial infarct (within 4–8 hours), peaking at 24 hours, and falls to a normal level within 3 days.
2. **Troponin I:** Very specific for damage to the heart. Troponin I rises within 3–4 hours after a myocardial infarct and remains elevated for 10–14 days.

### ECG findings of STEMI infarct

- Myocardial infarction: Focal ST elevation.
- Q-waves: Infarcted myocardium cannot conduct electrical forces; therefore, the electrical forces are directed away from the electrode and a Q wave results.

### Morphology of a myocardial infarct based upon age

(Table 10-1)

- **Microscopic morphology:** At 4 to 12 hours, coagulative necrosis begins; at 12 hours to 3 days, infiltration of neutrophils begins and grows more prominent; at 3 to 7 days, macrophages and neutrophils are present; at 7 to 10 days, granulation tissue develops; at 10 days or more, the start of collagen deposition; and at 8 weeks or more, dense fibrous scar is present.

**TABLE 10-1.** Morphology of Myocardial Infarct

Time Frame (after onset of infarct)	Microscopic Morphology	Gross Morphology
4–12 hours	Coagulative necrosis	Not visible
12 hours to 3 days	Coagulative necrosis and increasing neutrophilic infiltrate	Pale at 12 hours; progressing to yellow discoloration at 3 days
3–7 days	Increasing numbers of macrophages and decreasing neutrophilic infiltrate	Yellow and contracted (i.e., shrunken)
7–10 days	Granulation tissue	Variable; gray discoloration
10+ days	Beginning deposition of collagen	Variable; gray discoloration
8 weeks	Dense fibrous scar	Dense white scar

- **Gross morphology:** Prior to 12 hours of age, unable to see myocardial infarct; at 1 to 3 days, neutrophil infiltrate causes yellow discoloration; at 3 to 7 days, macrophages engulfing dead cells cause shrinkage of tissue; and by 8 weeks, only a dense scar is present (Figures 10-10, 10-11, and 10-12).

### REPERFUSION OF MYOCARDIAL INFARCT

**Basic description:** Term applied when blood flow is reestablished to a previously ischemic region.

#### Complications of reperfusion

- Calcium influx into the cells causes hypercontraction of the myofibrils.
- Generation of reactive oxygen species, which can further damage the cells.
- Leakage of blood from vessels previously damaged by ischemia (see Figure 10-9).

**Microscopic morphology of reperfusion:** Hemorrhage and contraction band necrosis.

### MECHANICAL, STRUCTURAL, AND ELECTRICAL COMPLICATIONS OF A MYOCARDIAL INFARCT

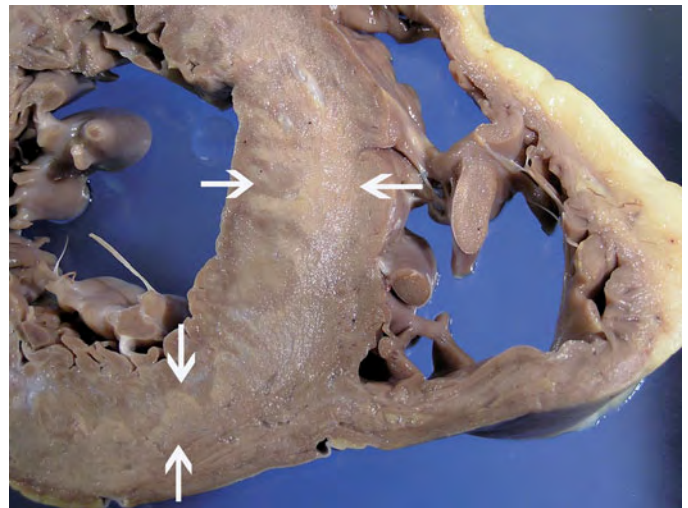
**Overview:** There are many possible complications of a myocardial infarct. Many of these complications can be divided into the three categories of mechanical, structural, and electrical (Table 10-2).

#### 1. Mechanical complications of myocardial infarct

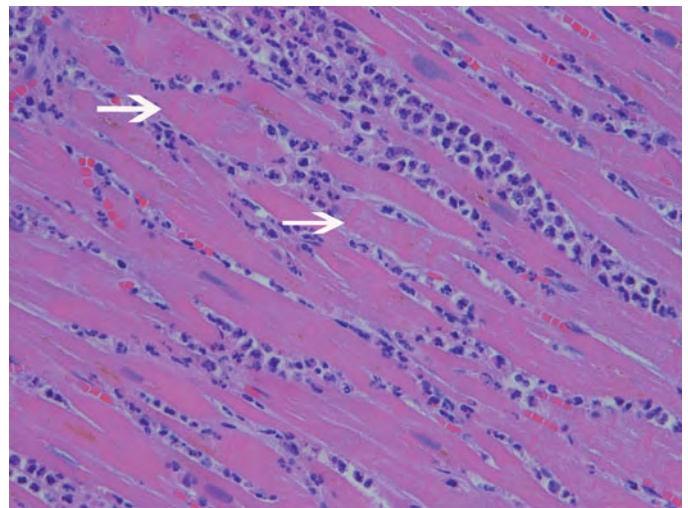
- Left ventricular failure.
- Right ventricular failure.
- **Cardiogenic shock:** Most common cause of death inside the hospital. Cardiogenic shock requires death of more than 40% of the myocardium for it to develop (Figure 10-13).

#### 2. Structural complications of myocardial infarct

- **Rupture:** Ruptures usually occur 3–7 days after a myocardial infarct, when the cells are dead and macrophages have removed debris. The three areas that can rupture with different subsequent complications are the free wall, the interventricular septum, and the papillary muscles.



**Figure 10-10.** Recent myocardial infarct of interventricular septum. The yellow discoloration in the interventricular septum and inferior wall of the left ventricle (arrows) is a myocardial infarct of approximately 2–4 days of age.



**Figure 10-11.** Recent myocardial infarct. This microscopic section of the infarct pictured in Figure 10-10 exhibits coagulative necrosis and a prominent neutrophilic infiltrate, consistent with 2–4 days of age. Occasional necrotic myocytes contain contraction bands (arrows). The punctate brown pigment is lipofuscin. Hematoxylin and eosin, 200×.

- **Complications of rupture:** Free wall rupture leads to a hemopericardium, which causes cardiac tamponade (Figures 10-14 A and B); interventricular septum rupture leads to a left-to-right shunt; papillary muscle rupture (or simply death of the papillary muscle) leads to acute mitral insufficiency (see Figure 10-13).

- **Risks for rupture:** Women, younger than 60 years of age, preexisting hypertension, and no prior infarcts (fibrosis of the myocardium caused by a prior infarct protects against rupture).

■ **Aneurysm:** A grossly visible aneurysm is a late term pathologic condition, which requires formation of a scar and subsequent bulging outward of the scar (Figure 10-15). Aneurysms can be seen immediately clinically because the necrotic tissue will bulge outward with contraction of the heart.

■ **Pseudoaneurysm:** Rupture of the free wall, which is sealed by the pericardium. The hematoma outside of the wall of the heart imitates an aneurysm.

### 3. Electrical complications of myocardial infarcts

■ **Arrhythmia** (bradyarrhythmias, ventricular ectopy, tachyarrhythmias, sudden cardiac death): Arrhythmias are the most common cause of death outside the hospital. Most deaths are due to sustained ventricular tachycardia or ventricular fibrillation.

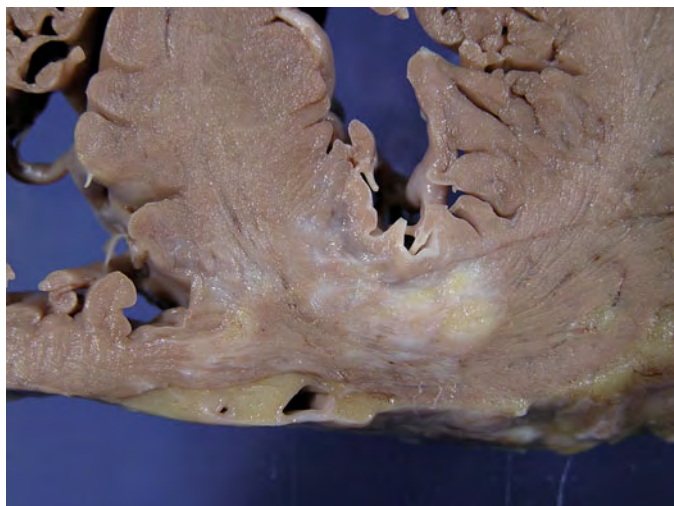
■ **Conduction abnormalities:** Heart block, bundle branch blocks.

**Other complications of myocardial infarcts:** Some complications of a myocardial infarct do not fit easily within the mechanical, structural, or electrical categories (see Table 10-2).

■ **Pericarditis** (two patterns)

1. Pericarditis occurring within days of the infarct: Caused by the acute inflammation associated with a transmural infarct.
2. Pericarditis occurring within 1 to 2 months after the infarct (referred to as **Dressler syndrome**): Attributed to probable autoimmune reaction; patients also have systemic symptoms (e.g., fever, malaise).

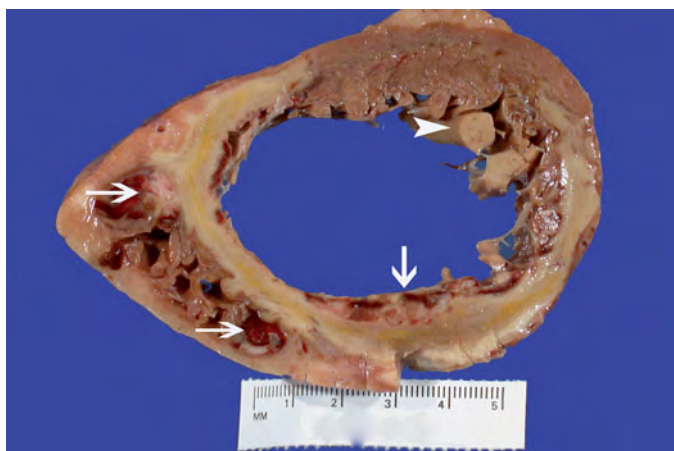
■ **Mural thrombi:** Adjacent inflammation of the wall and abnormal contraction of the wall can cause stasis of the blood and result in thrombi, which line the wall of the ventricle. Mural thrombi can embolize (see Figures 10-13 and 10-14B).



**Figure 10-12.** Remote myocardial infarct. The inferior wall of the left ventricle has a subendocardial scar (white fibrous area), with focal fatty degeneration (adjacent yellow area). A white fibrous scar indicates that the myocardial infarct is 2 or more months of age.

**TABLE 10-2.** Complications of Myocardial Infarct

Category of Complication	Types of Complications
Mechanical	Left and right ventricular failure Cardiogenic shock
Structural	Aneurysms Rupture
Electrical	Arrhythmias Conduction abnormalities
Other	Pericarditis Mural thrombi Right ventricular infarct Infarct extension Infarct expansion



**Figure 10-13.** Mural thrombi and acute mitral insufficiency following a myocardial infarct. This patient sustained a transmural myocardial infarct involving more than 40% of the myocardium of the left ventricle (the area of the infarct is the yellow tissue). The left ventricle is dilated, consistent with cardiogenic shock. The patient also had mural thrombi (arrows), as well as mitral insufficiency due to a necrotic papillary muscle (arrowhead).



- **Right ventricular infarct:** Infarcts solely of the right ventricle are rare, but inferoseptal infarcts of the left ventricle frequently (20% of cases) extend to involve the right ventricle.
- **Infarct extension:** Increase in size of the infarct beyond its original borders; due to retrograde propagation of thrombus, vasospasm, or impaired contractility.
- **Infarct expansion:** Outward bulging of the infarcted segment; due to stretching, thinning, and dilation of infarcted segment (see Figure 10-14 B).

## SUDDEN CARDIAC DEATH

**Overview:** Sudden cardiac death is due to cardiac pathology. The time frame required to call a death “sudden cardiac death” is < 24 hours if the patient is untreated, and < 1 hour if patient is treated). Most cases are due to an arrhythmia, usually ventricular tachycardia or fibrillation.

**Mechanism of sudden cardiac death:** Most cases of sudden cardiac death are associated with either atherosclerotic coronary artery disease or structural heart disease such as dilated or hypertrophic cardiomyopathy. The strongest predictor of sudden cardiac death is left ventricular dysfunction of any cause. Ischemia due to obstruction of a vessel makes myocytes irritable and irritable myocytes are prone to arrhythmias, some of which can be lethal. Patients with congenital arrhythmias such as long QT syndrome are also at increased risk for sudden cardiac death.

## CHRONIC ISCHEMIC HEART DISEASE

**Overview:** Chronic ischemic heart disease is a condition resulting from ischemic injuries occurring over time (i.e., in multiple episodes). Patients may have a few or many myocardial infarcts, or they may have diffuse severe atherosclerosis with chronic ischemia, which damages the heart over time, leading to structural changes such as hypertrophy and dilation (Figure 10-16).

**Complications:** Congestive heart failure.

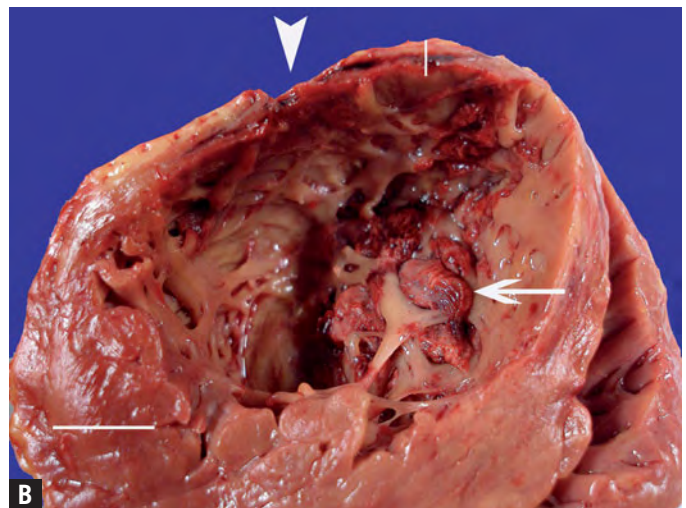
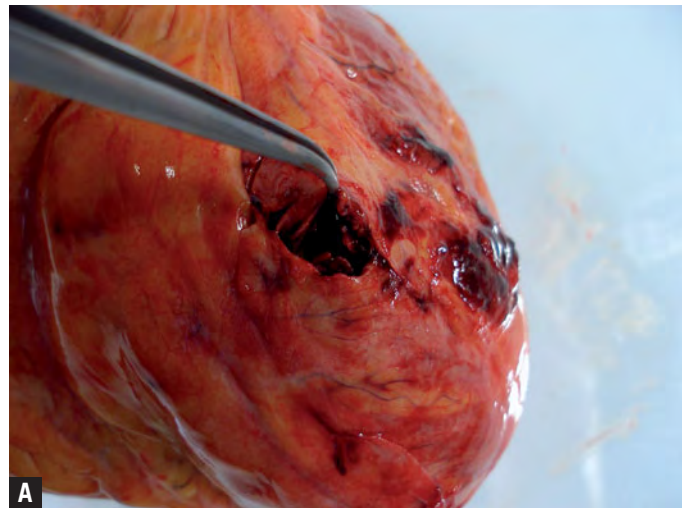
## HYPERTENSIVE CARDIOVASCULAR DISEASE

**Basic description:** Cardiac disease occurring because of long-standing hypertension.

### Gross morphology of hypertensive cardiovascular disease

- Cardiac hypertrophy: Increase in the weight of the heart and thickness of the wall of the left ventricle (**concentric hypertrophy**).
- The disease is often accompanied by significant coronary artery atherosclerosis.

**Complications of hypertensive cardiovascular disease:** CHF, lethal cardiac arrhythmias, and atrial fibrillation secondary to left atrial dilation. The hypertrophic myocardium is more susceptible to ischemic injury.



**Figure 10-14.** Ruptured myocardial infarct. **A**, A full-thickness tear in the anterior wall of the left ventricle, which resulted in a hemo-pericardium. **B**, A cross-section of the left ventricle at the level of the tear (arrowhead). The lumen of the left ventricle is expanded anteriorly in the area of the infarct and the infarcted myocardium is thinned (shorter white line) compared to a non-necrotic segment of the ventricle (longer white line); these changes represent infarct expansion. The arrow indicates mural thrombi.

## CONGESTIVE HEART FAILURE

**Basic description:** The heart can no longer pump out enough blood to supply the body's needs.

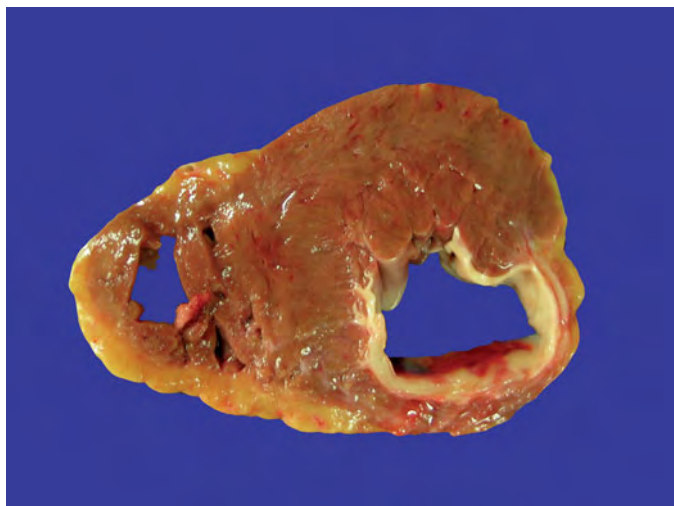
**Types and terminology of CHF:** Most cases of CHF are systolic, low output, and either left sided or biventricular.

- **Systolic dysfunction:** The heart cannot generate enough force to pump enough blood.
- **Diastolic dysfunction:** The heart cannot dilate adequately to fill with enough blood to pump out.
- **Left-sided heart failure:** CHF due to a condition involving or affecting the left side of the heart.
- **Right-sided heart failure:** CHF due to a condition involving or affecting the right side of the heart.
  - **Most common cause of right-sided heart failure:** Left-sided heart failure.
  - **Other causes of right-sided heart failure:** Pulmonary disease (e.g., obstructive and restrictive lung diseases; pulmonary hypertension).
- **High-output failure:** *Not* due to a problem intrinsic to the heart. The heart can pump an adequate amount of blood under normal circumstances, but some process extrinsic to the heart places additional demands upon the heart. Causes include anemia, hyperthyroidism, arteriovenous malformation, and thiamine deficiency (**wet beriberi**).
- **Low-output failure:** The heart simply cannot pump a sufficient amount of blood.
- **Acute or chronic failure:** Depends on rapidity of the development of symptoms.

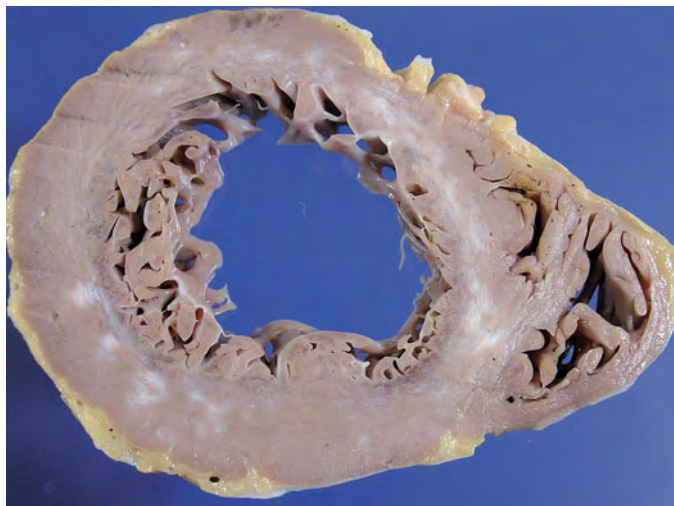
**Morphology of CHF:** The mechanism of the morphologic changes and signs and symptoms is primarily increased hydrostatic pressure; however, other mechanisms also play a role, including activation of the renin-angiotensin-aldosterone system and other intrarenal mechanisms for sodium retention. Therefore, although the following morphologic changes and the signs and symptoms are listed under one type of CHF (right or left sided), the changes are not 100% specific (i.e., pitting edema can occur with left-sided heart failure).

- **Morphology of left-sided heart failure:** Recurrent bouts of pulmonary edema and increased pulmonary venous pressure lead to hemorrhage and hemosiderin-laden macrophages (i.e., “**heart failure cells**”) in the lung.
- **Morphology of right-sided heart failure**
  - **Hepatosplenomegaly:** Increased venous pressure due to increased resistance to portal flow results in passive congestion of blood in the liver and spleen.
  - **Ascites and peripheral pitting edema.**

**Symptoms of CHF:** Dyspnea on exertion due to lack of increased cardiac output with exercise in patients with heart failure; orthopnea, as the result of pooling of blood in the lungs in the supine position due to increased venous pressure; and paroxysmal nocturnal dyspnea. Patients also have cough (because of interstitial pulmonary edema), fatigue, and nocturia (because



**Figure 10-15.** Ventricular aneurysm caused by a transmural myocardial infarct. This patient had a myocardial infarct involving the full thickness of the wall of the left ventricle, which healed, becoming a thin, but dense fibrous scar. With contraction of the heart, this noncontractile, scarred area expanded, producing an aneurysmal sac. The endocardium is thicker than normal.



**Figure 10-16.** Chronic ischemic heart disease. This heart contains multiple remote myocardial infarcts (all the dense white scars, most prominent in the interventricular septum). Although each infarct may have been undiagnosed clinically due to its small size, the cumulative loss of myocytes in such cases can eventually cause congestive heart failure.



the kidney attempts to reduce the volume of fluid that is mobilized when the patient is recumbent).

#### Signs of CHF occurring as result of compensatory mechanisms

- Increased heart rate due to increased sympathetic tone.
- Narrowed pulse pressure due to peripheral vasoconstriction.

#### Signs of CHF most commonly associated with right-sided heart failure

- Pitting peripheral edema.
- Increased right atrial pressure (i.e., distention of right internal jugular vein > 4 cm above the sternal angle).
- **Kussmaul sign:** Increase in venous pressure and jugular venous distention with inspiration. Normally, inspiration causes negative intrathoracic pressure, which causes blood to drain into the thorax, thereby reducing venous pressure. In right-sided heart failure, inspiration presents a venous load that a failing right ventricle cannot handle, resulting in an increase in jugular venous pressure and jugular venous distention.
- **Hepatojugular reflux:** Seen in right-sided heart failure, pressure applied over the congested liver returns blood to the heart and increases the right atrial pressure, resulting in increased jugular venous pressure and distention.

#### Signs of CHF most commonly associated with left-sided heart failure

- Crackles in the lung are indicative of pulmonary edema.
- $S_3$  is consistent with systolic dysfunction.

**Laboratory findings of CHF:**  $\beta$ -natriuretic peptide (BNP) is elevated in patients with symptomatic left ventricular dysfunction.

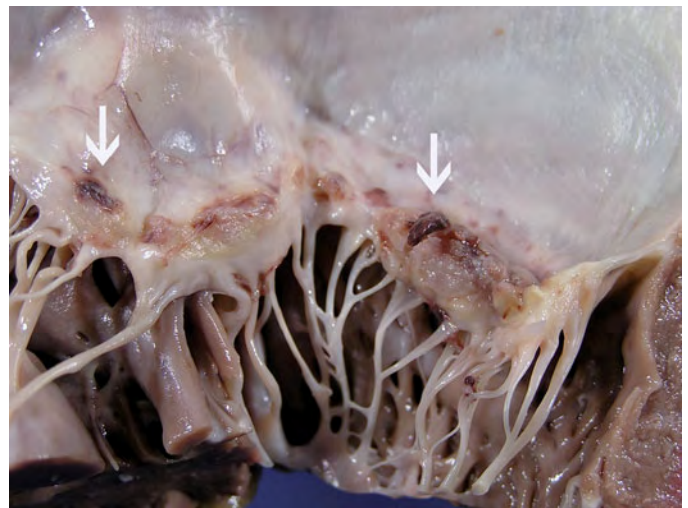## GENERAL VALVULAR DISEASE

**Overview:** Conditions specifically related to the aortic and mitral valve will be discussed later; endocarditis (inflammation of the cardiac valves) and rheumatic fever will be discussed in this section.

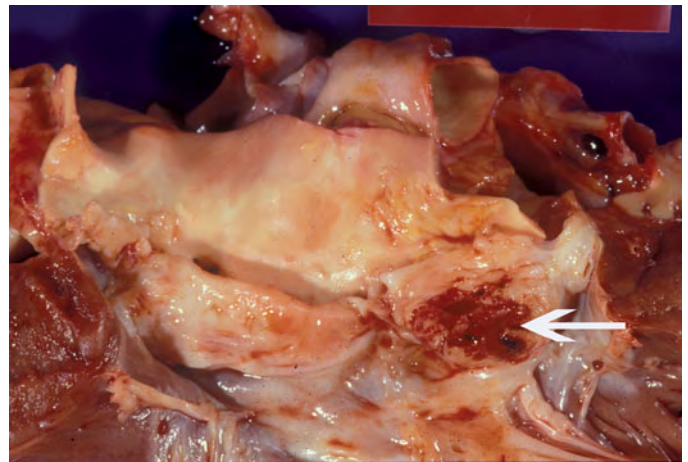
### ENDOCARDITIS

**Basic description:** Infection (usually bacterial) involving the valve cusps or the adjacent endocardium, or both (Figure 10-17).

**Risks for bacteremia:** Dental and gastrointestinal procedures. In patients with known valve abnormalities, prosthetic valves, or congenital heart defects, these procedures require antibiotic prophylaxis to reduce the risk of endocarditis (Figures 10-18 and 10-19). Rheumatic valvular disease, while less common today, is still a predisposing factor in as many as 20% of patients with infective endocarditis.



**Figure 10-17.** Endocarditis of the mitral valve. The leaflets of the mitral valve have several soft, tan-red vegetations (arrows).



**Figure 10-18.** Endocarditis of a bicuspid aortic valve. This patient had a congenital bicuspid aortic valve, and subsequently developed endocarditis (endocarditis commonly involves abnormal valves). The infectious agent perforated one cusp (arrow), which can result in acute valvular regurgitation.



### Types of endocarditis

- **Infective endocarditis:** Traditionally, the terminology of endocarditis was based upon the virulence of the causative organism and was divided into acute and subacute types. With effective antimicrobial therapy, the types are less well-defined and the general term **infective endocarditis** is preferred.
- **Nonbacterial thrombotic endocarditis (marantic endocarditis)**
  - **Microscopic morphology of nonbacterial thrombotic endocarditis:** Bland; vegetations contain fibrin but no neutrophils or bacteria.
  - **Causes of nonbacterial thrombotic endocarditis:** Nonbacterial thrombotic endocarditis forms in the background of sepsis and cancer (especially mucinous adenocarcinoma of the pancreas and gastrointestinal tract).

### Complications of infective endocarditis

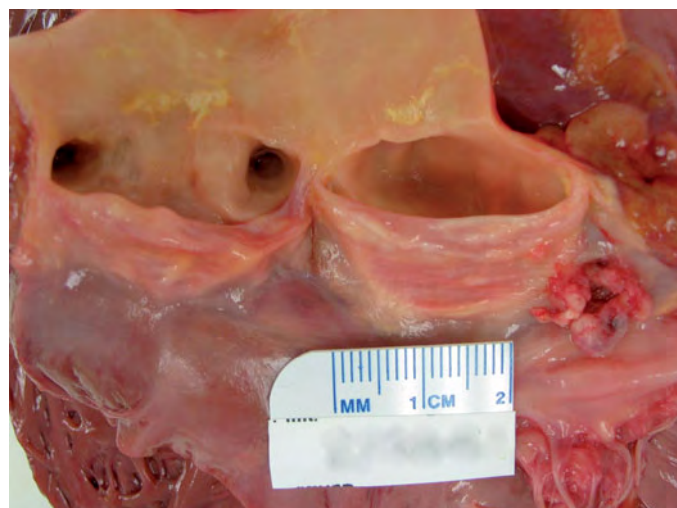
- **Sepsis:** Bacterial endocarditis sheds bacteria into the blood, which results in sepsis.
- **Septic emboli** with resultant distant abscesses and “mycotic” arterial aneurysms.
- **Valvular regurgitation:** Acute regurgitation as a result of perforation of the leaflet(s) or rupture of the chordae tendineae; or chronic regurgitation due to fibrosis occurring as result of repair of infective endocarditis (see Figure 10-18).
- **Ring abscess:** Inflammation of the valve ring.
- **Other complications of infective endocarditis:** Glomerulonephritis, pericarditis, and local myocarditis.

**Gross morphology of infective endocarditis:** Vegetations on the cusp or leaflet (i.e., friable excrescences associated with variable degrees of valve destruction).

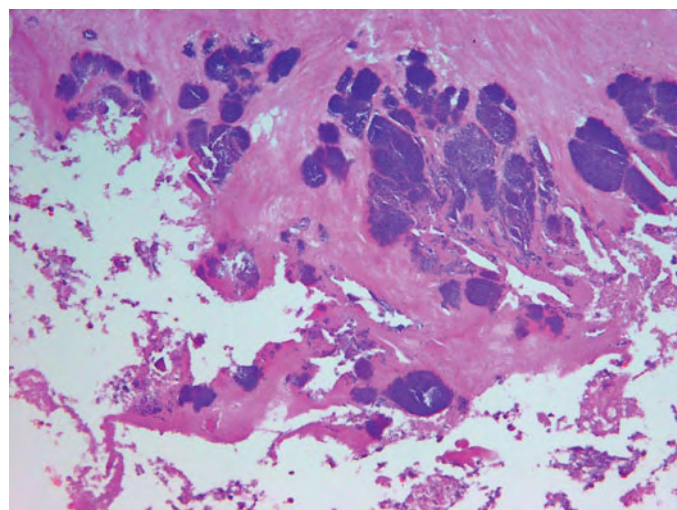
**Microscopic morphology of infective endocarditis:** Vegetations are composed mostly of fibrin and bacterial organisms with few neutrophils (Figure 10-20).

### Clinical presentation of infective endocarditis

- **Symptoms:** Fever, chills, night sweats, arthralgias, weakness, and shortness of breath are the most common symptoms.
- **Signs:** New cardiac murmur; other findings include **Osler nodes** (i.e., raised tender lesions on the fingers); **Roth spots** (i.e., pale lesions in the retina surrounded by hemorrhage); **Janeway lesions** (i.e., erythematous nontender lesion on palm or sole); and splinter hemorrhages in nail beds.
- **Diagnosis of infective endocarditis:** Persistently positive blood cultures in combination with fever and appropriate clinical history and physical examination. Transesophageal echocardiography identifies vegetations in 75–95% of patients with infective endocarditis.



**Figure 10-19.** Endocarditis of a bicuspid aortic valve. This aortic valve is an uncommon true bicuspid valve, in which the cusps are of equal size and neither has a midline raphe. To the right of the ruler, at the junction of the noncoronary cusp and anterior leaflet of the mitral valve, is a vegetation. Patients with abnormal cardiac valves (e.g., a bicuspid aortic valve) are at greater risk for the development of endocarditis. Courtesy of Dr. Janis Townsend-Parchman, Dallas County Medical Examiner's Office, Dallas, TX.



**Figure 10-20.** Endocarditis. This photomicrograph shows the components of a vegetation. The punctate blue material is bacterial organisms. The acellular pink material is fibrin. Only occasional neutrophils are present due to the absence of local blood vessels. This composition gives the vegetations little support, allowing small fragments to easily break free in the blood stream and embolize to distant sites. Hematoxylin and eosin, 40 $\times$ .

### Important points regarding infective endocarditis

- Valve cusps and leaflets are avascular; therefore, endocarditis is hard to treat because it is difficult to get high concentrations of antibiotics to the site of the infection.
- The former term, subacute bacterial endocarditis, described a condition that classically involved the left-sided heart valves and was most often associated with viridans streptococcus.
- Right-sided endocarditis is classically associated with intravenous drug use. It is commonly associated with *Staphylococcus aureus* and presents acutely.
- Staphylococcus epidermidis* is often associated with endocarditis after cardiac surgery.
- Endocarditis due to *Streptococcus bovis* is often due to an underlying colon cancer.

## RHEUMATIC FEVER

**Overview:** Group A  $\beta$ -hemolytic streptococcal pharyngitis causes production of antibodies that cross react with cardiac antigens. These antibodies produce a disease known as **acute rheumatic fever**. Acute rheumatic fever occurs most commonly in children aged 4 to 9 years.

## ACUTE RHEUMATIC FEVER

**Signs and symptoms:** Patients have two of five major criteria, or one major criterion and two minor criteria (Table 10-3).

- Major (Jones) criteria of acute rheumatic fever:** Pancarditis (either pericarditis, myocarditis, or endocarditis), subcutaneous nodules, Sydenham chorea, migratory polyarthritides, and erythema chronicum migrans.
- Minor criteria of acute rheumatic fever:** Fever, arthralgia, and history of previous rheumatic fever or known rheumatic heart disease.

**Diagnosis of acute rheumatic fever:** The diagnosis is clinical, and laboratory tests are largely confirmatory. Antistreptolysin O is elevated in 80% of patients; however, anti-DNAse B is more specific.

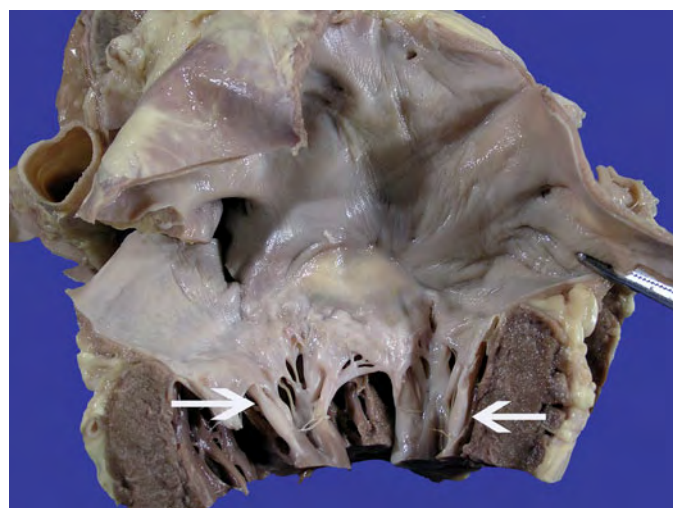
**Microscopic morphology: Aschoff nodules**, which are nodules of mononuclear cells with central fibrinoid necrosis that have Anitschkow cells (modified macrophages with nuclei that have central caterpillar-shaped chromatin).

**Chronic rheumatic valvulitis** (i.e., disease presenting many years after an episode of acute rheumatic fever).

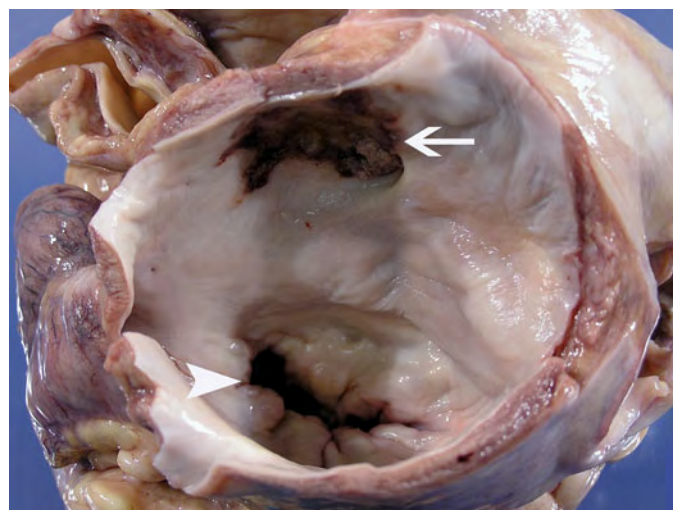- Mitral stenosis:** Caused by fusion, thickening, and shortening of the chordae tendineae and valve leaflets. The mitral valve is the most common valve affected in rheumatic valvulitis; conversely, rheumatic fever is the most common cause of isolated mitral stenosis (Figures 10-21 and 10-22).

**TABLE 10-3.** Criteria for Diagnosis of Acute Rheumatic Fever

Category of Criteria	Criteria
Major	Pancarditis (pericarditis, myocarditis or endocarditis) Subcutaneous nodules Sydenham chorea Migratory polyarthritides Erythema chronicum migrans
Minor	Fever Arthralgia History of previous rheumatic fever or chronic rheumatic heart disease



**Figures 10-21.** Chronic rheumatic valvulitis of the mitral valve. This mitral valve exhibits the characteristic features of chronic rheumatic mitral valvulitis—short, thick, and fused chordae tendineae (arrows). The leaflets are also thick. These changes can lead to mitral stenosis.



**Figure 10-22.** Chronic rheumatic valvulitis of the mitral valve. This figure shows mitral stenosis (arrowhead), which resulted in left atrial dilation. Atrial dilation can lead to atrial fibrillation, which can in turn predispose to thrombus formation (arrow). The thrombi can break loose and embolize to distant sites.



■ **Aortic stenosis and regurgitation:** Caused by fusion of the aortic valve commissures (Figure 10-23).

**General overview of stenotic and regurgitant valvular disease:** Diseases of the valves cause either stenosis (i.e., blockage of blood flow through the valve) or regurgitation (i.e., leakage of blood back through the valve). Often the changes in the valve can cause both stenosis and regurgitation, since a misshapen valve that does not open all the way is not likely to close completely. In cases of “combined” stenosis and regurgitation, however, one hemodynamic abnormality typically predominates. In most cases, stenosis develops chronically, while regurgitation can develop acutely or chronically, depending upon the underlying cause. Chronic conditions affecting the valves allow for compensatory changes, whereas acute conditions do not. Recognizing the clinical presentation of valvular disease requires a basic understanding of heart murmurs. Right-sided murmurs tend to increase in intensity with inspiration because of increased venous return. Murmurs are classified as systolic, diastolic, or continuous (occurring during both systole and diastole), and either ejection-type or regurgitant-type.

## AORTIC VALVULAR DISEASE

### AORTIC STENOSIS

**Basic description:** Obstruction of blood flow through the aortic valve.

#### Causes of aortic stenosis

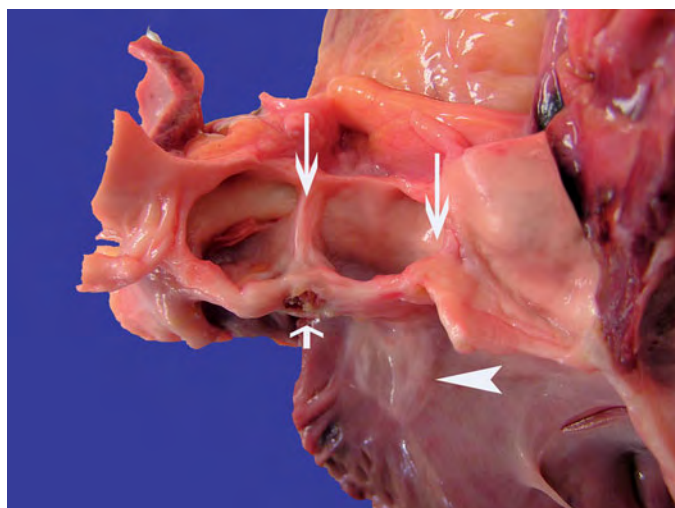
##### 1. Tricuspid aortic valve degenerative calcification

- **Gross morphology:** Nodules of calcium on the sinus side of the cusps with little involvement of the commissures (Figure 10-24).
- **Consequences:** Requires valve replacement in patients 70 to 80 years of age.

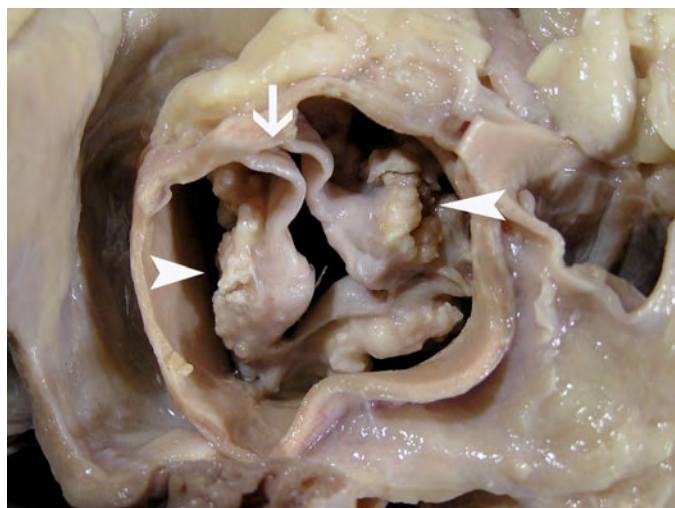
##### 2. Congenital bicuspid aortic valve degenerative calcification

- **Gross morphology:** Nodules of calcium on the sinus side of the cusps. In most cases, bicuspid valves have one smaller cusp and one large cusp. The larger cusp has a midline raphe, representing incomplete separation of two cusps (Figure 10-25).
- **Consequences:** Requires valve replacement in patients 50 to 60 years of age.
- **Associations:** Aortic dissection, coarctation of aorta.

##### 3. Chronic rheumatic valvulitis: (see chronic rheumatic valvulitis above).



**Figure 10-23.** Chronic rheumatic valvulitis of the aortic valve. The valve ring has been opened, and the aortic aspect of the valve is illustrated in the photograph. This aortic valve has the characteristic features of chronic rheumatic aortic valvulitis; namely, fusion of the commissures (*long arrows*) and thickening of the valve leaflets. The patient also has dystrophic calcification related to healed endocarditis (*short arrow*) and evidence of aortic regurgitation in the form of endocardial fibrosis from a jet lesion (*arrowhead*).



**Figure 10-24.** Degenerative tricuspid valve aortic stenosis. This elderly man had prominent nodules of calcium on the cusps of the aortic valve (*arrowheads*) as a result of dystrophic calcification. The nodules of calcium lead to impingement on the orifice and subsequent aortic stenosis. Note that the commissures are *not* fused (*arrow*), as would be expected if the aortic stenosis was due to chronic rheumatic valvulitis.



### Complications of aortic stenosis

- Concentric cardiac hypertrophy: Thickening of the left ventricle wall due to increased pressure required to pass blood through the valve orifice.
- Syncope: Transient loss of consciousness because of poor cerebral perfusion.
- Chest pain: Occurs because of poor filling of the coronary arteries and increased oxygen demands of the hypertrophic ventricle.
- Sudden death: Occurs because of ischemic changes or because of a lethal ventricular arrhythmia due to cardiac hypertrophy.

### Clinical presentation of aortic stenosis

**Symptoms:** The cardinal symptoms of aortic stenosis are angina, syncope, and CHF. Dyspnea may be due to a noncompliant hypertrophied left ventricle or due to systolic dysfunction late in the course of the disease. In the absence of preexisting valve damage or a congenital bicuspid aortic valve, aortic stenosis usually occurs in patients older than 65 years of age.

### Survival time from onset of symptoms

- 5 years from angina.
- 3 years from syncope.
- 2 years from CHF.

### Signs of aortic stenosis

- Attenuated carotid pulse with a delayed upstroke (**pulsus parvus et tardus**).
- Paradoxically split  $S_2$ , in which the pulmonic valve closes before the aortic valve.
- High-pitched systolic ejection-type systolic murmur (crescendo-decrescendo).

## AORTIC REGURGITATION

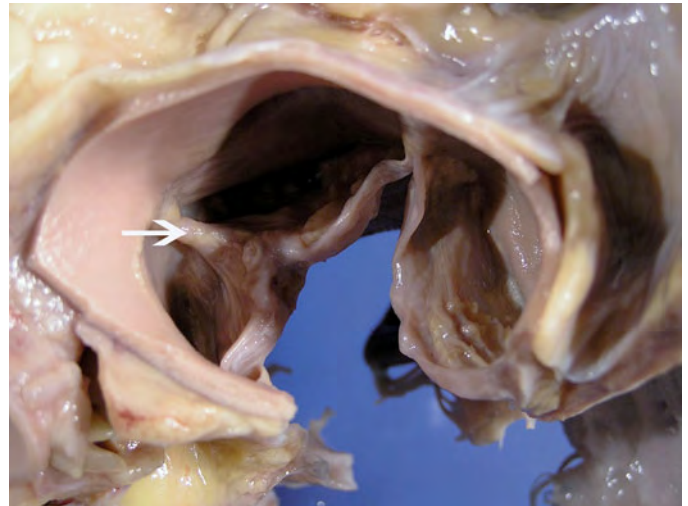
**Basic description:** Leakage of blood back through closed valve.

### Causes of chronic aortic regurgitation

- Dilation of aortic valve ring as occurs in Marfan syndrome, a syphilitic aneurysm, or an aortic dissection.
- Healed endocarditis.
- Bicuspid aortic valve.

### Causes of acute aortic regurgitation

- Infective endocarditis with perforation of valve leaflet (see [Figure 10-18](#)).
- Trauma.
- Aortic dissection.



**Figure 10-25.** Bicuspid aortic valve. This patient had the more common type of bicuspid aortic valve—a valve with two cusps of unequal size. The larger cusp has a midline raphe (*arrow*), which represents failed separation of the cusps at a commissure.

### Complications of aortic regurgitation

- Eccentric cardiac hypertrophy.
- Functional mitral regurgitation because of eccentric left ventricular hypertrophy.
- Acute aortic regurgitation can result in cardiogenic shock.

### Symptoms of aortic regurgitation

- Dyspnea, orthopnea, and paroxysmal nocturnal dyspnea.
- Fatigue and weakness (because of decreased cardiac output).
- Angina (because of decreased coronary perfusion pressures).
- Acute aortic regurgitation presents with symptoms of cardiogenic shock.

### Signs of aortic regurgitation

- Blood pressure in the leg is more than 20 mm Hg higher than pressure in the arm (**Hill sign**).
- Bounding pulse (**Corrigan** or **water-hammer pulse**) due to increased pulse pressure (difference between systolic and diastolic).
- **Bisferious pulse** (with two systolic peaks).
- Decrescendo, high-pitched, early diastolic murmur heard best at the left sternal border with the patient sitting up and leaning forward.

## MITRAL VALVULAR DISEASE

### MITRAL STENOSIS

**Cause:** In adults, mitral stenosis is almost always due to chronic rheumatic valvulitis (see Figures 10-21 and 10-22).

**Complications of mitral stenosis:** Left atrial dilation, leading to atrial fibrillation or mural thrombi, or both. Patients can also develop chronic passive congestion of the lung, which can lead to hemoptysis.

**Clinical presentation of mitral stenosis:** Mitral stenosis is characterized by a low-pitched diastolic rumbling heard best at the apex with the patient in the left lateral decubitus position. Mitral stenosis often produces an early opening snap. Shortness of breath and orthopnea are the most common symptoms. Occasionally, hemoptysis can occur due to rupture of dilated bronchial veins.

### MITRAL REGURGITATION

**Causes of mitral regurgitation:** Three of the main causes of mitral regurgitation are a myxomatous mitral valve, mitral annular calcification, and endocarditis. Details regarding myxomatous mitral valve and mitral annular calcification will be discussed below.

#### 1. Myxomatous mitral valve

**Epidemiology:** Approximately 1–3% of the general population; most common in young females; can be autosomal dominant with variable penetrance.

**Gross morphology of myxomatous mitral valve:** Hooding of leaflets, long chordae tendineae; possible rupture of chordae tendineae (Figure 10-26).

**Complications:** Regurgitation (the name for the resulting clinical presentation is **mitral valve prolapse**); endocarditis; and rarely, sudden death secondary to an arrhythmia.

#### Clinical presentation of myxomatous mitral valve

■ **Symptoms:** Asymptomatic in many patients.

■ **Signs:** Mid-systolic click with late systolic murmur.

#### 2. Mitral annular calcification

**Basic description:** Calcification of the mitral valve annulus.

**Epidemiology:** Common in the elderly.

**Gross morphology:** Variably thick and variably continuous ring of calcification in mitral valve annulus.

**Complications of mitral annular calcification:** Asymptomatic in many patients but it can cause regurgitation and, rarely, sudden cardiac death, because of encroachment of calcification on atrioventricular node.

**Complications of mitral regurgitation:** Dilation of the left atrium and left ventricle in response to increased volume. Acute mitral regurgitation is life threatening. The left atrium cannot dilate rapidly enough to accommodate the increased volume, thereby raising the pulmonary venous pressure and causing pulmonary edema.

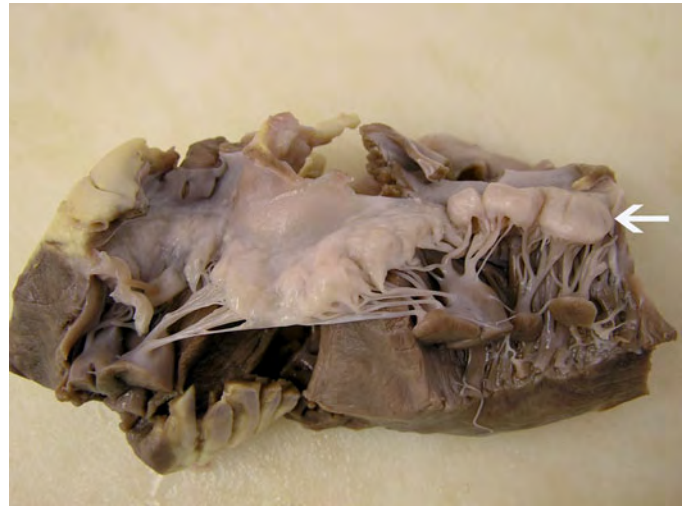#### Clinical presentation of mitral regurgitation

■ **Symptoms:** Fatigue and dyspnea as a result of reduced cardiac output and elevation in pulmonary venous pressures.

■ **Signs:** Holosystolic murmur, which is best auscultated at the apex.

## CARDIOMYOPATHIES

**Overview:** Cardiomyopathies are due to a primary abnormality of the myocardium. In some “traditional” classification schemes, cardiomyopathies were regarded as “idiopathic” disorders (i.e., no identifiable underlying cause), although the medical literature has since perpetuated certain cardiomyopathies as being associated with certain etiologies (e.g., dilated cardiomyopathy and alcohol abuse). More recently, it has become apparent that a number of cardiomyopathies traditionally classified as idiopathic are in fact due to a specific intrinsic myocardial abnormality (e.g., mutations in the  $\beta$ -myosin heavy chain gene or genes encoding various muscular dystrophy-associated proteins), certain toxic insults, and a number of infectious disorders. Myocardial abnormalities occurring as a consequence of ischemic injury or valvular disease are traditionally excluded from the cardiomyopathies.



**Figure 10-26.** Myxomatous mitral valve. This mitral valve, most prominently the posterior leaflet, exhibits ballooning of the leaflets (*arrow*). Although myxomatous mitral valves are most common in females, this patient was an 18-year-old man. Such lesions may occur as an isolated abnormality, but may also occur in association with a number of connective tissue disorders, such as Marfan syndrome, Ehlers-Danlos syndrome, and osteogenesis imperfecta.



## Types of cardiomyopathy

### 1. Hypertrophic cardiomyopathy

**Gross morphology:** Asymmetric thickening of the interventricular septum; fibrosis of the aortic outflow tract corresponding to thick interventricular septum striking the anterior leaflet of the mitral valve (Figure 10-27 A).

**Microscopic morphology:** Myocyte disarray (Figure 10-27 B).

**Importance of hypertrophic cardiomyopathy:** Many cases are genetic (autosomal dominant). Approximately 75% of cases are due to a mutation in the  $\beta$ -myosin heavy chain gene, myosin-binding protein C gene, or troponin T gene.

### Clinical presentation of hypertrophic cardiomyopathy

- **Symptoms:** The most frequent symptom is dyspnea on exertion. Patients can also have chest pain, which results from ischemia caused by increasing demands of hypertrophied muscle and concomitant decreased blood flow due to increased wall tension.
- **Signs:** Systolic ejection murmur,  $S_4$ , brisk carotid upstroke, and paradoxically split  $S_2$ .
- **Diagnosis:** Echocardiogram. A biopsy will help rule out amyloidosis, sarcoidosis, hemochromatosis, and myocarditis.
- **Important points:** Hypertrophic cardiomyopathy is a cause of sudden cardiac death. It is the most common cause of sudden, natural death of athletes younger than 35 years of age. Patients have diastolic dysfunction due to the inability of the heart to appropriately dilate to fill during diastole.

### 2. Dilated cardiomyopathy

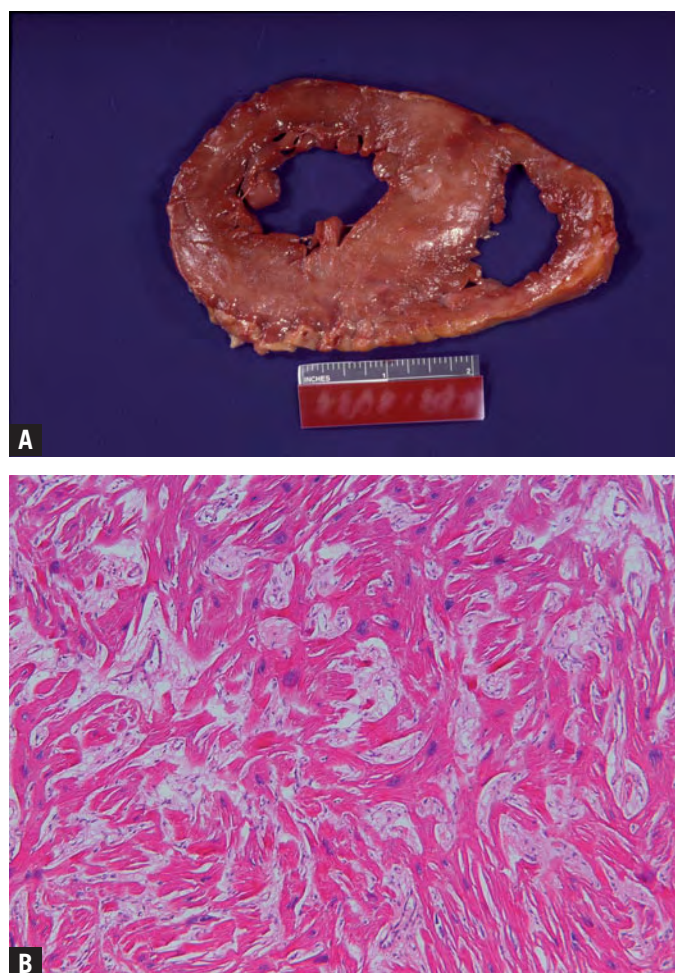
#### Gross morphology

- **External features:** Globular (round) heart.
- **Internal features:** Dilation of all four chambers (Figure 10-28).

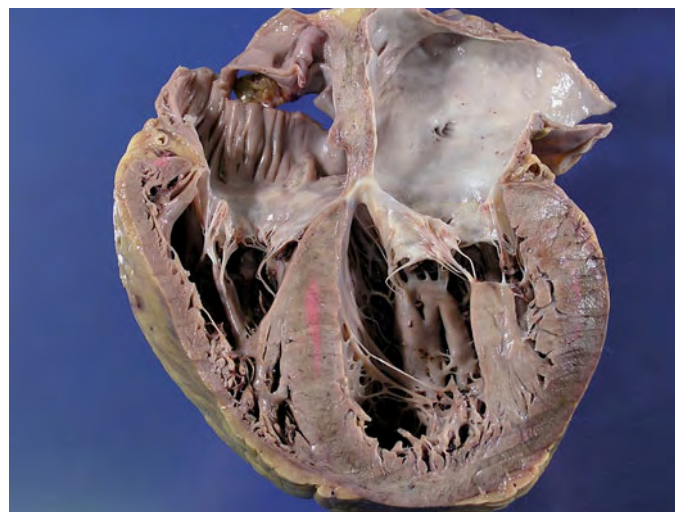
**Clinical features:** Systolic dysfunction due to the heart with dilated chambers and thin walls not being able to contract forcefully enough to supply the body with an adequate amount of blood leading to CHF. Patients can also have atrial and ventricular arrhythmias. The signs and symptoms of dilated cardiomyopathy are similar to those of CHF.

#### Causes of dilated cardiomyopathy

- **Idiopathic.**
- **Genetic causes:** X-linked recessive, autosomal dominant, and autosomal recessive transmission. Many of the genetic forms of dilated cardiomyopathy are associated with muscular dystrophy (e.g., Duchenne muscular dystrophy).
- **Toxin-induced:** Alcohol, doxorubicin (Adriamycin), cobalt.
- **Infectious causes:** Viral (postmyocarditis), parasitic (e.g., Chagas disease).
- **Metabolic causes:** Starvation; thiamine deficiency (also called wet beriberi).
- **Miscellaneous causes:** Sarcoidosis, hemochromatosis.



**Figure 10-27.** Hypertrophic cardiomyopathy. This heart is from a 31-year-old woman who died suddenly. **A**, The interventricular septum is notably thicker than the lateral wall. The tan discoloration is the result of fibrosis, which is commonly noted microscopically in these patients. **B**, The characteristic myocardial disarray of hypertrophic cardiomyopathy. The myocytes are oriented perpendicular to each other, and also appear in a whorled or pinwheel pattern. These patients have cardiac diastolic dysfunction and are at risk for lethal arrhythmias. Hematoxylin and eosin, 200 $\times$ .



**Figure 10-28.** Dilated cardiomyopathy. All four chambers of this heart are dilated, characteristic of a dilated cardiomyopathy, and there is biventricular hypertrophy. These patients have cardiac systolic dysfunction.



### 3. Restrictive cardiomyopathy

**Basic description:** The myocardium is partially infiltrated by noncontractile tissue or extracellular material (e.g., collagen, amyloid). This infiltration of the myocardium impairs the ability of the heart to dilate.

**Clinical features of restrictive cardiomyopathy:** Usually causes diastolic dysfunction. Patients have signs and symptoms of CHF with prominent right-sided features. Restrictive cardiomyopathy may be difficult to clinically distinguish from constrictive pericarditis (see below).

**Causes of restrictive cardiomyopathy:** Most common cause is amyloidosis.

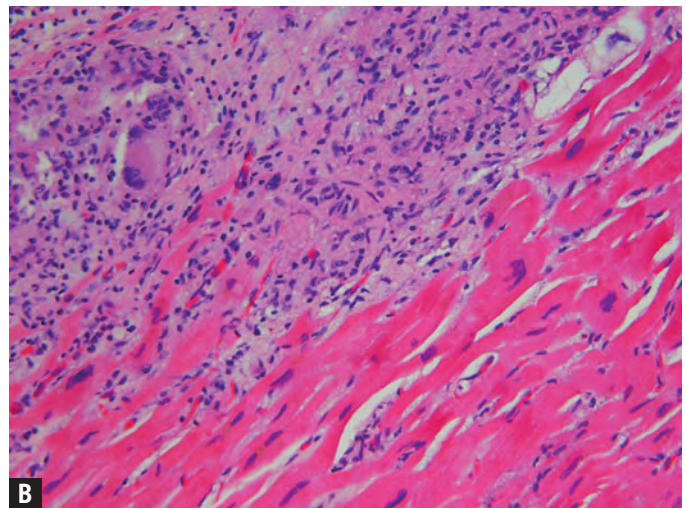
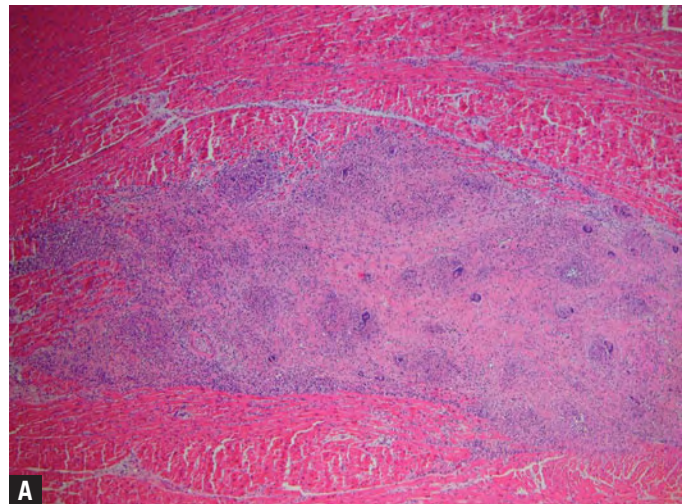
- **Infiltrative causes:** Amyloid, sarcoid (Figure 10-29 A and B).
- **Noninfiltrative causes:** Idiopathic, scleroderma.
- **Other causes:** Hemochromatosis (hemochromatosis also causes dilated cardiomyopathy), diffuse interstitial fibrosis, sarcoidosis, postradiation fibrosis.

#### Other disease of the myocardium: Myocarditis

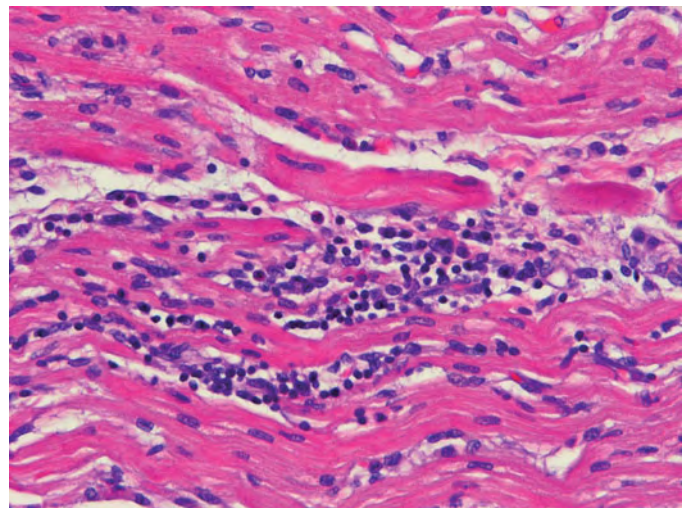
**Basic description:** Inflammation of the heart muscle. In most cases, the term myocarditis is used to refer to **lymphocytic myocarditis**.

#### Lymphocytic myocarditis

- **Diagnostic criteria for lymphocytic myocarditis:** Lymphocytes and myocyte necrosis (Figure 10-30).
- **Causes:** Viral (most common are Coxsackie B virus and echovirus). Recently, adenovirus has been identified as a common cause.
- **Complications:** Sudden death because of lethal arrhythmias; dilated cardiomyopathy.
- **Clinical presentation of lymphocytic myocarditis:** May be asymptomatic or patients may have nonspecific complaints (e.g., fever, malaise, myalgia).



**Figure 10-29 A and B.** Cardiac sarcoidosis. The myocardium in this section is infiltrated by granulomas and giant cells, and the diagnosis was consistent with sarcoidosis. These patients commonly present with a restrictive cardiomyopathy, although they can have a dilated cardiomyopathy. Hematoxylin and eosin, **A**, 100 $\times$ ; **B**, 400 $\times$ .



**Figure 10-30.** Lymphocytic myocarditis. The myocardium in this section is infiltrated by lymphocytes and has focal loss of cardiac myocytes (due to necrosis). These changes are most commonly due to a viral infection, usually Coxsackie B virus. Hematoxylin and eosin, 400 $\times$ .

## PERICARDIAL DISEASE

**Overview:** This section will cover pericarditis, pericardial effusion, and cardiac tamponade.

**Pericarditis** (Figure 10-31; Table 10-4)

**Forms of pericarditis:** Can be categorized two ways, by nature of transudate or exudate or by general etiology.

### ■ By nature of transudate or exudate

- **Serous pericarditis:** Viral (most common is Coxsackie B virus, echovirus, adenovirus); collagen vascular disease (e.g., systemic lupus erythematosus).
- **Fibrinous pericarditis:** Collagen vascular disease (e.g., systemic lupus erythematosus); uremia (due to renal failure); myocardial infarct.
- **Purulent pericarditis:** Bacterial, fungal, mycobacterial.
- **Hemorrhagic pericarditis:** Neoplasms, tuberculosis.

### ■ By general etiology

- **Infectious:** Viral, bacterial (staphylococcal, streptococcal), fungal, tuberculosis.
- **Noninfectious:** Idiopathic, neoplastic, uremic, myxedema.
- **Hypersensitivity:** Collagen vascular disease, Dressler syndrome.

### Complications of pericarditis

- Pericarditis can resolve with no scarring and thus no complications.
- Fibrosis of pericardium to epicardium (i.e., **constrictive pericarditis**) leads to diastolic dysfunction of heart. This outcome is more common when the cause of pericarditis is bacterial, fungal, or mycobacterial (Figure 10-32 A and B).

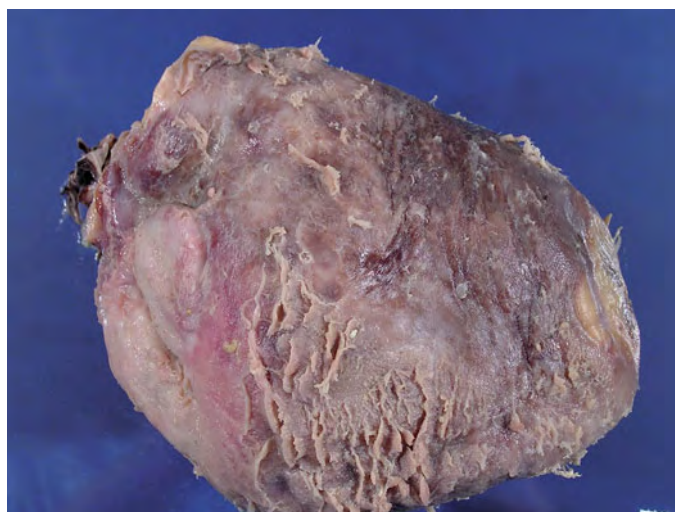
### Clinical presentation of pericarditis

**Symptoms:** Sharp retrosternal chest pain occurs left of the sternum; abrupt in onset. Pain worsens with inspiration and is relieved when leaning forward.

**Duration of symptoms:** Hours.

### Signs

- Friction rub and diffuse ST elevations on electrocardiogram.
- Increased right atrial pressure: Distention of the right internal jugular vein > 4 cm above the sternal angle occurs with constrictive pericarditis.
- Kussmaul sign.
- Pulsus paradoxus; distant heart sounds.



**Figure 10-31.** Pericarditis. The surface of the heart is covered by extensive fibrinous deposits, causing the granular appearance visible in this photograph. This pattern is sometimes referred to as “bread and butter” pericarditis. This condition is commonly seen in patients with uremia, but may also be seen in a number of other conditions, such as systemic autoimmune diseases and acute myocardial infarcts. Patients with pericarditis can have chest pain that is worse on inspiration, diffuse ST elevations on electrocardiogram, and a friction rub on cardiac auscultation. This condition may be associated with the presence of a pericardial effusion.

**TABLE 10-4.** Classification, Forms, and Causes of Pericarditis

Classification	Form	Cause
By nature of transudate or exudate	Serous	Viral, SLE
	Fibrinous	SLE, uremia, MI
	Purulent	Bacterial, fungal
	Hemorrhagic	Neoplasms, TB
By general etiology	Infectious	Viral, bacterial
	Noninfectious	Neoplasms, uremia
	Hypersensitivity	SLE, Dressler syndrome

SLE, systemic lupus erythematosus; MI, myocardial infarct; TB, tuberculosis.



### PERICARDIAL EFFUSION

**Basic description:** Accumulation of fluid in the pericardial sac.

**Causes of pericardial effusion:** Same as pericarditis.

**Clinical presentation of pericardial effusion**

- **Symptoms:** Pressure in chest; symptoms due to compression of adjacent structures (e.g., dysphagia, dyspnea).
- **Signs:** Muffled heart sounds; diminished QRS voltages; variation of amplitude of QRS from beat-to-beat (called **QRS alternans**).

### CARDIAC TAMPONADE

**Basic description:** Compression of the heart due to an increase in fluid within the pericardial sac.

**Clinical presentation of cardiac tamponade**

- **Symptoms:** If slowly developing, dyspnea and fatigue; if rapidly developing, cardiogenic shock.
- **Signs**
  - **Pulsus paradoxus**, which is an exaggerated decrease in systolic pressure with inspiration. Systolic pressure normally decreases by as much as 10 mm Hg with inspiration due to negative intrathoracic pressure; the right ventricle distends but compression of the left ventricle is minimal. With cardiac tamponade, expansion of the right ventricle pushes on the interventricular septum more since the right ventricle cannot push into the pericardial sac. This additional pressure on the left ventricle by the right ventricle reduces systolic pressure.
  - QRS alternans.
  - Pulseless electrical activity (the heart generates electrical impulses but does not contract accordingly).

### CARDIAC TUMORS

**Overview of cardiac tumors:** Primary cardiac tumors are rare. Neoplasms with a propensity for cardiac metastases include malignant melanoma.

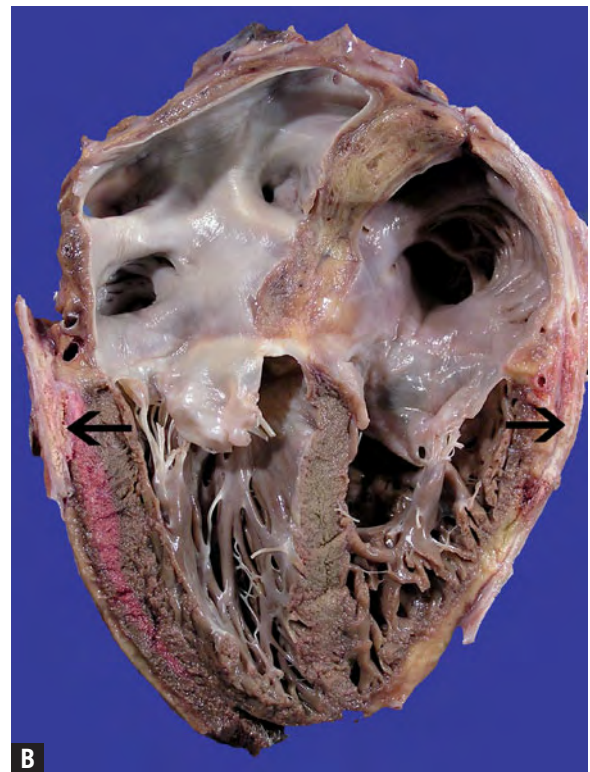
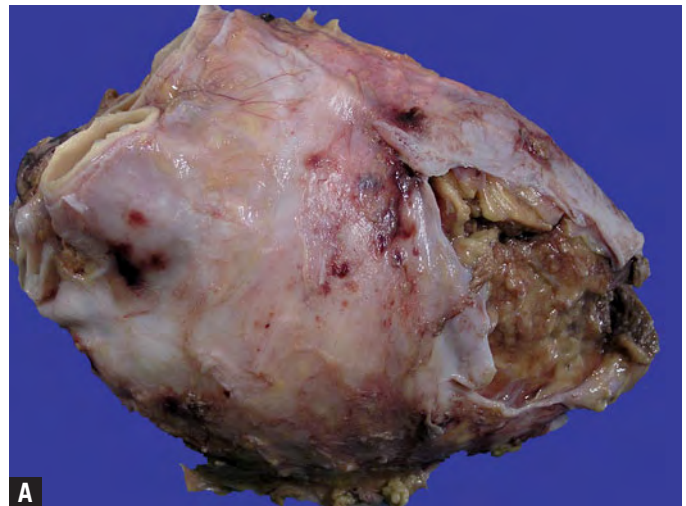
#### IMPORTANT POINTS REGARDING CARDIAC TUMORS

##### Atrial myxoma

- Most common primary tumor in adults.
- Usually benign.
- Usually in the left atrium.
- **Complications:** Embolization of fragments; obstruction of the mitral valve.

##### Rhabdomyoma

- Benign tumor of skeletal muscle.
- Associated with tuberous sclerosis.



**Figure 10-32. A and B.** Constrictive pericarditis. This patient had systemic lupus erythematosus, and presumably experienced multiple episodes of acute pericarditis. These episodes resulted in the formation of a dense fibrous and partially calcified band around the heart (**A**, and *arrows* in **B**). Because of the constrictive nature of the pericarditis, these patients can present with hemodynamic abnormalities similar to those seen in a restrictive cardiomyopathy.



# CHAPTER 11

## NEUROPATHOLOGY

### OVERVIEW

The central nervous system (CNS) is the body's major communication network. Because of localization of functions, neurologic deficits related to disease processes are variable in their presentation. In certain locations of the brain, a lesion will cause minimal or no symptoms, whereas in other areas, it will cause major neurologic deficits. CNS disease can present in many ways, including changes in consciousness, focal neurologic deficits (e.g., aphasia and amnesia, motor and sensory defects), headaches, dizziness, and seizures. Knowledge of the various neurologic pathways will allow a physician to localize the cause of the patient's symptoms.

CNS diseases are classified within one of many categories, including vascular diseases (e.g., infarcts and spontaneous hemorrhages), trauma, infections, neoplasms, degenerative diseases, toxic and metabolic disorders, and demyelinating diseases. Because the pathology of nervous system diseases is intimately related to their neurologic manifestations, this chapter will begin with a discussion of clinical presentations of central nervous system disorders. This will be followed by a discussion of basic pathologic changes, malformations, vascular diseases, traumatic disorders, infections of the CNS, neoplasms, degenerative diseases, demyelinating disorders, and, finally, a few basic peripheral nerve and skeletal muscle disorders.

### DISORDERS OF CONSCIOUSNESS

**Requirement for consciousness:** Intact and functioning brainstem reticular activating system and its cortical projections.

**Terminology for impaired levels of consciousness, in order of increasing severity**

- **Confusion:** Impairment of the capacity to think with normal speed and clarity, associated with inattentiveness and disorientation. Delirium is a special example of an acute confusional state in which impaired attention and reasoning are associated with agitation, hallucinations, and in some cases, tremor and convulsions.
- **Drowsiness:** Inability to remain awake without external stimulation; often associated with some degree of confusion.

- **Stupor:** State in which only vigorous external stimulation can arouse the patient; once aroused, responses remain markedly impaired.
- **Coma:** Deep sleep-like state; patient cannot be aroused even with vigorous or repeated external stimulation.

### Causes of change in consciousness

#### 1. With abnormal CT scan

- Hemispheric mass lesions that cross the midline or impinge upon the brainstem.
- Brainstem lesions that directly affect the reticular formation.
- Subarachnoid hemorrhage.

#### 2. With normal CT scan

- Inflammatory disorders, such as bacterial meningitis and viral encephalitis.
- Exogenous toxins, such as sedative drugs, alcohols, opioids, and carbon monoxide.
- Endogenous metabolic insults, such as global hypoxic-ischemic insults, hypoglycemia, hyperammonemia, and hypercalcemia.
- Postictal state.
- Selective brainstem ischemia.

**Diagnosis of cause of changes in consciousness:** Establishing a differential diagnosis for the cause of a patient's change in consciousness requires evaluation of the history preceding the change, the physical examination, and the effectiveness of initial empirical therapy.

### Categories of cause of changes in consciousness

- **Toxic and metabolic** (e.g., opiate overdose, alcohol).
- **Infectious** (e.g., meningitis, encephalitis, septic shock).
- **Cerebrovascular** (e.g., stroke).
- **Trauma.**
- **Other** (e.g., seizures, neoplasms).

### Role of history in diagnosis of changes in consciousness

- Preceding headache suggests meningitis, subarachnoid hemorrhage, or encephalitis.
- Preceding intoxication, confusion, or delirium suggests a diffuse process such as meningitis, endogenous metabolic insults, or exogenous toxins.
- Sudden onset of coma suggests brainstem infarct or hemorrhage (e.g., subarachnoid hemorrhage).

### Role of physical examination in diagnosis of changes in consciousness

- **Localizing signs:** Suggest focal lesion.
- **No localizing signs:** Suggests encephalopathy as a result of either an exogenous toxin or an endogenous metabolic insult.



## STRUCTURAL VERSUS METABOLIC CAUSES OF COMA

Asymmetrical or reflex functioning of the motor system indicates a focal mass lesion. Changes in pupillary size and reflexes are also useful in assessing the cause of coma.

- A unilaterally dilated nonreactive pupil suggests oculomotor nerve (CN III) compression by an expanding hemispheric mass.
- Pinpoint minimally reactive pupils suggests compromise of the pontine tegmentum (e.g., in a pontine hemorrhage); may also be seen in opiate intoxication. Small but reactive pupils are a feature of many metabolic encephalopathies.
- Minimally reactive pupils in a mid or slightly dilated position suggests a midbrain lesion.
- Bilaterally dilated, nonreactive pupils can be seen in cases of damage to the midbrain tectum or in global ischemic brain injury. It may also be caused by atropine and similar anticholinergic agents.

## LOCALIZED CORTICAL DEFECTS

**Overview:** Focal lesions within the brain can cause symptoms that help the physician localize the lesion to a specific site. These localizing cortical defects include weakness, visual changes, decreased sensation, and a few specialized conditions such as aphasia and amnesia, and others conditions including agnosia and apraxia. Aphasia and amnesia are described in this section.

### APHASIA

**Basic description:** Aphasia is impairment or loss of language function due to damage to language centers in the dominant hemisphere (usually the left). In addition to the two forms of aphasia (Broca and Wernicke aphasia) described below, there are many other forms, such as conduction aphasias caused by lesions to the arcuate fasciculus and global aphasia.

#### 1. Broca (expressive) aphasia

**Basic description:** Disorder of fluency of speech affecting both speech and writing. Patients speak with “broken sentences” but comprehension is intact.

**Association:** Contralateral arm and face weakness due to the proximity of Broca’s area to the motor cortex.

**Area involved to produce Broca aphasia:** Dominant hemisphere (usually left), inferior frontal lobe.

#### 2. Wernicke (receptive) aphasia

**Basic description:** Impairment of comprehension of written and spoken language. Patient can speak but sentences are meaningless (i.e., “wordy sentences”).

**Area involved to produce Wernicke aphasia:** Inferior superior temporal cortex of the dominant hemisphere.

### AMNESIA

**Overview:** In general terms, amnesia indicates the presence of a memory deficit. With **anterograde amnesia**, patients cannot form new memories. This type of amnesia commonly occurs

after cerebral trauma or with dementia. With **retrograde amnesia**, patients cannot recall past events. Areas of the brain most commonly affected in patients with amnesia include the hippocampus and the diencephalon (hypothalamus, thalamus). One specific form of amnesia discussed here is Korsakoff syndrome.

#### Korsakoff syndrome

- **Cause:** Untreated Wernicke encephalopathy (due to thiamine deficiency); most commonly associated with chronic alcoholism.
- **Symptoms:** Anterograde amnesia, confabulation, ophthalmoplegia, ataxia.

## HEADACHE

**Causes of primary headache:** Vascular (e.g., migraine), musculoskeletal, tension headaches, cluster headaches, sinus disease.

**Secondary causes of headache:** Conditions associated with increased intracranial pressure.

## DIZZINESS

**Terminology related to dizziness** (dizziness is a nonspecific term)

- **Vertigo:** Rotational sensation.
- **Presyncope:** Lightheadedness, near fainting, dimming of vision.
- **Disequilibrium:** Dysfunctional balance or gait.
- **Nystagmus:** Involuntary drifting eye movements accompanied by rapid corrective movement. Direction can be horizontal, vertical, rotatory, or mixed. Pure vertical nystagmus is almost always associated with a central lesion.

#### Forms of vertigo

- **Peripheral vertigo:** Affecting the inner ear, cochlear apparatus, or vestibulocochlear nerve (CN VIII). Vestibular neuromas are classic but uncommon. In peripheral lesions, the fast phase of nystagmus is away from the affected side.
- **Central vertigo:** Causes include ischemia, hemorrhage, or infarction; occasionally demyelinating diseases or mass lesions.

## SEIZURES

**Basic description of epilepsy:** Disease characterized by recurrent paroxysmal electrical discharges in the cerebral cortex known as “seizures.” Manifestations of seizures are variable and include abnormal motor activity, abnormal sensory experiences, and episodic changes in the level of consciousness.

**Epidemiology:** Seizures can begin at any time during the lifespan; 2–4% of the population has seizures.

**Causes of seizures:** The incidence of seizures has a bimodal distribution, with seizures in younger patients most often

related to epilepsy. The increase in incidence in the elderly population is most often related to cerebrovascular disease and stroke. Most primary seizure disorders are idiopathic and are labeled broadly as **epilepsy**. Secondary causes of seizures include traumatic brain injury, febrile seizures in children, and tumors.

**Absence seizures:** Common in children; characterized by staring spells, and classically associated with a 3 Hz “spike and wave” pattern on electroencephalogram (EEG).

## GENERAL MORPHOLOGIC CHANGES IN THE CNS IN RESPONSE TO INJURY

### Neuronal changes

- **Acute changes: “Red” neurons** (i.e., neurons with hyper-eosinophilic cytoplasm and pyknotic nuclei ([Figure 11-1](#)); usually caused by ischemic injury.
- **Subacute and chronic changes:** Neuronal loss, inclusions; causes are degenerative diseases.

### Astrocytic reactions

- **Gliosis:** Reactive astrocytes with prominent eosinophilic processes.
- Swelling.
- **Rosenthal fibers:** Brightly eosinophilic elongated structures occurring in response to long-standing gliosis as well as several slow-growing tumors.

**Microglial reactions:** Microglia are cells derived from bone marrow precursors. Accumulations of microglia occur in various patterns, including **foam cells** in demyelinating disorders and organizing necrosis, and **microglial nodules** (i.e., compact reactive clusters of microglial cells) in encephalitis.

## HYDROCEPHALUS AND RELATED DISORDERS

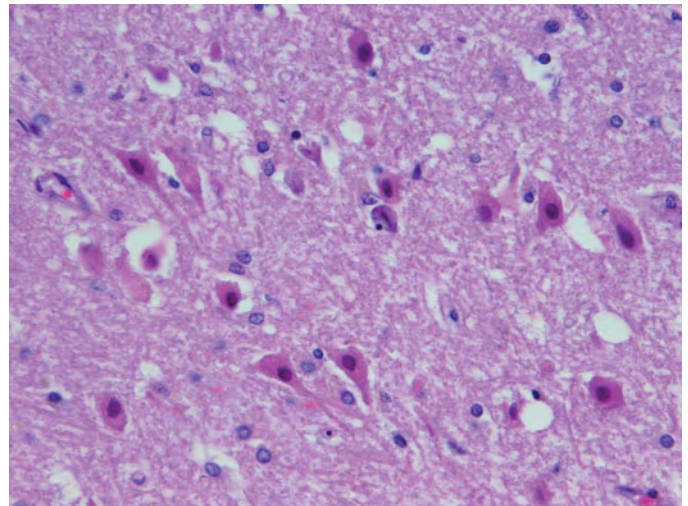
**Overview:** Hydrocephalus is dilation of the ventricular system and accumulation of excessive cerebrospinal fluid (CSF). It is most often due to impaired resorption of CSF, and is rarely due to overproduction of CSF.

### Forms of hydrocephalus

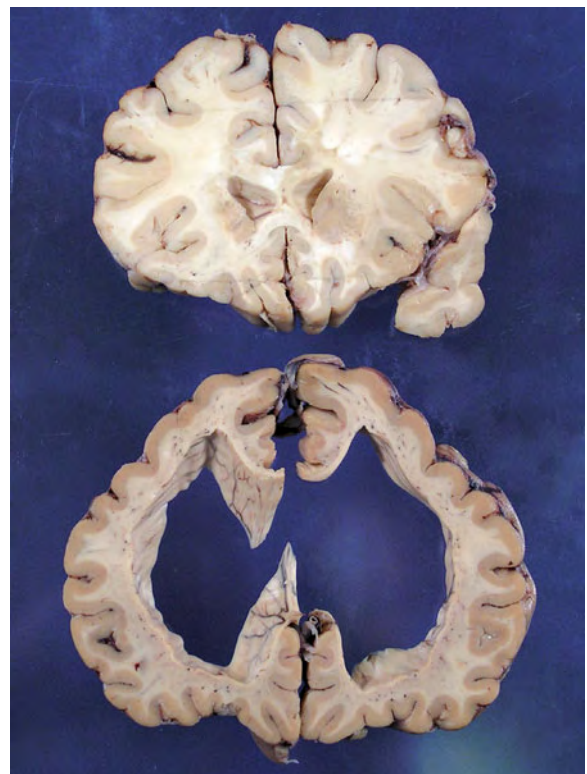- The two main forms of hydrocephalus are communicating and noncommunicating hydrocephalus, and the distinction between the two is based upon the location of obstruction to CSF flow ([Figure 11-2](#)). Communicating and noncommunicating hydrocephalus and hydrocephalus ex vacuo, which are general conditions due to one of several underlying causes, are discussed in this section. The other two forms of hydrocephalus mentioned below are specific conditions.

### Communicating hydrocephalus

- **Mechanism:** CSF is unable to drain from the subarachnoid granulations into the dural sinuses.
- **Causes:** Include remote meningitis with scarring; chronic subdural hemorrhage.



**Figure 11-1.** “Red neurons.” This photomicrograph illustrates many red neurons. Note the red cytoplasm and pyknotic nuclei. Red neurons are most often indicative of ischemic injury. Hematoxylin and eosin, 400×.



**Figure 11-2.** Hydrocephalus (*bottom*) versus the normal brain (*top*). Both sections in this image were taken from approximately the same region of two different brains. The section of the brain at the top is normal, and the section at the bottom exhibits marked hydrocephalus. Determining a communicating versus a noncommunicating hydrocephalus based upon one section of brain alone would be difficult unless a process such as fibrosis or hemorrhage were identified in the meninges (causing a communicating hydrocephalus), or the section included the lesion causing obstruction of the ventricular system (causing a noncommunicating hydrocephalus). In addition to obstructive processes, a loss of parenchyma may also cause enlargement of the ventricular system. Dilatation of the ventricular system secondary to tissue loss is usually referred to as hydrocephalus ex vacuo.



### Noncommunicating (obstructive) hydrocephalus

- **Mechanism:** An obstruction exists somewhere within the ventricular system.
- **Causes:** Include a tumor in the third ventricle or one that obstructs the foramen of Munro; a tumor of the cerebral aqueduct; or, in infants, a malformed or stenotic aqueduct.

### Hydrocephalus ex vacuo

- **Mechanism:** A compensatory dilation of the ventricles in response to a loss of cerebral parenchyma. Not typically associated with increased intracranial pressure.
- **Causes:** Include Alzheimer disease or a stroke.

**Normal pressure hydrocephalus:** Patients have dilated cerebral ventricles associated with a normal intracranial pressure. Normal pressure hydrocephalus causes dementia.

**Pseudotumor cerebri:** Classically seen in young obese females; presents as severe headache with papilledema and elevated intracranial pressure.

## CEREBRAL EDEMA AND HERNIATION

**Overview:** Because of the rigid nature of the cranial vault and dural reflections, the brain has only a limited space in which to expand. Expansion of the brain is associated with a variety of mechanical deformations, including flattening of the gyri (Figure 11-3) and several types of herniation patterns. Although cerebral edema can be a generalized process, expansion of the brain can occur as a local process due to a wide variety of causes, including neoplasms and hemorrhage.

### TYPES OF CEREBRAL EDEMA

**Overview:** The two types of cerebral edema are vasogenic and cytotoxic edema, both of which are explained below. However, in many clinical situations, edema is caused by both cytotoxic and vasogenic mechanisms.

#### 1. Vasogenic edema

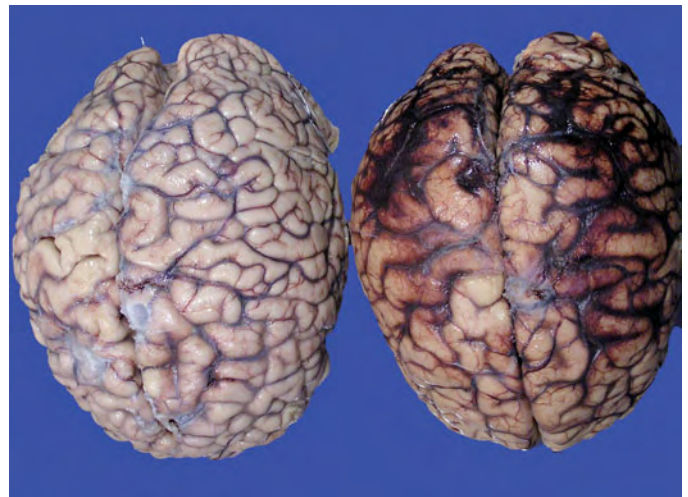
- **Basic description:** Edema occurring as a result of disruption of the integrity of the blood-brain barrier, allowing fluid to escape into the interstitial tissue. The brain has no lymphatics.
- **Examples:** Neoplasms, abscesses, infarcts.

#### 2. Cytotoxic edema

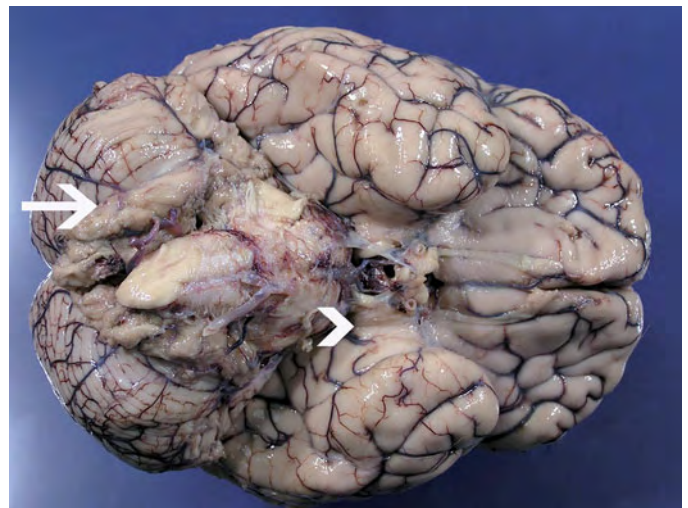
- **Basic description:** Increase in intracellular fluid due to cellular injury.
- **Examples:** Generalized ischemic injury, infarcts.

### Complications of cerebral edema

- **Cerebellar tonsillar herniation** (Figure 11-4): Cerebellar tonsils herniate down the foramen magnum and press on the brainstem. A cerebellar tonsillar herniation is almost always associated with damage to adjacent brainstem structures that control respiration and heart beat, and for that reason, this type of herniation is associated with a high mortality rate.



**Figure 11-3.** Cerebral edema due to subarachnoid hemorrhage versus the normal brain. The brain on the right side had a subarachnoid hemorrhage, which caused cerebral edema. Note the flattened gyri and narrowed sulci. In comparison, the gyral surfaces of the normal brain on the left are gently rounded, and the intervening sulci are well preserved.



**Figure 11-4.** Cerebellar tonsillar and uncal herniation. Increased intracranial pressure in this case has displaced the ventral portion of the cerebellum downward through the foramen magnum, compressing the cerebellar tonsils (arrow). The tonsillar parenchyma is soft and fragmented due to ischemic injury associated with mechanical compression. In addition, the uncal gyri, located on the medial aspect of each temporal lobe, have been pushed against the free leaflet of the tentorium cerebelli, causing prominent grooves to form in these structures (arrowhead).

■ **Uncal (transtentorial) herniation** (see Figure 11-4): The uncus (on the medial aspect of the temporal lobe) herniates under the tentorium cerebelli. The *uncus can compress the oculomotor nerve (CN III), compromising the parasympathetic fibers and resulting in ipsilateral pupillary dilation with associated ophthalmoplegia* (“down and out”). The uncus can also compress the posterior cerebral artery, causing an ipsilateral occipital lobe infarct (Figure 11-5). **Cheyne-Stokes respirations** are commonly seen with mesial temporal transtentorial herniation.

■ **Cingulate (subfalcine) herniation:** The cingulate gyrus herniates under the falx cerebri. The anterior cerebral artery may be compressed, causing an infarct of the frontal or parietal lobe in the midline.

■ **Transcalvarial herniation:** When cerebral edema develops in a patient after surgery or trauma, the brain can herniate through the surgical defect in the skull.

**Associated condition:** Secondary brainstem (**Duret**) hemorrhage.

■ **Mechanism of formation of Duret hemorrhage:** Kinking of branches of the basilar artery during downward displacement of the brainstem.

■ **Gross morphology:** Midline and paramedian streak-like hemorrhage in the brainstem, oriented dorsal to ventral (Figure 11-6).

## MALFORMATIONS

**Overview:** Most CNS malformations are classified in one of several categories, including neural tube defects, malformations associated with hydrocephalus (Chiari types I and II), disorders of forebrain development, and disorders of neuronal migration. Each of these categories will be discussed below, with examples of each.

### NEURAL TUBE DEFECTS

**Risk factors:** Include maternal folate deficiency, incompletely defined geographic and other environmental factors, and gender (incidence is greater in females than in males).

**Laboratory testing:** Increased level of  $\alpha$ -fetoprotein.

**Examples of neural tube defects: anencephaly and spina bifida**

1. **Anencephaly** (Figure 11-7)

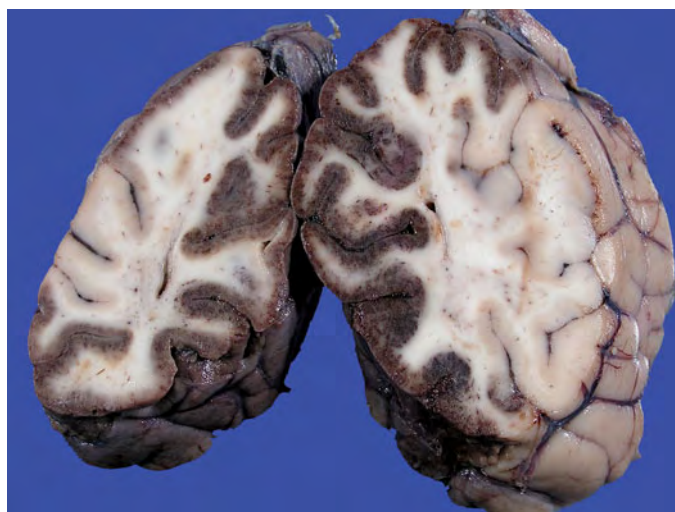
**Mechanism of formation:** Failure of closure of the anterior neuropore.

**Manifestation:** Failure of development of the brain and the calvarium.

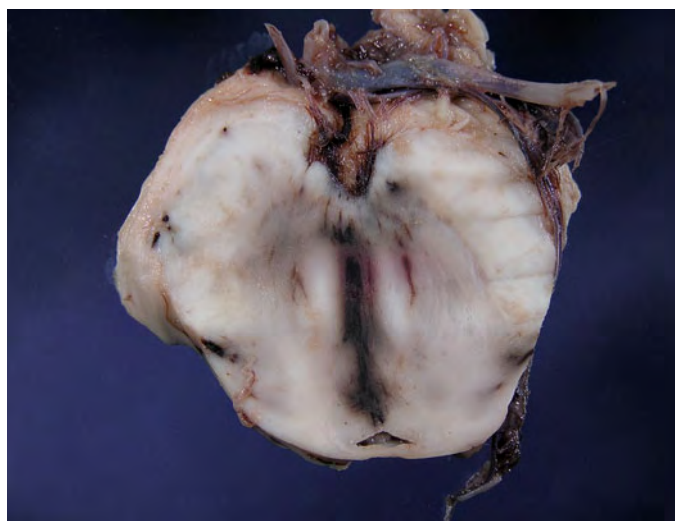
**Incidence:** 2–3 in 1000 live births.

2. **Spina bifida**

**Mechanism of formation:** The more severe forms of spina bifida are the result of failure of closure of the posterior neuropore. Less severe forms, such as **spina bifida occulta**, are the result of failure of secondary neurulation and failure of tail bud formation.



**Figure 11-5.** Bilateral occipital lobe infarcts due to uncal herniation. The red discoloration of the medial gray matter of both occipital lobes is secondary to ischemia induced by compression of the posterior cerebral arteries. Uncal herniation compresses the posterior cerebral arteries, and can also impinge upon the oculomotor nerve (CN III), damaging the parasympathetic nerves and causing ipsilateral pupillary dilation.



**Figure 11-6.** Duret hemorrhage. This section of the midbrain contains a secondary brainstem, or Duret hemorrhage, visible here as a midline linear focus of hemorrhage. A secondary brainstem hemorrhage is believed to result from downward displacement of the brainstem, resulting in kinking of branches of the basilar artery and hemorrhagic necrosis of the brainstem parenchyma supplied by these branches.

**Manifestation:** Varies from spina bifida occulta (i.e., incomplete vertebral arch) to **myelomeningocele**, which has prolapse of the meninges and spinal cord through the defect in the vertebral arch. The most common finding in spina bifida occulta is an abnormal growth of hair over the affected vertebral segment.

**Symptoms of spina bifida:** Some patients are asymptomatic, whereas other patients have motor and sensory dysfunction and poor bowel and bladder control. The symptoms manifested depend upon the severity of the defect.

### MALFORMATIONS ASSOCIATED WITH HYDROCEPHALUS (CHIARI TYPES I AND II)

#### 1. Chiari type I malformation

**Gross morphology:** Herniation of elongated segment of the inferior cerebellar vermis and paravermal folia through the foramen magnum.

**Complications:** Many patients are asymptomatic; however, the lesion is associated with cranial nerve abnormalities, sudden death, and, in adults, with cerebellar ataxia and late-onset hydrocephalus. Approximately 90% of cases of idiopathic syringomyelia (an abnormal cavity in the spinal cord) have an associated Chiari type I malformation.

#### 2. Chiari type II malformation

**Gross morphology:** Abnormally shallow posterior cranial fossa associated with a caudal “herniation” of the medulla and portions of the cerebellar vermis through the foramen magnum.

**Complications:** Hydrocephalus.

**Important point:** Almost all cases of Chiari type II malformations are associated with a meningocele in the lumbosacral spinal cord.

### DISORDERS OF FOREBRAIN DEVELOPMENT

**Overview:** Disorders of forebrain development include holoprosencephaly, agenesis of corpus callosum, and absence of septum pellucidum. Only holoprosencephaly will be discussed here.

#### HOLOPROSENCEPHALY

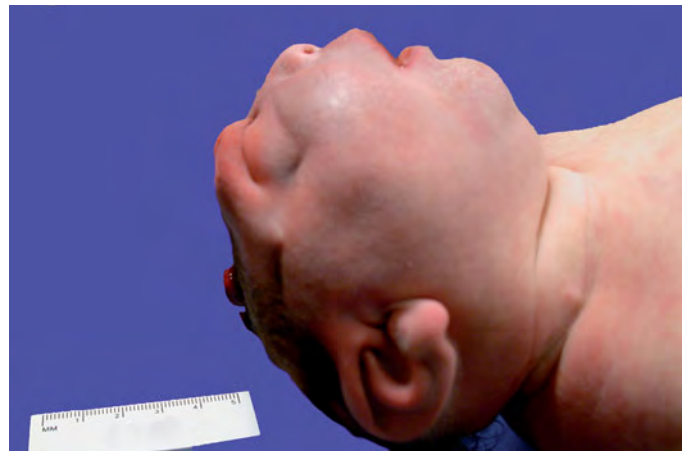**Basic description:** Malformation resulting from abnormal growth and separation of the developing forebrain.

**Incidence:** 1 in 30,000 births. Most cases are sporadic, but familial forms also occur.

**Risk factors:** Certain maternal and environmental factors (e.g., maternal diabetes mellitus, fetal alcohol syndrome, congenital infections), trisomy 13, and mutations in the *ZIC2* gene on chromosome 13q. Other cases of holoprosencephaly have been mapped to several additional genetic loci.

#### Morphology of three types of holoprosencephaly

■ **Alobar holoprosencephaly:** The brain has no hemispheric development. A rudimentary forebrain overlies a common ventricular cavity. The straight gyri, olfactory structures, and commissural structures (e.g., corpus callosum) are absent. There are also severe facial abnormalities (e.g., cyclopia).



**Figure 11-7.** Anencephaly. Anencephaly represents one of the most extreme forms of neural tube defect. In this lateral view, one can appreciate the nearly complete absence of the cranial vault and brain above the level of the ears and eyes. As might be expected, such extreme defects are incompatible with prolonged extrauterine survival.



- **Semilobar holoprosencephaly:** Some development of an interhemispheric fissure; straight gyri, olfactory structures, and corpus callosum usually are still absent.
- **Lobar holoprosencephaly:** Interhemispheric fissure is present, and individual lobes are distinguishable; however, there is some continuity of the cerebral cortex in the midline and aplasia or dysplasia of the corpus callosum.

### DISORDERS OF NEURONAL MIGRATION

- **Agyria (lissencephaly):** The brain is virtually devoid of surface convolutions expected for age.
- **Pachygyria:** Reduced numbers of gyri, and gyri present are abnormally broad.
- **Polymicrogyria:** Numerous abnormally convoluted gyri.
- **Other disorders of neuronal migration:** Neuronal heterotopias, white matter heterotopias.

### ACQUIRED CNS ABNORMALITIES IN NEONATES

**Overview:** Primary malformations may be difficult to distinguish from acquired injury, because prior to 16 weeks' gestational age, the brain does not mount the usual reaction to injuries. Germinal matrix hemorrhage, periventricular leukomalacia, porencephaly, and multicystic encephalopathy are discussed in this section.

**Germinal matrix hemorrhage:** Hemorrhage occurring in premature infants (see Chapter 7).

#### Periventricular leukomalacia (PVL)

- **Morphology:** Chalky discoloration of the white matter associated with hemorrhage and cavitation.
- **Risk factors:** Hyaline membrane disease, shock, sepsis, and congenital heart disease.
- **Important point:** PVL is often seen in association with cerebral palsy.

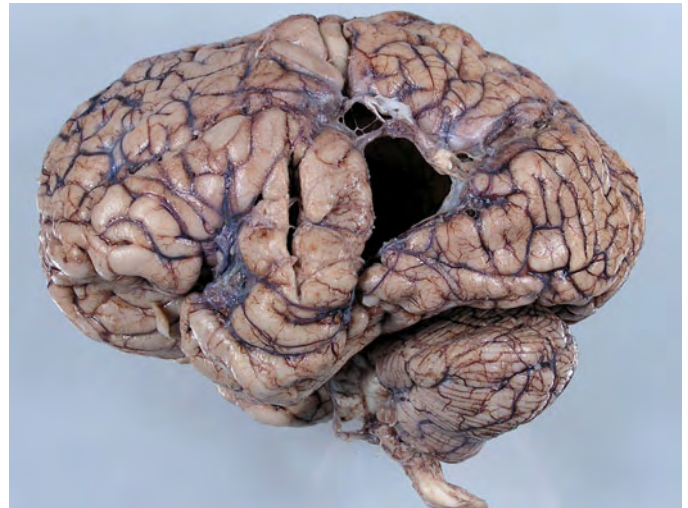
**Porencephaly:** Cystic defect with a smooth contour that allows the ventricular system to communicate with the subarachnoid space (Figure 11-8). Most examples likely represent sequelae of intrauterine ischemic injury early in gestation.

**Multicystic encephalopathy:** Irregularly distributed cystic lesions that lack a smooth contour. Lesions develop due to injury later in gestation than injury that causes porencephalic defects.

### VASCULAR MALFORMATIONS

#### Arteriovenous malformation

- **Morphology:** Mass of enlarged arteries, veins, and hybrid channels, with intervening nervous tissue.
- **Epidemiology:** 10–30 years of age; male predominance.
- **Location:** Most occur along the distribution of the middle cerebral artery.
- **Complications of arteriovenous malformation:** Seizure disorder, intracerebral hemorrhage, subarachnoid hemorrhage.



**Figure 11-8.** Porencephaly. Porencephaly is caused by ischemic injury to the developing fetal brain. Note the large defect in the left cerebral hemisphere that allows the ventricular system to communicate with the subarachnoid space.

**Cavernous angioma:** Dilated venous spaces (no arterial component) with no intervening nervous tissue; these malformations may bleed.

**Capillary angioma:** Proliferation of small diameter blood vessels; most are asymptomatic.

## VASCULAR DISEASES

**Overview:** Cerebrovascular disease is the third main cause of death in adults. The most common causes are thrombosis, emboli, and hemorrhage. Cerebrovascular disease can be generalized, as might be seen following cardiac arrest (global hypoxic ischemic encephalopathy), or it can be localized (cerebral infarct). The term “**stroke**” is used to designate the sudden onset of a localized, nonconvulsive, neurologic deficit. Strokes can be caused by either a cerebral infarct or a primary (non-traumatic) hemorrhage. Stroke, global hypoxic-ischemic encephalopathy, cerebral infarcts, and intracerebral hemorrhage will be discussed in this section.

### STROKE

**Basic description of stroke:** Term used when CNS symptoms begin suddenly and persist for more than 24 hours. As noted, strokes can be caused by ischemic injury or by primary hemorrhage; 80% are ischemic in origin.

**Basic description of transient ischemic attack (TIA):** Brief episode of neurologic dysfunction relating to a specific vascular bed that lasts less than 24 hours. TIAs are usually caused by small emboli. The risk of having a future stroke following a TIA is 15% within 1 year and 25% within 2 years.

**Clinical presentation of stroke:** Acute spontaneous onset of central, localizing, neurologic dysfunction of more than 24 hours’ duration.

### GLOBAL HYPOXIC-ISCHEMIC ENCEPHALOPATHY

**Basic description:** Condition resulting from generalized poor perfusion of the brain, and hence is probably more properly termed “ischemic” encephalopathy. Some areas of the brain are more sensitive than others.

**Cause:** Global cerebral ischemia.

**Areas most commonly affected by global hypoxic-ischemic encephalopathy in adults**

- Arterial borderzone areas (i.e., regions between the distribution of the cerebral arteries).
- Hippocampus (particularly the so-called CA1 region of the pyramidal cell layer).
- Purkinje cells and dentate nucleus in cerebellum.
- The basal ganglia and thalamus are other common sites of injury.

**Morphology of global hypoxic-ischemic encephalopathy**

- **Gross:** Appearance depends upon time period since injury; can have edema, dusky red discoloration (particularly if there has been reperfusion), and **laminar cortical necrosis**

(midcortical layer neurons are most susceptible to ischemic injury). In the cerebral cortex, ischemic injury is almost always more pronounced at the depths of sulci than in the gyral crests.

- **Microscopic:** At 12–24 hours, “red” neurons (i.e., neurons with eosinophilic cytoplasm and pyknotic nuclei). There is usually minimal host inflammatory reaction due to lack of perfusion of the brain.

### CEREBRAL INFARCTS

**Basic description:** Focal irreversible brain injury resulting from a localized loss of blood flow.

#### Causes of cerebral infarcts

- In the anterior circulation, most commonly middle cerebral artery territory, infarcts are usually due to emboli from atherosclerotic plaques in the carotid arteries.
- In the posterior circulation, infarcts are usually from thrombi due to atherosclerosis. Vasculitis (either infectious or noninfectious) and trauma are less common causes.

#### Types of cerebral infarcts

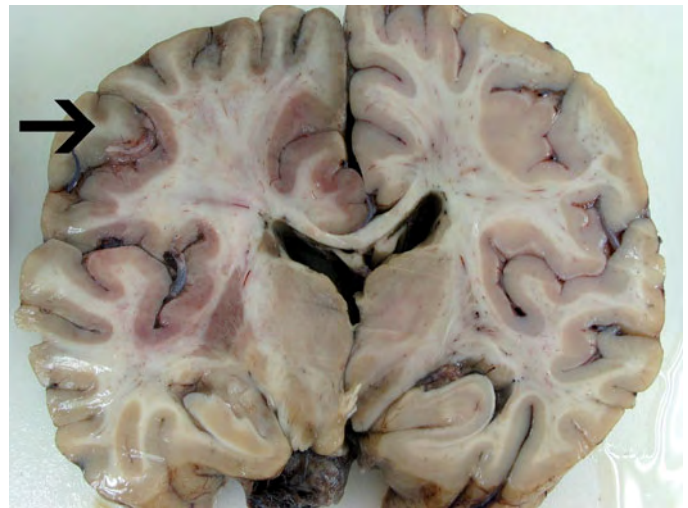
- **Hemorrhagic infarct:** Causes are usually emboli or conditions associated with compression of the vessels such as herniations.
- **Nonhemorrhagic infarct:** Cause is usually thrombi.

#### Three stages of morphologic development of a cerebral infarct (Table 11-1)

- Acute.
- Organizing (changes develop beginning about day 3).
- Remote (changes develop within 6 months after infarct).

#### Morphology of acute infarcts

- **Gross:** Soft parenchyma with preservation of architecture. Hemorrhagic infarcts have petechial hemorrhages and larger hemorrhages as a result of reperfusion (Figure 11-9).
- **Microscopic:** Red neurons and rarefaction of white matter (within 12–24 hours) are associated with a neutrophilic infiltrate. In hemorrhagic infarcts, there are extravasated red blood cells as a result of reperfusion.



**Figure 11-9.** Acute cerebral infarct. Much of the left cerebral hemisphere is expanded by an area of acute necrosis in the distribution of the left middle and anterior cerebral arteries. Note the subtle dusky discoloration of much of the medial, superior, and lateral cerebral cortex on the left (*black arrow*) caused by leakage of small amounts of blood into the necrotic parenchyma (some of the red discoloration in the deeper areas of the brain is caused by incomplete fixation of the necrotic tissue). The infarct was caused by a surgical procedure that compromised the left internal carotid artery. Microscopic examination of the infarct at this stage would reveal red neurons. Also note herniation of the left cingulate gyrus and left uncus, which was caused by edema associated with the infarct.

**TABLE 11-1.** Morphology of Cerebral Infarct

Stage of Infarct	Gross	Microscopic
Acute	Poorly defined area of soft parenchyma; preservation of architecture	Red neurons Rarefaction of white matter
Organizing	Well-defined area of soft, friable parenchyma; loss of architecture	Sheets of foamy macrophages
Remote	Cystic lesion	Gliosis at periphery



### Morphology of organizing infarcts

- **Gross:** Soft, friable parenchyma with loss of architecture; the lesion becomes more sharply defined over time (Figure 11-10).
- **Microscopic:** Foamy macrophages containing engulfed myelin debris begin to infiltrate within 48–72 hours and remain in the area for about 6 months (Figures 11-11 to 11-13).

### Morphology of remote infarcts

- **Gross:** Cystic lesion (Figure 11-14).
- **Microscopic:** Gliosis. If the infarct is near the cortical surface, there is subpial sparing because the subpial parenchyma receives its oxygen and nutrients from the CSF and meningeal vessels.

**Clinical presentation of infarcts:** Symptoms depend upon the size and location of the infarct.

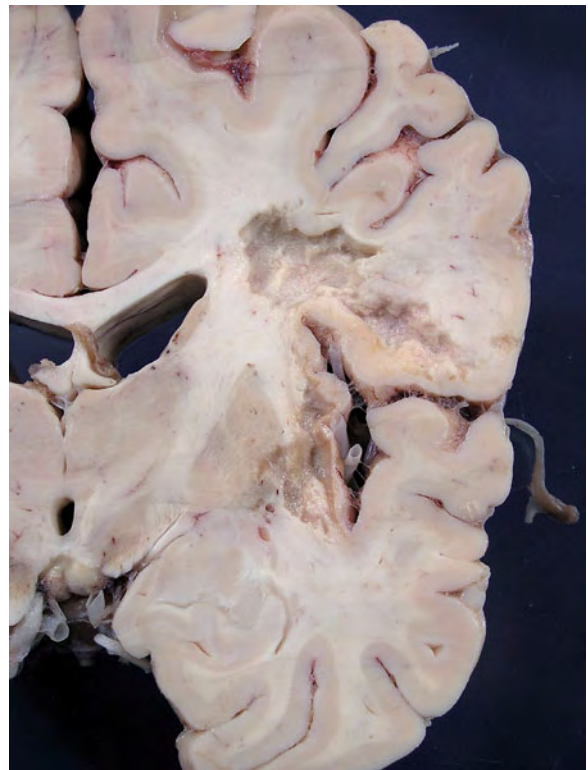
- **Middle cerebral artery distribution:** Contralateral hemiparesis and hemisensory loss; the face and upper extremity are more affected than the lower extremity; aphasia if the infarct involves the dominant cerebral hemisphere.
- **Anterior cerebral artery distribution:** Contralateral hemiparesis and hemisensory loss; the lower extremity is more affected than the upper extremity.
- **Posterior cerebral artery distribution:** Contralateral hemiparesis, homonymous hemianopsia, amnesia, sensory loss.
- **Basilar artery distribution:** Quadriparesis, dysarthria, dysphagia, diplopia.

**Diagnosis of cerebral infarct:** CT scan, MRI.

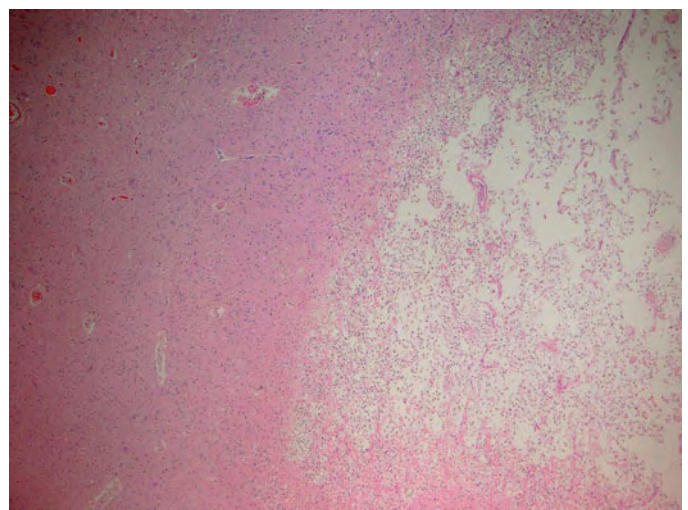
### Two special forms of infarcts

#### 1. Borderzone infarcts

- **Basic description:** Infarcts occurring at the boundary between two vascular distributions; for example, at the edge between the anterior and middle cerebral artery distributions.
- **Causes:** Hypotension is the most common cause.



**Figure 11-10.** Organizing cerebral infarct. In the area of the right insula is a well-demarcated cystic lesion involving the insular cortex, fronto-parietal white matter, and portions of the basal ganglia. This process is an organizing cerebral infarct. The lesion is well demarcated because the sheets of macrophages, which are engulfing dead neurons and broken-down myelin, end abruptly at the viable tissue. Once the dead tissue is completely removed, only a cavity will remain.



**Figure 11-11.** Organizing cerebral infarct. This lower power photomicrograph illustrates an organizing cerebral infarct. The right side of the image has sheets of lipid-laden macrophages, and the left side of the image has viable white matter. Note the clear line of demarcation between the two components. Hematoxylin and eosin, 40×.

## 2. Lacunar infarcts

- **Basic description:** Small (<1.0 cm) infarcts.
- **Locations:** Commonly in the basal ganglia and brainstem (Figure 11-15).
- **Cause:** Usually associated with hypertension.
- **Clinical presentation of lacunar infarcts:** Most patients are asymptomatic, but those with symptoms commonly have pure motor hemiparesis due to a defect in the internal capsule. Lacunar infarcts can also cause weakness and ataxia.

## INTRACEREBRAL HEMORRHAGE

**Basic description:** Hemorrhage within the cerebral parenchyma.

**Location:** More than 50% are centered on the basal ganglia and the thalamus; the next most common regions affected are the pons and the cerebellum. Intracerebral hemorrhage can also originate in the deep white matter (Figure 11-16).

**Causes of intracerebral hemorrhage:** Most commonly due to hypertension (50% of cases); can also result from **cerebral amyloid angiopathy** (in the elderly), vasculitis, systemic coagulation abnormalities, tumor, overlying contusions, and arteriovenous malformations.

### Types of intracerebral hemorrhage

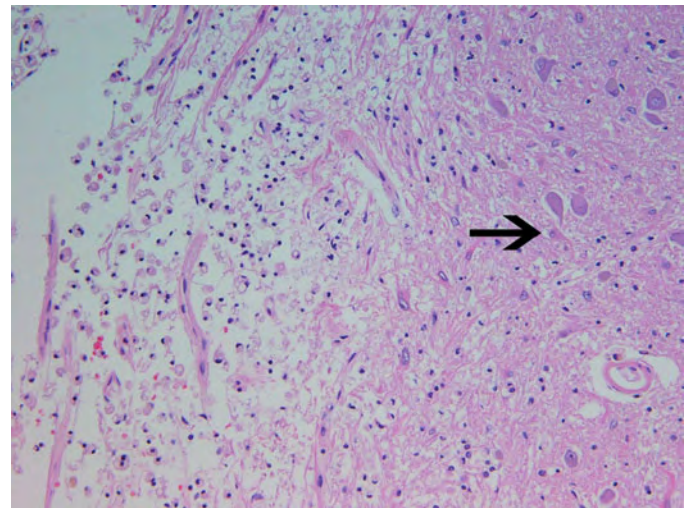
- **Ganglionic:** Centered on the basal ganglia and the thalamus; the main cause is hypertension.
- **Lobar:** In lobes of the cerebral hemisphere; causes include hemorrhagic diatheses, neoplasms, infections, and cerebral amyloid angiopathy.

**Mechanism of intracerebral hemorrhage:** In hypertension, elevated blood pressure over time is thought to cause the formation of small (<300  $\mu$ m) aneurysms (i.e., **Charcot-Bouchard aneurysms**) that rupture; these are extremely difficult to demonstrate in clinical practice.

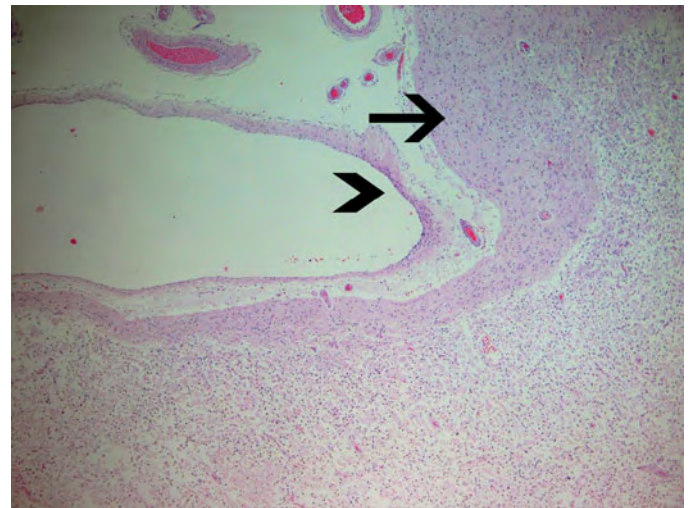
**Important point:** If an intracerebral hemorrhage occurs, blood can rupture through the cortical surface, causing a subarachnoid hemorrhage and possibly a subdural hemorrhage. Also, the intracerebral hemorrhage can rupture into the ventricular system, exit the foramen of Luschka and Magendie, and cause a basilar subarachnoid and subdural hemorrhage. Other more common causes of subarachnoid and subdural hemorrhage are discussed below.

### Clinical presentation of intracerebral hemorrhage

- **Symptoms of hypertensive intracerebral hemorrhage:** Headache (the severity of the headache correlates with the size of the hemorrhage); decreased alertness (as a result of mass effect); seizures.
- **Diagnosis:** CT scan and MRI (CT is more sensitive in acute hemorrhages, and MRI is more sensitive in detecting old hemorrhages).



**Figure 11-12.** Organizing cerebral infarct. This higher power photomicrograph of an organizing cerebral infarct better shows the cellular morphology, with lipid-laden macrophages to the left side of the image and viable neurons on the right side of the image. In the white matter, at the junction, are a few astrocytes with prominent eosinophilic stellate cytoplasmic processes (*arrow*). The term “gliosis” is often used to designate an accumulation of reactive astrocytes of this type. Hematoxylin and eosin, 200 $\times$ .



**Figure 11-13.** Organizing cerebral infarct with subpial sparing. The subpial gray matter (*arrow*) receives its nutrients from meningeal vessels and cerebrospinal fluid, and thus survives ischemic injury induced by thrombosis or an embolus involving the cerebral arteries. The arrowhead indicates the pia mater. Underlying the subpial white matter is an organizing cerebral infarct containing sheets of lipid-laden macrophages. This pattern of subpial sparing is sometimes helpful in distinguishing infarcts from contusions of the brain. Hematoxylin and eosin, 40 $\times$ .



### Other CNS sequelae of hypertension

- **Lacunar infarcts:** Most commonly of the basal ganglia and the brainstem; due to arteriolar sclerosis of deep penetrating arteries.
- **Slit hemorrhages:** Small slit-like intracerebral hemorrhage with resolution and resorption of blood and subsequent deposition of hemosiderin.
- **Hypertensive encephalopathy**
  - **Symptoms:** Headache as a result of edema and increased intracranial pressure; confusion, vomiting, and coma.
  - **Cause:** Markedly elevated blood pressure.

## EXTRACEREBRAL HEMORRHAGE

**Overview:** Extracerebral hemorrhage is hemorrhage that occurs outside the cerebral parenchyma, over and between the coverings of the brain. There are three types of extracerebral hemorrhage: epidural, subdural, and subarachnoid.

### EPIDURAL HEMORRHAGE

**Cause:** Trauma.

**Mechanism:** Fracture of the temporal bone lacerates the middle meningeal artery and bleeding occurs (Figure 11-17 A and B).

**Complications:** Causes a midline shift and herniation and death.

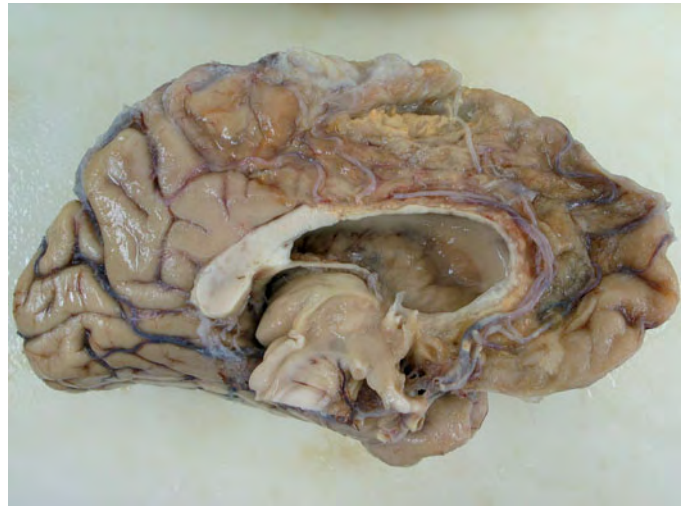#### Clinical presentation of epidural hemorrhage

- **History:** Injury with “lucid interval.” The dura inhibits blood flow, so symptoms take time to develop (minutes to hours).
- **Signs and symptoms:** Neurologic deterioration in minutes to hours following the injury.
- **Diagnosis:** CT scan (the hemorrhage appears as a biconvex disk that does not cross suture lines) and MRI.

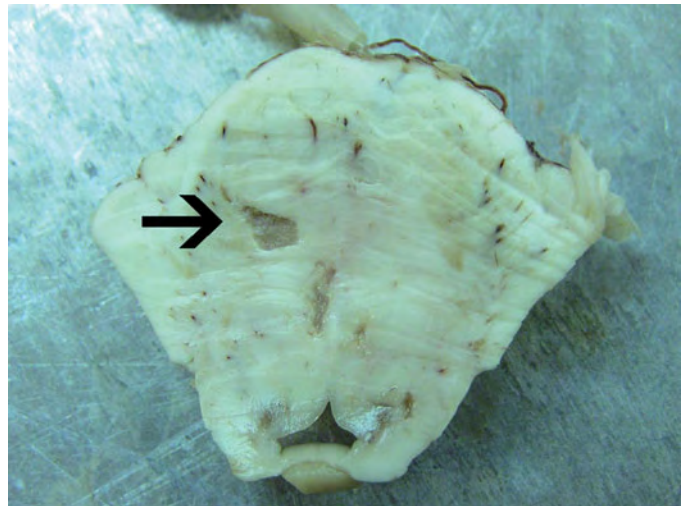
### SUBDURAL HEMORRHAGE

**Causes:** Usually traumatic in origin.

**Mechanism:** Tearing of bridging veins that connect the cerebral hemispheres to the dural vessels and the superior sagittal sinus.



**Figure 11-14.** Remote cerebral infarct. In the distribution of the left anterior cerebral artery is a remote cerebral infarct involving the medial aspect of the cerebral hemisphere. Remote cerebral infarcts are cavitory, as gliosis does not produce a macroscopically appreciable scar. In the photograph, the cavity has collapsed, imparting an irregular contracted appearance to the surface of the hemisphere.



**Figure 11-15.** Lacunar infarct of the pons. The arrow indicates a lacunar infarct. Lacunar infarcts are small ( $< 1.0$  cm) and can be the result of hypertensive cardiovascular disease. Because of their small size, most lacunar infarcts are asymptomatic.



In the elderly and alcoholics, cerebral atrophy leads to elongation of the distance the bridging veins must cross between the cortical surface and the dural sinuses (Figure 11-18 A and B).

**Location:** Most are at convexities; 10% are bilateral.

#### Types of subdural hemorrhage

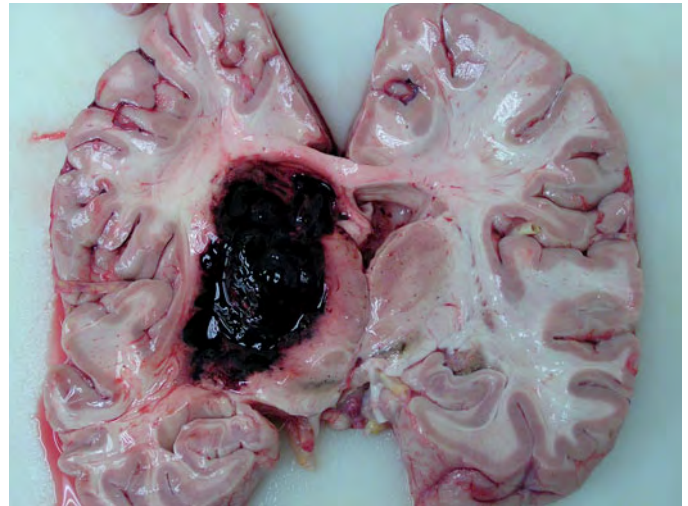
- **Acute subdural hemorrhage:** Rapid accumulation of blood leads to a midline shift and herniation and death. Patients may have focal neurologic signs or generalized symptoms such as confusion and headache.
- **Chronic subdural hemorrhage:** Accumulation of blood is not enough to cause death. The hemorrhage organizes and forms a membrane between the hemorrhage and the dura mater and between the hemorrhage and the arachnoid mater. A chronic subdural hemorrhage can cause psychiatric symptoms and communicating hydrocephalus secondary to obstruction of the arachnoid granulations.

#### Morphology of subdural hemorrhage

- **Gross:** Hemorrhage underlying the dura. Acute subdural hemorrhages are blood clots. Chronic subdural hemorrhages are in various stages of healing, depending upon the time period since their development, but are adherent to the dura and not to the arachnoid.
- **Microscopic**
  - Lysis of clot at 1 week.
  - Fibroblast growth into hemorrhage at 2 weeks.
  - Connective tissue proliferation at 1–3 months.

#### Clinical presentation of subdural hemorrhage

- **Signs and symptoms:** Patients have loss of consciousness following trauma, and with return of consciousness, they often have cognitive impairment.
- **Diagnosis:** CT scan (a subdural hemorrhage is crescent-shaped and crosses suture lines) and MRI.



**Figure 11-16.** Acute intracerebral hemorrhage. Centered on the left basal ganglia is an intracerebral hemorrhage. Intracerebral hemorrhages are most commonly due to underlying hypertension, and most often occur at the basal ganglia.

## SUBARACHNOID HEMORRHAGE

**Causes:** Most common cause overall is trauma, but the most common cause of a nontraumatic (spontaneous) subarachnoid hemorrhage is a ruptured **berry (saccular) aneurysm** (Figures 11-19 and 11-20).

**Other causes of subarachnoid hemorrhage:** Include rupture of intracerebral hemorrhage into ventricles, vascular malformations, tumors, and hemorrhagic diatheses.

### Subarachnoid hemorrhage due to ruptured berry aneurysm

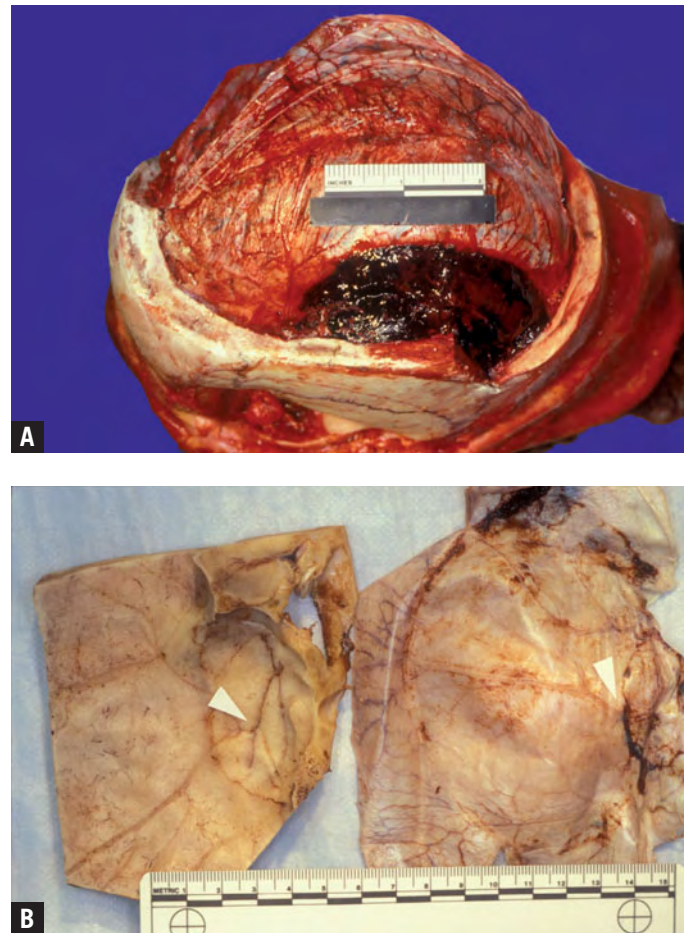
- **Basic description of berry aneurysm:** Rounded to lobulated sac-like dilatation of an artery, usually at arterial branch points.
- **Locations:** Branch points of intracranial arteries. The most common location is in the anterior circulation (90% of aneurysms) of the circle of Willis (see Figure 11-20).
- **Mechanism of formation:** The etiology is most likely congenital weakness of the media of the arterial wall but other factors, including hypertension, smoking, and alcohol abuse, may contribute to their growth and eventual rupture. Berry aneurysms are never seen in pediatric patients.
- **Important points regarding berry aneurysm**
  - Berry aneurysms may occur as an isolated lesion, and also are associated with polycystic kidney disease, Ehlers-Danlos syndrome, neurofibromatosis type 1 (NF-1), Marfan syndrome, and arteriovenous malformations.
  - The risk of rupture of a berry aneurysm increases with size (>10 mm have 50% chance of rupture within 1 year). One third of ruptures occur in situations of increased intracranial pressure (exercise, intercourse, straining at stool).

### Complications of subarachnoid hemorrhage

- **Death:** High mortality rate (30–40%).
- Can lead to communicating hydrocephalus.
- Can cause cerebral infarcts because of vasospasm induced by an irritating effect of extravasated red blood cells on the cerebral vasculature.

### Clinical presentation of subarachnoid hemorrhage due to ruptured berry aneurysm

- **Symptoms:** “Worst headache of life,” meningismus (neck stiffness due to meningeal irritation), vomiting, loss of consciousness, seizures.
- **Diagnosis:** Revealed by MRI or CT scan in 95% of cases; occasionally require lumbar puncture, which reveals bloody CSF.



**Figure 11-17.** Acute epidural hemorrhage. **A**, The scalp is reflected and the cranial vault removed, revealing a loosely adherent hematoma on the outer surface of the dura overlying the left cerebral hemisphere. **B**, The left side of the image shows the inner surface of the cranium. The white arrowhead indicates the point where the fracture line crosses the course of the middle meningeal artery. The right side of the image shows the outer surface of the dura mater. The white arrowhead indicates the point at which the middle meningeal artery was torn (compare to the inner surface of the skull). Courtesy of Dr. Gary Dale, Forensic Science Division, Montana State Department of Justice, Missoula, MT.

## TRAUMATIC LESIONS OF THE CEREBRAL PARENCHYMA

**Overview:** Trauma to the CNS can have several sequelae, including a seizure disorder, dementia, and hydrocephalus. The hydrocephalus is secondary to impaired CSF flow as a result of blockage of subarachnoid granulations by fibrosed subarachnoid hemorrhage. Two forms of cerebral contusions (coup and contrecoup), diffuse axonal injury, and concussion will be discussed in this section.

### COUP CONTUSION

**Basic description:** Contusions (i.e., bruising of the brain) occurring at the point of impact.

**Cause:** Usually due to a blow to the head.

### CONTRECOUR CONTUSION

**Basic description:** Contusions on the side of the brain opposite the point of impact.

**Causes:** Usually due to a fall in which the head strikes the ground. Contrecoup contusions are most commonly due to falling and hitting the back of the head, with the contusions occurring on the inferior surface of the frontal and temporal lobes (Figure 11-21). Most commonly occur in alcoholics or the elderly,

**Complications of cerebral contusions:** Include seizures and post-traumatic intracerebral hemorrhage (i.e., **lobar hemorrhage**).

#### Gross morphology of cerebral contusions

- **Acute:** Wedge-shaped hemorrhage at the crests of gyri; edema.
- **Chronic:** Yellow-brown well-circumscribed depressions of variable depth.

#### Microscopic morphology of cerebral contusions

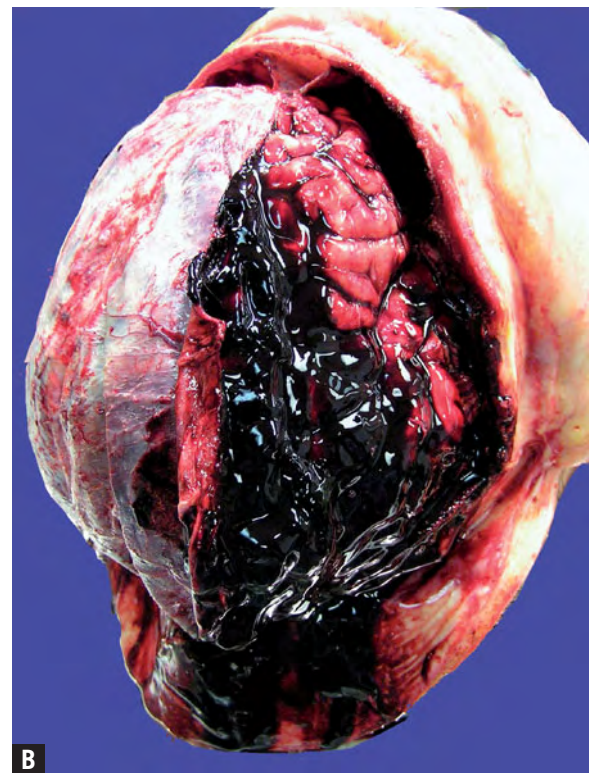
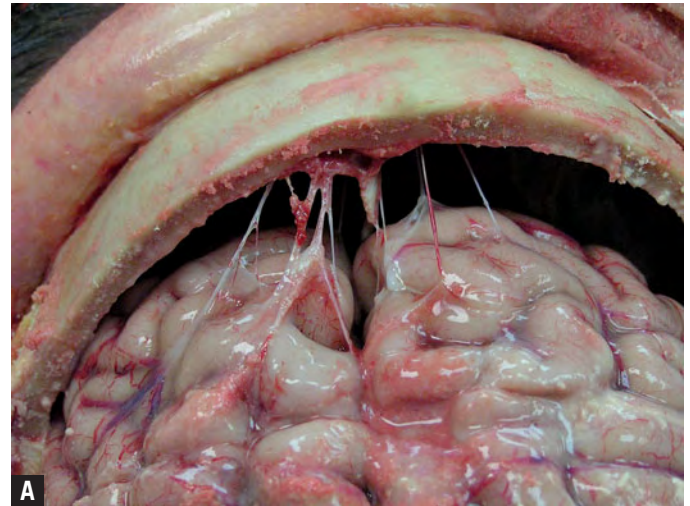
- **Acute:** Extravasated red blood cells; red neurons (after 12–24 hours).
- **Chronic:** Hemosiderin deposition; gliosis.

### DIFFUSE AXONAL INJURY

**Basic description:** Injury due to shearing, stretching, and possibly tearing of the axons by angular acceleration or deceleration forces.

**Locations:** Corpus callosum, hippocampus, and dorsolateral brainstem (i.e., cerebral peduncles, superior colliculi).

**Complications:** Death; persistent vegetative state.



**Figure 11-18.** Acute subdural hemorrhage. **A**, The normal brain in this section (i.e., without subdural hemorrhage) has been mildly retracted posteriorly during removal, highlighting the bridging veins. Tearing of a bridging vein is the mechanism by which a traumatic subdural hemorrhage occurs. **B**, Covering the right cerebral convexity is clotted blood (the dura mater has been partially retracted to the midline to better view the clot). An acute subdural hemorrhage has not organized and is not appreciably adherent to the dura, and thus easily falls away from the brain (as is evident in the photograph). An acute subdural hemorrhage, if large enough, can produce a mass effect, potentially causing cerebral herniations.



### Morphology of diffuse axonal injury

■ **Gross:** Punctate hemorrhages in the corpus callosum or the dorsolateral brainstem.

■ **Microscopic:** Axonal spheroids (globular, eosinophilic structures), which stain with  $\beta$ -amyloid precursor protein (Figure 11-22).

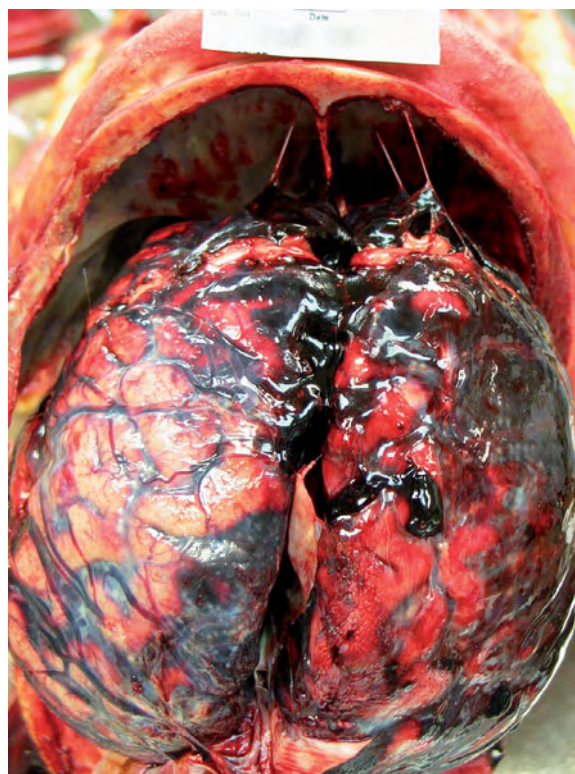
**Clinical presentation of diffuse axonal injury:** Abrupt loss of consciousness following head trauma.

### CONCUSSION

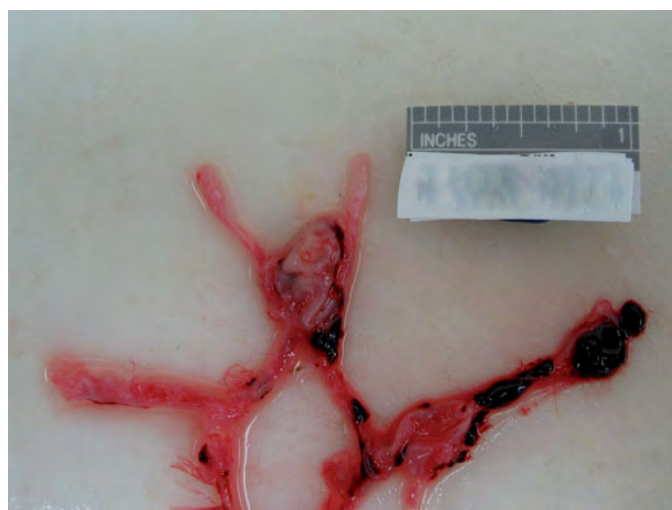**Basic description:** Head injury causing temporary loss of consciousness and reflexes; can have residual amnesia. There are no visible pathologic injuries (considered grade 0 diffuse axonal injury).

### CNS INFECTIONS

**Overview:** The three main forms of CNS infections are meningitis, brain abscesses, and encephalitis. The routes by which the brain and meninges can become infected include hematogenous, direct implantation, local extension, and spread along the peripheral nervous system.



**Figure 11-19.** Subarachnoid hemorrhage. In contrast to the subdural hemorrhage in Figure 11-18, the hemorrhage in this photograph is tightly applied to the brain because it is under the arachnoid mater. Compared to an acute subdural hemorrhage, in a subarachnoid hemorrhage, the amount of blood required to cause death is far less. Subarachnoid hemorrhages often do not cause significant mass effect; instead, presumably because of the irritating and compressive nature the subarachnoid blood has on cerebral vessels, they cause vasoconstriction and resultant ischemia.



**Figure 11-20.** Berry (saccular) aneurysm. Arising from the junction of the anterior communicating cerebral artery and the left anterior cerebral artery is an approximately 1.0 cm aneurysm. Most berry aneurysms occur within the cerebral vessels derived from the internal carotid system, and most commonly arise at arterial branch points.

## MENINGITIS

**Basic description:** Inflammation of the leptomeninges and subarachnoid space.

### Types and causes of meningitis

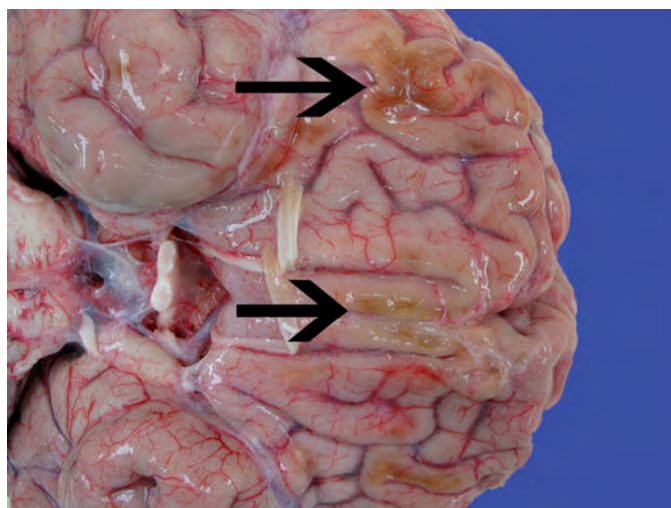
- **Acute purulent (pyogenic) meningitis:** Usually bacterial in origin. Causes by age group are listed in [Table 11-2](#).
- **Acute lymphocytic (aseptic) meningitis:** Viral in origin; commonly echovirus, coxsackie, mumps, or human immunodeficiency virus (HIV).
- **Chronic meningitis** (bacterial or fungal): Causes include tuberculosis, *Cryptococcus*, or dimorphic fungi.
- **Chemical meningitis:** Causes include an irritating parameningeal process such as a tumor or abscess, or a foreign substance such as air, or medications.

### Complications of meningitis

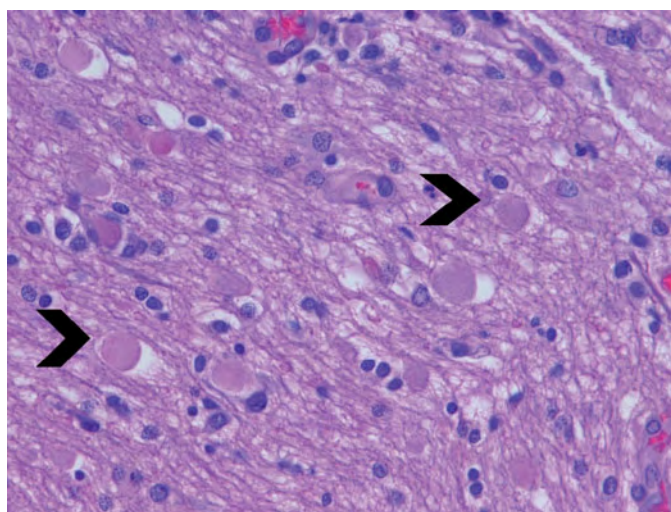
- **Bacterial meningitis:** Scarring with resultant communicating hydrocephalus, mental retardation, seizures, or focal cranial nerve deficits. Acute bacterial meningitis can cause death.
- **Viral meningitis:** Usually resolves with no complications, unless accompanied by encephalitis.

### Important points regarding meningitis

- In children, *Haemophilus influenzae* was at one time the most common cause of bacterial meningitis; however, the development of an effective vaccine has greatly reduced its incidence.
- Meningitis usually remains localized to the meninges and does not involve the cerebral parenchyma, unless the pia or blood-brain barrier is damaged (e.g., old head injuries).



**Figure 11-21.** Remote cerebral contusions. The arrows indicate shallow, irregular depressions on the inferior surface of the left and right frontal lobes. The yellow-brown discoloration of the rims of the depressions is from hemosiderin deposition. Based upon the location, these lesions most likely represent remote contrecoup contusions, occurring as a result of a fall and landing on the back of the head.



**Figure 11-22.** Diffuse axonal injury. The arrowheads indicate spheroids. Spheroids are axonal swellings associated with diffuse axonal injury. Diffuse axonal injury is most commonly associated with severe head injury; however, spheroids can also occur as a result of ischemic, infectious, and various other processes. Hematoxylin and eosin, 400 $\times$ .

**TABLE 11-2.** Causative Organisms of Meningitis by Age Group

Age Group	Causative Organism
Neonate	<i>Escherichia coli</i> , group B <i>Streptococcus</i> , <i>Listeria monocytogenes</i>
Children, young and old adults	<i>Streptococcus pneumoniae</i> , <i>Haemophilus influenzae</i>
Epidemics in young adults in crowded living conditions (e.g., college dormitories and military barracks)	<i>Neisseria meningitidis</i>

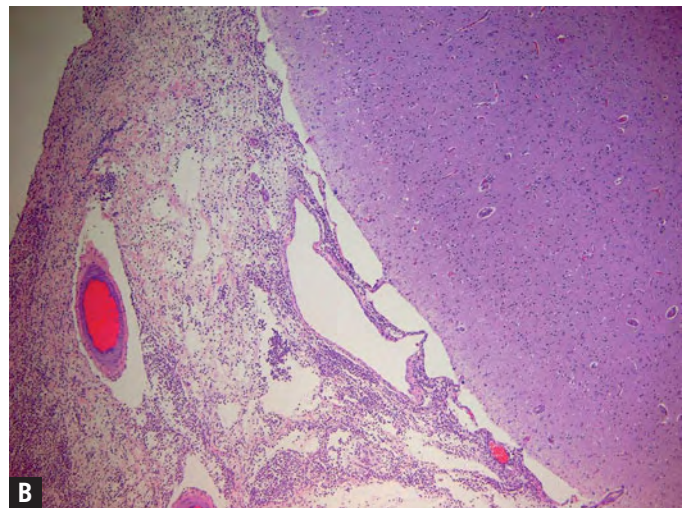
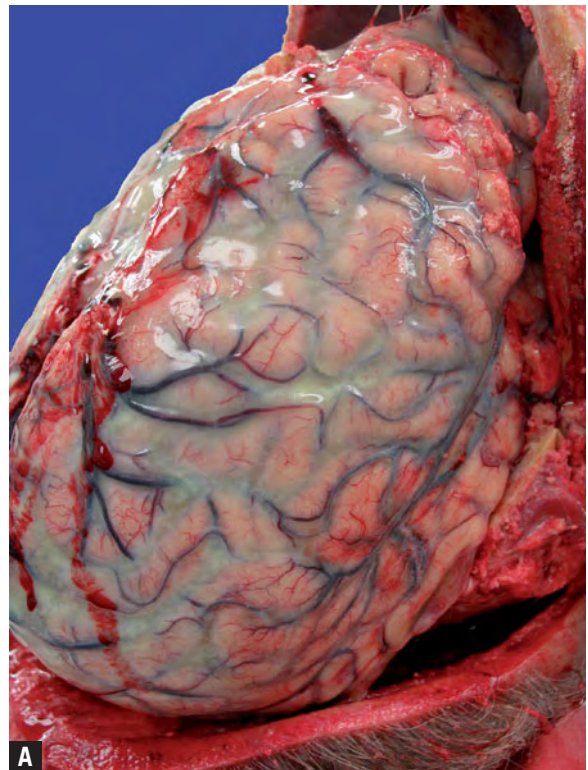


**Gross morphology of meningitis:** The morphology can depend upon the pathogen, as described below.

- **Acute bacterial meningitis:** In *Streptococcus pneumoniae*, purulent exudates on the cerebral convexities (Figure 11-23 A and B); *H influenzae* is classically associated with basal exudates; and *Neisseria meningitidis* often has considerably less exudates grossly than meningitis caused by *S pneumoniae* infection. *N meningitidis* infection is often associated with a cutaneous petechial rash and hemorrhage into the adrenal glands (referred to as **Waterhouse-Friderichsen syndrome**).
- **Tuberculous meningitis and meningitis caused by dimorphic fungi:** Classically associated with a thick basilar exudate, and often accompanied by acute infarcts of underlying brain parenchyma.
- **Cryptococcal meningitis:** Gelatinous slick material in leptomeninges; usually no associated exudate.
- **Acute lymphocytic meningitis:** Parenchyma may be edematous; leptomeninges are usually clear.

**Microscopic morphology of meningitis:** As with the gross morphology, the microscopic morphology depends upon the pathogen.

- **Bacterial:** Neutrophilic infiltrate.
- **Mycobacterial and dimorphic fungal:** Can have granulomas and giant cells; commonly associated with inflammation and thrombosis of the penetrating arteries.
- **Cryptococcal meningitis:** Numerous budding yeasts with little if any associated inflammation. Mucicarmin stain is used to identify organisms in tissue sections (Figure 11-24). India ink is used in CSF smears.
- **Viral:** Lymphocytic infiltrate; many organisms have associated parenchymal inflammation (encephalitis).



**Figure 11-23.** Acute purulent bacterial meningitis. **A**, The yellow-green discoloration centered around the vessels at the convexity of the right cerebral hemisphere represents an acute bacterial meningitis caused, in this case by *Streptococcus pneumoniae*. **B**, This low-power photomicrograph depicts the cortical surface and meninges. The meninges are expanded by a cellular infiltrate, which is composed predominantly of neutrophils. Hematoxylin and eosin, 40 $\times$ .



### Important points regarding morphology of meningitis

■ **Tuberculosis** (and dimorphic fungi): Usually basilar in location (Figure 11-25). Heal with fibrosis, which can involve the brain (**meningoencephalitis**), cranial nerves, and blood vessels (**obliterative endarteritis**), with resultant complications (e.g., ischemia from obliterative endarteritis).

■ ***S pneumoniae*** usually involves the convexities.

**Symptoms of meningitis:** In general, meningeal irritation causes headache, neck stiffness, photophobia, and altered mental status.

■ **Bacterial meningitis:** Headache, fever, meningismus, photophobia; can have cranial nerve deficits.

■ **Viral meningitis:** Can have the same symptoms as with bacterial meningitis.

■ **Fungal meningitis:** Infections are more indolent. Patients may have only headache and a decreased level of consciousness. In cryptococcal meningitis, in particular, classic “meningeal” symptoms and signs are often absent.

**Signs of meningitis:** Passive flexion of the neck results in reflex flexion of one or both knees (**Brudzinski sign**); neck pain with knee extension while the hip is flexed (**Kernig sign**).

**Diagnosis of meningitis:** Analysis of CSF obtained by lumbar puncture (Table 11-3).

### Brain abscess (Figure 11-26)

#### Causes

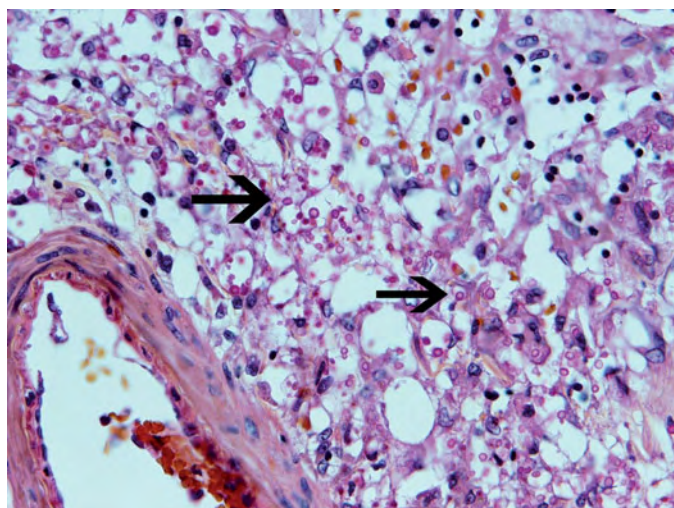
■ **Hematogenous dissemination** (e.g., from bacterial endocarditis, or in patients with cyanotic congenital heart disease with right-to-left shunt, which allows infectious emboli to bypass lungs, a phenomenon known as “**paradoxical embolism**”).

○ **Organisms:** *Staphylococcus*, *Streptococcus*.

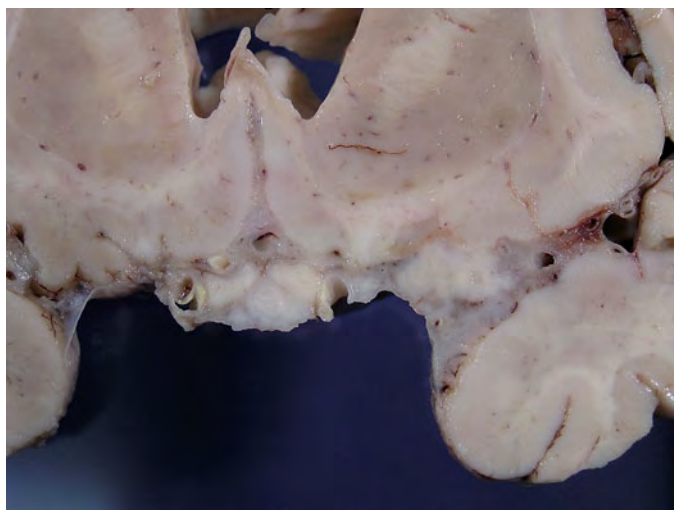
○ **Locations:** Frontal lobe more commonly than the parietal lobe, which is affected more commonly than the cerebellum.

■ **Local extension** (e.g., from sinusitis, otitis media).

■ **Implantation.**



**Figure 11-24.** Cryptococcal meningitis. This high-power photomicrograph of the meninges, stained with mucicarmine, highlights encapsulated and budding yeast forms. In cryptococcal meningitis, an opportunistic disorder most commonly associated with HIV infection, there is minimal inflammatory reaction. The capsule of *Cryptococcus neoformans* stains with mucicarmine (arrows). Mucicarmine, 400×.



**Figure 11-25.** Basilar meningitis. The vessels and cranial nerves are encased by a thick white-tan inflammatory exudate. Basilar meningitis is most commonly associated with *Mycobacterium tuberculosis*; however, dimorphic fungi can also produce a similar picture. The causative agent in this case was *Coccidioides immitis*.

### Clinical presentation of brain abscess

- **Signs and symptoms due to local destructive effects:** Hemiparesis, aphasia, personality changes, seizures, ataxia, and visual disturbances.
- **Signs and symptoms due to mass effect causing increased intracranial pressure:** Headache, nausea and vomiting, papilledema, and cranial nerve palsies.
- **Diagnosis:** A CT scan or MRI will reveal a ring-enhancing mass, which is characteristic of an abscess. A brain biopsy will rule out a neoplasm.

## ENCEPHALITIS

**Basic description:** Inflammation of cerebral parenchyma, which is often viral in origin, including arboviruses, herpes simplex virus (HSV), cytomegalovirus (CMV), and HIV.

### HSV-1 encephalitis

- **Epidemiology:** Children and young adults; most common cause of sporadic encephalitis in adults in the United States.
- **Symptoms:** Alterations in mood, memory, and behavior related to temporal lobe involvement.

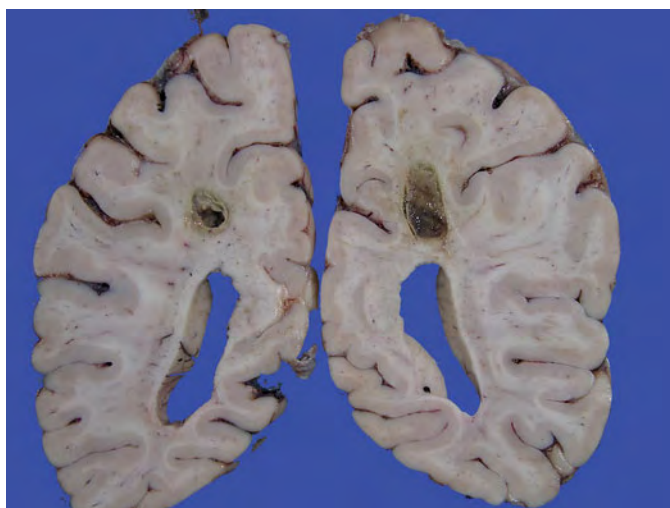
**HSV-2 encephalitis:** May cause meningitis in adults or a more generalized encephalitis; most common cause of encephalitis in neonates.

**HIV encephalitis:** Occurs in HIV-infected individuals, usually in later stages of HIV infection.

**CMV encephalitis:** Occurs in the fetus and in immunosuppressed patients.

### Rabies encephalitis

- **Epidemiology:** Most commonly follows bite by an infected animal.
- **Symptoms:** Paresthesias at the site of the bite; hypersalivation and hydrophobia. CNS hyperexcitability leads to respiratory failure.



**Figure 11-26.** Brain abscess. Both the right and left parietal lobes of this brain contain abscesses with shaggy yellow-green linings. Cavitation in abscesses is caused by the activity of neutrophils, which liquefy the affected tissue. Multiple abscesses suggest an embolic process such as endocarditis as the underlying cause. Abscesses may also occur following implantation of bacteria into the brain in traumatic injuries, or following spread of organisms from a contiguous site of infection (e.g., paranasal sinuses).

**TABLE 11-3.** Laboratory Analysis of CSF for Infectious Meningitis

Type of Meningitis	CSF Pressure (mm CSF)	WBC Count (in cells/ $\mu$ L)	Protein (mg/dL)	Glucose (mg/dL)
Bacterial	200–500	100–10,000	50–500	Absent; or greatly decreased
Tuberculosis	200–500	10–500	50–500	< 40
Viral	200–500	10–500	45–200	Normal
Normal CSF	50–200	0–10	< 45	50–80

CSF, cerebrospinal fluid; WBC, white blood cells.

### Microscopic morphology of encephalitis

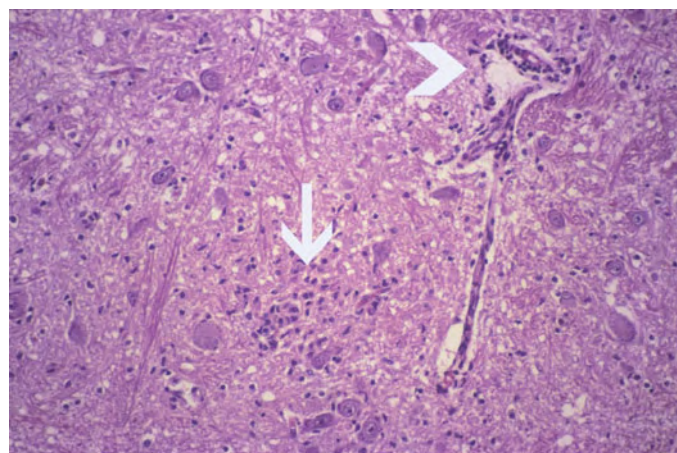
#### Three general nonspecific features (Figure 11-27)

- Microglial nodules.
- Lymphocytic cuffing of vessels (in Virchow-Robin space).
- Neuronophagia (i.e., engulfment/destruction of neurons by inflammatory cells).

#### Specific microscopic features for certain pathogens

- **HSV:** Intranuclear inclusions; usually involves inferior and medial temporal lobes and orbital gyri.
- **HIV:** Multinucleated giant cells.
- **CMV:** Intranuclear (“owl’s eye”) inclusions; may also have intracytoplasmic inclusions. CMV may involve ependyma and subependymal white matter, causing hemorrhagic necrotizing ventriculo-encephalitis and choroid plexitis.
- **Rabies:** Round to oval eosinophilic cytoplasmic inclusions (i.e., **Negri bodies**) in pyramidal neurons of the hippocampus and the Purkinje cells of the cerebellum. “Bullet-shaped” virion seen on electron microscopy.

**Important point:** Some viruses (e.g., arboviruses, West Nile virus, and poliovirus) lack specific intranuclear or intracytoplasmic inclusions.



**Figure 11-27.** Encephalitis. Two common features of encephalitis, namely microglial nodules (*arrow*) and lymphocytes in the Virchow-Robin spaces (*arrowhead*) are visible in this image. Viral infections are responsible for most cases of encephalitis. Hematoxylin and eosin, 200 $\times$ .

## SPONGIFORM ENCEPHALOPATHIES

**Overview:** Conditions associated with prion proteins. Specific conditions include **Creutzfeldt-Jakob disease (CJD)**, variant CJD (the human counterpart of bovine spongiform encephalopathy, or “mad cow disease”), Gerstmann-Straüssler-Scheinker syndrome, and fatal familial insomnia.

**Epidemiology:** Most cases of spongiform encephalopathy are sporadic. Peak incidence of classic CJD is in the seventh decade of life.

**General pathogenesis:** The prion protein ( $\text{PrP}^c$ ) is a normal structural protein (in an  $\alpha$ -helix configuration) found in the nervous system; the gene is on chromosome 20. Prion-associated disease occurs when the normal structural protein is exposed to a structurally abnormal protein ( $\text{PrP}^{\text{sc}}$ ), which takes on the abnormal configuration ( $\beta$ -pleated sheet) and is then capable of transforming other normal proteins.

#### Three specific mechanisms by which the abnormal protein can be acquired

- **Sporadic:** Random conformational change of normal protein to abnormal protein. It is the most common cause of CJD, accounting for 90% of cases.
- **Hereditary:** Inheritance of a gene that encodes an unstable prion protein that has a greater propensity to undergo a spontaneous conformational change to  $\text{PrP}^{\text{sc}}$ .
- **Transmitted:** Infectious forms; can be iatrogenic (e.g., as a result of transplantation of certain  $\text{PrP}^{\text{sc}}$ -infected tissues into a normal host, or the use of inadequately disinfected neurosurgical instruments contaminated with  $\text{PrP}^{\text{sc}}$ ).



**Complications of spongiform encephalopathies:** Rapidly progressive dementia, death.

### Morphology of CJD

- **Gross:** The brain may have a normal external appearance; in advanced cases, it may be atrophic.
- **Microscopic:** Spongiform transformation of the cortex and deep gray matter (i.e., vacuoles within neurons and in surrounding neuropil).

### Clinical presentation of CJD

- **Symptoms:** Subtle changes in memory and behavior, progressing to rapid dementia. Patients also have **startle myoclonus** (i.e., involuntary jerking spasms of muscles), ataxia, and cortical blindness.
- **Laboratory testing:** 14-3-3 protein in CSF (not present in all cases).
- **EEG:** Diffuse slowing and periodic sharp waves and spikes.
- **Diagnosis:** Biopsy and autopsy are confirmatory.

## TUMORS OF THE CNS

**Overview:** Brain tumors may originate within the CNS (primary CNS neoplasms), or they may metastasize to the brain from extracranial sites. The major types of primary CNS tumors are gliomas (i.e., astrocytomas, oligodendrogliomas, ependymomas), poorly differentiated neuroectodermal neoplasms (e.g., medulloblastomas), and meningiomas (Table 11-4). Less commonly, tumors may be composed of more

**TABLE 11-4.** CNS Neoplasms

Neoplasm	Age	Location	Mutation	Histologic Features
Astrocytoma	Any; represent 80% of primary adult brain tumors	Cerebral hemispheres	In primary GBM, EGFR, MDM2, and PTEN	Grading is based upon pleomorphism, mitotic figures, necrosis, and microvascular proliferation
Pilocytic astrocytoma	Any; more common in children	Any; common in cerebellum, third ventricle		Hair-like cell processes; Rosenthal fibers
Oligodendroglioma	4th–5th decades	Cerebral hemispheres	LOH 1p, 17q	Round cells with perinuclear halos; satellitosis
Ependymoma	Any age	Periventricular; spinal cord	Associated with NF2	Pseudorosettes and rosettes
Medulloblastoma	Peak at age 7 years	Cerebellar vermis in children; cerebellar hemispheres in adults	i17q	Small round cell tumor; Homer-Wright rosettes
Meningioma	Adults	Cranial vault; spinal cord	Associated with NF2	Whorls; psammoma bodies

CNS, central nervous system; GBM, glioblastoma multiforme; EGFR, epidermal growth factor receptor; PTEN, phosphatase and tensin homologue; LOH, loss of heterozygosity; NF, neurofibromatosis.

mature neurons. Almost all of the metastatic tumors that occur in the CNS are carcinomas or melanomas. Carcinomas of the lung and breast account for most of the metastatic carcinomas.

In adults, CNS neoplasms arise most commonly above the tentorium cerebelli. Common CNS tumors in adults include metastatic carcinomas, infiltrating glial neoplasms, and meningiomas. In contrast, in the pediatric population, tumors arise more commonly in the infratentorial region and are almost always primary. Glial tumors and primitive neuroectodermal neoplasms account for most of the brain tumors in this population. Most brain tumors have no known cause (i.e., there are no known risk factors), although a minority are associated with hereditary conditions (e.g., NF-2).

### Histologic versus biologic malignancy

- Histologic malignancy is determined by the tumor's ability to cause ill effects based upon its cellular anaplasia (i.e., mitotic figures, hyperchromasia, pleomorphism) and its ability to invade and metastasize. Interestingly, even histologically malignant primary CNS neoplasms rarely metastasize.
- Biologic malignancy is based upon the tumor's ability to cause ill effects based upon its location or products. For example, a histologically bland noninvasive meningioma can still be lethal, based upon its ability to expand within a confined space and eventually cause herniation.

## CLINICAL PRESENTATION OF TUMORS OF THE CNS

### 1. Mechanisms for clinical presentation of tumors

- Expansion and compression of the brain by a tumor mass or associated edema.
- Infiltration of cerebral parenchyma.

### 2. General symptoms (resulting from a mass effect)

- **Headache:** Most common general symptom. When caused by brain tumors, the headaches are usually worse in the morning or in situations that increase intracranial pressure.
- Changes in personality.
- Projectile vomiting: Common in children, rare in adults.
- Seizures.

### 3. Focal symptoms, which result from localized disruption of cerebral parenchyma and depend upon location of tumor.

- **Frontal location:** Personality changes; impaired concentration and memory.
- **Parietal location:** Spatial disorientation; aphasia.
- **Temporal location:** Personality changes; complex partial seizures.

### 4. Diagnosis

- MRI is more sensitive at evaluating the posterior fossa and in detecting infiltration of the cerebral parenchyma. However, CT is superior to MRI for detecting calcified lesions.
- Biopsy.

## ASTROCYTOMAS

**Several types:** Include fibrillary, pilocytic, and pleomorphic xanthoastrocytoma.

**Forms of fibrillary astrocytomas:** All are *infiltrative lesions*! In increasing order of aggressiveness, these lesions range from WHO grade II to WHO grade IV.

- **Well-differentiated astrocytoma** (WHO grade II).
- **Anaplastic astrocytoma** (WHO grade III).
- **Glioblastoma multiforme (GBM)** (WHO grade IV).

**Epidemiology:** May occur at any age; peak incidence is between the fourth and sixth decades. Represent about 80% of primary adult brain tumors.

**Location:** Most commonly cerebral hemispheres, but they may occur at other sites (e.g., brainstem).

### Mutations found in primary (“de novo”) GBMs

- **Basic description of primary GBM:** Arise in older patients; no preexisting lower grade tumor.
- **Mutations:** Have *EGFR* (epidermal growth factor receptor) amplification; *MDM2* and *PTEN* (phosphatase and tensin homologue) overexpression.

### Mutations found in secondary GBMs

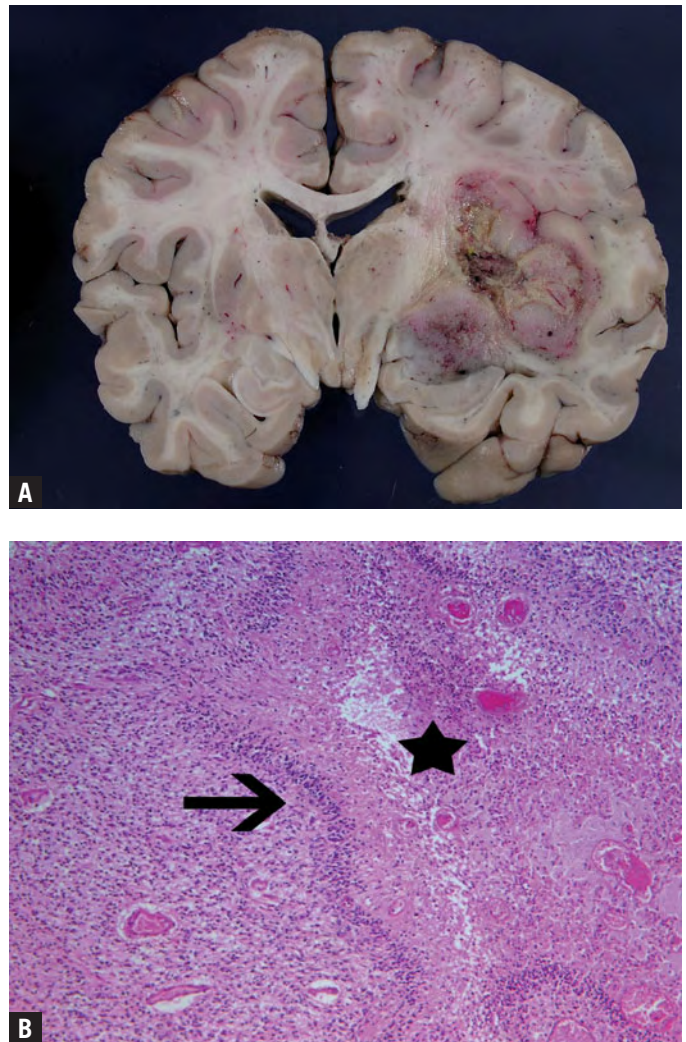
- **Basic description of secondary GBM:** Arise from preexisting lower grade astrocytomas. Generally occur in younger patients than do primary GBMs.
- **Mutations:** Have inactivation of *p53*; overexpression of *PDGF-A*.

### Important points regarding astrocytomas

- Well-differentiated astrocytomas are virtually impossible to completely excise. Patients can live 5–10 years after diagnosis of the tumor.
- GBM: Highly aggressive; median survival is approximately 12 months.

### Morphology of astrocytomas (Figure 11-28 A and B)

- **Gross:** Infiltrative and ill-defined expansion of involved parenchyma with blurring of normal landmarks. GBMs often contain grossly apparent areas of necrosis and hemorrhage.
- **Microscopic criteria for differentiation of astrocytomas:** Based upon pleomorphism, mitotic figures, necrosis, and/or microvascular proliferation. The finding of necrosis and/or microvascular proliferation in an infiltrating astrocytic neoplasm indicates the presence of a grade IV neoplasm (GBM). Necrosis in GBMs is often associated with pseudopalisading of neoplastic cells around the necrosis.



**Figure 11-28.** Glioblastoma multiforme (GBM). **A**, The right cerebral hemisphere is expanded by an irregularly contoured mass containing areas of necrosis (yellow) and small areas of hemorrhage. Although this lesion appears fairly well demarcated in this gross photograph, GBMs are aggressive astrocytic neoplasms that widely infiltrate the surrounding brain. **B**, The distinction between the various grades of infiltrating astrocytic neoplasms is based upon four histologic features: nuclear pleomorphism, mitotic figures, endothelial proliferation, and necrosis. GBMs, by definition, contain at least three of these four histologic features. In this section, the necrosis is apparent (*star*). As is characteristic for GBMs, this tumor has palisading of neoplastic cells at the edge of the necrosis (*arrow*). Hematoxylin and eosin, 100 $\times$ .



## PILOCYTIC ASTROCYTOMA

**Epidemiology:** Most common in children, but may occur at any age.

**Location:** May arise anywhere, but common sites include the cerebellum, third ventricle, and optic nerves.

**Behavior:** Pilocytic astrocytomas are very low-grade neoplasms (WHO grade I).

**Important point:** Some pilocytic astrocytomas arise in association with NF1.

### Morphology of pilocytic astrocytomas

- **Gross:** Often cystic mass with a radiographically enhancing mural nodule.
- **Microscopic:** Elongated, hair-like (“piloid”) cell processes; cystic areas, **Rosenthal fibers** (thick refractile eosinophilic accumulations) (Figure 11-29), and eosinophilic granular bodies.

## BRAINSTEM GLIOMA

**Basic description:** Descriptive term for a tumor based upon location of origin. All are astrocytic neoplasms; lesions may be infiltrative or pilocytic.

**Epidemiology:** Most brainstem gliomas commonly occur during the first two decades of life (account for 20% of CNS tumors in this age range).

## OLIGODENDROGLIOMA

**Epidemiology:** Adults, fourth to fifth decades; represent 5–15% of gliomas.

**Mutations:** Have loss of heterozygosity involving chromosomes 1p and/or 19q.

**Important points:** Oligodendrogliomas tend to be less aggressive than astrocytomas when comparing similar grades. Oligodendrogliomas are more responsive to chemotherapy.

### Morphology of oligodendrogliomas (Figure 11-30 A and B)

- **Gross:** More well circumscribed than astrocytomas; most cases have calcification.
- **Microscopic:** Round nuclei with perinuclear halos (i.e., “fried egg appearance”); clustering of neoplastic cells around neurons and blood vessels (satellitosis); and branching capillaries (“chicken-wire vasculature”).

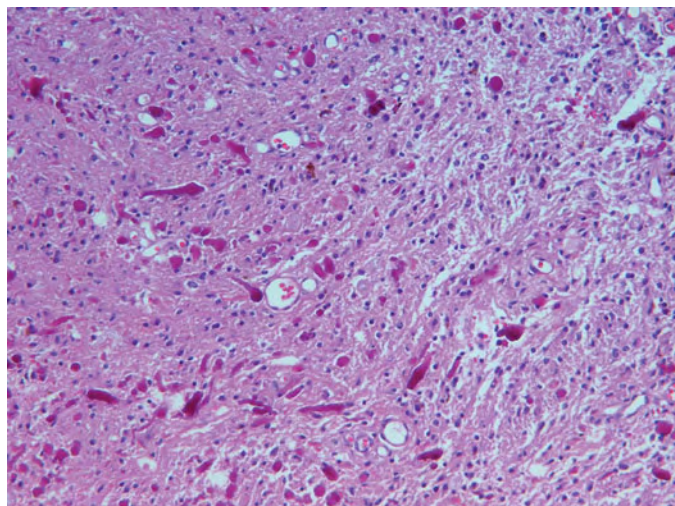
## EPENDYMOMA

**Epidemiology:** Any age.

**Location:** In proximity to ventricular cavities or within spinal cord; may occur in association with NF-2.

**Complications:** Noncommunicating hydrocephalus in the case of ventricular lesions.

**Microscopic morphology of ependymoma:** Ovoid nuclei with cytoplasmic processes forming **pseudorosettes** (radiate around vessel) or **true rosettes** (radiate around a central lumen).



**Figure 11-29.** Rosenthal fibers. The thick, irregular, eosinophilic structures scattered throughout this image are Rosenthal fibers. Rosenthal fibers are associated with pilocytic astrocytomas and a number of other indolent central nervous system neoplasms, but can also be seen at the edge of chronic non-neoplastic processes. In this regard, Rosenthal fibers indicate slow growth, which is consistent with pilocytic astrocytomas. Hematoxylin and eosin, 200 $\times$ .

## MEDULLOBLASTOMA

**Basic description:** Poorly differentiated neuroectodermal neoplasm arising in the cerebellum. Histologically similar tumors may arise in other (extracerebellar) sites; these are sometimes designated simply as “primitive neuroectodermal tumors.”

**Epidemiology:** Most occur in childhood. Peak incidence is at 7 years of age, with a second, smaller peak in young adults (aged 20–40 years).

**Location:** Vermis in younger children; cerebellar hemispheres in older children and adults.

**Mutation:** 17q isochromosome (loss of 17p); abnormalities in chromosome 1 are also common.

### Complications of medulloblastoma

- Noncommunicating hydrocephalus.
- Gait abnormalities.
- Dissemination through CSF via “drop metastases” to the spinal cord.

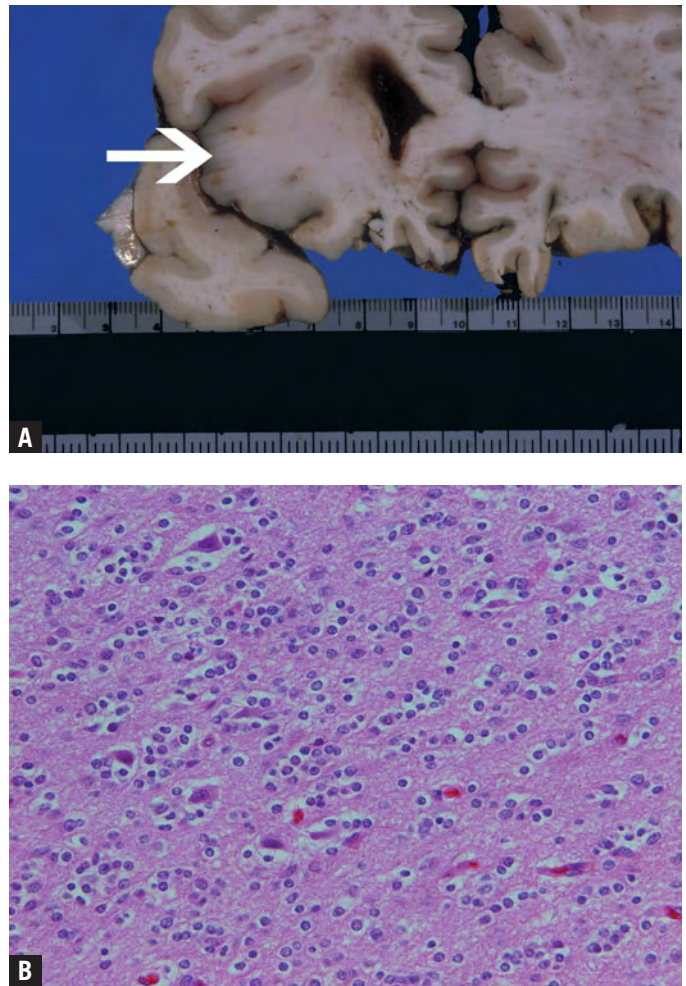
**Microscopic morphology of medulloblastoma (Figure 11-31):** “Small round cell tumor.” May have **Homer-Wright rosettes** (circle of neoplastic cells around a central fibrillar core); some medulloblastomas may contain differentiated cells (e.g., neurons).

## LYMPHOMA

**Epidemiology:** Older adults; increased incidence in immunosuppressed patients (e.g., AIDS).

**Type:** Most are high grade B-cell lymphomas.

**Important point:** If a patient has a B-cell lymphoma of the brain, the possibility of an underlying immunosuppression should be considered. A B-cell lymphoma of the brain is now recognized as an AIDS-defining illness in the setting of HIV seropositivity.



**Figure 11-30. Oligodendroglioma. A,** In the left frontal lobe of this brain is an oligodendroglioma. The tumor is poorly circumscribed; its margins are impossible to distinguish. Compare the gross appearance of this low grade neoplasm to that of the high-grade astrocytic neoplasm (GBM) in Figure 11-28 A. Calcification, not visible in this lesion, is a common feature of oligodendrogliomas. **B,** This medium-power photomicrograph illustrates the histologic features of an oligodendroglioma. Note the “fried egg” appearance (i.e., prominent clearing around the cells) and the comparatively uniform round nuclei characteristic of this neoplasm. Hematoxylin and eosin, 200×. Courtesy of Dr. Stephen Cohle, Spectrum Health-Blodgett Campus, Grand Rapids, MI.



**Microscopic morphology of lymphoma** (Figure 11-32): Neoplastic lymphoid cells that grow around and within the walls of blood vessels (“angiocentric” growth).

### MENINGIOMA

**Epidemiology:** Usually adults; female predominance (meningiomas have progesterone receptors).

**Locations:** Cranial vault, spinal cord.

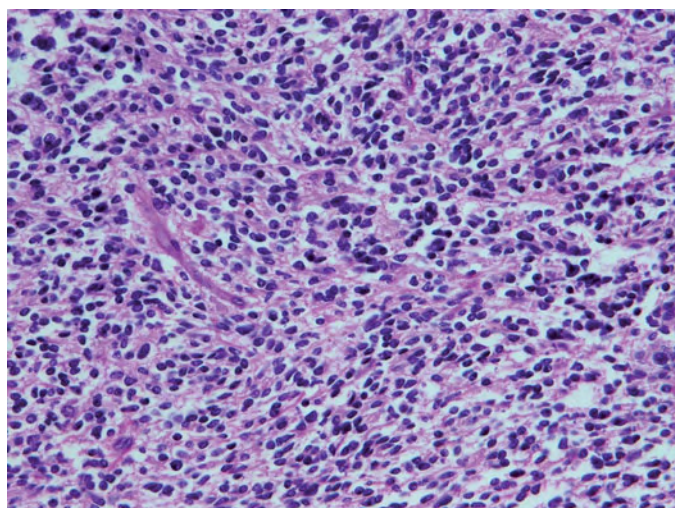
**Important point:** Increased frequency in patients with NF2.

**Morphology of meningioma** (Figure 11-33 A and B)

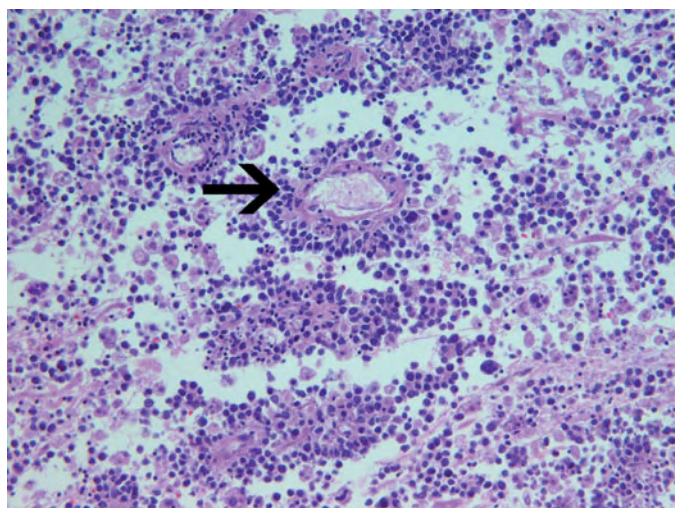
■ **Gross:** Firm dural-based tumor, usually well demarcated from adjacent brain parenchyma. May invade the skull and overlying soft tissues. Brain invasion is uncommon, and when present, usually indicates an aggressive variant.

■ **Microscopic:** Wide range of histologic patterns. Common growth patterns include whorls of meningothelial cells associated with psammoma bodies.

**Clinical presentation of meningioma:** Increased intracranial pressure, causing headaches; also, seizures and focal neurologic deficits in some patients, depending upon the site of the tumor.



**Figure 11-31.** Medulloblastoma. One of the “small round cell” tumors of childhood, medulloblastomas originate in the cerebellum. Hematoxylin and eosin, 200×.



**Figure 11-32.** Lymphoma. Malignant lymphomas may occur in the brain, either as primary lesions or as secondary (metastatic) lesion in patients with systemic lymphoma. Although they can occur spontaneously in apparently immunocompetent hosts, primary central nervous system lymphomas are especially common in patients compromised by HIV infection or other forms of immunosuppression. Most of these lymphomas are high grade non-Hodgkin B-cell tumors. Many such cases are associated with the presence of Epstein-Barr virus infection. Note the monotonous appearance of the cells and their perivascular location (*arrow*). Hematoxylin and eosin, 200×.



## NEURODEGENERATIVE DISEASES PRIMARILY CAUSING DEMENTIA

**Overview:** Each neurodegenerative disease is distinguished by progressive degeneration of neurons in a specific reproducible and defined area of the brain. Some diseases result in progressive dementia and others result in impairment of motor function or other abnormalities. Neurodegenerative diseases have selective neuronal loss with no inciting event. Many are associated with accumulation of protein aggregates that are resistant to degradation. Both hereditary and sporadic forms exist.

**Basic description of dementia:** Characterized by memory impairment and cognitive deficits with preservation of consciousness and sensory and motor function.

**Types of neurodegenerative diseases causing dementia:** Although there are many different forms, only Alzheimer disease, diffuse Lewy body disease, frontotemporal dementia (frontotemporal dementia has multiple subtypes), vascular dementia, and normal pressure hydrocephalus will be discussed here.

### ALZHEIMER DISEASE

**Epidemiology:** Most common cause of dementia in the elderly (causes 70% of cases of dementia). Patients with Down syndrome have a greatly increased risk for the development of Alzheimer disease.

#### Forms of Alzheimer disease

- **Sporadic:** Usually occurs in patients older than 65 years of age.
- **Hereditary:** Tends to occur at a younger age than sporadic form.

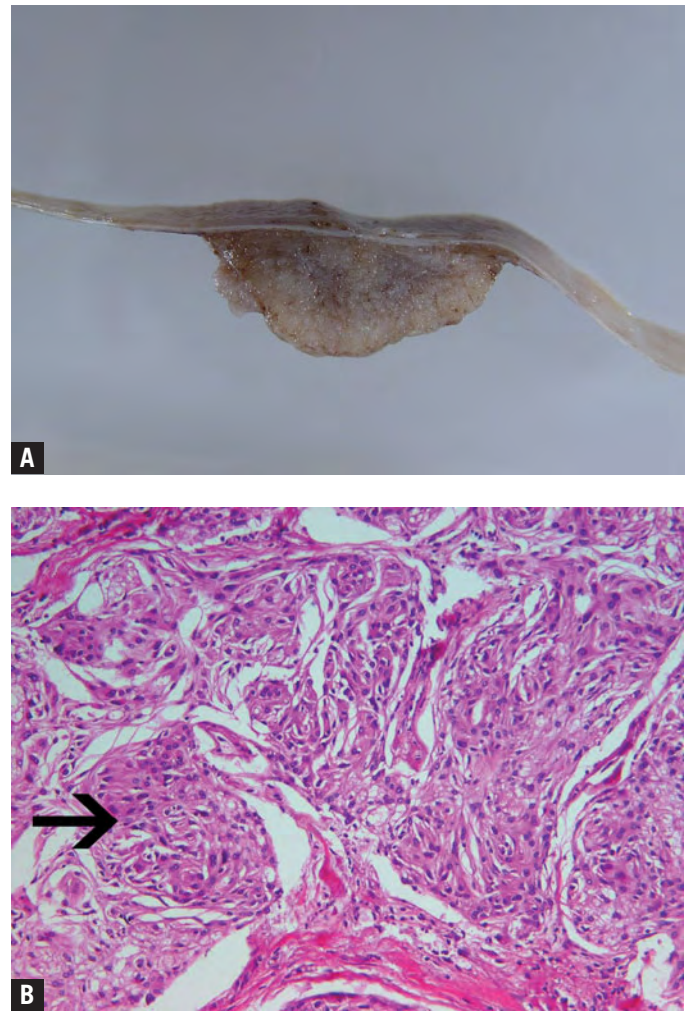
#### Risk factors for Alzheimer disease

- Increasing age.
- Genetics (in hereditary cases): Genes involved include the gene for the amyloid precursor protein (APP) on chromosome 21, the gene for presenilin-1 on chromosome 14, and the gene for presenilin-2 on chromosome 1. Presenilins are a component of  $\gamma$ -secretase.
- $\alpha 4$  allele of apoE on chromosome 19.

**Pathogenesis of Alzheimer disease:** Due to defects in the processing of the amyloid precursor protein.  $\alpha$ -Secretase cleaves APP into a large soluble fragment and a smaller membrane-anchored fragment. The membrane-anchored fragment is cleaved by  $\gamma$ -secretase. If APP is cleaved by  $\beta$ -secretase, then when the membrane-bound fragment is cleaved by  $\gamma$ -secretase, less soluble peptides are formed that aggregate. The clearance of these aggregates is impaired in Alzheimer disease.

#### Morphology of Alzheimer disease (Figure 11-34 A–C)

- **Gross:** Cerebral atrophy with resultant hydrocephalus ex vacuo (i.e., compensatory expansion of ventricles because of loss of cerebral parenchyma).
- **Microscopic:** Neurofibrillary tangles and senile (neuritic) plaques, particularly in the hippocampus, cerebral neocortex, and in some subcortical neurons. Other microscopic



**Figure 11-33. Meningioma.** **A**, Meningiomas are dural-based neoplasms, frequently located at the cerebral convexities. While most meningiomas do not invade, the tumor can grow in size and, because of the confining space of the cranium, produce symptoms and untoward effects. **B**, This medium-power photomicrograph demonstrates the characteristic whorled architecture of a meningioma (arrow). Although meningiomas are frequently associated with Psammoma bodies, none are present in this image. Hematoxylin and eosin, 200 $\times$ .

findings of Alzheimer disease include amyloid angiopathy and “**granulovacuolar degeneration**” in hippocampal neurons.

#### ■ Microscopic components

- **Senile plaques:** Swollen neuronal processes rich in hyperphosphorylated tau protein, usually surrounding a  $\beta$ -amyloid core.
- **Neurofibrillary tangles:** Intracellular aggregates of hyperphosphorylated tau protein (paired helical filaments).

#### Clinical presentation of Alzheimer disease

- **Symptoms:** Gradual decline in cognitive function (i.e., memory, orientation, language, judgment, insight) leading to severe cognitive dysfunction. Patients have loss of ability to care for self and loss of some biologic functions. The disease is often fatal within 5–10 years, usually from a concomitant pathologic process such as pneumonia.
- **Diagnosis:** The diagnosis of Alzheimer disease is made by the clinical diagnosis of dementia without another explanation (with fixed deficits in two cognitive areas). Definitive diagnosis requires the demonstration of significant neocortical accumulations of plaques and tangles at autopsy.
- **Clinical studies (to exclude another cause for the dementia)**
  - Rapid plasmin reagin (RPR), vitamin B<sub>12</sub> and folate levels, and thyroid-stimulating hormone (TSH).
  - CT or MRI scans to rule out a mass, normal pressure hydrocephalus, or a chronic subdural hemorrhage.

### DIFFUSE LEWY BODY DISEASE (DEMENTIA WITH LEWY BODIES)

**Epidemiology:** Elderly patients; second most common cause of dementia in some populations.

**Microscopic morphology:** Patients have Lewy bodies in the neocortical neurons similar to those seen in Parkinson disease.

**Clinical presentation of diffuse Lewy body disease:** Parkinsonism (slow movement, rigidity, balance abnormalities) combined with dementia; hallucinations are common.

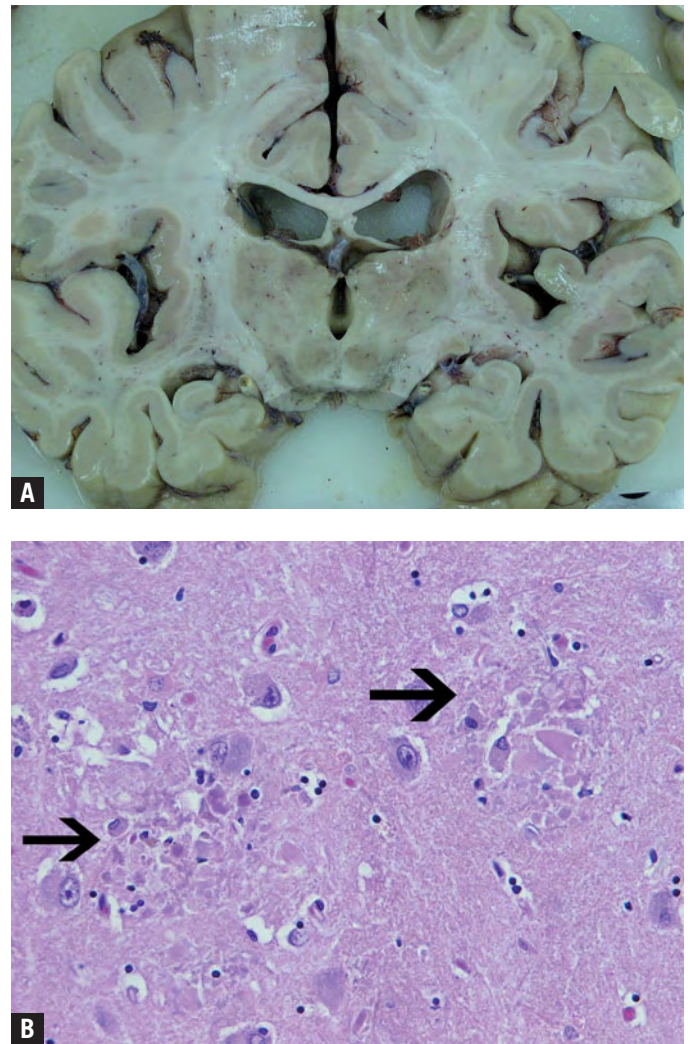
### FRONTOTEMPORAL DEMENTIA

#### ■ Pick disease

- **Gross morphology:** Atrophy of frontal and temporal lobes.
- **Microscopic morphology:** Particularly common in the dentate gyrus of the hippocampus and deeper cortical neurons are Pick bodies (i.e., round eosinophilic intracytoplasmic inclusions containing accumulation of abnormal 3-repeat tau protein).
- **Clinical presentation of Pick disease:** Early onset behavioral abnormalities, with alterations in personality and language disturbances.

■ **Frontotemporal dementia with Parkinsonism linked to chromosome 17:** Due to a mutation in the tau gene.

■ **Frontotemporal dementia with motor neuron disease:** Associated with the presence of ubiquitin-rich neuronal inclusions, particularly in the dentate gyrus of the hippocampus.



**Figure 11-34.** Alzheimer disease. **A**, Alzheimer disease produces a loss of cerebral parenchyma. This loss of parenchyma is easily visible in this section as widening of the sulci and hydrocephalus ex vacuo. Hydrocephalus ex vacuo is compensatory dilation of the cerebral ventricles in response to loss of cerebral parenchyma. **B**, This photomicrograph illustrates two senile plaques, visible in this preparation as coarse deposits within the neuropil (arrows). Classic senile plaques are composed of collections of swollen dystrophic neuritic processes containing hyperphosphorylated tau protein, surrounding a central core of  $\beta$ -amyloid. Senile plaques can be identified with normal hematoxylin and eosin stains (H&E), but are best visualized with specialized silver stains or with immunohistochemical stains for tau protein or  $\beta$ -amyloid. (Continued)



## VASCULAR DEMENTIA

**Clinical presentation:** Stepwise decline in cognitive function.

**Pathogenesis of vascular dementia:** Small microinfarcts and/or strategic infarcts (i.e., infarcts affecting the hippocampus and other areas specifically involved with memory function).

## NORMAL PRESSURE HYDROCEPHALUS

**Clinical presentation:** Clinical triad of dementia, gait instability, and urinary incontinence (“wacky, wobbly, and wet”).

**Important points:** Lumbar puncture and shunting may be therapeutic. Most commonly seen in elderly patients, and is one of the few reversible causes of dementia. CT shows dilated ventricles; normal intracranial pressure. Treatment is with CSF shunt.

## OTHER NEURODEGENERATIVE DISEASES

**Overview:** In addition to the neurodegenerative diseases that cause dementia and affect mainly the cerebral cortex, there are many other neurodegenerative diseases that affect other parts of the brain, including the basal ganglia and brainstem, causing movement disorders. The features of some of these other neurodegenerative disorders, including Huntington chorea, idiopathic Parkinson disease, progressive supranuclear palsy, and amyotrophic lateral sclerosis, will be discussed here.

## HUNTINGTON CHOREA

### Clinical findings

- Involuntary writhing motions (i.e., **choreiform**) when presenting in adults during the fourth or fifth decades; seizures and rigidity when presenting at a younger age.
- Depression and cognitive impairment (i.e., dementia).
- Patients often commit suicide because of the prognosis.

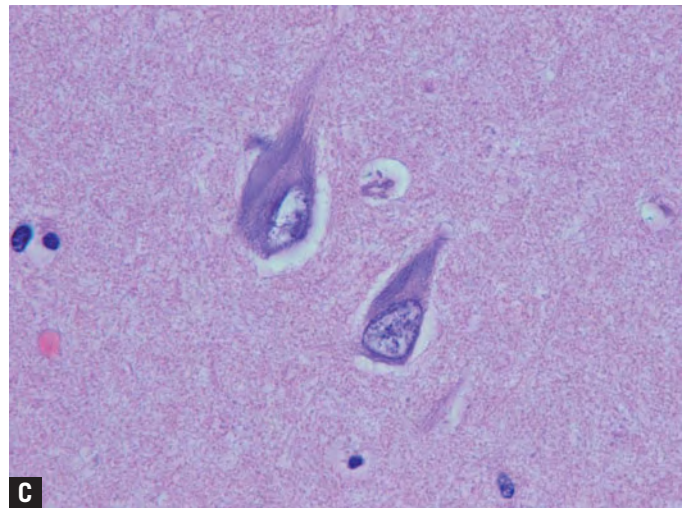
### Mutation

- Huntingtin gene on chromosome 4.
- Mutation is an increase in the number of CAG repeats in the huntingtin gene. Transcription of the expanded CAG repeats results in the accumulation of excess numbers of polyglutamine residues in the huntingtin protein. There is an inverse relationship between the number of CAG repeats and the age of onset of disease. The CAG repeats increase in number during spermatogenesis, which results in the disease presenting earlier in successive generations (referred to as **anticipation**).

**Inheritance pattern:** Autosomal dominant.

### Morphology of Huntington chorea

- **Gross:** Bilateral atrophy of caudate nuclei and putamen.
- **Microscopic:** Loss of medium spiny GABA-ergic neurons in the caudate and putamen; associated with gliosis.



**Figure 11-34. (Continued) C,** Both neurons in this section contain neurofibrillary tangles, which appear in this H&E stained section as compact filamentous basophilic inclusions within the cytoplasm of the neurons. Like the dystrophic neurites in senile plaques, neurofibrillary tangles are rich in hyperphosphorylated tau protein. The morphologic diagnosis of Alzheimer disease is based upon the identification of large numbers of senile plaques and neurofibrillary tangles in the cerebral neocortex. Hematoxylin and eosin, B and C, 400X.



## IDIOPATHIC PARKINSON DISEASE

**Basic description:** Degenerative disease with impairment of motor function; 20% of patients have dementia. Idiopathic Parkinson disease represents a spontaneous systems degeneration (i.e., it is *not* caused by an exogenous insult). Similar clinical abnormalities (“parkinsonism”) may be caused by certain exogenous insults, however, as discussed below.

**Pathogenesis of idiopathic Parkinson disease:** Reduced level of dopamine because of loss of dopamine-containing neurons, particularly in the substantia nigra.

**Mutations:** Mutations of  $\alpha$ -synuclein and parkin (substrate of  $\alpha$ -synuclein) occur in rare hereditary cases.

**Clinical findings of parkinsonism:** Cogwheel rigidity (ratchet-like movements), bradykinesia, flat affect, “masked facies,” and pill-rolling tremor plus a shuffling gait. Parkinson disease is a movement disorder; however, 20% of patients have a dementia component. The dementia may be the result of associated Alzheimer disease, or it may occur as a component of diffuse Lewy body disease.

**Morphology of idiopathic Parkinson disease** (Figure 11-35 A and B)

■ **Gross:** Pallor of substantia nigra and locus ceruleus.

■ **Microscopic:** Lewy bodies, which are round well-demarcated intracytoplasmic eosinophilic inclusions that stain with antibodies to ubiquitin and  $\alpha$ -synuclein.

**Important point regarding idiopathic Parkinson disease:** The diagnosis of idiopathic Parkinson disease is determined based upon the clinical findings.

## SECONDARY PARKINSONISM

**Basic description:** Parkinsonian symptoms caused by an exogenous insult.

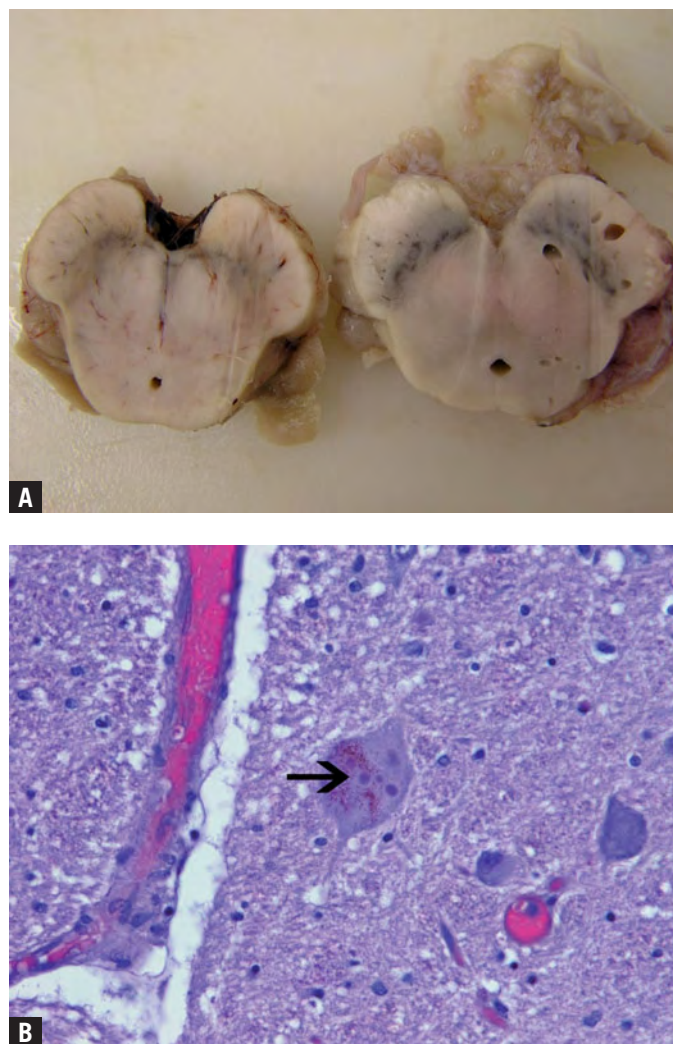
**Causes:** Medications (e.g., antipsychotic agents), toxins (e.g., carbon monoxide), MPTP (1-methyl-4-phenyl-1,2,3,6-tetrahydropyridine) toxicity, encephalitis (e.g., West Nile virus), and hypoxic-ischemic injury.

## PROGRESSIVE SUPRANUCLEAR PALSY

**Epidemiology:** Occurs in the fifth to seventh decades; male predominance, with a male to female ratio of 2:1.

**Microscopic morphology of progressive supranuclear palsy:** Neuronal loss in the globus pallidus, subthalamic nucleus, and dentate nucleus of cerebellum. Progressive supranuclear palsy is associated with the accumulation of tau-rich globose neurofibrillary tangles and tau-rich aggregates in glial cells (progressive supranuclear palsy represents yet another member of a growing list of degenerative diseases associated with accumulation of the abnormal tau protein. Other examples include Alzheimer disease, Pick disease, and frontotemporal dementia associated with parkinsonism).

**Clinical presentation:** Progressive supranuclear palsy shares some of the features of Parkinson disease. Patients have truncal rigidity, disequilibrium (with resultant falls), pseudobulbar



**Figure 11-35.** Idiopathic Parkinson disease. **A**, The brainstem on the left side of the image has a pale substantia nigra compared to the age-matched control on the right side of the image. A grossly pale substantia nigra is characteristic of Parkinson disease, and is caused by a selective loss of pigmented dopamine-secreting neurons in this nucleus. The well-circumscribed defects near the substantia nigra in the brainstem on the right side are artifacts, due to early decomposition and gas formation. **B**, The neuron in the center of the image has several Lewy bodies, visible in this section as basophilic homogeneous cytoplasmic inclusions surrounded by a clear halo (arrow). Lewy bodies are the hallmark of Parkinson disease, and are rich in a protein known as  $\alpha$ -synuclein. Hematoxylin and eosin, 400 $\times$ .

palsy, abnormal speech, and ocular disturbances (e.g., loss of voluntary eye movements with preservation of oculocephalic reflex eye movements).

### AMYOTROPHIC LATERAL SCLEROSIS (ALS; LOU GEHRIG DISEASE)

**Basic description:** Neurogenic muscle atrophy (i.e., amyotrophy) occurs because of loss of lower motor neurons, and hyperreflexia occurs because of loss of upper motor neurons.

**Epidemiology:** Usually occurs in the fifth decade or later; male predominance. Most cases are sporadic; however, hereditary forms account for a minority of cases (5–10%). Some familial cases have been linked to mutations in the superoxide dismutase (SOD)-1 gene.

#### Morphology of ALS

- **Gross:** Atrophic anterior spinal nerve roots.
- **Microscopic:** A loss of neurons in the anterior horn is associated with gliosis. Residual motor neurons may contain eosinophilic **Bunina bodies** and ubiquitin-rich filamentous aggregates. There is loss of some brainstem motor nuclei and neurons in the primary motor cortex and degeneration of corticospinal tracts caused by the upper motor neuron loss.

#### Clinical presentation of ALS

- **Upper motor neuron signs:** Spasticity, hyperreflexia, and Babinski sign.
- **Lower motor neuron signs:** Weakness, fasciculations, and muscle atrophy.

### SPINAL MUSCULAR ATROPHY, INCLUDING WERDNIH-HOFFMANN DISEASE

**Basic description:** Condition caused by degeneration of the anterior horn cells of the spinal cord.

**Important point:** Spinal muscular atrophy is the second most common lethal autosomal recessive disease (cystic fibrosis is the most common).

**Mutation:** 5q11.2-13.3; deletions or point mutations in the survival motor neuron (SMN) locus in this region account for more than 98% of cases.

**Clinical presentation of spinal muscular atrophy:** Severe and progressive weakness and hypotonia in early infancy. Most infants do not survive beyond 1 year of age. Tongue fasciculations are classic but not specific.

**Microscopic morphology of spinal muscular atrophy:** Groups of rounded and atrophic fibers associated with fibers of normal diameter and hypertrophied type I fibers; loss of neurons in the anterior horn of the spinal cord.

## DEMYELINATING DISEASES

**Overview:** Demyelinating diseases are due to a process that affects the oligodendroglia cells or the myelin sheath itself, resulting in loss of myelin. May be primary (e.g., leukodystrophies) or acquired (e.g., multiple sclerosis). Multiple sclerosis,

acute disseminated encephalomyelitis, acute necrotizing hemorrhagic encephalomyelitis, progressive multifocal leukoencephalopathy, and central pontine myelinolysis are discussed in this section.

### MULTIPLE SCLEROSIS (MS)

**Basic description:** Most common demyelinating disorder of the CNS.

**Epidemiology:** Young adults (< 40 years); occurs in 1 in 1000 individuals (in the U.S. and Europe). Female to male ratio is 2:1. Generally more common in northern regions of the United States and Europe than in the southern regions.

**Pathogenesis of MS:** Almost certainly an autoimmune disorder. There is presence of CD4<sup>+</sup> T<sub>H</sub>1 and CD8<sup>+</sup> T cells in lesions, which are reactive against myelin basic protein. Environmental and hereditary factors also likely to play a role.

**Forms of MS:** Although most of the discussion in this section pertains to classic MS, there are a few other forms, including Devic disease, acute MS, and Baló disease, that are also discussed.

#### ■ Devic disease (neuromyelitis optica)

- **Manifestations:** Bilateral optic neuritis and spinal cord involvement.
- **Clinical course:** Rapidly progressive.

■ **Acute MS (Marburg):** Widespread myelin injury; affects younger patients and has a fulminant, monophasic course.

■ **Baló disease (concentric sclerosis):** Rare, rapidly progressive variant associated with the development of lesions containing concentric rings of myelinated and demyelinated white matter.

#### Morphology of MS (Figure 11-36 A and B)

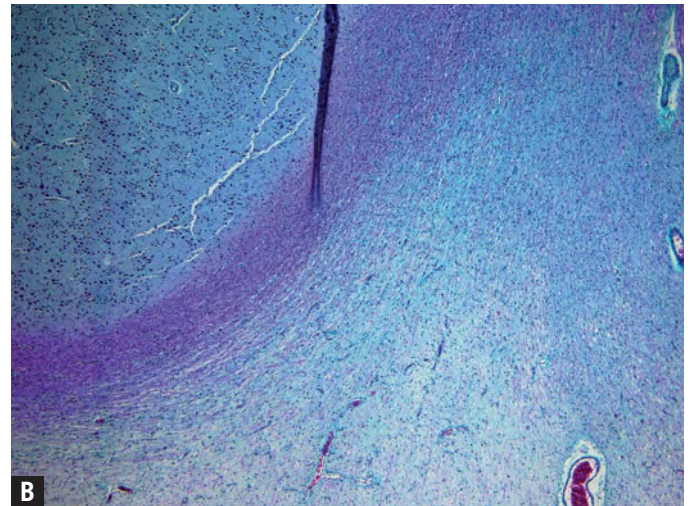
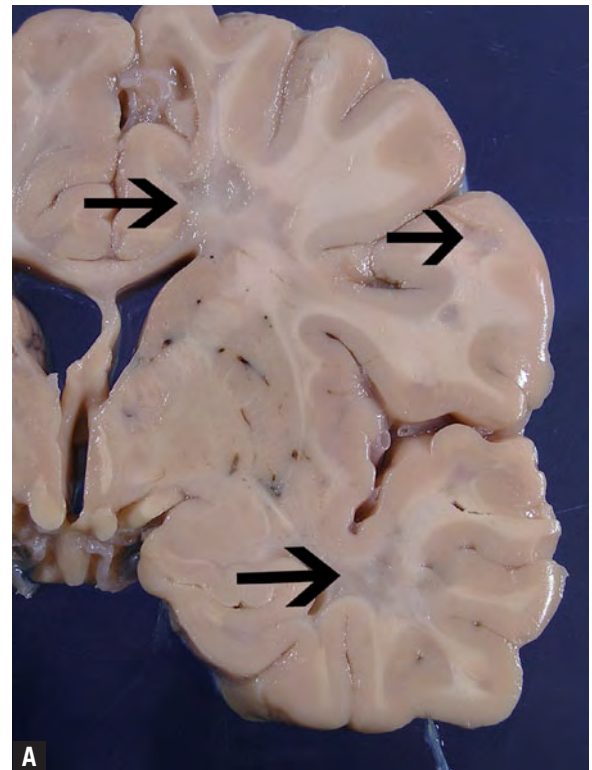
■ **Gross:** Gray-white translucent areas (i.e., **plaques**) occurring in white matter. Common sites of occurrence include the corner of the lateral ventricles, optic nerves, and spinal cord. **Acute plaques** are soft and slightly pink, and **remote plaques** are more firm, pearly gray, and relatively circumscribed.

#### ■ Microscopic

- **Active plaque:** Sharply defined collections of foamy macrophages, associated with relative preservation of neurons.
- **Remote (inactive) plaques:** Gliosis.
- **Shadow plaques:** Axons with a thin layer of myelin at the edge (i.e., evidence of partial demyelination or remyelination); not sharply circumscribed.

#### Clinical presentation of MS

■ **Symptoms:** The symptoms are highly variable from patient to patient and depend upon location of plaques, and may involve both upper and lower motor neurons. **Unilateral optic neuritis** (i.e., eye pain with an acute change in visual acuity) and **transverse myelitis** are common and highly suggestive of MS. Other symptoms include diplopia, ataxia, spasticity, and weakness. The course of MS in most patients is relapsing and remitting (with intervals from weeks to months to years).



**Figure 11-36.** Multiple sclerosis. **A**, This section of the brain contains several opaque vaguely gelatinous areas in the white matter, which represent areas of demyelination, also known as plaques (arrows). As in the two on the left side of this image, the plaques are characteristically found at the corner of the cerebral ventricles. **B**, In the left upper corner of this image is gray matter. The purple band immediately adjacent to it is normally staining white matter. The remainder of the image (right lower half of photomicrograph) is white matter, which is poorly stained due to the loss of myelin. This image is a photomicrograph of an inactive plaque. Luxol-fast blue, 40×.



- **Laboratory studies:** Evaluation of CSF can reveal myelin basic protein during active myelin breakdown, oligoclonal bands because of proliferation of B cells, and elevated CSF IgG index (CSF IgG/CSF albumin divided by serum IgG/serum albumin). The antibodies produced are not shown to directly initiate the disease process.

### ACUTE DISSEMINATED ENCEPHALOMYELITIS

**Basic description:** Immune-mediated demyelinating disease that follows a viral illness (often measles or chickenpox) or occasionally follows a vaccination.

**Clinical course of acute disseminated encephalomyelitis**

- Monophasic illness of abrupt onset (in contrast to classical MS, which is relapsing and remitting and chronic in nature).
- **Symptoms:** Seizures, coma, focal neurologic deficits.
- **Important point:** The disease has an acute onset and fulminant course, and is fatal in about one fourth of cases.

**Microscopic morphology:** Collections of foamy macrophages, comparable to those seen in MS plaques.

### ACUTE NECROTIZING HEMORRHAGIC ENCEPHALOMYELITIS

**Basic description:** Immune-mediated demyelinating disease that follows an upper respiratory tract infection (usually *Mycoplasma pneumoniae*).

**Epidemiology:** Affects children and young adults.

**Clinical course of acute necrotizing hemorrhagic encephalomyelitis:** Acute onset; fulminant course.

**Microscopic morphology:** More extensive than acute disseminated encephalomyelitis; has white and gray matter necrosis, neutrophilic infiltrate, and fibrin deposition.

### PROGRESSIVE MULTIFOCAL LEUKOENCEPHALOPATHY

**Basic description:** Demyelination as result of viral infection involving oligodendroglial cells.

**Causes:** JC virus (a member of the papovavirus family) in association with immunosuppression (most commonly HIV infection).

**Morphology of progressive multifocal leukoencephalopathy**

- **Gross:** Gelatinous foci at junction between gray and white matter.
- **Microscopic:** Demyelination associated with enlarged oligodendroglial cells whose nuclei contain smudgy purple inclusions. Atypical astrocytes are also quite common.

### CENTRAL PONTINE MYELINOLYSIS

**Basic description:** Demyelinating disorder involving the central area of the basal pons.

**Causes:** Uncertain; associations include rapid correction of hyponatremia and alcoholism.

## PERIPHERAL NERVE PATHOLOGY

**Overview:** Neuropathies are conditions involving primary injury to the axon, nerve cell body, or myelin sheath. Some specific types of peripheral neuropathies discussed in this section include axonal neuropathy, demyelinating neuropathy, immune neuropathy (e.g., Guillain-Barré syndrome), metabolic and toxic neuropathy, and infectious neuropathy.

**Axonal neuropathy:** Primary injury of the axonal process, associated with the formation of fragmented axonal processes and myelin debris (“**myelin ovoids**”). Most cases evolve as a dying-back process with distal to proximal degeneration. A special form of axonal degeneration, termed **Wallerian degeneration**, represents degeneration of the distal axonal process following transection, as might occur in a patient with segmental ischemic nerve injury associated with vasculitis. The most common types of neuropathies are axonal.

**Demyelinating neuropathy:** Primary damage is to Schwann cells, typically in a multifocal segmental distribution along the length of the axon. It is characterized by selective myelin injury and relative preservation of the axon; secondary axonal injury may occur in some cases, however. Chronic cases are associated with concentric layers of Schwann cell cytoplasm and collagen (so-called “**onion bulbs**”) around residual axons.

### Immune neuropathy

**Overview:** Although there are several immune neuropathies, one of the most important is Guillain-Barré syndrome, which will be discussed in detail.

**Incidence of Guillain-Barré syndrome:** 1–3/100,000 of the general population.

### Clinical presentation of Guillain-Barré syndrome

- **Course:** Usually begins with weakness in the distal extremities and progresses to involve the proximal muscle groups (the progression is referred to as ascending paralysis); respiratory muscles may be involved.
- **Predisposing factor:** Two thirds of cases follow an influenza-like illness. Guillain-Barré syndrome is also associated with *Campylobacter jejuni*, CMV, and Epstein-Barr virus (EBV) infections.

**Microscopic morphology of Guillain-Barré syndrome:** Inflammation and demyelination of nerves.

### Metabolic and toxic neuropathies

- **Diabetes mellitus** (various types of neuropathy): Distal symmetric sensory or sensorimotor, autonomic, and focal or multifocal asymmetric.
- **Other causes:** Vitamin deficiencies, malignancy, heavy metals.

**Infectious neuropathy:** Causes include leprosy, diphtheria, and varicella-zoster virus.

## SKELETAL MUSCLE PATHOLOGY

**Overview:** A variety of different conditions can produce abnormalities in skeletal muscle. These include disorders of the peripheral nervous system and lower motor neurons in which muscle fibers undergo a change known as **denervation atrophy**. In classic denervation atrophy, the muscle contains angular atrophic fibers, often lying in small groups. Both fast twitch (type 2) and slow twitch (type 1) fibers are affected. Denervation occurring in infants with **spinal muscular atrophy** is described above in the section on degenerative diseases. Myofiber atrophy is also a feature of **disuse atrophy**. In this condition, the atrophic fibers are exclusively type 2 fibers, in contrast to the mixed type 1 and type 2 myofiber involvement that occurs in denervation atrophy.

In addition to denervation atrophy and disuse atrophy, there are a number of important conditions that represent primary diseases of muscle fibers, known collectively as **myopathies**. Examples of myopathic disorders include muscular dystrophies (see Chapter 6), exogenous toxic insults, hereditary metabolic disorders, and inflammatory conditions. Most of the inflammatory myopathies (e.g., polymyositis, dermatomyositis, and inclusion body myositis) present with some degree of proximal muscle weakness (e.g., inability to rise from a chair or to comb one's hair).

Some disorders of skeletal muscle (e.g., myasthenia gravis and Lambert-Eaton syndrome) are due to neuromuscular transmission defects, and will be discussed after the various forms of myopathies.

### Inflammatory myopathies

#### 1. Polymyositis and dermatomyositis

##### **Clinical presentation of polymyositis and dermatomyositis:**

Proximal muscle weakness with laboratory testing revealing elevated muscle enzymes (i.e., total creatine kinase [CK]). In addition, patients with dermatomyositis have a lilac-colored rash of the upper eyelids (**heliotrope rash**) with associated periorbital edema and scaly erythematous eruption on the elbows and knuckles (**Gotttron papules**) and an erythematous rash involving the shoulders and upper chest (**shawl sign**).

**Important point:** In adult patients with dermatomyositis, there is an increased risk for an associated visceral malignancy. Juvenile dermatomyositis may be associated with ischemic injury in other organs as a result of vascular disease. In both types, the patients also have an increased risk of developing interstitial lung disease.

**Microscopic morphology of dermatomyositis:** Inflammation around the vessels and in the perimysial connective tissue. Atrophic fibers at the periphery of fascicles (so-called "**perifascicular atrophy**") is characteristic, due to associated microvascular disease. Endothelial cells contain characteristic tubuloreticular inclusions, visible under the electron microscope.

**Microscopic morphology of polymyositis:** Predominantly endomysial lymphoid infiltrates associated with muscle fiber degeneration and regeneration. Invasion of viable myofibers by lymphocytes is a helpful diagnostic feature.



## 2. Inclusion body myositis

**Basic description:** Chronic myopathy associated with inflammation and characteristic “rimmed” vacuoles in muscle fibers.

**Important points:** In contrast to polymyositis and dermatomyositis, patients with inclusion body myositis do not respond to immunosuppressive therapy. This condition is probably better thought of as an acquired degenerative disorder of skeletal muscle rather than a primary inflammatory myopathy. In contrast to polymyositis and dermatomyositis, patients with inclusion body myositis present with weakness of distal muscle groups (forearms and quadriceps), which progresses to involve more proximal groups.

**Toxic myopathies:** HMG-CoA reductase inhibitors (statins) and other anti-hyperlipidemic drugs are a particularly important cause of toxic myopathy.

### Other forms of myopathies

- **Mitochondrial myopathies:** Caused by abnormalities in one or more mitochondrial proteins; often associated with abnormal mitochondrial proliferation. The classic morphologic change is the “ragged red” fiber, visible in trichrome-stained frozen sections.
- **Myopathies associated with hereditary metabolic defects** (e.g., glycogen storage disorders and lipid storage disorders).
- **Congenital myopathies:** “Nondestructive” myopathies, classically defined by the presence of a particular type of structural abnormality (e.g., central cores, nemaline rods, central nuclei). Some cases have been shown to be caused by an inherited abnormality in a specific structural protein, particularly those associated with the contractile apparatus (e.g., actin).

## MYASTHENIA GRAVIS

**Basic description:** Immune-mediated disease characterized by loss of acetylcholine receptors associated with antibodies against the acetylcholine receptors.

**Epidemiology:** 3 in 100,000 of the general population. If patients are younger than 40 years of age, female predominance; if patients are older, the number of males and females affected is equal.

**Clinical presentation of myasthenia gravis:** Weakness of skeletal muscles and weakness of extraocular muscles, causing ptosis and diplopia. Muscle weakness improves when patients are given anticholinesterase medications (“edrophonium challenge test”).

**Associated conditions:** About 65% of patients have thymic hyperplasia and 15% have a thymoma.

**Morphology of myasthenia gravis:** Nonspecific muscle fiber atrophy.

## LAMBERT-EATON SYNDROME

**Basic description:** Paraneoplastic syndrome associated with small cell lung cancer, which is caused by antibody against presynaptic calcium channels.

**Clinical presentation:** Weakness of proximal muscle groups. The muscle weakness does not improve with use of anticholinesterase inhibitors.

**Important point:** In myasthenia gravis, motor response decreases with successive contractions on electromyography. In Lambert-Eaton syndrome, motor response improves with successive contractions.



# CHAPTER 12

## HEMATOPATHOLOGY

### OVERVIEW

Hematopathology includes both diseases of red blood cells and diseases of white blood cells, as well as coagulation disorders. The first part of this chapter will discuss diseases of red blood cells, including general features of anemia, microcytic anemia, macrocytic anemia, and other anemias associated with decreased production, general features of hemolytic anemias, antibody-mediated destruction of red blood cells and other external causes of red blood cell destruction, hereditary causes of increased red blood cell destruction, and polycythemia. The second part of the chapter will discuss diseases of white blood cells and coagulation disorders.

### ANEMIA

**Overview:** A shortage of red blood cells is referred to as anemia. There are three mechanisms by which the body becomes anemic: blood loss (either acute or chronic), decreased production of red blood cells, and increased destruction of red blood cells (i.e., hemolysis). These anemias can be categorized in two general ways: by mechanism (as outlined above), and by morphology, such as by mean corpuscular volume (MCV). To evaluate an anemia, the initial step is classification based upon the MCV, the reticulocyte count, and the blood smear. A high reticulocyte count indicates that the bone marrow is responding to the anemia by producing red blood cells. A low reticulocyte count indicates a production problem. The laboratory measures red cell indices based upon the size of the red blood cell and the amount of hemoglobin (Hb) per cell. Of these, MCV is very important in the morphologic classification of anemias. The other red cell indices are mean cell hemoglobin (MCH), mean cell Hb concentration (MCHC), and red cell distribution width (RDW). Anemias due to a deficiency of a substance (e.g., iron) usually have a higher RDW than anemias due to a genetic defect or bone marrow disorder.



**TABLE 12-1.** Differential Diagnosis of Anemia Based upon the Three General Mechanisms

General Mechanism of Anemia	General Cause	Specific Cause	Specific Cause
Blood loss	Acute blood loss Chronic blood loss	Trauma GI malignancy, menstruation	
Decreased production	Defect of stem cells Defective heme production Defective DNA production Destruction of bone marrow	Aplastic anemia, pure red cell aplasia Iron deficiency anemia, thalassemia Vitamin B <sub>12</sub> and folate deficiency Metastatic tumor	
Increased destruction	External factors: antibody mediated  External factors: non-antibody-mediated  Hereditary internal factors  Acquired internal factors	Isohemagglutinin  Autoimmune  Trauma Infections Sequestration Defect in cytoskeleton Abnormal hemoglobin Enzyme deficiency PNH	Transfusion reactions, erythroblastosis fetalis Warm and cold autoimmune hemolytic anemia   Hereditary spherocytosis Sickle cell anemia, HbC G6PD deficiency

GI, gastrointestinal; Hb, hemoglobin; G6PD, glucose-6-phosphate dehydrogenase; PNH, paroxysmal nocturnal hemoglobinuria.

**Mechanisms of anemia:** Blood loss, decreased production of red blood cells, and increased destruction of red blood cells due to external factors and both hereditary and acquired internal factors (Table 12-1).

### 1. Causes of blood loss

- Acute blood loss: Often due to trauma.
- Chronic blood loss: Often due to bleeding from gastrointestinal malignancies or menstruation.

### 2. Causes of decreased production of red blood cells

- Disturbance of stem cells (e.g., aplastic anemia, pure red cell aplasia).
- Defective heme production (e.g., iron deficiency, thalassemias).
- Defective DNA production (e.g., vitamin B<sub>12</sub> and folate deficiencies).
- Destruction of bone marrow (e.g., metastatic tumor).

### 3. Causes of increased destruction of red blood cells due to external factors

- Antibody mediated: Etiology is either **isohemagglutinin** (e.g., transfusion reactions or erythroblastosis fetalis) or **autoimmune**.
- Trauma to red cells.
- Infectious (e.g., malaria).
- Sequestration in an enlarged spleen.

#### 4. Causes of increased destruction of red blood cells due to hereditary internal factors

- Defects in cytoskeleton (e.g., hereditary spherocytosis).
- Structurally abnormal hemoglobin (e.g., sickle cell anemia, thalassemias).
- Enzyme deficiencies (e.g., glucose-6-phosphate dehydrogenase [G6PD] deficiency).

#### 5. Cause of increased destruction due to acquired defect: Paroxysmal nocturnal hemoglobinuria (PNH)

- **Defect:** In normal red blood cells, phosphatidylinositol glycan A (PIGA) is needed for synthesis of the glycosylphosphatidylinositol (GPI) anchor, which binds certain proteins to the cell membrane. These proteins include CD55 (also referred to as decay-accelerating factor [DAF]), and CD59, a membrane inhibitor of reactive lysis. These factors degrade complement. In patients with PNH, the loss of PIGA causes the loss of CD55 and CD59, resulting in red blood cells being more prone to lysis by complement.
- **Complications of PNH:** Venous thrombosis (hepatic, portal, and cerebral veins).

#### Sites of removal of red blood cells from circulation and their complications

- **Extravascular:** Removal of red blood cells from the circulation by the phagocytic system in the spleen and liver. Complications include hemosiderin deposition in organs and jaundice and gallstones. The jaundice and gallstones result from the elevated unconjugated bilirubin associated with the hemolysis.
- **Intravascular:** Destruction of red blood cells within the blood vessels. Complications include unconjugated bilirubinemia, hemoglobinemia, hemoglobinuria, and hemosiderinuria. Hemoglobinemia can lead to acute tubular necrosis, which causes acute renal failure. Jaundice and gallstones can occur due to the elevated level of unconjugated bilirubin.

#### Microscopic morphology of anemia

- **Spherocytes:** Present in hereditary spherocytosis and immune hemolysis.
- **Schistocytes:** Present in microangiopathic hemolytic anemia (e.g., thrombotic thrombocytopenic purpura [TTP], hemolytic uremic syndrome [HUS]).
- **Target cells:** Present in hemoglobinopathies (e.g., HbC) and obstructive liver disease.
- **Teardrop cells:** Present in myelofibrosis.
- **Sickle cells:** Present in sickle cell anemia or thalassemia minor in combination with sickle cell anemia.
- **Rouleaux:** Present in conditions with increased globins or decreased albumin (e.g., multiple myeloma).

### Clinical presentation of anemia

- **General features:** Pale skin, fatigue, dyspnea on exertion, chest pain, syncope, and dizziness. Chest pain, syncope, and dizziness are all due to inadequate oxygenation of the heart and brain.
- **Laboratory studies:** Most important are MCV, reticulocyte count, and peripheral smear. The reticulocyte count is critical in distinguishing primary failure of red blood cell production (which has decreased reticulocytes or no reticulocytes) from increased red cell destruction (which has increased numbers of reticulocytes). Accurate assessment of the reticulocyte count requires a corrected count (reticulocyte count multiplied by the patient's Hct/normal Hct). If the reticulocyte count is decreased, consider primary bone marrow disorders or deficiency of iron, vitamin B<sub>12</sub>, or folate. If the reticulocyte count is increased, consider hemolysis or blood loss as the source of the anemia.

### Types of anemia based upon morphologic classification:

There are three types of anemia based upon the patient's MCV: microcytic, normocytic, and macrocytic.

- MCV < 80 femtoliter (fL) is microcytic.
- MCV from 80 to 100 fL is normocytic.
- MCV > 100 fL is macrocytic.

## MICROCYTIC ANEMIAS

**Overview:** MCV < 80 fL. Types include iron deficiency anemia, thalassemias, and anemia of chronic disease.

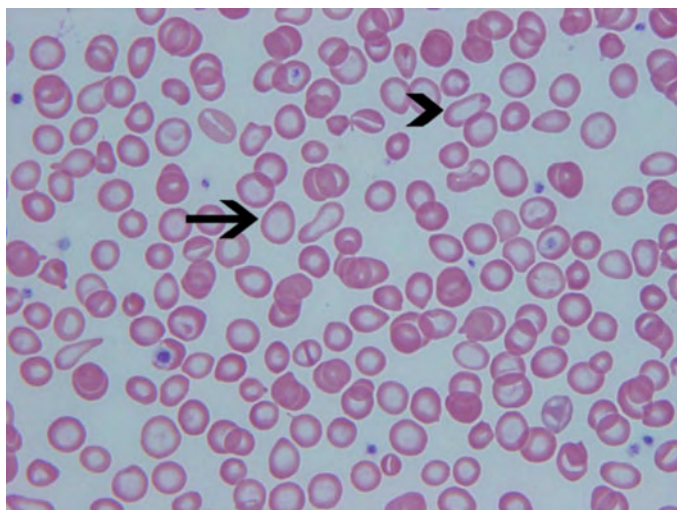
### Iron deficiency anemia

- **Causes:** In the United States, iron deficiency anemia is most commonly the result of chronic loss of blood due to gastrointestinal hemorrhage or menstruation. Therefore, it is often an anemia due to two mechanisms: chronic blood loss and subsequent decreased production. Other causes include dietary iron deficiency (rare in the U.S.), malabsorption of iron, or increased demands for iron (such as occur in pregnancy).
- **Laboratory findings in iron deficiency anemia** (Table 12-2): Decreased ferritin (storage form of iron), decreased serum iron, decreased iron in bone marrow on biopsy, increased total iron-binding capacity (TIBC), increased RDW, and decreased transferrin saturation (transferrin saturation is the ratio of serum iron to TIBC, which is normally > 20%). In iron deficiency anemia, transferrin saturation is normally < 10%.
- **Microscopic morphology of iron deficiency anemia:** Prominent central pallor of red blood cells due to greatly reduced hemoglobin; “pencil cells” (i.e., elongated red blood cells); and marked anisocytosis of red blood cells (i.e., variation in size), which corresponds to high RDW (Figure 12-1).

**TABLE 12-2.** Laboratory Studies Used to Differentiate Microcytic Anemias

Type of Microcytic Anemia	Ferritin Concentration	Serum Iron Concentration	TIBC	Transferrin Saturation
Iron deficiency anemia	↓	↓	↑	↓
Thalassemia	N	N	N	N
ACD	↑	↓	↓	↑

TIBC, total iron binding capacity; N, normal; ACD, anemia of chronic disease.



**Figure 12-1.** Iron deficiency anemia. The majority of the red cells in this photomicrograph exhibit central pallor (arrow). Also present is a characteristic “pencil cell” (arrowhead). Wright-Giemsa, 1000×.



## THALASSEMIAS

**Basic description:** Deficient production of hemoglobin due to mutation or complete loss of a globin chain. There are four copies of the  $\alpha$ -globulin chain gene and two copies of the  $\beta$ -globulin chain gene; the types are  **$\alpha$ -thalassemia** and  **$\beta$ -thalassemia**.

### $\alpha$ -Thalassemia

■ **Basic description:** Condition is due to complete loss of one or more of the four copies of the  $\alpha$ -globulin chain gene. The loss of one copy of the gene is silent (the patient is a carrier), and the loss of two copies is asymptomatic (called  **$\alpha$ -Thal trait**). The loss of three copies of the gene (called **HbH disease**) and of four copies (called **hydrops fetalis**) produces symptoms.

■ **Epidemiology:** Prevalent in Africans and Asians.

#### ■ Important points regarding $\alpha$ -thalassemia

- Loss of three copies of the gene results in elevated levels of HbH ( $\beta_4$ ) and HbBart (four  $\gamma$  chains).
- $\beta_4$  tetramers are relatively soluble and *do not* damage cells as do  $\alpha$  chain tetramers.
- Loss of four  $\alpha$  chains usually results in death in utero (hydrops fetalis).

### $\beta$ -Thalassemia

■ **Basic description:** Malfunction of the gene is due to a mutation in the promoter sequence or to a mutation that causes chain termination or splicing defects, unlike in  $\alpha$ -thalassemia, in which the disease is due to complete loss of one or more of the  $\alpha$ -globulin chain genes. Mutations producing chain termination result in complete loss of protein ( $\beta^0$ ). Mutations in the promoter sequence may result in decreased production of the protein ( $\beta^+$ ). Mutations causing splicing defects can cause no splicing to occur ( $\beta^0$ ), or form new splice sites with some normal protein being produced ( $\beta^+$ ). Patients who are  $\beta^+/\beta^+$  or  $\beta^0/\beta^0$  have **thalassemia major**; patients who are  $\beta^+/\beta$  or  $\beta^0/\beta$  have **thalassemia minor**; and patients who are  $\beta^+/\beta^+$  (minor variants, not severe enough to cause thalassemia major) or  $\beta^+/\beta^0$ , have **thalassemia intermedia**.

#### ■ Important points regarding $\beta$ -thalassemia

- $\alpha$ -Chains are insoluble and damage red blood cells, resulting in intravascular hemolysis and ineffective erythropoiesis (apoptosis of red blood cells in marrow).
- Patients with  $\beta$ -thalassemia have elevated HbA<sub>2</sub>.

■ **Epidemiology:** Common in Mediterranean countries (where patients have a worse form of the disease) and in parts of Africa and Southeast Asia.

#### ■ Complications

- Thalassemia major requires blood transfusions from about the time of birth, eventually leading to secondary hemochromatosis.
- Bone marrow expansion leads to skeletal abnormalities.

**Laboratory findings in thalassemia** (see Table 12-2): Iron deficiency anemia and thalassemia are both hypochromic

microcytic anemias. In thalassemia, however, the decrease in Hb is out of proportion to that of the decrease in MCV (e.g., Hb of 10.0 mg/dL and MCV of 55), whereas in iron deficiency anemia, the decrease in Hb and MCV are proportional (e.g., Hb of 10.0 mg/dL and MCV of 70).

#### Morphology of thalassemia

- **Peripheral blood smear:** Hemolysis, **anisocytosis** (i.e., variation in size of red blood cell), **poikilocytosis** (i.e., variation in shape of red blood cell), microcytosis, target cells, and reticulocytopenia (Figure 12-2).
- **Other findings:** “Crew-cut” skull seen on radiograph, due to bony growth; splenomegaly, hemosiderosis, or hemochromatosis.

### ANEMIA OF CHRONIC DISEASE

**Basic description:** Anemia that occurs in the background of a chronic disease (e.g., neoplasms such as lung carcinoma or Hodgkin disease; autoimmune conditions such as rheumatoid arthritis; or chronic infections such as tuberculosis). Anemia of chronic disease is usually normocytic, but in the late stage can be microcytic.

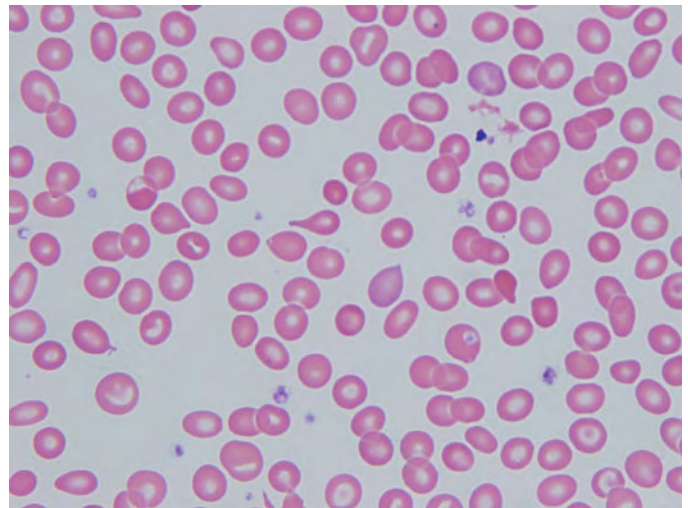
**Mechanism of anemia of chronic disease:** Patients with anemia of chronic disease have elevated levels of storage iron (although serum iron is decreased) and increased ferritin and decreased TIBC, but they cannot transfer the iron from the phagocytic cells to the erythroid precursors. Elevated levels of interleukin-1 (IL-1), tumor necrosis factor (TNF), and interferon- $\gamma$  associated with chronic disease processes cause decreased levels of erythropoietin and stimulate **hepcidin**. Hepcidin is a protein that normally impairs release of iron from storage.

**Laboratory findings** (see Table 12-2): Decreased TIBC, elevated ferritin, and transferrin saturation > 10%.

**Other causes of microcytic anemia: Sideroblastic anemia** (due to failure to synthesize iron); lead poisoning (lead blocks incorporation of iron into heme); alcohol use (ethanol inhibits enzymes in the heme synthetic pathway); and genetic diseases (e.g., **Pearson disease**).

**Laboratory findings distinguishing microcytic anemias** (see Table 12-2)

- **Iron deficiency anemia:** Increased RDW, TIBC, and erythrocyte protoporphyrin; decreased iron, transferrin saturation, and ferritin.
- **Anemia of chronic disease:** Increased ferritin and erythrocyte protoporphyrin; decreased serum iron (other tests are normal). In anemia of chronic disease, the MCV usually is > 78.
- **Thalassemia minor:** Elevated HbA<sub>2</sub> helps distinguish it from thalassemia trait. Meltzer index (MCV/RBC) is > 13 in iron deficiency and < 13 in thalassemia minor.
- **Sideroblastic anemia:** Elevated RDW and transferrin saturation; other tests are normal.



**Figure 12-2.**  $\beta$ -Thalassemia minor. As would be expected, the changes in this blood smear are not prominent. The number of red blood cells is decreased, and there is only a minor variation in cell size (anisocytosis) and shape (poikilocytosis). Wright-Giemsa, 1000 $\times$ .

## MACROCYTIC ANEMIA

**Overview:** MCV > 100. A subpopulation of macrocytic anemias is referred to as **megaloblastic anemia** and usually has an MCV > 110. The main causes of megaloblastic anemia are deficiencies of vitamin B<sub>12</sub> and folate.

### VITAMIN B<sub>12</sub> DEFICIENCY

**Pathogenesis:** Impaired DNA synthesis (i.e., S phase), which involves all bone marrow precursors and not just red blood cells. The impairment of DNA synthesis slows nuclear maturation but not cytoplasmic maturation, so cells have nuclear-cytoplasmic dyssynchrony.

#### Complications of vitamin B<sub>12</sub> deficiency

- Anemia, thrombocytopenia, and leukopenia.
- **Ineffective erythropoiesis:** Patients have an adequate number of red blood cell precursors, but many cells undergo apoptosis in bone marrow because of impaired nuclear maturation.
- **Neurologic deficiencies:** Peripheral neuropathy and spinal cord pathology (**subacute combined degeneration** involving posterior and lateral columns of the spinal cord). *Neurologic deficiencies are not seen in folate deficiency.*

#### Important points

- Vitamin B<sub>12</sub> is required for the regeneration of tetrahydrofolate. In vitamin B<sub>12</sub> deficiency, administering folate will correct the anemia; however, it will not treat or prevent the neurologic deficiency. Administering folate bypasses the need for vitamin B<sub>12</sub> in the production of red blood cells (i.e., there is no need to regenerate tetrahydrofolate if it is constantly being supplied).
- Vitamin B<sub>12</sub> deficiency causes elevated levels of methylmalonic acid and homocysteine.

#### Causes of vitamin B<sub>12</sub> deficiency

- Pernicious anemia (see associated condition below) is the most common cause.
- Rarely dietary in the United States, but can occur in vegetarians.
- Gastrectomy (intrinsic factor required for vitamin B<sub>12</sub> absorption is produced by parietal cells of the stomach).
- Ileal disease (e.g., Crohn disease) or resection, due to impaired resorption.
- *Diphyllobothrium latum* (giant fish tapeworm).

#### Clinical presentation of vitamin B<sub>12</sub> deficiency

- Defect is not just limited to red blood cells, but to all cells that are growing rapidly. Therefore, symptoms of the condition are related to pancytopenia (loss of all forms of bone marrow cells) and to the loss of intestinal cells, causing diarrhea and malabsorption.
- Subacute combined degeneration is damage of the dorsal columns of the spinal cord, causing bilateral loss of proprioception, and damage of the corticospinal tracts of the spinal cord, causing spastic paresis.



**Associated condition: pernicious anemia**

- **Basic description:** Pernicious anemia is another term for autoimmune gastritis, which secondarily causes vitamin B<sub>12</sub> deficiency because of loss of parietal cells and, thus, of intrinsic factor (IF).
- **Pathogenesis of pernicious anemia:** Autoimmune condition due to antibodies against parietal cells, or blocking antibodies that prevent binding of vitamin B<sub>12</sub> to IF, or antibodies against the vitamin B<sub>12</sub>-IF complex. Any of these three antibodies prevents the absorption of vitamin B<sub>12</sub>.

**FOLATE DEFICIENCY**

**Important point:** The megaloblastic anemia caused by folate deficiency is clinically indistinguishable from that caused by vitamin B<sub>12</sub> deficiency without testing of the levels of each vitamin. There are, however, some important differences between the two deficiencies.

**Differences between deficiencies of folate and vitamin B<sub>12</sub>**  
(Table 12-3)

- Folate deficiency does *not* cause neurologic deficits.
- In the United States, folate deficiency is often due to dietary deficiency.
- Folate deficiency is *not* associated with pernicious anemia.

**Microscopic morphology of megaloblastic anemia**

- **Peripheral blood smear:** Oval macrocytes and hypersegmented neutrophils; pancytopenia (Figure 12-3).
- **Bone marrow biopsy:** Hyperplasia; patients have **ineffective erythropoiesis** in which cells are dividing, but they undergo apoptosis in the bone marrow due to impaired DNA synthesis.

**OTHER FORMS OF ANEMIA ASSOCIATED WITH DECREASED PRODUCTION**

**Overview:** When comparing the initial outline of mechanisms of anemia to the classification of anemia based upon morphology, with the exception of aplastic anemia, infiltration of bone marrow (i.e., myelophthisic anemia), and pure red cell aplasia, most anemias due to decreased production can be categorized as microcytic or macrocytic. As microcytic and macrocytic anemias have been discussed in their own sections, this section will discuss aplastic anemia, myelophthisic anemia, and pure red cell aplasia.

**APLASTIC ANEMIA**

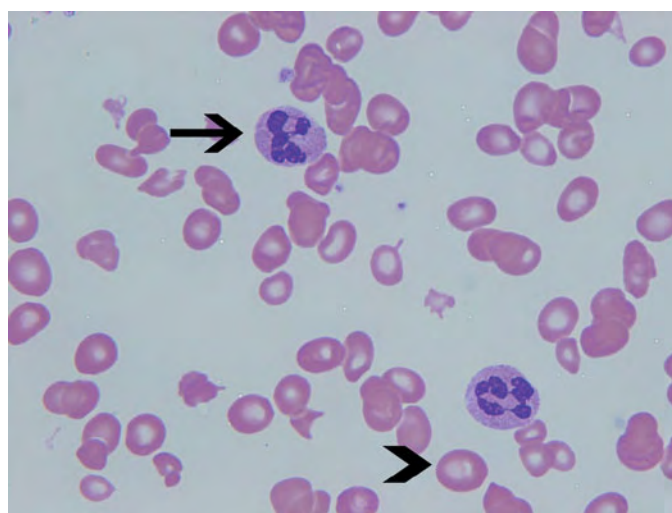
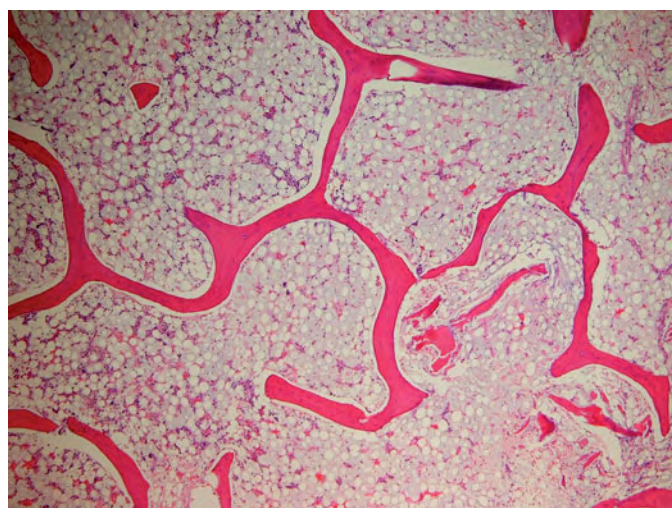
**Basic description:** Anemia due to absence (or near absence) of red blood cells in the bone marrow (Figure 12-4). Aplastic anemia also involves other hematopoietic cells, unless it is pure red cell aplasia, a disease associated with thymomas.

**Causes of aplastic anemia**

- Idiopathic (> 50% of cases).
- Secondary to drug therapy: May be a dose-dependent response (as seen with use of alkylating agents), or an idiosyncratic response (as seen with use of chloramphenicol).

**TABLE 12-3.** Comparison and Contrast of Vitamin B<sub>12</sub> and Folate Deficiencies

Feature	Vitamin B <sub>12</sub> Deficiency	Folate Deficiency
Form of anemia caused	Megaloblastic anemia	Megaloblastic anemia
Cause of neurologic deficits	Yes	No
Common cause of vitamin deficiency	Pernicious anemia	Dietary

**Figure 12-3.** Megaloblastic anemia. This photomicrograph illustrates the two characteristic cells of megaloblastic anemia, hypersegmented neutrophils (arrow) and oval macrocytes (arrowhead). Wright-Giemsa, 1000×.**Figure 12-4.** Aplastic anemia. This low-power photomicrograph of the bone marrow exhibits only a small amount of hematopoiesis. Hematoxylin and eosin, 40×.

- Secondary to toxins: Benzene.
- Secondary to infections: Parvovirus B19, Epstein-Barr virus (EBV), human immunodeficiency virus (HIV), and hepatitis (not hepatitis A, B, or C).
- Radiation.
- Genetic (e.g., **Diamond-Blackfan syndrome**).

**Pathogenesis of aplastic anemia:** Possibly due to suppression of stem cell function, or because the inciting agent exposes new antigens on the red blood cells, which are acted upon by the immune system.

**Important point:** No splenomegaly.

#### Laboratory findings for aplastic anemia

- Two of three findings are needed to determine a diagnosis of aplastic anemia: Neutrophil count  $< 500/\mu\text{L}$ , platelet count  $< 20,000/\mu\text{L}$ , or anemia with corrected reticulocyte count of  $< 1\%$ .
- Bone marrow: Cellularity  $< 25\%$ .

**Clinical presentation:** Can be insidious. Symptoms include weakness, fatigue, dyspnea, palpitations, gingival bleeding, epistaxis, and recurrent bacterial infections.

### MYELOPHTHISIC ANEMIA

**Basic description:** Anemia due to space-occupying disease of the bone marrow (**Figure 12-5**); often associated with extramedullary hematopoiesis (i.e., hematopoiesis outside the bone marrow, often in the liver or spleen).

**Causes of myelophthistic anemia:** Metastatic tumor or idiopathic fibrosis of bone marrow.

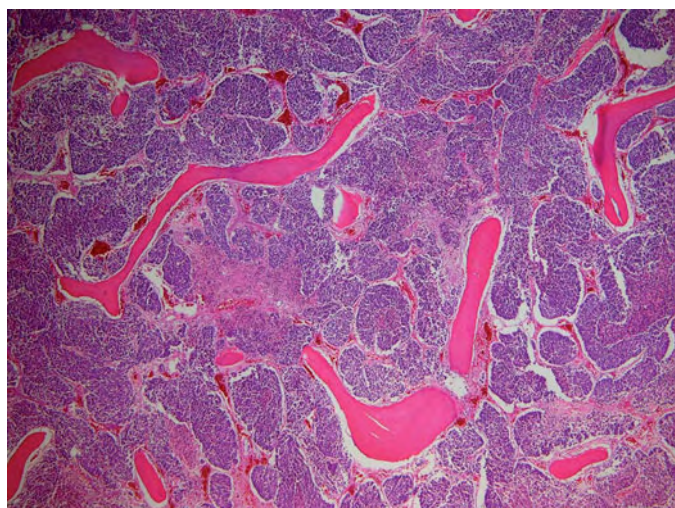
### PURE RED CELL APLASIA

**Overview:** May be primary or secondary. Secondary causes of pure red cell aplasia include thymoma (**Figure 12-6**), large granular lymphocytic leukemia, and autoimmune diseases.

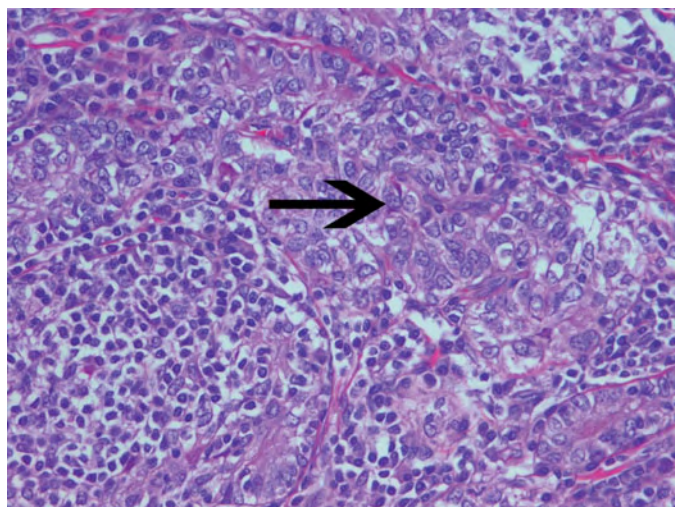
### HEMOLYTIC ANEMIAS

**Overview:** All hemolytic anemias have increased red blood cell destruction (either intravascular or extravascular), increased erythropoiesis (elevated erythropoietin and reticulocytosis), and increased iron deposition in tissues (mainly in the spleen and liver). Some patients have pigment gallstones and occasional extramedullary hematopoiesis.

**Laboratory findings for hemolytic anemia:** Patients with intravascular hemolysis have decreased plasma haptoglobin, increased unconjugated bilirubin, increased lactate dehydrogenase (LDH), positive urine hemosiderin, and positive urine hemoglobin. Patients with extravascular hemolysis have decreased haptoglobin and increased unconjugated bilirubin, but they do not have positive results for urine hemosiderin or urine hemoglobin.



**Figure 12-5.** Myelophthistic anemia. Myelophthistic anemia is due to a space-occupying lesion in the bone marrow, which hinders hematopoiesis. In this photomicrograph, the bone marrow space is expanded and the hematopoietic cells are obliterated by metastatic small cell lung carcinoma. Hematoxylin and eosin, 40 $\times$ .



**Figure 12-6.** Thymoma. The two histologic features of a thymoma are lymphocytes (left lower corner) and epithelial cells (arrow). Thymomas are associated with pure red cell aplasia. Hematoxylin and eosin, 400 $\times$ .

### Mechanisms of hemolytic anemias

- **Congenital** (e.g., enzyme deficiencies, defects of cytoskeleton, hemoglobinopathies) versus **acquired** (e.g., antibody-induced, mechanical fragmentation, membrane protein anchoring abnormalities, such as in PNH).
- **External factors** (e.g., antibody-induced, mechanical fragmentation) versus **internal factors** (e.g., enzyme deficiencies, hemoglobinopathies).

**Important point:** Hemolytic anemias can be immune-mediated or non-immune-mediated. Important laboratory testing used to distinguish these anemias are the **direct** and **indirect Coombs tests** (also called, respectively, **direct antiglobulin test** and **indirect antiglobulin test**).

#### Direct Coombs test

- **Assumption:** Antibodies causing the hemolysis are present on the surface of the red blood cells.
- **Mechanism:** By adding antibody against Ig (which is already presumed to be on the surface of the red blood cells), cross-linking occurs, resulting in agglutination of red blood cells.

#### Indirect Coombs test

- **Assumption:** Antibodies causing the hemolysis are present within the plasma, but are not on the surface of the red blood cells.
- **Mechanism:** The indirect Coombs test requires an additional step beyond that of the direct Coombs test. Red blood cells, with an antigen the antibodies react to, are first added to the patient's plasma. The antibodies present in the plasma bind to the added red blood cells. Then, as in the direct Coombs test, antibody is added, which cross-links the antibody bound to the red blood cells and causes agglutination of the red blood cells.

## ANTIBODY-MEDIATED DESTRUCTION OF RED BLOOD CELLS

**Overview:** Antibody-mediated destruction of red blood cells occurs through one of two main mechanisms: **isoagglutinin** and **autoimmune** reactions. Isoagglutinin causes of antibody-mediated destruction of red blood cells include red blood cell transfusion reactions and **erythroblastosis fetalis**. Red blood cell transfusion reactions occur when the recipient has an antibody against one of the donor's red cell antigens, and can be due to ABO incompatibility or to another blood group incompatibility. Erythroblastosis fetalis occurs when there is blood group incompatibility between mother and fetus. **Immuno-hemolytic anemias** represent hemolytic anemias with an autoimmune etiology. Types of immuno-hemolytic anemias include **warm autoimmune hemolytic anemia** and **cold autoimmune hemolytic anemia**. This section will discuss details of ABO incompatible blood transfusion reactions, non-ABO incompatible blood transfusion reactions, erythroblastosis fetalis, warm autoimmune hemolytic anemia, cold autoimmune hemolytic anemia, and cold hemolysin hemolytic anemia.



## ABO INCOMPATIBLE BLOOD TRANSFUSION REACTIONS

**Antibody type:** IgM.

**Area of hemolysis:** Intravascular.

**Results:** Hemoglobinemia leading to acute renal failure; high mortality rate.

**Important points:** Anti-A and anti-B IgM are naturally occurring antibodies; therefore, an ABO incompatible red cell transfusion does not require a previous exposure to an incompatible ABO blood type.

## NON-ABO INCOMPATIBLE BLOOD TRANSFUSION REACTIONS

**Antibody type:** Usually IgG; IgM occurs due to exposure to some non-ABO blood group antigens, but these reactions usually are not clinically significant.

**Area of hemolysis:** Extravascular (antibody binds to antigen on the transfused red blood cell, and the complex is removed by the spleen).

**Results:** Jaundice; loss of transfused unit.

**Important points:** Clinically significant antibodies to blood groups other than ABO (i.e., those that can cause destruction of red blood cells) usually require previous exposure to the antigen for formation. For example, the first time a patient who is D<sup>-</sup> is transfused with D<sup>+</sup> blood may result in the formation of an antibody, and the second transfusion, in the future, will result in hemolysis. Antibodies do not always form with exposure, but some blood antigens are highly immunogenic (as is D, in which antibodies form with exposure 85% of the time).

## ERYTHROBLASTOSIS FETALIS

**Basic description:** Condition due to maternal antibody against a fetal red blood cell antigen (usually D). When a mother who is D<sup>-</sup> has a child who is D<sup>+</sup>, the mother is exposed to the D antigen and develops anti-D antibodies. If she then has a second child who is D<sup>+</sup>, the second child can develop erythroblastosis fetalis because the maternal anti-D is IgG, which crosses the placenta and causes hemolysis of fetal red blood cells.

**Presentation of erythroblastosis fetalis:** Fetal hemolytic anemia, hydrops fetalis (i.e. severe fetal edema), and positive direct Coombs test. Unconjugated hyperbilirubinemia can be severe and may lead to **kernicterus**.

**Treatment and prevention:** Mothers who are D<sup>-</sup> are given Rh<sub>0</sub>D (an anti-D antibody) during pregnancy. When fetal red blood cells cross into the maternal circulation, the Rh<sub>0</sub>D binds to them, masking the D antigen from the mother and preventing her from forming antibodies against it.

**TABLE 12-4.** Comparison and Contrast of Warm and Cold Autoimmune Hemolytic Anemias

Feature	Warm Autoimmune Hemolytic Anemia	Cold Autoimmune Hemolytic Anemia	
Antibody type	IgG	IgM	
Antibody versus	Self antigens	I and i	
Coombs test	Positive	Negative	
Causes	Idiopathic B-cell neoplasms SLE Drug reactions	Acute Chronic	Mycoplasma, EBV B-cell neoplasms

SLE, systemic lupus erythematosus; EBV, Epstein-Barr virus.

### WARM AUTOIMMUNE HEMOLYTIC ANEMIA (TABLE 12-4)

#### General mechanism of warm autoimmune hemolytic anemia:

IgG versus self-antigen binds red blood cells at 37°C and acts as an opsonin. Then, red blood cells are removed by the phagocytic system. The red blood cell destruction is extravascular.

**Mechanisms of drug-induced hemolysis (a form of warm autoimmune hemolytic anemia):** There are three mechanisms of warm autoimmune hemolytic anemia due to drug-induced hemolysis.

- Stimulation of autoantibody production (e.g., due to  $\alpha$ -methyldopa).
- Drugs act as a hapten and induce antibody formation (e.g., due to penicillin).
- Immune complex deposition: Antibody binds to the drug, and complex deposits on surface of the red blood cell.

#### Causes of production of antibody versus self-antigens on red blood cells

- Primary: 60% of cases of warm autoimmune hemolytic anemia are idiopathic, with no identifiable cause.
- Secondary: Due to B-cell neoplasms, systemic lupus erythematosus, and drugs.

**Microscopic morphology of warm autoimmune hemolytic anemia:** Spherocytes in peripheral blood smear.

#### Clinical presentation of warm autoimmune hemolytic anemia

- Anemia, jaundice, elevated reticulocyte count. Patient may have splenomegaly.
- Coombs test is positive.

### COLD AUTOIMMUNE HEMOLYTIC ANEMIA (SEE TABLE 12-4)

**Mechanism:** IgM binds to red blood cells. IgM binding to I antigen is associated with *Mycoplasma* infections. IgM binding to i antigen is associated with EBV infections. The IgM binds at 30°C and also binds complement. The IgM releases at 37°C, leaving C3b, which acts as opsonin.

### Causes of cold autoimmune hemolytic anemia

- **Acute form:** *Mycoplasma pneumoniae*; infectious mononucleosis (EBV). Acute cold autoimmune hemolytic anemia is usually self-limited.
- **Chronic form:** Idiopathic; B-cell neoplasms.

**Morphology:** Spherocytes.

**Laboratory finding:** Coombs test is negative.

### COLD HEMOLYSIN HEMOLYTIC ANEMIA (PAROXYSMAL COLD HEMOGLOBINURIA)

**Mechanism:** An IgG antibody (referred to as **Donath-Landsteiner antibody**) binds to the P antigen on red blood cells at low temperatures, and complement then mediates intravascular hemolysis at 37°C.

**Causes:** Many cases occur after infections (e.g., *Mycoplasma*, measles).

### OTHER EXTERNAL CAUSES OF HEMOLYTIC ANEMIA

**Overview:** The above discussion of antibody-mediated destruction of red blood cells covers many of the external causes of hemolytic anemia (i.e., external to the red blood cell). However, there are a few other general categories of external causes that produce destruction of red blood cells. These other categories include trauma to red blood cells, infections, and splenic sequestration. A brief list of forms of trauma and infections causing red blood cell destruction are listed below.

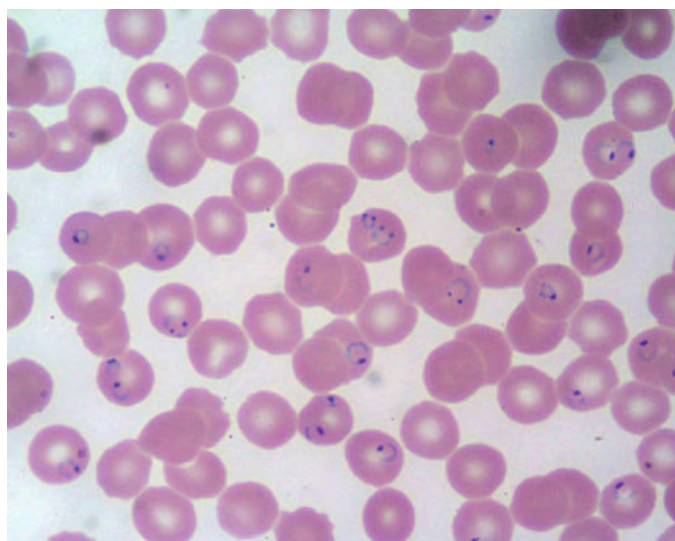
#### Traumatic causes of red blood cell destruction

- Artificial cardiac valves.
- Intravascular thrombi, due to thrombotic thrombocytopenic purpura (TTP), idiopathic thrombocytopenic purpura (ITP), or disseminated intravascular coagulation (DIC). Hemolysis due to one of these diseases is called **microangiopathic hemolytic anemia**.

**Infectious causes of red blood cell destruction:** Malaria (Figure 12-7); babesiosis.

### HEREDITARY CAUSES OF INCREASED DESTRUCTION OF RED BLOOD CELLS

**Overview:** The three general categories of hereditary disease processes causing increased destruction of red blood cells are defects in the cytoskeleton, structurally abnormal hemoglobins, and enzyme deficiencies. The most common condition causing defects in the cytoskeleton is hereditary spherocytosis, which will be discussed below. Although there are many structurally abnormal types of hemoglobins, only sickle cell anemia (due to



**Figure 12-7.** Malaria. This patient has an infection caused by *Plasmodium falciparum*. Note the characteristic heavy parasite load. Infection with the parasite can lead to hemolysis. Courtesy of Dr. Sean Hussey, University of Texas Southwestern Medical Center, Dallas, TX. Wright-Giemsa, 1000×.



HbS) will be discussed below. The most common enzyme deficiency causing increased destruction of red blood cells is glucose-6-phosphate dehydrogenase (G6PD) deficiency, which will be discussed later in this section.

### DEFECT IN CYTOSKELETON: HEREDITARY SPHEROCYTOSIS

**Inheritance pattern:** Three fourths of cases are autosomal dominant.

**Mutation:** Gene for one of the proteins that plays a role in spectrin binding to cytoskeletal matrix. The protein affected is usually ankyrin, but mutations also occur in the gene for spectrin, band 4.1, or band 3.

**Result of mutation:** Less deformable red blood cells become trapped in the spleen.

**Epidemiology:** 1 in 5000; prevalent in Northern Europeans.

**Complications of hereditary spherocytosis:** Mild anemia, splenomegaly (500–1000 g), jaundice (due to hemolysis and elevated unconjugated bilirubin), gallstones, and aplastic crisis.

**Microscopic morphology: Spherocytes** (small hyperchromatic red blood cells with no central pallor).

**Laboratory findings for hereditary spherocytosis:** Increased osmotic fragility (cell cannot swell in hypotonic solution because of a defect in the cytoskeleton); Coombs test is negative.

**Treatment:** Splenectomy can correct anemia.

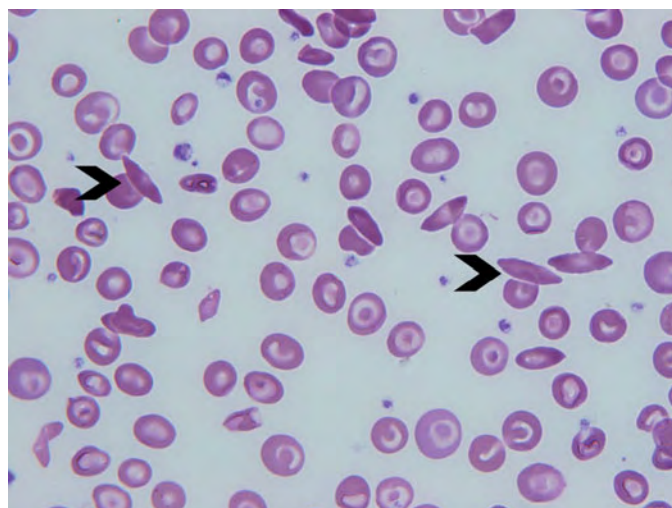
### STRUCTURALLY ABNORMAL HEMOGLOBIN: SICKLE CELL ANEMIA (FIGURE 12-8)

**Epidemiology:** Homozygotes have sickle cell anemia (all hemoglobin is HbS), and heterozygotes have **sickle cell trait** (only 50% of hemoglobin is HbS); 8% of Africans have sickle cell trait because of the protective effect conferred by the mutation versus malaria infection, and 0.2% of Africans have sickle cell anemia.

**Mutation:** In the sixth position of the  $\beta$ -globulin chain, a valine is exchanged for glutamic acid.

**Pathogenesis of sickle cell anemia:** Valine is hydrophobic, causing the hemoglobin to be “sticky”; therefore, HbS polymerizes under certain circumstances (e.g., deoxygenation). The sickling is initially reversible by oxygenation, but because of multiple episodes of sickling, the process is irreversible.

- HbS does *not* bind to HbA, so only rare sickling occurs in a heterozygote (i.e., patient with sickle cell trait).
- HbS does bind to HbC (another structurally abnormal hemoglobin).
- HbS does *not* bind to HbF, so children with sickle cell anemia do not present until the age of 5–6 months.
- When dehydration occurs, MCHC increases, which promotes sickling.
- When HbS is combined with  $\alpha$ -thalassemia (which has a lower MCHC), the incidence of sickling decreases.



**Figure 12-8.** Sickle cell anemia. This peripheral blood smear exhibits sickled cells (*arrowheads*). Sickled cells pass through the vasculature with more difficulty, becoming lodged in capillaries and other small vessels and leading to tissue ischemia. Ischemia in turn promotes additional sickling of the red blood cells. Wright-Giemsa, 1000 $\times$ .

- Normal transit time through the capillaries is not enough to cause sickling. For red blood cells to sickle, their transit time must be slowed. Inflammation or dehydration can delay transit time in the capillaries, or normal transit time in the bone marrow and the spleen can be sufficiently long to promote sickling.

### Complications of sickle cell anemia

- Anemia.
- Microvascular obstruction causes ischemia and infarction, which lead to the following conditions.
  - Painful vaso-occlusive crises caused by necrosis in bone marrow.
  - Necrotic bone marrow can embolize to the lung, causing **acute chest syndrome**. Pneumonia, as an infectious process, causes vascular dilation and congestion, which promote red blood cell sickling and, therefore, can potentiate acute chest syndrome.
  - Autopsplenectomy, with resultant increased risk of infections with encapsulated organisms.
  - Priapism, cerebral infarcts, and avascular necrosis of bone.
- Increased erythropoiesis, with bone resorption and bone deposition on the outside of the bone, producing a “crewcut” skull, as seen on radiograph.
- Defects in urine concentrating ability: The renal medulla is highly susceptible to damage because of its high tonicity and low oxygen tension.
- Renal papillary necrosis.
- *Salmonella* osteomyelitis.
- **Sequestration crises:** Sluggish flow can lead to the sequestration of sickled red blood cells in the spleen, with subsequent enlargement of the spleen.
- Aplastic anemia following infection with parvovirus.
- Renal failure and pulmonary failure are the leading causes of death in patients with sickle cell anemia.

### ENZYME DEFICIENCIES: G6PD DEFICIENCY

**Inheritance:** X-linked recessive trait.

**Epidemiology:** Prevalent in the Middle East and Africa (Africans have a more mild form of the disease).

**Effect of mutation:** Red blood cells are unable to regenerate glutathione, which normally helps reduce oxidized substances, because G6PD is needed to convert nicotinamide adenine dinucleotide phosphate (NADP) to reduced nicotinamide adenine dinucleotide phosphate (NADPH). Therefore, when exposed to oxidizing substances, red blood cells are more likely to be damaged.

**Associated substances (i.e., sources of oxidants):** Antimalarials, sulfonamides, aspirin, nitrofurantoin, viral hepatitis, and fava beans.

**Microscopic morphology of G6PD deficiency:** Denatured Hb forms **Heinz bodies**. **Bite cells** are red blood cells that look like they have a bite taken out of them. Bite cells are the result of phagocytes removing Heinz bodies from red blood cells.

## POLYCYTHEMIA

**Overview:** Polycythemia is an increased number of red blood cells, which can be relative due to a decreased amount of plasma, or polycythemia can occur as a primary or secondary process.

### Causes

- **Relative polycythemia:** Hemoconcentration; this form of polycythemia is not an absolute increase in the number of red blood cells, but rather a relative increase in the number of red blood cells due to a decreased amount of plasma.
- **Primary polycythemia: Polycythemia rubra vera**, which is a neoplastic proliferation of red blood cells.
- **Secondary polycythemia** (due to stimulus to increase red blood cell production)
  - Lung disease.
  - Cyanotic heart disease.
  - Erythropoietin-producing tumors: renal cell carcinoma, hepatoma, and cerebellar hemangioblastoma.

## DISEASES OF WHITE BLOOD CELLS

**Overview:** Although there are many reactive types of leukocytosis and leukopenia (Table 12-5), the neoplastic diseases responsible for leukocytosis and leukopenias are some of the most clinically important. Basically, leukemias are conditions in which the neoplastic cells are in the blood, and lymphomas are conditions in which the neoplastic cells are in the lymph nodes. Overlap does occur, and the two conditions are *not* mutually exclusive. Symptoms of leukemias and lymphomas relate to the cells affected. In leukemia, the neoplastic cells replace the normal hematopoietic population, and patients will have anemia (with pallor and fatigue), thrombocytopenia (with bleeding), and leukopenia (with propensity for infections).

**TABLE 12-5.** Causes of Reactive Increases and Decreases in Number of White Blood Cells

Finding	Cause	More Specific Cause
Reactive neutropenia	Ineffective granulopoiesis	Chemotherapeutic agents, infiltrative processes, drugs SLE, splenic sequestration
	Accelerated removal	
Reactive neutrophilia	Bacterial infections, tissue necrosis	
Reactive eosinophilia	Allergic reactions, drugs, parasites	
Reactive monocytosis	Chronic infections, collagen vascular disease, inflammatory bowel disease	
Reactive lymphocytosis	Viral infections, tuberculosis	

SLE, systemic lupus erythematosus.



Because lymphomas are proliferations within lymph nodes, patients often present with a painless mass. Leukemias are either acute (composed of blasts) or chronic (composed of more mature precursor cells), and are either lymphoid or myeloid in origin. Together, these two groups create four possible pairings: acute myeloid, acute lymphoid, chronic myeloid, and chronic lymphoid leukemias. About 90% of cases of adult acute leukemia are acute myeloid leukemia (AML), and 90% of cases of childhood acute leukemia are acute lymphoid leukemia (ALL). Lymphomas are either Hodgkin lymphoma or non-Hodgkin lymphoma. This part of the chapter will discuss myelodysplastic syndromes, acute and chronic leukemias, chronic myeloproliferative disorders, Hodgkin lymphoma, various types of non-Hodgkin lymphoma, plasma cell dyscrasias, and bleeding disorders.

## MYELODYSPLASTIC SYNDROMES (MDS)

**Basic description:** A group of conditions caused by a defect in cellular maturation, resulting in disorganized and ineffective hematopoiesis.

**Clinical course:** Depends upon specific type.

### Important points regarding myelodysplastic syndromes

- MDS may be primary or secondary; secondary MDS is often therapy related.
- Secondary MDS is difficult to treat, and many patients progress to a myeloid leukemia.

### Cytogenetic abnormalities associated with MDS

- Deletion of the long arm of chromosome 5 (referred to as **de novo 5q- syndrome**).
  - **Clinical features of de novo 5q- syndrome:** Patients with this mutation are usually older women with refractory macrocytic anemia and normal or elevated platelet counts. The 5q- syndrome has a better prognosis than other forms of MDS.
- Deletion of the short arm of chromosome 7 (7p-): Has worse prognosis.

**Microscopic morphology of MDS:** The exact morphology depends upon the specific type of MDS. Listed below are general histologic features of MDS.

- Macrocytic erythroid cells with basophilic stippling.
- Hypogranular and hypolobated neutrophils (bilobed nuclear morphology, which is referred to as **pseudo Pelger-Huët anomaly**).
- Micromegakaryocytes.
- Normocellular or hypercellular bone marrow.

**Clinical presentation of MDS:** Signs and symptoms are largely those of cytopenias, including bleeding and bruising due to decreased platelets; increased risk of infection due to neutropenia; and fatigue, weakness, and dyspnea due to decreased production of red blood cells. Patients can have splenomegaly (25%).

## OVERVIEW OF LEUKEMIA AND LYMPHOMA

**Overview:** The neoplastic process represents a monoclonal proliferation resulting from one transformed cell. Thus, testing such as immunoglobulin heavy-chain rearrangement or analysis of  $\kappa$  or  $\lambda$  light chains will reveal only one type. About 80–85% of leukemias and lymphomas are B cell in origin.

### Surface markers expressed by myeloid and lymphoid cells (can be used to analyze origin of neoplastic cell)

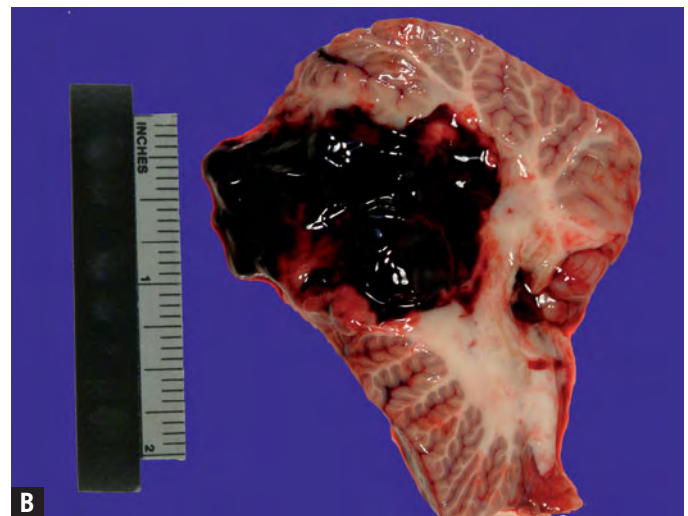
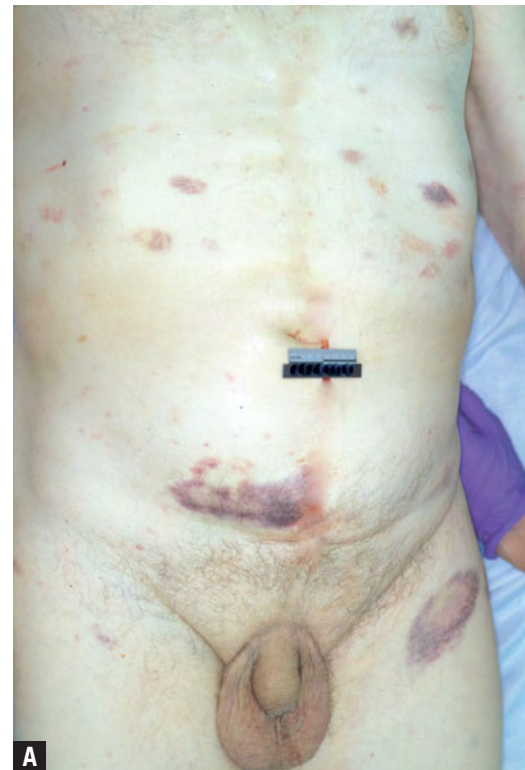- B-cell markers: CD10, CD19, and CD20
- T-cell markers: CD2, CD3, CD4, CD7, and CD8
- Lymphoblast: TdT
- Myeloid markers: CD13, CD14, CD15, and CD64
- Stem cell marker: CD34

**Signs and symptoms:** The signs and symptoms listed below apply mainly to leukemia, since most lymphomas present as a painless mass. However, in advanced states where there is metastases and extensive bone marrow involvement, lymphomas can present with many of the listed signs and symptoms.

- Damage to bone marrow by leukemias and metastatic lymphomas causes anemia, which will produce pallor, dyspnea, and fatigue; leukopenia, which causes the patient to be susceptible to infections, fever, and sepsis; and thrombocytopenia, which causes abnormal bleeding (e.g., petechial hemorrhages, ecchymoses) (Figure 12-9 A and B).
- The neoplasms are disorders of the immune system; therefore, the neoplastic cells may be responsible for a hypogammaglobulinemia or autoimmune complications.
- Acute leukemias usually have a sudden onset of a few months from symptoms to diagnosis, whereas chronic leukemias may be an incidental diagnosis determined in patients who are hospitalized for other reasons.
- Bone pain from expansion of marrow; lymphadenopathy and splenomegaly are due to infiltration of lymph nodes and the spleen by neoplastic cells.
- Hypertrophy of gingivae is due to infiltration with leukemic cells.
- Meningismus and cranial nerve deficits are due to infiltration of meninges with leukemic cells.
- Occlusion of blood vessels leads to priapism; central nervous system (CNS) symptoms (e.g., headache, blurring of vision), and strokes.

### Microscopic morphology of leukemia

- **Lymphoid leukemias:** High nuclear to cytoplasmic ratio; few nucleoli.
- **Myeloid leukemias:** More prominent cytoplasm; more prominent nucleoli.
- **Acute leukemias:** Composed of immature cells (i.e., blasts) that are using their chromatin, so it will be euchromatin and the nucleus will have a smooth texture.
- **Chronic leukemias:** Composed of mature cells (e.g., myelocytes) that are *not* using their chromatin, so it will be more heterochromatin and the nucleus will have a more granular texture.



**Figure 12-9.** Hemorrhage due to leukemia. This patient has multiple cutaneous hemorrhages (ecchymoses) due to a coagulopathy associated with leukemia. **A**, Note the large hemorrhages on the anterior surface of the left thigh and on the right lower quadrant of the abdomen, as well as other smaller hemorrhages on the upper torso. **B**, Cerebellar hemorrhage, which was the cause of death of this patient. Courtesy of Dr. Gary Dale, Forensic Science Division, Montana State Department of Justice, Missoula, MT.

## LEUKEMIA

**Overview:** Risk factors for leukemia include high-dose radiation and benzene. The clinical presentation of acute leukemia is usually due to complications of bone marrow failure (i.e., anemia, infections, bleeding), and proliferating blasts can produce bone pain. There are four types of leukemia: acute lymphoid leukemia, chronic lymphoid leukemia, acute myeloid leukemia, and chronic myeloid leukemia (see below). The four types of leukemia are each associated with specific cell markers and genetic abnormalities (Table 12-6).

### ACUTE LYMPHOID LEUKEMIA (ALL) (SEE TABLE 12-6)

**Basic description:** Neoplastic monoclonal proliferation of lymphoid cells, predominantly present in the blood. The neoplastic proliferation is composed of lymphoblasts. ALL is subdivided into several categories, based upon the CD markers present on the cell. Most are **precursor B-cell type** (CD10 positive); some are **early precursor B-cell type** (CD10 negative); and others are **pre-B cell type**, which is defined by the presence of cytoplasmic Ig.

**Epidemiology:** ALL occurs more commonly in children and represents 70% of all childhood leukemias. An increased incidence is seen in patients with Down syndrome.

**Markers:** Most cases of ALL are precursor B-cell type and cells are positive for CD19, CD20, and CD10; however, 20% are precursor T-cell type.

- Precursor B-cell leukemia presents with leukemia and extensive bone marrow involvement.
- Precursor T-cell leukemia/lymphoma (see below): Male predominance; thymic involvement.

#### Good prognostic factors for ALL

- Hyperdiploid (> 50 chromosomes per cell).
- Age of patient: 2–10 years.
- CD10 positive.
- t(12;21) involving *TEL1* and *AML1*.
- Low white blood cell count.

**TABLE 12-6.** Cell Markers and Genetic Abnormalities for Leukemia

Form of Leukemia	Cell Markers	Genetic Abnormality
Acute lymphoid (lymphoblastic) leukemia (ALL)	Precursor B-cell	CD 10+
	Early precursor B-cell	CD10-
	Pre-B-cell	Cytoplasmic Ig+
Chronic lymphocytic leukemia (CLL)	CD 19,20,23, and 5 positive	del 13q12-14 and del 11q trisomy 12
Acute myelogenous leukemia (AML)	CD 13,15, 64 positive	t(15;17)– <i>PML/RARA</i> t(8;21)– <i>CBF<math>\alpha</math>/ETO</i>
Chronic myelogenous leukemia (CML)		t(9;22)– <i>bcr-abl</i>



### Poor prognostic factors for ALL

- Hypodiploid.
- Age younger than 2 years or older than 10 years.
- Male gender.
- t(9;22), and translocations involving *ML1* (chr 11q23).
- High white blood cell count ( $> 100,000$  cells/ $\mu$ L).

**Important points:** ALL, especially during recurrences, can involve the CNS and testes.

**Microscopic morphology of ALL:** Nucleus with smooth chromatin (Figure 12-10); myeloperoxidase negative; positive for PAS and TdT.

### CHRONIC LYMPHOID LEUKEMIA (CLL) (SEE TABLE 12-6)

**Basic description:** Neoplastic monoclonal proliferation of lymphoid cells, predominantly present in the blood. The neoplastic proliferation is composed of mature lymphocytes.

**Epidemiology:** Patients are older than 50 years of age; male to female ratio is 2:1. CLL is the most common form of leukemia in the United States (represents 30% of adult leukemias).

**Markers for CLL:** Neoplastic cells are positive for CD19, CD20, CD23, and CD5.

**Associated mutations:** del 13q12-14; trisomy 12; deletions 11q and 17p. Leukemias associated with a mutation have a worse prognosis.

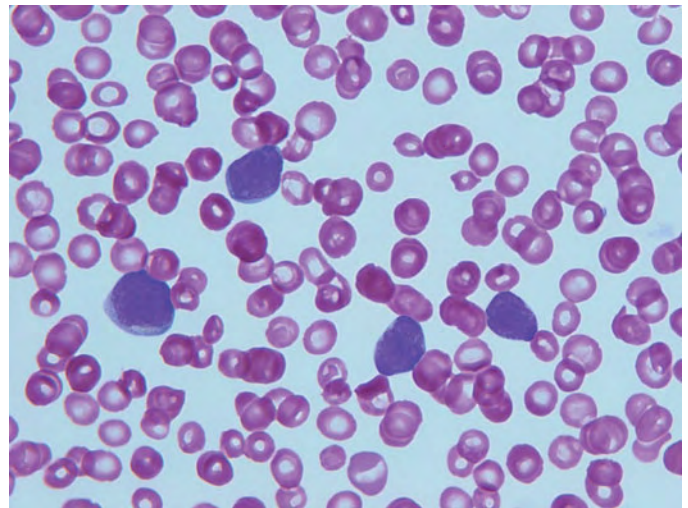
**Prognosis of CLL:** Overall survival is long (about 10 years). Some patients undergo transformation to **prolymphocytic leukemia** (with  $< 1$ -year survival) or to diffuse large B-cell lymphoma.

### Complications of CLL

- Hypogammaglobulinemia.
- 10–15% of patients develop autoimmune hemolytic anemia.
- Immune thrombocytopenia.
- 5% of cases transform to a diffuse large B-cell lymphoma (referred to as **Richter transformation**).

### Important points regarding CLL

- The features of CLL and **small lymphocytic lymphoma** (SLL) overlap. Both conditions are very similar, except that CLL denotes prominent involvement of the blood and SLL denotes prominent involvement of the lymph nodes. The close overlap of these two diseases illustrates how leukemia and lymphoma are *not* mutually exclusive entities.
- CLL is CD5 positive. CD5 is a T-cell marker, but 80% of cases of CLL are B-cell derived; therefore, expression of CD5 is an aberrant expression of a cell marker.
- CLL is the most common type of leukemia in the United States.



**Figure 12-10.** Acute lymphoid leukemia (ALL). The four white blood cells (lymphoblasts) in the photomicrograph have a high nuclear to cytoplasmic ratio, and the chromatin in the nuclei is finely dispersed and homogenous in appearance. These changes are consistent with an acute leukemia of lymphocytic origin. Wright-Giemsa, 1000 $\times$ .

**Microscopic morphology of CLL (Figure 12-11)**

- Cells have a “cracked earth” or “gingersnap” appearance.
- Cells are fragile. Cells that break during processing on the slide are referred to as “**smudge cells**.”

**Clinical presentation of CLL**

- **Symptoms:** Many patients are asymptomatic. Some patients experience fatigue and weight loss.
- **Signs:** Many patients have a normal physical examination. Some patients have splenomegaly.

**ACUTE MYELOID (MYELOGENOUS) LEUKEMIA (AML)**

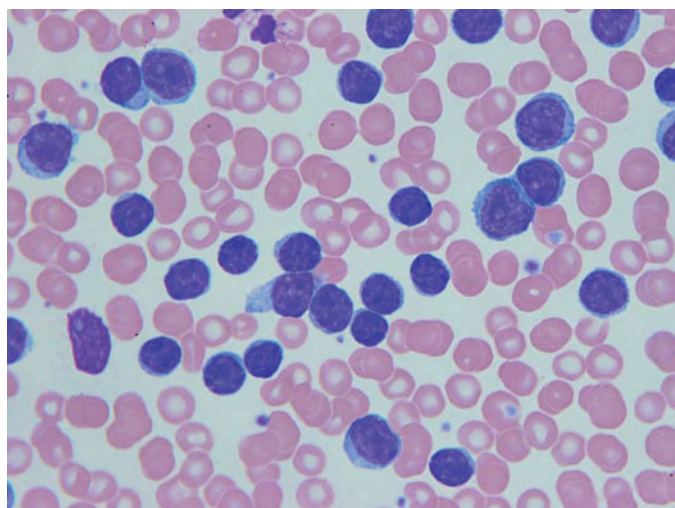
**Basic description:** Neoplastic monoclonal proliferation of one or more forms of myeloid cells (i.e., red blood cells, megakaryocytes, neutrophils, or monocytes). AML is a category of leukemia with many subtypes based upon the cell of origin and the degree of differentiation.

**Classification (Table 12-7)**

- FAB (French-American-British): Older classification scheme for leukemias based upon the cell line the leukemia was derived from and its differentiation.
- World Health Organization (WHO) classification: Newer classification scheme for leukemias based largely upon cytogenetic abnormalities and outcomes. One category of the WHO classification is acute myeloid leukemia not otherwise categorized, which essentially follows the older FAB classification.

**Epidemiology:** Predominantly older patients.

**Markers:** Neoplastic cells are positive for CD13, CD15, and CD64.



**Figure 12-11.** Chronic lymphocytic leukemia (CLL). The white blood cells in this photomicrograph are increased in number and have a high nuclear to cytoplasmic ratio. The chromatin in the nuclei is clumped and more heterogeneous in appearance. The terms “cracked earth” and “gingersnap” are used to describe the nuclear appearance of CLL cells. Wright-Giemsa, 1000 $\times$ .

**TABLE 12-7.** Abbreviated WHO Classification of Acute Myeloid Leukemia

AML with recurrent genetic abnormalities	AML with t(8;21) AML with inv(16) AML with t(15;17) AML with 11q23 abnormalities
AML with multilineage dysplasia	Following a myelodysplastic syndrome Without antecedent myelodysplastic syndrome
AML and myelodysplastic syndromes, therapy related	Alkylating agent related Topoisomerase II inhibitor related
AML not otherwise categorized	AML minimally differentiated (FAB M0) AML without maturation (FAB M1) AML with maturation (FAB M2) Acute myelomonocytic leukemia (FAB M4) Acute monoblastic and monocytic leukemia (FAB M5) Acute erythroid leukemia (FAB M6) Acute megakaryoblastic leukemia (FAB M7)

AML, acute myeloid leukemia; FAB (French-American-British).

### Associated cytogenetic abnormalities

#### ■ t(15;17)

- **Genes involved:** *PML* and *RARA* (retinoic acid receptor).
- **Consequence of translocation:** Cells are fixed at the promyelocyte stage of differentiation. Treatment with all-trans-retinoic acid (ATRA) matures the cells.
- This translocation is most commonly associated with AML-M3 (by FAB). AML-M3 is also referred to as **acute promyelocytic leukemia (by WHO classification)**. The classic clinical case is a younger patient (median age 40) with symptoms of leukemia (e.g., bruising, fever) who presents in disseminated intravascular coagulation (DIC).

#### ■ t(8;21)

- **Genes involved:** *CBF $\alpha$*  and *ETO*.
- This translocation is most commonly associated with AML-M2 (by FAB). AML-M2 is called AML with maturation. The translocation carries a good prognosis.

#### ■ inv16 or del 16q

- **Genes involved:** *CBF $\beta$*  and *MYH11*.
- **Morphology:** Increased eosinophils.
- This genetic mutation is associated with AML-M4 (by FAB). AML-M4 is called **acute myelomonocytic leukemia**.

### Morphology of AML

- Varies depending upon source of neoplastic cells (i.e., whether they are neutrophil, monocyte, megakaryocyte, or red blood cell in origin) and with the degree of differentiation.
- AML-M2 and AML-M3 (acute promyelocyte leukemia) are associated with **Auer rods**, one per cell in AML-M2 and many per cell in AML-M3 (Figure 12-12).

### Important points

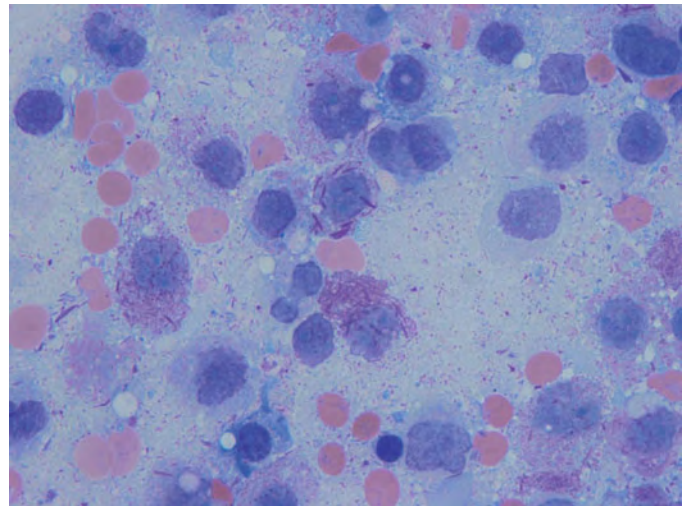
- The diagnosis of acute promyelocytic leukemia is a medical emergency, as the disease is associated with the development of DIC.
- Patients with monocytic leukemias (AML-M4 and M5) can present with swollen gums, due to blast infiltrates of the gingivae.
- AML-M7 (**acute megakaryocytic leukemia**) can have marrow fibrosis with organomegaly and pancytopenia and is associated with Down syndrome.

### Complications of AML

- Cell counts > 100,000 cells/ $\mu$ L lead to pulmonary infiltrates and acute respiratory difficulties.
- CNS bleeding due to injury to microvasculature.
- Metabolic acidosis and hyperuricemia are due to cellular turnover.

## CHRONIC MYELOID LEUKEMIA (CML)

**Basic description:** Neoplastic monoclonal proliferation of granulocytes. The granulocytes are more mature precursors of neutrophils (i.e., metamyelocytes, myelocytes, and bands). CML is responsible for 15–20% of all cases of leukemia.



**Figure 12-12.** Acute promyelocytic leukemia. This photomicrograph of a postmortem bone marrow aspirate from a patient with acute promyelocytic leukemia shows neoplastic cells with numerous Auer rods within the cytoplasm. Because this image is from a postmortem specimen, much of the other cellular detail is lost, and the cells themselves are no longer intact. Wright-Giemsa, 1000 $\times$ .



**Classification:** Although CML is a chronic myeloid leukemia, it also is included in the group of disorders referred to as chronic myeloproliferative disorders (see below).

**Epidemiology:** Older patients; median age is 52 years, although a juvenile form of CML exists.

**Associated cytogenetic abnormality:** Philadelphia chromosome t(9;22), translocation juxtaposes *abl* and *bcr*.

#### Complications of CML

- Progression of CML to AML (two thirds of patients) or to ALL (one third of patients), called **blast crisis**, has a *poor prognosis*.
- Splenomegaly.

**Microscopic morphology:** Increased white blood cell count, with a range of myeloid maturation from myelocytes to band and segmented neutrophils. The number of basophils is characteristically increased (Figure 12-13).

#### Clinical presentation of CML

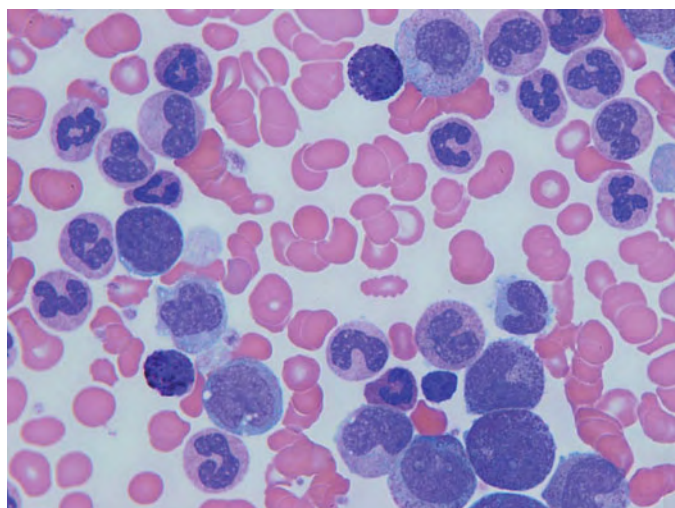
- **Symptoms:** Up to 40% of patients are asymptomatic, but patients can experience fatigue, lethargy, shortness of breath, weight loss, and early satiety. Early satiety is due to splenomegaly.
- **Signs:** Markedly elevated white blood cell count (median of 170,000 cells/ $\mu$ L), low leukocyte alkaline phosphatase (LAP) levels, high uric acid level, and high lactate dehydrogenase (LDH) level. Neoplastic cells have an increased amount of DNA and increased cellular turnover, which causes the high levels of uric acid and LDH. Also, the neoplastic cells do not function as normal white blood cells, which explains the decreased LAP.
- **Course of CML:** Patients are usually diagnosed in the chronic phase; this indolent phase lasts 3–5 years and can be asymptomatic. The chronic phase leads to an accelerated phase characterized by fever, weight loss, night sweats, worsening splenomegaly, and bone pain due to rapid cell turnover; and finally, patients progress to a blast crisis.
- **Treatment:** Imatinib mesylate (Gleevec), competitive inhibitor of bcr-abl.

## CHRONIC MYELOPROLIFERATIVE DISORDERS

**Overview:** Chronic myeloproliferative disorders involve the neoplastic proliferation of more mature forms of the myeloid cells (i.e., white blood cells, red blood cells, platelets, and megakaryocytes). There are four types of chronic myeloproliferative disorders: chronic myelogenous leukemia, essential thrombocytosis, polycythemia rubra vera, and myelofibrosis with myeloid metaplasia. CML was discussed above, and the remaining three conditions will be discussed below.

### ESSENTIAL THROMBOCYTOSIS

**Epidemiology:** Median age is 60–65 years; 10–25% of patients are younger than 40 years of age.



**Figure 12-13.** Chronic myelogenous leukemia (CML). This photomicrograph illustrates a patient with an increased white blood cell count. The white blood cells in the image represent a spectrum of myelogenous maturation, from myelocytes to band neutrophils. Also present are three basophils. These features are consistent with CML. Wright-Giemsa, 1000 $\times$ .

### Clinical presentation of essential thrombocytosis

- **Symptoms:** Headache, dizziness, visual changes, and **erythromelalgia** (burning pain and erythema of the feet and hands).
- **Signs:** Splenomegaly
- **Laboratory findings:** Platelet count  $> 600,000$  cells/ $\mu$ L with normal red cell mass (RCM), normal iron studies, and normal bone marrow examination.
- **Complications:** Strokes, transient ischemic attacks (TIAs), and myocardial infarcts can occur due to sludging of blood in the vessels because of the high cell count. Patients have about 3–4% risk of leukemic transformation.

## POLYCYTHEMIA RUBRA VERA

**Epidemiology:** Median age is 65 years.

### Clinical presentation of polycythemia rubra vera

- **Symptoms:** Headache; pruritus after bathing.
- **Signs:** Plethora (ruddy complexion), splenomegaly, hypertension.
- **Laboratory findings:** Low serum erythropoietin levels with increased red blood cell count.
- **Complications:** Thromboembolic disease. Patients have a 5–20% chance of progression to myelofibrosis and myeloid leukemia over a period of 20 years. Patients also can have strokes, TIAs, myocardial infarcts, **Budd-Chiari syndrome**, and retinal vein occlusion due to sludging of blood in the vessels because of the high red blood cell count.

## MYELOFIBROSIS WITH MYELOID METAPLASIA

**Basic description:** Fibrosis of the bone marrow not due to another source (such as metastatic carcinoma), with resultant production of bone marrow cells outside the bone marrow, usually in the spleen and liver (Figure 12-14 A and B). The condition may be due to dysplastic megakaryocytes that produce elevated levels of fibroblast growth factor.

**Epidemiology:** Elderly.

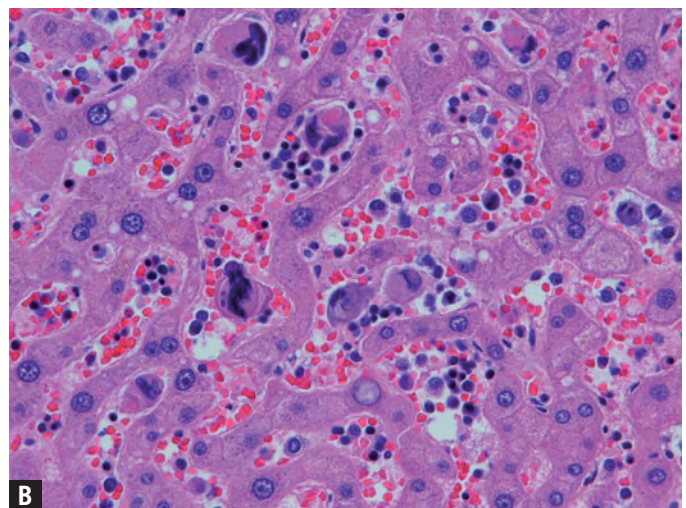
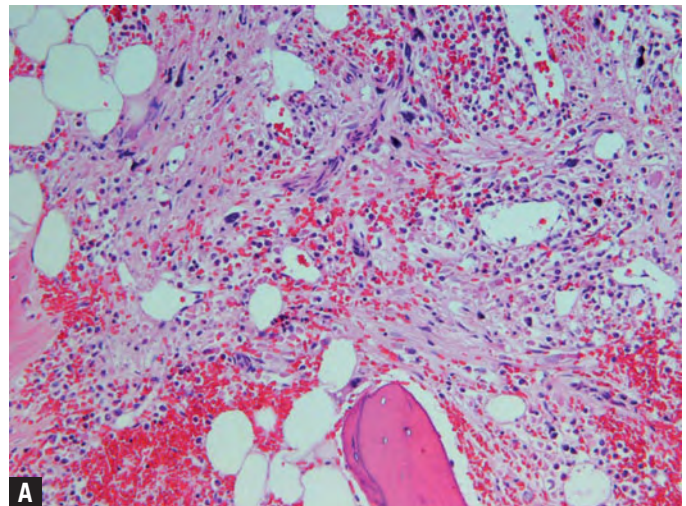
### Clinical presentation

- **Symptoms:** Fatigue and dyspnea; early satiety related to splenomegaly; fever, weight loss, and night sweats.
- **Signs:** Complications of neutropenia, anemia, and thrombocytopenia. Teardrop-shaped erythrocytes are characteristic but not specific.

## HODGKIN LYMPHOMA

### Overview (Table 12-8)

- **Epidemiology:** Male predominance, except nodular sclerositis Hodgkin lymphoma, which is more common in females. Hodgkin lymphoma has two peaks: one at about 20 years of age and another at about 50 years of age.
- **Clinical symptoms:** One third of patients with Hodgkin lymphoma have constitutional symptoms, including fever, night sweats, and weight loss (called “B” symptoms). Generalized



**Figure 12-14.** Idiopathic myelofibrosis with myeloid metaplasia. **A**, This photomicrograph shows fibrosis of the bone marrow, with a decreased number of myeloid precursors. **B**, This photomicrograph shows myeloid metaplasia within the liver. The sinusoids contain myeloid and erythroid cells of variable degrees of maturation. Also present are several megakaryocytes (large cells with multilobed nucleus). Hematoxylin and eosin, 400 $\times$ .

**TABLE 12-8.** Cell Markers and Genetic Abnormalities for Hodgkin and Non-Hodgkin Lymphomas

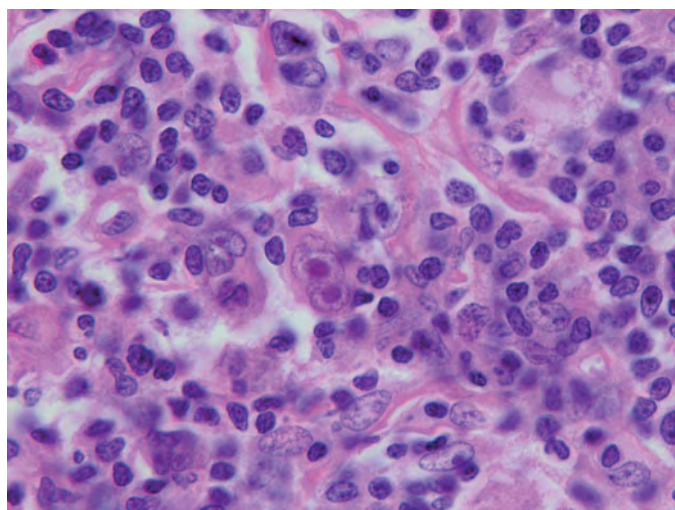
General Category of Lymphoma	Specific Name of Lymphoma	Cell Markers	Genetic Abnormality (if associated with one)
Hodgkin lymphoma	NS-HL	CD 15, 30+ EBV–	
	MC-HL	CD 15, 30+ EBV+	
	LP-HL	CD 20, EMA + CD 15, 30–	
Non-Hodgkin lymphoma	Follicular lymphoma	CD 19,20, and 10+ surface Ig, bcl-2+	t(14;18)– <i>bcl-2</i> 3q27 abnormalities
	Diffuse large B-cell lymphoma	CD 19,20, and 79a+ Surface Ig+	t(14;18)– <i>bcl-2</i> 3q27 abnormalities
	Burkitt lymphoma	CD 10, 19 and 20+ Bcl-6 and surface Ig+	t(8;14)– <i>MYC</i>
	Precursor T-cell lymphoblastic leukemia/lymphoma	Tdt, CD 2 and 7+	Abnormalities of <i>TAL1</i>
	Mantle cell lymphoma	CD 19,20 and 5+ Surface Ig+ CD23–	t(11;14)–cyclin D1
	MALToma	CD19, 20+	t(1;14)– <i>bcl-10</i> t(11;18)
	Hairy cell leukemia	CD 19, 20, 11c and 103+ TRAP+	

NS-HL, nodular sclerosis Hodgkin lymphoma; EBV, Epstein-Barr virus; EMA, epithelial membrane antigen; MC-HL, mixed cellularity Hodgkin lymphoma; LP-HL, lymphocyte predominant Hodgkin lymphoma; TRAP, tartrate-resistant acid phosphatase.

pruritus can occur with nodular sclerosis type. Painless cervical lymphadenopathy is the most common presenting symptom of Hodgkin lymphoma. Pain in the lymph nodes with ingestion of alcohol is classic and specific, but present in few patients.

- **Lymph node involvement:** Contiguous groups; therefore Hodgkin lymphoma may be surgically excised. Extranodal involvement is rare, and Hodgkin lymphoma most commonly involves mediastinal or neck lymph nodes.
- **Neoplastic cell: Reed-Sternberg cell** (Figure 12-15); the other cells in the lymph nodes (e.g., eosinophils, neutrophils) are reactive.
- **Prognostic factors:** Adverse prognostic factors include mixed cellularity or lymphocyte-depleted types, male gender, and advanced age (> 40 years). The presence of “B” symptoms and bulky disease with numerous nodal sites involved are also adverse prognostic factors.

**WHO Classification of Hodgkin lymphoma** (all of the following, except lymphocyte predominant, are considered classic types of Hodgkin lymphoma): Nodular sclerosis, mixed cellularity, lymphocyte-rich, lymphocyte-depleted, and lymphocyte-predominant types. The nodular sclerosis, mixed cellularity, and lymphocyte-predominant types are discussed below.



**Figure 12-15.** Hodgkin lymphoma with a Reed-Sternberg cell. In the center of the photomicrograph is a classic Reed-Sternberg cell, a binucleate cell with large “owl’s eyes” eosinophilic nucleoli. Hematoxylin and eosin, 400×.



### HODGKIN LYMPHOMA-NODULAR SCLEROSIS TYPE

**Microscopic morphology:** The parenchyma is divided by bands of sclerosis (i.e., fibrosis) into nodules (Figure 12-16); rare Reed-Sternberg cells are present. Hodgkin lymphoma-nodular sclerosis type has **lacunar cells**, which are characterized by clearing around the mononuclear Reed-Sternberg cell variants.

**Epidemiology:** Female predominance. Nodular sclerosis is the most common type of Hodgkin lymphoma (60–70% of cases).

**Markers of nodular sclerosis Hodgkin lymphoma:** Cells are positive for CD15 and CD30; Reed-Sternberg cells are negative for EBV.

### MIXED CELLULARITY HODGKIN LYMPHOMA

**Microscopic morphology:** Reed-Sternberg cells are more easily found in the tumor than in the nodular sclerosis type. The background cells are reactive and include eosinophils, neutrophils, and lymphocytes (Figure 12-17).

**Epidemiology:** Older patients (> 50 years). Mixed cellularity Hodgkin lymphoma represents 25% of cases of Hodgkin lymphoma.

**Markers of mixed cellularity Hodgkin lymphoma:** Cells are positive for CD15 and CD30; 70% of Reed-Sternberg cells are positive for EBV.

### LYMPHOCYTE PREDOMINANT HODGKIN LYMPHOMA

**Microscopic morphology:** Vaguely nodular; has Reed-Sternberg cell variants, which are referred to as L&H, or popcorn cells.

**Epidemiology:** Younger males (age 35).

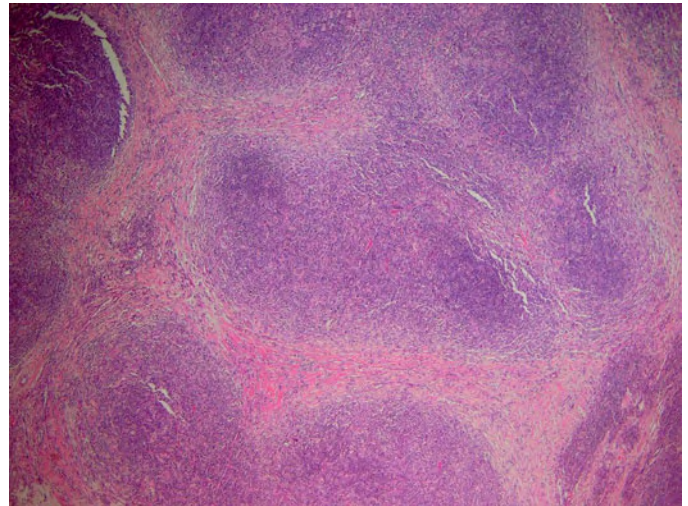
**Markers of lymphocyte predominant Hodgkin lymphoma:** Cells are negative for CD15 and CD30; cells are positive for CD20 and EMA.

#### Important points regarding lymphocyte predominant Hodgkin lymphoma

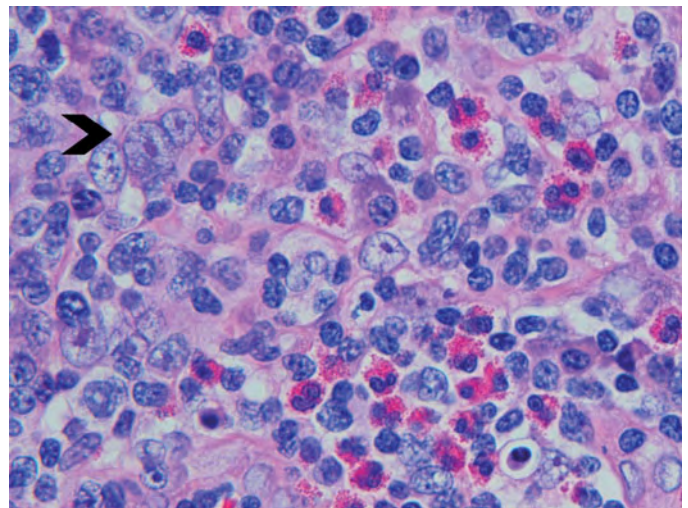
- Very benign and often cured with local excision.
- Often present with cervical or axillary lymphadenopathy.

#### Important points regarding Hodgkin lymphoma

- **Staging:** HL staging is based upon the number of lymph nodes involved (stage I is one lymph node) and the location of lymph nodes in relation to the diaphragm. Stage II is two or more lymph nodes on the same side of the diaphragm; stage III is two or more lymph nodes on opposite sides of the diaphragm; and stage IV represents disseminated disease.
- HL spreads node-to-node and is often localized at the time of presentation.



**Figure 12-16.** Hodgkin lymphoma, nodular sclerosis variant. Note the nodules of lymphocytes and other hematopoietic cells divided by broad fibrous septae. Hematoxylin and eosin, 40×.



**Figure 12-17.** Hodgkin lymphoma, mixed cellularity variant. Note the Reed-Sternberg cell (arrowhead). The other cell types in this image are reactive (only the Reed-Sternberg cell is neoplastic) and include neutrophils, lymphocytes, and, prominently in this image, eosinophils. Hematoxylin and eosin, 400×.

## NON-HODGKIN LYMPHOMA

### Overview (see Table 12-8)

- **Epidemiology:** Varies with types. Some are more common in childhood, and others are more common in adulthood.
- **Lymph node involvement:** Discontinuous groups, so non-Hodgkin lymphoma cannot be effectively surgically excised. Extranodal involvement is common and more so among aggressive subtypes of non-Hodgkin lymphoma. Non-Hodgkin lymphoma can involve the spleen (Figure 12-18).
- **Neoplastic cells:** Most non-Hodgkin lymphomas are derived from B cells, and others are from T cells.
- **Important points:** Non-Hodgkin lymphoma is often disseminated at the time of diagnosis; aggressive lymphomas have a propensity for involving the leptomeninges.
- **Clinical presentation of non-Hodgkin lymphoma**
  - Painless lymphadenopathy (most commonly, neck, inguinal, and axillary regions).
  - Approximately 20% of patients have constitutional symptoms (e.g., fever, weight loss, and/or night sweats) called “B” symptoms. These symptoms are more common in patients with aggressive lymphomas.

### TWO GENERAL TYPES OF NON-HODGKIN LYMPHOMA: INDOLENT AND AGGRESSIVE

**Overview:** Indolent (low-grade) lymphomas have a longer survival curve, but patients are never cured. Aggressive (high-grade) lymphomas have a rapid drop off of the survival curve, but the curve then flattens out because patients can be cured. Mantle cell lymphoma has the worst prognosis of both types: a more rapid drop off of the survival curve, with no patients being cured.

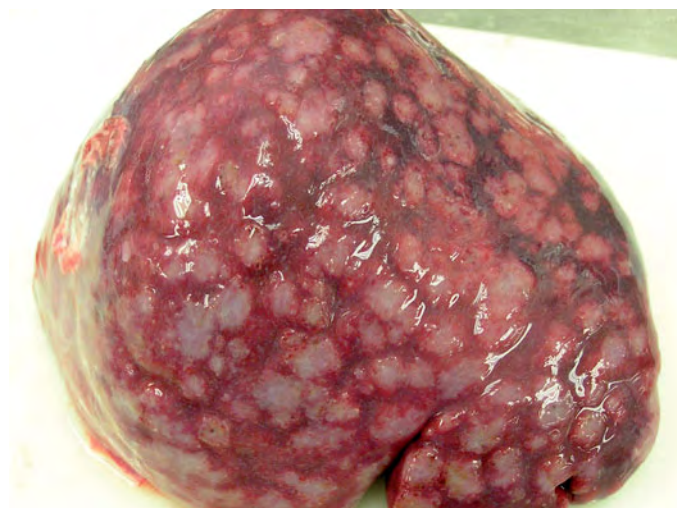
- Indolent lymphomas have a longer survival interval with no hope of cure, and include follicular lymphoma and small lymphocytic lymphoma.
- Aggressive lymphomas have a shorter survival interval; however, with correct treatment, a cure is possible with indefinite survival. Includes Burkitt lymphoma and diffuse large B-cell lymphoma.

### WHO classification of lymphoid neoplasms

- Precursor B-cell neoplasms.
- Peripheral B-cell neoplasms (CLL/SLL, lymphoplasmacytic lymphoma, mantle cell lymphoma, follicular lymphoma, hairy cell leukemia).
- Precursor T-cell neoplasms.
- Peripheral T-cell and NK-cell neoplasms (anaplastic large cell lymphoma).

### TYPES OF NON-HODGKIN LYMPHOMA

**Overview:** Although there are many types of non-Hodgkin lymphoma, only the more common types will be discussed below. These include follicular lymphoma, small lymphocytic lymphoma, diffuse large B-cell lymphoma, Burkitt lymphoma,



**Figure 12-18.** Spleen, non-Hodgkin lymphoma. This spleen exhibits uniform multicentric involvement of the white pulp by a malignant lymphoma. These changes contribute to generalized splenomegaly.



precursor T-cell lymphoblastic leukemia and lymphoma, mantle cell lymphoma, MALToma, hairy cell leukemia, and mycosis fungoides and Sézary syndrome.

### FOLLICULAR LYMPHOMA (FIGURE 12-19 A AND B)

**Epidemiology:** Older patients; male to female ratio is equal; 40% of cases of non-Hodgkin lymphoma are diagnosed as follicular lymphoma.

**Cytogenetic abnormality:**  $t(14;18)$ , which moves *bcl-2* gene adjacent to the Ig heavy-chain gene. Bcl-2 inhibits apoptosis; by moving its location adjacent to the Ig heavy-chain gene (a gene often transcribed), more bcl-2 is produced. Occasionally, follicular lymphomas have translocations involving *bcl-6* on 3q27.

**Markers of follicular lymphoma:** Neoplastic cells are positive for CD19, CD20, CD10, surface Ig, and bcl-2 (normal follicle center cells are negative for bcl-2).

**Prognosis:** Patients can survive 7–9 years, and most progress to develop diffuse large B-cell lymphoma or to Burkitt lymphoma.

**Microscopic morphology of follicular lymphoma:** Back-to-back follicles of the same size, composed of small cells or large cells. Bone marrow involvement (seen in 85% of cases) is usually peritrabecular.

#### Clinical presentation of follicular lymphoma

- Painless lymphadenopathy.
- Fever, night sweats, and fatigue.
- Most patients (80–90%) present with advanced stage III or stage IV disease.

### SMALL LYMPHOCYTIC LYMPHOMA (SLL)

**Microscopic morphology:** SLL has proliferation centers, which are clusters of mitotically active prolymphocytes.

**Important point:** SLL and CLL are essentially the same process; however, in SLL the involvement of the lymph nodes is the most prominent, and in CLL the involvement of the bone marrow and blood is the most prominent.

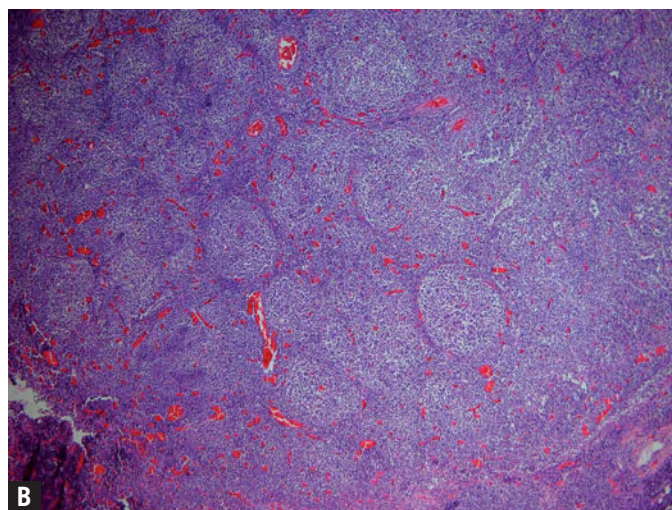
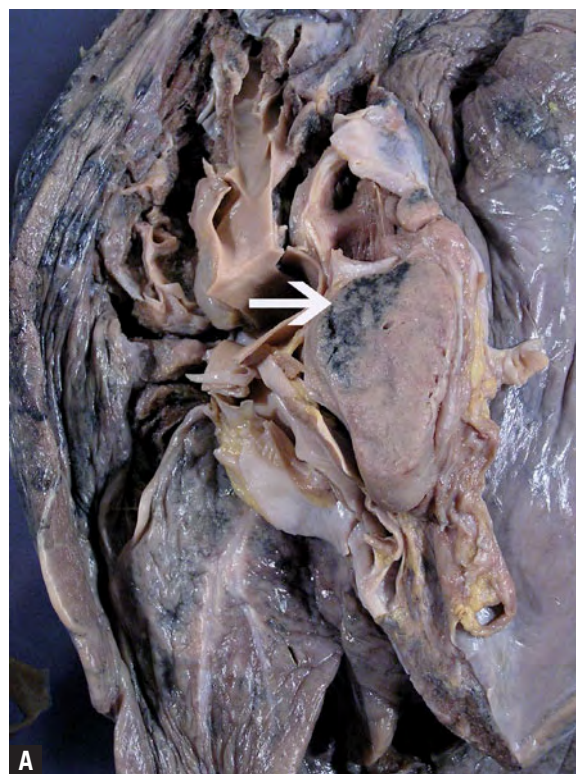
### DIFFUSE LARGE B-CELL LYMPHOMA (DLBCL)

**Epidemiology:** Most patients are older than 60 years of age; however, DLBCL represents 15% of childhood lymphomas. Overall, DLBCL represents 50% of cases of adult NHL. It occurs in males slightly more commonly than in females.

**Cytogenetic abnormality:** Approximately 10–20% of cases have  $t(14;18)$ , a translocation involving *bcl-2*; 30% of cases have a translocation involving 3q27 (*bcl-6*).

**Markers:** Neoplastic cells are positive for CD19, CD20, CD79a, and surface Ig.

**Microscopic morphology:** Monotonous sheets of large cells with prominent nucleoli (Figure 12-20).



**Figure 12-19.** Follicular lymphoma. **A**, Follicular lymphoma involves this hilar lymph node. The black material (arrow) represents normal lymphoid parenchyma with anthracotic pigment displaced to one side by the expanding tan lymphomatous process. **B**, This lymph node exhibits the characteristic low power features of follicular lymphoma, tightly packed lymphoid follicles of approximately equal size. Hematoxylin and eosin, 40 $\times$ .



**Important points regarding DLBCL**

- Some cases of DLBCL are associated with EBV (in HIV and immunosuppressed patients).
- Human herpesvirus 8 (HHV-8) is associated with a form of DLBCL called **primary effusion lymphoma**, which occurs in body cavities.

**BURKITT LYMPHOMA**

**Epidemiology:** Represents 30% of cases of childhood non-Hodgkin lymphoma.

**Forms of Burkitt lymphoma: Sporadic and endemic**

- **Sporadic type:** Occurs in the United States. Presents in the abdomen near the ileocecal valve, in the ovaries, or in the retroperitoneum; 15–20% of sporadic-type Burkitt lymphomas are associated with EBV infection.
- **Endemic type:** Occurs in Africa. Commonly presents in the jaw. All endemic-type Burkitt lymphomas are associated with EBV infection.

**Cytogenetic abnormality:** *MYC* (chr 8) translocated adjacent to the Ig heavy-chain gene on chromosome 14 (t(8;14) is the most common; or *MYC* is translocated adjacent to Ig light-chain gene ( $\kappa$  on chromosome 2 [t(2;8)] or  $\lambda$  on chromosome 22 [t(8;22)]).

**Markers of Burkitt lymphoma:** Neoplastic cells are positive for CD10, CD19, CD20, bcl-6, and surface Ig.

**Microscopic morphology:** Tumor is composed of diffuse sheets of cells. There is a “starry-sky” pattern produced by macrophages engulfing cellular debris (Figure 12-21).

**Important points regarding Burkitt lymphoma**

- Burkitt lymphoma has the highest turnover rate of any human malignancy, and carries an extremely high risk of tumor lysis syndrome.
- **Tumor lysis syndrome** is caused by chemotherapy, and is characterized by metabolic acidosis, hyperuricemia, hyperkalemia, and hyperphosphatemia. Acute renal failure is the most common complication. Treatment with allopurinol or rasburicase before chemotherapy is preventative.

**PRECURSOR T-CELL LYMPHOBLASTIC LEUKEMIA AND LYMPHOMA**

**Epidemiology:** Adolescent males aged 15–20 years.

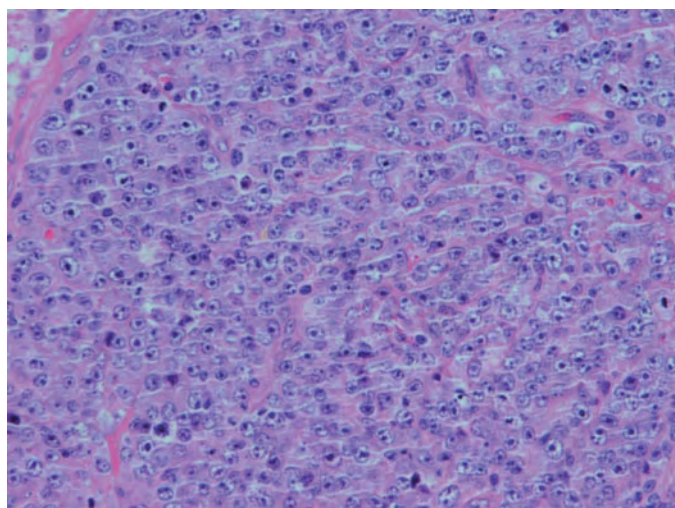
**Markers:** Cells are positive for TdT, CD2, and CD7.

**Cytogenetic abnormality:** Most common is translocation involving *TAL1*.

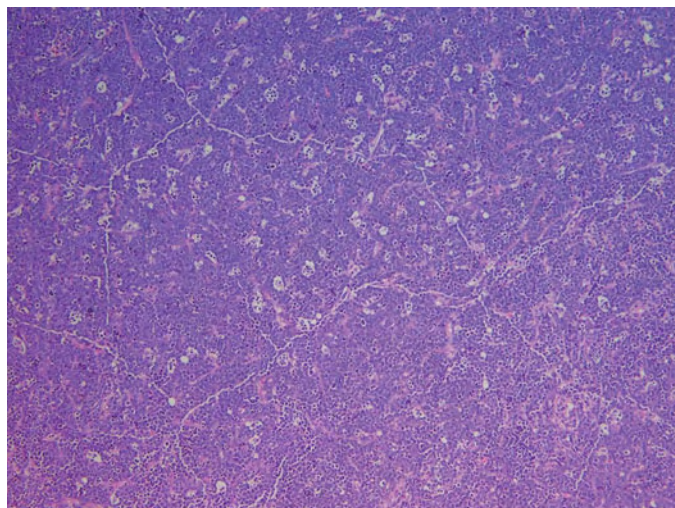
**Gross morphology:** Usually presents as a mediastinal mass.

**Microscopic morphology:** Lymphoblasts with irregular nuclear contours, small nucleoli, and scant cytoplasm.

**Important points:** Propensity for involving bone marrow and propensity to relapse and involve the leptomeninges.



**Figure 12-20.** Diffuse large B-cell lymphoma. The photomicrograph shows a sheet of monotonous large neoplastic cells with prominent nucleoli. Hematoxylin and eosin, 200 $\times$ .



**Figure 12-21.** Burkitt lymphoma. This photomicrograph illustrates the characteristic low power features of Burkitt lymphoma, a sheet of neoplastic cells interspersed with punctate clearings (“starry sky pattern”). The punctate clearings are macrophages engulfing cellular debris. Burkitt lymphoma is an aggressive rapidly growing neoplasm with abundant cellular turnover, hence the presence of the macrophages. Hematoxylin and eosin, 40 $\times$ .

### MANTLE CELL LYMPHOMA

**Epidemiology:** Older males.

**Cytogenetic abnormality:** t(11;14), in which cyclin *D1* on chromosome 11 is translocated adjacent to the Ig heavy-chain gene.

**Markers of mantle cell lymphoma:** Neoplastic cells are positive for CD19, CD20, CD5, and surface Ig, and are negative for CD 23.

**Microscopic morphology:** Vaguely nodular or diffuse pattern composed of small cells (some are deeply cleft); usually there are no large cells.

**Important points regarding mantle cell lymphoma**

- Survival is 3–5 years; *there is no cure*.
- Cells are CD5 positive, although it is a neoplasm of B cells, which indicates aberrant expression of CD5, similar to that seen in CLL.
- Can involve gastrointestinal tract producing polyps (i.e., **lymphomatoid polyposis**).

### MALTOMA (ALSO REFERRED TO AS MARGINAL ZONE LYMPHOMA)

**Basic description:** Lymphoma arising from mucosa-associated lymphoid tissue (MALT).

**Cytogenetic abnormalities:** t(1;14) involving *bcl-10*; t(11;18) involving *MAL1* and *IAP2*.

**Conditions associated with MALTomas:** *Helicobacter pylori* infection of the stomach, Hashimoto thyroiditis, and Sjögren syndrome.

**Important points:** MALTomas may regress if the inciting agent is removed; MALTomas remain localized for long periods of time.

### HAIRY CELL LEUKEMIA (FIGURE 12-22)

**Clinical triad:** Older male with pancytopenia and splenomegaly.

**Markers:** Neoplastic cells are positive for CD19, CD20, CD25, CD11c, and CD103.

**Additional clinical finding:** Positive for tartrate-resistant acid phosphatase (TRAP).

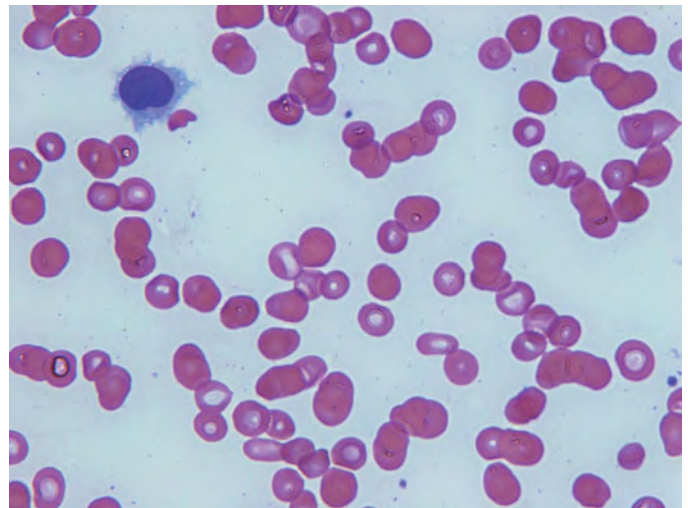
### ADULT T-CELL LEUKEMIA/LYMPHOMA

**Basic description:** Associated with infections with human T-cell leukemia virus-1 (HTLV-1).

### MYCOSIS FUNGOIDES AND SÉZARY SYNDROME

**Basic description:** Mycosis fungoides is a T-cell lymphoma with infiltration of the epidermis and dermis. It is a chronic condition. Sézary syndrome is a generalized exfoliative dermatitis with leukemic spread.

**Microscopic morphology:** Cerebriform nuclei (Sézary cells) and Pautrier microabscesses.



**Figure 12-22.** Hairy cell leukemia. In the upper left corner is a single neoplastic lymphoid cell. Note the fine hair-like projections from its surface. Wright-Giemsa, 1000 $\times$ .



## PLASMA CELL DYSCRASIAS

**Overview:** Plasma cell dyscrasias are a group of disorders characterized by a monoclonal proliferation of plasma cells. In many types, this proliferation of cells results in an overproduction of one clone of Ig, producing an **M spike** in the  $\gamma$  region on serum protein electrophoresis. The neoplastic plasma cells can secrete light and heavy chains along with complete immunoglobulin; sometimes they secrete only free light or heavy chains. Free light chains are called **Bence Jones proteins**. The types of plasma cell dyscrasias discussed in this section are multiple myeloma, monoclonal gammopathy of undetermined significance, plasmacytoma, lymphoplasmacytic lymphoma, and heavy chain disease.

### MULTIPLE MYELOMA

**Epidemiology:** 50–60 years of age. Multiple myeloma is the most common tumor arising within bone.

#### Complications of multiple myeloma

- The most common bones involved are the vertebrae, skull, and ribs.
  - Bone pain due to expansion of marrow.
  - Lytic lesions in bone due to the expansion of plasma cells, which can predispose to pathologic fractures. Production of IL-6 by neoplastic cells stimulates osteoclasts through the RANK ligand.
  - Hypercalcemia due to bone resorption.
- Decreased levels of functional immunoglobulin predispose patients to recurrent infections (e.g., *Staphylococcus aureus*, *Streptococcus pneumoniae*, and *Escherichia coli*).
- Overproduction of the light chains, which collect in the kidney as casts in the distal convoluted tubules and collecting tubules. The light chains can cause renal insufficiency.
- Amyloidosis due to overproduction of light chains.

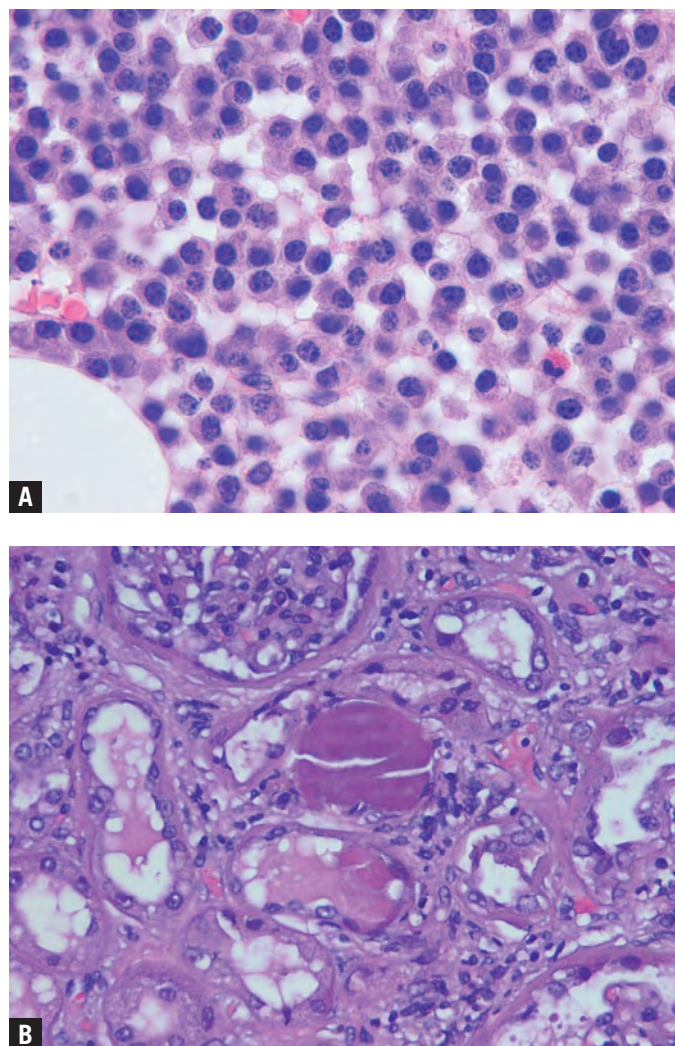
**Cytogenetic abnormalities:** t(4;14) in which fibroblast growth factor receptor gene is translocated adjacent to the Ig heavy-chain gene; also, 13q deletions.

#### Important points regarding multiple myeloma

- Almost 99% of multiple myelomas secrete Ig. There is no M spike in nonsecretory myelomas.
- Approximately 60% of multiple myelomas produce IgG; 20–25% produce IgA; and 15–20% produce light chains only ( $\kappa$  or  $\lambda$ ).
- The main cause of death is infection, and the second most common cause of death is renal failure.
- Approximately 20% of patients with multiple myeloma do not have a detectable M protein, but they do have free light chains in the urine.

#### Microscopic morphology of multiple myeloma (Figure 12-23 A and B)

- More than 30% of bone marrow cells are plasma cells.
- Accumulation of immunoglobins in plasma cells (**Russell bodies**).
- On peripheral blood smear, cells stack (i.e., rouleaux) like a roll of coins.



**Figure 12-23.** Multiple myeloma. **A**, The photomicrograph is of a bone-marrow aspirate from a patient with multiple myeloma. Note that almost all cells present are plasma cells (with “clock-face” chromatin). **B**, The photomicrograph illustrates the changes in the kidney that occur in multiple myeloma. In the center of the image is a tubule plugged with Bence Jones proteins (note the clefts). Hematoxylin and eosin, A and B, 400 $\times$ .



**Clinical presentation of multiple myeloma**

- **Symptoms:** Bone pain, infection.
- **Signs:** “Punched out” lesions of the skull seen on plain films are classic. Compression fractures of the vertebrae and pathologic fractures of the long bones are common, as is hypercalcemia. Patients have renal failure associated with enlarged kidneys.
- **Diagnosis:** Serum M protein > 3.5 g/dL for IgG-secreting neoplasms and > 2 g/dL for IgA-secreting neoplasms. Urine M protein > 1 g/24 h. Remember the M spike, Bence Jones proteinuria, and rouleaux formation; there is a large gap between total protein and albumin levels.

**MONOCLONAL GAMMOPATHY OF UNDETERMINED SIGNIFICANCE (MGUS)**

**Basic description:** Patients have an M spike with no other features of multiple myeloma (e.g., no osteolytic lesions).

**Complications:** 20% of patients develop multiple myeloma within 10–15 years.

**PLASMACYTOMA**

**Basic description:** Solitary mass composed of clonal proliferation of plasma cells. The mass can be osseous or extraosseous in location. Patients with an osseous plasmacytoma commonly progress to multiple myeloma.

**Complications:** Most patients progress to multiple myeloma within 5–10 years.

**LYMPHOPLASMACYTIC LYMPHOMA (LPL) AND WALDENSTRÖM MACROGLOBULINEMIA**

**Basic description:** LPL is a form of lymphoma composed of plasmacytoid (plasma cell-like) cells. Waldenström macroglobulinemia is a condition caused by overproduction of IgM, which causes sludging of cells in the vessels.

**Epidemiology:** Median age is 64 years.

**Complications**

- IgM M spike produces sludging in the vessels, which results in visual and neurologic disturbances (e.g., headaches).
- Bleeding.
- **Cryoglobulins** (i.e., precipitation of IgM in cold temperatures) cause Raynaud phenomenon.
- No lytic lesions in the bone.

**Cytogenetic abnormalities:** t(9;14) placing *PAX5* adjacent to Ig heavy-chain gene.

**Clinical presentation**

- **Signs:** Hepatosplenomegaly and lymphadenopathy; rarely, lytic lesions and/or hypercalcemia and retinal hemorrhages.
- **Symptoms:** Epistaxis, dizziness, and confusion due to hyperviscosity.

## HEAVY-CHAIN DISEASE

**Basic Description:** Only heavy chains of the IgG, IgM, or IgA type are produced.

## DISORDERS OF PRIMARY HEMOSTASIS

**Overview:** Disorders of primary hemostasis involve the platelets and can be due to (1) increased destruction of platelets, which can be immune-mediated or non-immune-mediated; (2) decreased production of platelets; or (3) platelet dysfunction. Patients with a platelet dysfunction, such as that caused by aspirin therapy, have normal levels of platelets but the platelets do not function normally. Bleeding due to platelet disorders is usually petechial, and the clinical presentation of platelet disorders includes epistaxis, menorrhagia, gingival bleeding, nonpalpable petechiae, and purpura. Coagulation studies show increased bleeding time.

## IMMUNE-MEDIATED DESTRUCTION OF PLATELETS

**Overview:** Causes of immune-mediated destruction of platelets include immune thrombocytopenic purpura (ITP) and heparin-induced thrombocytopenia, which are discussed below, followed by a brief listing of other immune-mediated causes of platelet destruction.

### IMMUNE THROMBOCYTOPENIC PURPURA (ITP)

**Basic description:** Antibody-mediated destruction of platelets. May be primary or secondary; secondary forms of the disease are due to systemic lupus erythematosus (SLE) or acquired immunodeficiency syndrome (AIDS). The former name for this condition was idiopathic thrombocytopenic purpura.

#### Types of immune thrombocytopenic purpura

- **Acute ITP**
- **Chronic ITP**, due to antibody versus IIb-IIIa or Ib-IX.

#### Clinical presentation

- Acute ITP occurs in children following a viral infection.
- Chronic ITP occurs in adults. Chronic ITP may be idiopathic, or it may be associated with lymphoma or collagen vascular disease.

#### Important points regarding immune thrombocytopenic purpura

- The acute form is self-limited.
- Patients have an increased number of megakaryocytes.

### HEPARIN-INDUCED THROMBOCYTOPENIA

**Basic description:** Acquired paradoxical hypercoagulable disorder associated with use of heparin.

**Mechanism:** Antibody (acquired or hereditary) versus platelet factor 4 and heparin complex. The antibody binding triggers platelet thrombosis.

**Complications:** Stroke, deep venous thrombosis, limb ischemia, and myocardial infarction.

**Important point:** Heparin causes a transient thrombocytopenia in 25% of all patients. This is a non-immune-mediated and usually self-limited adverse effect.

#### Other causes of immune-mediated thrombocytopenias

- **Iso-immune thrombocytopenia:** Development of antiplatelet antibodies due to previous blood or platelet transfusion.
- Collagen vascular disease.
- Drug induced.
- Infectious (HIV).

### NON-IMMUNE-MEDIATED DESTRUCTION OF PLATELETS

**Overview:** Causes of non-immune-mediated destruction of platelets include thrombotic thrombocytopenic purpura (TTP), hemolytic uremic syndrome (HUS), DIC, and giant hemangiomas. TTP, HUS, and DIC are discussed below.

#### THROMBOTIC THROMBOCYTOPENIC PURPURA (TTP)

**Clinical presentation of TTP:** The classic pentad of signs and symptoms is fever, thrombocytopenia, renal failure, neurologic changes, and microangiopathic hemolytic anemia.

**Mechanism:** Genetic, autoimmune, or acquired deficiency in ADAMTS-13, an enzyme that degrades very high-weight multimers of von Willebrand factor (vWF).

**Laboratory findings of TTP:** Microangiopathic hemolytic anemia (with schistocytes); normal PT and PTT.

**Microscopic morphology of TTP:** Microthrombi (platelets surrounded by fibrin) in capillaries. Schistocytes are seen on peripheral blood smears (Figure 12-24).

#### HEMOLYTIC UREMIC SYNDROME (HUS)

**Clinical presentation of HUS:** Similar to TTP, but renal dysfunction is more prominent and neurologic symptoms are less likely. HUS is most commonly associated with O157:H7 *E coli* infections in children, but it also occurs during the postpartum period.

**Laboratory findings:** See TTP.

**Microscopic morphology:** See TTP.

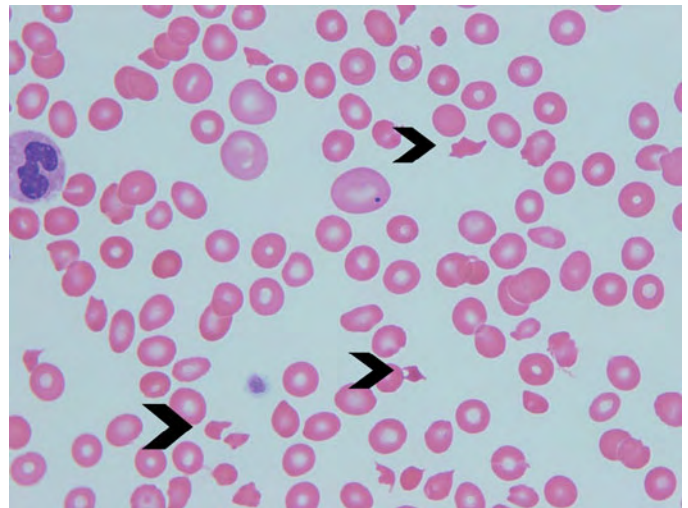
#### DISSEMINATED INTRAVASCULAR COAGULATION (DIC)

**Basic description:** A condition with widespread activation of both the coagulation system and the fibrinolytic system.

**Mechanism:** Release of tissue factor and widespread damage to endothelial cells.

#### Causes of DIC

- **Obstetric conditions:** Placental abruption, retained fetus, septic abortion, and amniotic fluid embolus.
- **Infectious:** Sepsis, meningococcemia, and Histoplasmosis.



**Figure 12-24.** Thrombotic thrombocytopenic purpura (TTP). Patients with TTP form platelet microthrombi in their vasculature. Red blood cells impacting these platelet thrombi can be damaged and, hence, the formation of schistocytes (arrowheads). Wright-Giemsa, 1000 $\times$ .



- **Neoplastic:** Carcinomas of the pancreas, prostate, and lung, and acute promyelocytic leukemia.
- **Other:** Massive trauma and thermal injury, acute pancreatitis, and liver disease.

#### Complications of DIC

- Widespread thrombi, which produce ischemia.
- Activation of fibrinolysis and depletion of coagulation factors and platelets leads to bleeding.

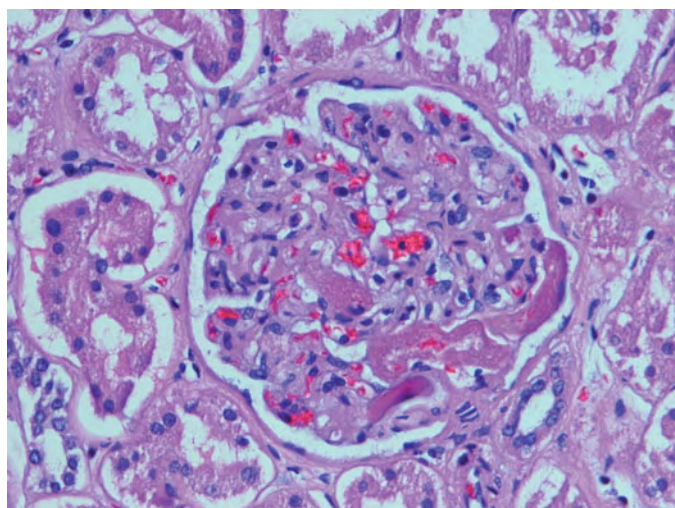
#### Laboratory findings of DIC

- Low number of platelets and elevated PT and PTT.
- Increased fibrin split products.
- Schistocytes on blood smear.

#### Forms of DIC

- **Acute DIC:** Form most often associated with obstetric and infectious etiologies and with bleeding complications.
- **Chronic DIC:** Form most often associated with neoplastic and hepatic disease and with thrombotic complications.

**Microscopic morphology of DIC:** Microthrombi in the kidney, heart, lung, and liver ([Figure 12-25](#)).



**Figure 12-25.** Kidney, with disseminated intravascular coagulation (DIC). In DIC, patients have widespread activation of both the clotting and fibrinolytic systems. One result is multiple microthrombi, which can lodge in small vessels. In this glomerulus, the capillaries of the glomerular tuft have several microthrombi (serpentine eosinophilic smudged structures from the 3-o'clock to the 6-o'clock position). Hematoxylin and eosin, 400 $\times$ .

## OTHER PLATELET DISORDERS

**Overview:** In addition to immune-mediated and non-immune-mediated destruction of platelets, the other categories of platelet disorders are decreased production of platelets and platelet dysfunction. Each of these categories will be discussed briefly below.

#### Causes of decreased production of platelets

- General conditions that cause depletion of all marrow elements (e.g., aplastic anemia, leukemia, lymphoma, and metastatic carcinoma).
- Conditions that selectively cause thrombocytopenia (e.g., alcohol use, thiazide diuretics, measles, and HIV).
- Ineffective megakaryopoiesis (e.g., in megaloblastic anemia).

## PLATELET DYSFUNCTION

**Overview:** The number of platelets is adequate, but the platelets themselves are not functioning correctly.

#### Causes

- Aspirin therapy, which impairs cyclooxygenase, which in turn impairs production of thromboxane, a factor that is necessary for primary hemostasis.
- Uremia.

## DISORDERS OF SECONDARY HEMOSTASIS

**Overview:** Disorders of secondary hemostasis most commonly are due to an inherited defect in the clotting cascade. Although there are many disorders of secondary hemostasis, three of the more common conditions, von Willebrand disease, hemophilia A and hemophilia B, will be discussed below.

### VON WILLEBRAND DISEASE

**Mechanism:** Due to deficiency (quantitative or qualitative) of vWF, which impairs platelet binding to exposed collagen. VWF serves two roles: to bind platelets to the collagen underlying a damaged vessel wall, and to act as a carrier for factor VIII.

**Inheritance pattern:** Some forms are autosomal dominant (such as type I), and others are autosomal recessive.

#### Clinical presentation of von Willebrand disease

- **Symptoms:** Bleeding in mucous membranes, epistaxis, increased bleeding after trauma, and menorrhagia.
- **Laboratory findings:** Elevated bleeding time and partial thromboplastin time (PTT); increased ristocetin factor assay.

### HEMOPHILIA A

**Mechanism:** Due to deficiency of factor VIII.

**Inheritance pattern:** X-linked recessive (30% of cases are new mutations).

#### Clinical presentation

- **Symptoms:** Hemorrhage after trauma or surgery and hemorrhage into joints and soft tissue. Complications include recurrent hemarthroses, which leads to joint destruction, and intracranial bleeding. Intracranial bleeding is the most common cause of death in hemophiliacs.
- **Laboratory findings:** Elevated PTT with normal PT, bleeding time, and fibrinogen levels.

### HEMOPHILIA B

**Basic description:** Similar characteristics as hemophilia A, but the mechanism is a deficiency of factor IX.



## CHAPTER 13

# PULMONARY PATHOLOGY

### OVERVIEW

Diseases of the lung can be classified into four general categories: (1) obstructive lung disease; (2) restrictive lung disease; (3) infectious disease; and (4) neoplastic disease ([Table 13-1](#)). The key clinical difference between obstructive and restrictive lung disease is the forced expiratory volume at one second ( $FEV_1$ ) and the forced vital capacity (FVC) ratio, which is decreased in obstructive lung disease and normal in restrictive lung disease. In obstructive lung disease, air is trapped within the parenchyma; in restrictive lung disease, airway filling is impaired due to fibrosis of alveolar septae. The four main types of obstructive lung disease are **emphysema**, **asthma**, **bronchiectasis**, and **chronic bronchitis**. Restrictive lung disease can be divided into acute and chronic forms, and chronic forms can be subdivided by etiology (i.e., work related, drug induced, autoimmune, and idiopathic).

The seven major forms of infectious lung disease (i.e., pneumonia) are (1) community-acquired typical (e.g., bacterial); (2) community-acquired atypical (e.g., viral, others); (3) nosocomial; (4) aspiration; (5) necrotizing pneumonia; (6) chronic pneumonia (e.g., fungal, mycobacterial); and (7) pneumonia in immunocompromised hosts. Neoplastic disease can be divided into **small cell lung carcinoma** and **non-small cell lung carcinoma**. The designation of non-small cell carcinoma versus small cell carcinoma is of utmost importance when determining treatment options. Small cell carcinoma is assumed at the time of diagnosis to have already metastasized.

This chapter will discuss acute respiratory failure, atelectasis, obstructive lung disease, restrictive lung disease, causes of chronic restrictive lung disease, diffuse pulmonary hemorrhage, pulmonary hypertension, pulmonary infections, pulmonary neoplasms, miscellaneous pleural conditions (including pleural effusions and mesothelioma), and upper respiratory tract conditions.

### ACUTE RESPIRATORY FAILURE

**Overview:** There are two types of acute respiratory failure: hypoxemic acute respiratory failure and hypercapnic acute respiratory failure.



### HYPOXEMIC ACUTE RESPIRATORY FAILURE

**Basic description:** Respiratory failure with  $pO_2$  of  $< 60$  mm Hg.

**Causes:** Pulmonary edema, **acute respiratory distress syndrome (ARDS)**, pneumonia.

### HYPERCAPNIC ACUTE RESPIRATORY FAILURE

**Basic description:** Respiratory failure with  $pCO_2$  of  $> 45$  mm Hg.

**Causes:** Obstructive lung disease (e.g., **chronic obstructive pulmonary disease [COPD]**, asthma), upper respiratory obstruction, decreased compliance of the chest wall (e.g., kyphoscoliosis), and hypoventilation.

## ATELECTASIS

**Overview:** Atelectasis is collapse of the pulmonary parenchyma. Because of atelectasis, airways and alveoli are unable to fill, and blood is shunted from the arteries to the veins without adequate oxygenation. The four common types of atelectasis discussed below are compressive, obstructive, microatelectasis, and contraction atelectasis.

### COMPRESSIVE ATELECTASIS (FIGURE 13-1)

**Mechanism:** A condition or lesion external to the lungs (i.e., in the pleural cavity) compresses the lung and impairs filling of the alveoli upon respiration.

**Causes of compressive atelectasis:** Blood in the pleural cavity (i.e., **hemothorax**), air in the pleural cavity (i.e., **pneumothorax**), and fluid in the pleural cavity (e.g., pulmonary edema).

**Mediastinal shift:** Away from the source of the atelectasis.

### OBSTRUCTIVE ATELECTASIS (RESORPTIVE ATELECTASIS)

**Mechanism:** An obstruction in the airway impairs filling of alveoli. All air in the alveoli is eventually resorbed and the alveoli collapse.

**Causes of obstructive atelectasis:** Aspirated foreign body, tumor, and mucus (e.g., in chronic bronchitis and cystic fibrosis).

**Mediastinal shift:** Toward the source of the atelectasis.

### MICROATELECTASIS

**Mechanism:** Loss of surfactant.

**Causes:** Prematurity, interstitial inflammation, postsurgical.

### CONTRACTION ATELECTASIS

**Mechanism:** Due to localized or generalized fibrosis impairing the ability of the alveoli to expand and contract.

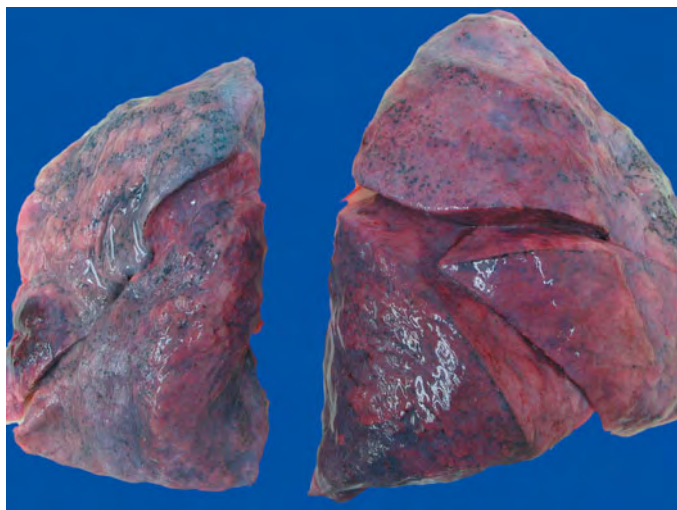**Cause:** Pulmonary fibrosis and scarring.

## OBSTRUCTIVE LUNG DISEASE

**Overview:** Obstructive lung disease is a disease of the lungs that impairs the ability of air to leave the alveoli during expiration,

**TABLE 13-1.** General Categories of Pulmonary Disease

Category	Subcategories or Specific Conditions
Obstructive lung disease	Emphysema Asthma Chronic bronchitis Bronchiectasis
Restrictive lung disease	Autoimmune Idiopathic Work related Drug related
Infectious lung disease	Community-acquired typical pneumonia Community-acquired atypical pneumonia Nosocomial pneumonia Aspiration pneumonia Necrotizing pneumonia Chronic pneumonia Pneumonia in immunocompromised
Neoplastic lung disease	Non–small cell lung carcinoma Small cell lung carcinoma



**Figure 13-1.** Atelectasis. This photograph shows atelectasis as the result of a left-sided hemothorax due to a gunshot wound. The blood in the left pleural cavity caused compressive atelectasis of the left lung. Note the smaller size of the left lung and its wrinkled pleural surface (due to collapse), compared to the smooth pleural surface of the right lung.

trapping it. It is clinically defined by the decreased  $FEV_1/FVC$  ratio. The residual volume and functional residual capacity (FRC) are increased, but the total lung capacity may remain normal. The condition eventually leads to hypercapnic respiratory failure, with  $pCO_2$  of  $> 45$  mm Hg. The four types of obstructive lung disease discussed below are emphysema, asthma, chronic bronchitis, and bronchiectasis.

## EMPHYSEMA

**Basic description:** Disease process that is characterized by the loss of pulmonary parenchyma (i.e., loss of alveolar septae and walls of airways) and dilation of terminal airways.

### Types of emphysema

- **Centriacinar emphysema**, which affects the respiratory bronchioles and involves the upper lobes. Centriacinar emphysema is associated with smoking.
- **Panacinar emphysema**, which affects the alveoli and alveolar ducts and eventually the respiratory bronchioles and involves the lower lobes. Panacinar emphysema is associated with  $\alpha_1$ -antitrypsin deficiency.

**Mechanism of emphysema:** The loss of pulmonary parenchyma causes a loss of elastic recoil. When the patient breathes out, the airways collapse, trapping air because of reduced driving pressure.

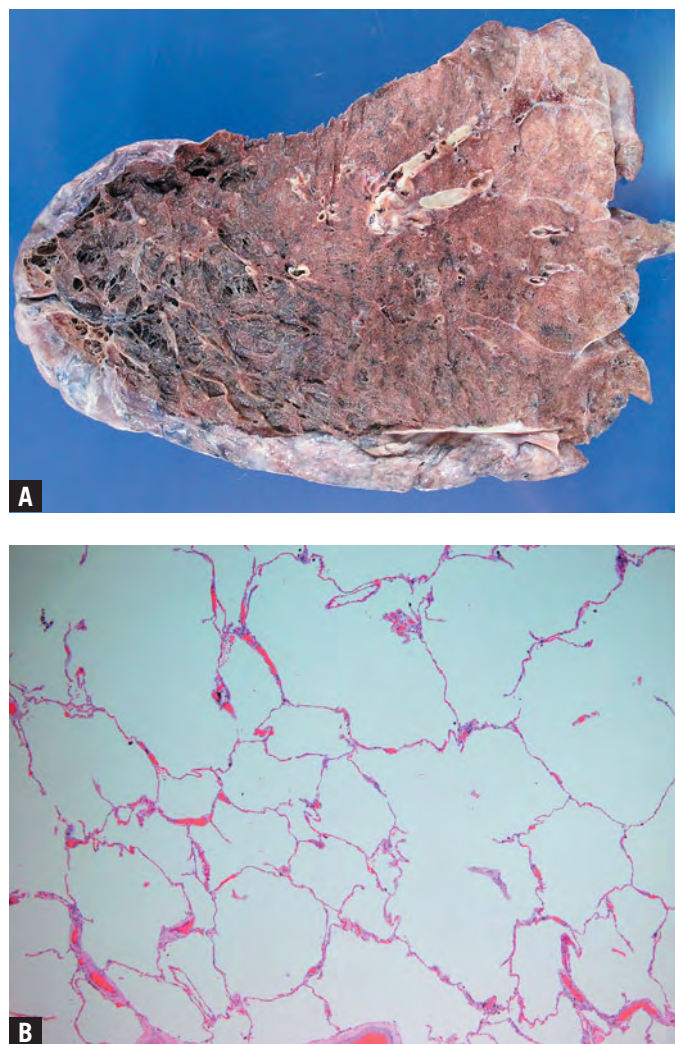
### Causes of emphysema

- Both centriacinar and panacinar emphysema are caused by an imbalance in protease-antiprotease and oxidant-antioxidant.
- Centriacinar emphysema is caused by cigarette smoking. The nicotine plays several roles.
  - Nicotine is a chemoattractant of neutrophils by induction of nuclear factor- $\kappa B$  and resultant production of tumor necrosis factor (TNF) and interleukin-8 (IL-8). TNF and IL-8 activate neutrophils, which release damaging proteases.
  - Nicotine causes inactivation of antiproteases.
  - Nicotine causes production of reactive oxygen species, which inactivate proteases and deplete antioxidants.
- Panacinar emphysema is caused by a deficiency in  $\alpha_1$ -antitrypsin. The normal allele encoding  $\alpha_1$ -antitrypsin is PiMM, but 0.012% of the population has a PiZZ allele, which is associated with a significant decrease in the amount of  $\alpha_1$ -antitrypsin.

### Complications of emphysema

- **Pulmonary hypertension** as a result of hypoxia-induced vasospasm and loss of vascular surface area (i.e., losing alveolar septae causes loss of alveolar capillaries).
- **Cor pulmonale** (right-sided heart failure secondary to pulmonary hypertension).
- **Mismatched ventilation-perfusion**, with shunting of blood to areas of poor ventilation.

**Morphology of emphysema:** Dilation of airspaces; bullae formation at the pleural surface (Figure 13-2 A–C).



**Figure 13-2.** Emphysema. **A**, The lung is lying on its posterior surface, and the upper lobe is at the left side of the image. Note the loss of parenchyma and greatly increased size of the airspaces (imparting a spiderweb-like appearance). **B**, The microscopic appearance of emphysema correlates with the gross appearance in **A**. Once again, note the loss of pulmonary parenchyma and greatly increased size of the airspaces. Hematoxylin and eosin, 40 $\times$ . (Continued).

### Clinical presentation of emphysema

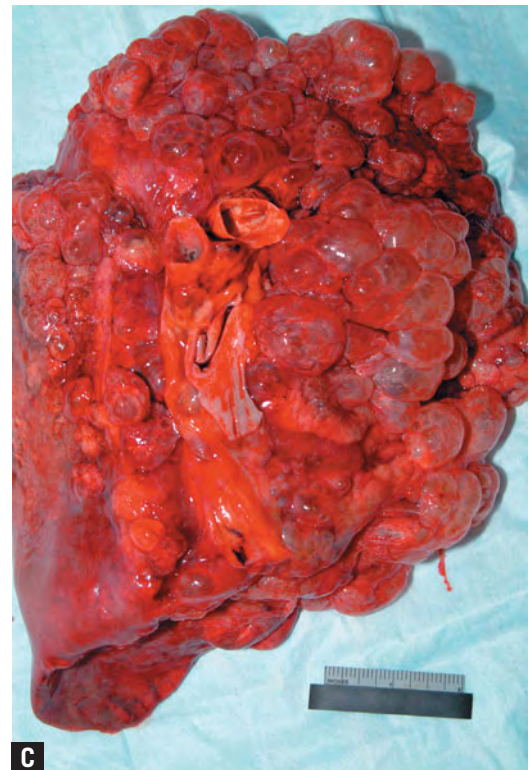- **Signs and symptoms:** Dyspnea, hypoxemia, hypercapnia, hyperventilation (patients are referred to as “pink puffers”). Decreased breath sounds and increased expiratory phase on auscultation. Chronic respiratory acidosis with compensatory alkalosis in stable patients. Weight loss (pulmonary cachexia) may be prominent in patients with emphysema, and digital clubbing may be observed.
- **Chest radiograph:** Flattened diaphragm and expanded hyperlucent lung fields.
- **Electrocardiogram:** Small amplitude QRS (due to increased airspace) and right axis deviation (usually associated with right ventricular hypertrophy). Tachycardia is common, and multifocal atrial tachycardia (MAT) is classic in patients with COPD.

## ASTHMA

**Basic description:** Disease process characterized by episodic reversible bronchoconstriction of hyperreactive airways in response to various exogenous and endogenous stimuli. Asthma is also associated with chronic inflammation.

### Types of asthma

- **Older classification:** Extrinsic and intrinsic.
- **Newer preferred classification**
  - Atopic: A type I hypersensitivity reaction with strong familial tendencies.
  - Nonatopic: Asthma associated with viral infection (e.g., rhinovirus, parainfluenza virus) in patients with no family history of allergies and who have normal levels of IgE.
  - Drug-induced asthma.
  - Occupational asthma.
  - Cardiac asthma.
- **Alternative classification:** Allergic asthma versus nonallergic asthma.
- **Allergic asthma**
  - **Epidemiology:** Occurs more frequently in children.
  - **Associated conditions:** Patients may have hay fever or eczema.
  - **Mechanism of allergic asthma:** Type I hypersensitivity reaction.
  - **Causes:** Pollens, dust, drugs.
- **Nonallergic asthma**
  - **Epidemiology:** Occurs more frequently in adults.
  - **Mechanism of nonallergic asthma:** Not type I hypersensitivity reaction; IgE levels are normal.
  - **Causes:** Exercise, cold air, drugs, gastroesophageal reflux, viral infections.



**Figure 13-2.** (Continued) **C**, A lung with marked bullae formation.



### Pathogenesis of asthma

- In general, asthma is characterized by hyperreactive airways that constrict in response to stimuli, causing increased airway resistance.
- In atopic and occupational asthma, the disease process is a type I hypersensitivity reaction involving CD4+ T<sub>H</sub>2 cells, which release IL-4 and IL-5. IL-4 and IL-5 stimulate eosinophils and production of IgE.
- In nonatopic and drug-induced asthma, the mechanism is less well understood, but it is *not* IgE mediated.

**Important point:** There are two stages of asthma, early and late.

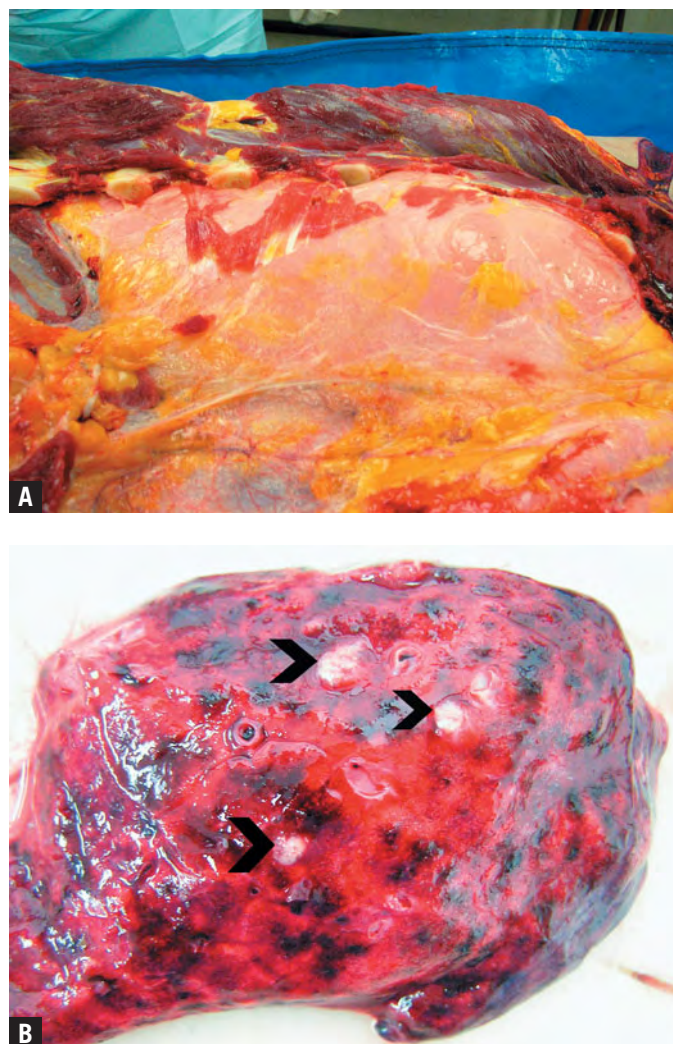
- **Early stage of asthma:** Due to the release of mediators from cells, which cause or promote bronchoconstriction (e.g., leukotrienes C<sub>4</sub>, D<sub>4</sub>, and E<sub>4</sub>; histamine, prostaglandin D<sub>2</sub> (PGD<sub>2</sub>)). Another mediator released is **mast cell tryptase**, which inactivates vasoactive intestinal peptide (VIP), a bronchodilator, causing edema and increased vascular permeability.
- **Late stage of asthma:** The late stage of asthma is due to release of enzymes by eosinophils and neutrophils. The arrival of eosinophils and neutrophils is induced by chemotactic factors released during the early stage of asthma. Neutrophils release proteases, and eosinophils release major basic protein, which are directly toxic to epithelial cells. The late phase is responsible for the morphologic changes that occur in asthma.

### Morphology of asthma (Figure 13-3 A–E)

- **Gross:** Hyperinflated lungs; mucous plugging of airways.
- **Microscopic:** Hypertrophy of smooth muscle, increased collagen under basement membrane, hyperplasia of mucous glands, and eosinophilic infiltrate; **Charcot-Leyden crystals** (composed of major basic protein); and **Curschmann spirals** (i.e., sloughed epithelial cells in mucous cast in the shape of airways).

### Clinical presentation of asthma

- **Symptoms:** Classic triad is persistent wheezing, chronic episodic dyspnea, and chronic nonproductive cough. Symptoms may be worse, or only present at night, due to the physiologic drop in cortisol secretion. Night-time cough, which may be the only symptom, is a classic symptom of asthma. Dark rings under the eyes (“allergic shiners”) and a dark transverse crease on the nose (“allergic salute”) are often seen, especially in children. **Status asthmaticus** is a prolonged asthmatic attack, which can be fatal.
- **Laboratory studies:** Low peak expiratory flow (PEF). FEV<sub>1</sub>/FVC is often decreased as in other obstructive lung diseases, and residual volume is increased. Carbon dioxide is usually low in an acute asthma exacerbation secondary to hyperventilation, and a rising carbon dioxide concentration in this setting often precedes respiratory failure. Eosinophilia may be present.



**Figure 13-3.** Asthma. **A**, A patient who died as a result of status asthmaticus. Patients with status asthmaticus can breathe in, but not out. The lungs become overinflated and press against the surrounding chest wall. Note the indentations in the lung produced by its expansion against the ribs. The lung is pink; most lungs, at autopsy, are red and congested from lividity. In this case, however, the pressure on the vasculature produced by the overdistended airspaces prevented blood from settling in the lungs. **B**, Mucous plugging of the airways (arrowheads), another characteristic gross feature of status asthmaticus. (Continued)

## CHRONIC BRONCHITIS

**Basic description:** Productive cough for at least 3 months in 2 consecutive years.

**Pathogenesis:** Related to cigarette smoking. Toxins in smoke irritate the airway, resulting in increased production of mucus, which, in turn, stimulates hyperplasia of mucous-secreting glands.

**Types of chronic bronchitis:** Simple, obstructive, and asthmatic.

### Complications of chronic bronchitis

- Obstruction of the airway by mucus, leading to bronchiectasis or atelectasis.
- Pulmonary hypertension.

### Morphology of chronic bronchitis

- **Gross:** Mucous plugging.
- **Microscopic:** Submucosal gland hypertrophy producing increased **Reid index**. The Reid index is the thickness of mucous glands in relation to thickness of the wall; in chronic bronchitis, it is  $> 0.40$ .

**Clinical presentation of chronic bronchitis** (see basic description of chronic bronchitis)

- **Signs and symptoms:** Chronic productive cough; hypercapnia (patients are referred to as “blue bloaters”).
- **Important point:** Can have asthmatic component (“asthmatic bronchitis”).

## BRONCHIECTASIS

**Basic description:** Abnormal, permanent dilation of airways.

**Pathogenesis:** Requires two components, infection and obstruction, each one of which can occur first and start the disease process. The infection results in destruction of the smooth muscle and elastic fibers in the wall of the airway.

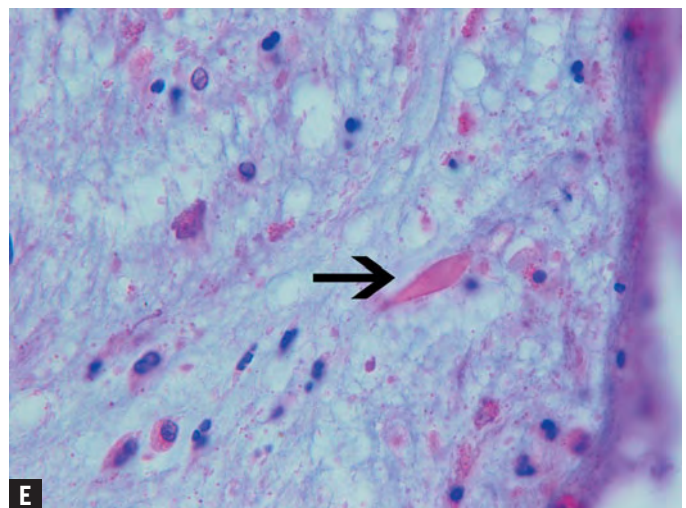
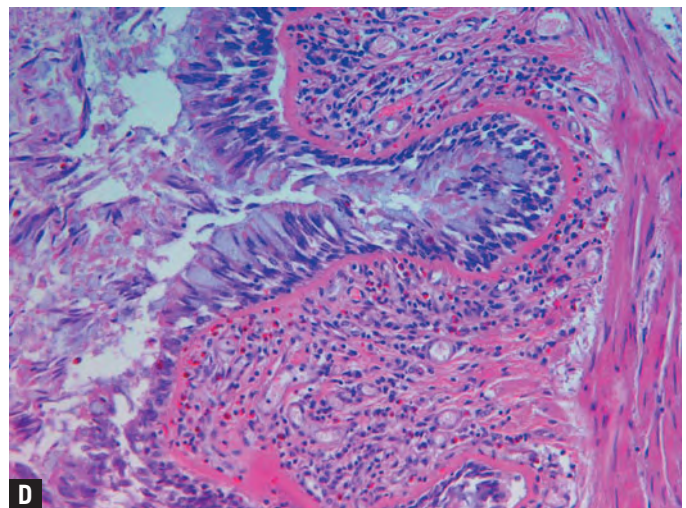
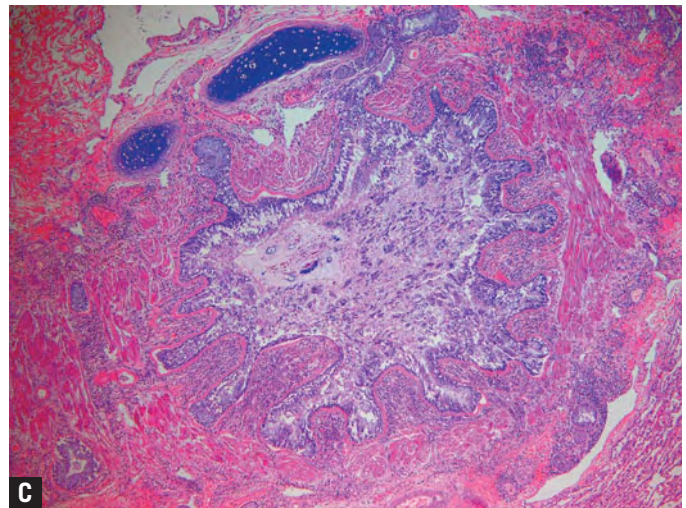
**Causes of bronchiectasis:** Allergic bronchopulmonary aspergillosis, cystic fibrosis, and **Kartagener syndrome** (see related condition below); necrotizing pulmonary infections leading to obstruction (e.g., *Staphylococcus*, *Klebsiella*); and other sources of obstruction including tumors, foreign bodies, and mucus in the airways (e.g., from asthma, chronic bronchitis, cystic fibrosis).

### Complications of bronchiectasis

- Hemoptysis, with potentially life-threatening hemorrhage.
- Rarely, pulmonary hypertension, abscess formation, and amyloidosis.

### Morphology of bronchiectasis

- **Gross:** Dilation of airways, usually involving lower lobes, right side more often than left, with airways almost extending to the pleural surface (Figure 13-4).
- **Microscopic:** Appearance depends upon stage, inflammatory infiltrate, and tissue destruction.



**Figure 13-3.** (Continued) **C**, Low-power histologic changes associated with asthma, mucous plug of the airway, prominent basement membrane, and smooth muscle hypertrophy. The smooth muscle hypertrophy is producing a vaguely polyp-like architecture to the airway lining, with projections into the lumen. **D**, The characteristic eosinophilic infiltrate associated with some forms of asthma. **E**, A Charcot-Leyden crystal (arrow), formed by major basic protein. Hematoxylin and eosin, C, 40 $\times$ ; D, 200 $\times$ ; E, 1000 $\times$ .



### Clinical presentation of bronchiectasis

- **Symptoms:** Dyspnea, chronic cough (dry, or with large amounts of purulent sputum production). Hemoptysis is common.
- **Signs:** Clubbing of the fingers (i.e., **pulmonary osteoarthritis**), hypoxemia, and hypercapnia.
- **Chest radiograph:** Parallel lines in peripheral lung fields, which represent nontapering thickened bronchial walls.

### Related condition: Primary ciliary dyskinesia

- **Genetic abnormality:** Hereditary condition associated with short dynein arms.
- **Subset of primary ciliary dyskinesia is Kartagener syndrome**, which includes bronchiectasis, sinusitis, situs inversus, and sterility.

## CHRONIC OBSTRUCTIVE PULMONARY DISEASE

**Overview:** Chronic bronchitis is a clinical diagnosis, and emphysema is an anatomic diagnosis. Patients with symptoms of obstructive lung disease (except asthma and bronchiectasis) are often assigned the clinical diagnosis of chronic obstructive pulmonary disease (COPD). The cause of death in patients with COPD is respiratory acidosis, cor pulmonale, or potentially a pneumothorax.

### Clinical presentation of COPD

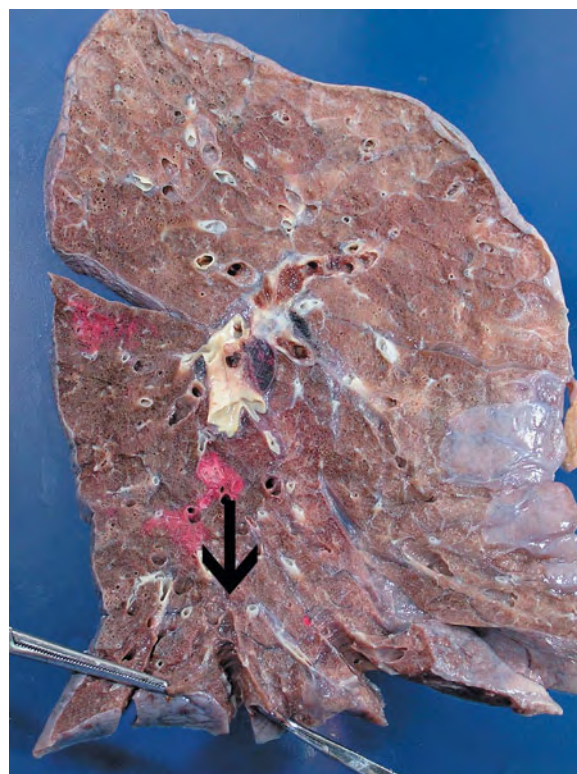
- **Symptoms:** Earliest is chronic productive cough, followed by dyspnea on exertion.
- **Signs:** Increased anteroposterior chest diameter (i.e., barrel chest) due to chronic lung overinflation. Patients use accessory muscles to breathe. Patients are often dependent on supplemental oxygen, and pulmonary function tests are consistent with a diagnosis of obstructive lung disease with decreased FEV<sub>1</sub>/FVC ratio.

## RESTRICTIVE LUNG DISEASE

**Overview:** There are two categories of restrictive lung disease, **extrapulmonary and intrapulmonary**. Extrapulmonary sources include obesity and kyphoscoliosis, and cause a restrictive lung disease by externally impairing filling of the lung. There are two subcategories of intrapulmonary restrictive lung disease, **acute and chronic**. Acute restrictive lung disease is primarily confined to the diagnosis of acute respiratory distress syndrome (ARDS). Chronic restrictive lung disease is a broad group, which includes many distinct entities. Chronic restrictive lung disease will be discussed following acute restrictive lung disease.

### ACUTE RESTRICTIVE LUNG DISEASE

**Basic description:** Disease developing over a short time period (minutes to days), usually secondary to a major systemic insult (e.g., sepsis, shock), which causes an acute restrictive lung disease, hypoxemic respiratory failure ( $pO_2$  is  $< 60$  mm Hg), and diffuse pulmonary infiltrates, and is not attributable to left-sided heart failure. The clinical term for acute restrictive lung disease is **acute respiratory distress syndrome (ARDS)**, and the pathologic term is **diffuse alveolar damage**.



**Figure 13-4.** Bronchiectasis. In the lower lobe of this lung, the bronchi can be traced to the pleural surface (arrow).



**Pathogenesis of diffuse alveolar damage:** Damage to the epithelium or endothelium causes the alveolar septae to become leaky (i.e., increased vascular permeability and loss of diffusion capacity), allowing protein to enter the alveoli. The epithelial cells undergo necrosis and slough into the alveoli. There are three stages of diffuse alveolar damage: exudative, proliferative, and fibrosis.

**Stages of diffuse alveolar damage** (in order of appearance)

- **Exudative stage:** The protein and necrotic cells layer out on the alveolar septae, forming **hyaline membranes**.
- **Proliferative stage:** Occurs in response to the damage. Type II pneumocytes undergo hyperplasia.
- **Fibrosis.**

**Causes of diffuse alveolar damage**

- **Four main causes:** Severe pulmonary infection, aspiration, sepsis, and severe trauma with shock.
- **Other causes:** Acute pancreatitis, cardiopulmonary bypass, fat emboli, viral infection (e.g., Hantavirus, severe acute respiratory syndrome [SARS]).
- **Acute interstitial pneumonitis** (see idiopathic pulmonary fibrosis below) is diffuse alveolar damage of undetermined etiology.

**Complications of diffuse alveolar damage:** High mortality rate. With survival, patients may develop fibrosis, causing development of a chronic restrictive lung disease, which can lead to pulmonary hypertension.

**Morphology of diffuse alveolar damage**

- **Gross:** Firm lungs.
- **Microscopic:** Hyaline membranes in the exudative stage (Figure 13-5); type II pneumocyte hyperplasia in the proliferative stage; and fibrosis.

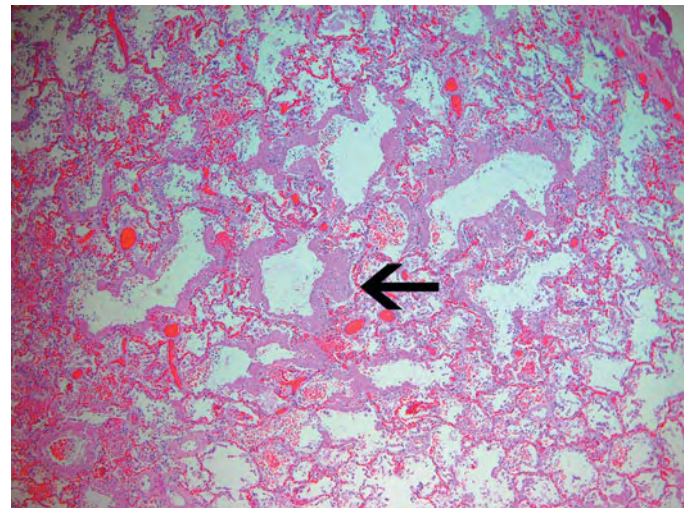
**Clinical presentation of diffuse alveolar damage**

- **Symptoms:** Severe dyspnea and pink frothy sputum within 72 hours of exposure to an inciting agent.
- **Signs:** Diffuse crackles, hypoxemia, and diffuse alveolar infiltrates seen on chest radiograph.

## CHRONIC RESTRICTIVE LUNG DISEASE

**Basic description:** Chronic restrictive lung disease, also referred to as interstitial lung disease, is characterized by chronic diffuse lung injury with inflammation and fibrosis, impaired gas exchange (low diffusing capacity of lung for carbon monoxide [DLCO]), decreased FEV<sub>1</sub> and FVC, and normal FEV<sub>1</sub>/FVC ratio.

**Causes of interstitial lung disease, by etiology:** There are four general categories of causes of interstitial lung disease, which are drug-related, occupational, autoimmune, and idiopathic (Table 13-2).



**Figure 13-5.** Diffuse alveolar damage. Diffuse alveolar damage (the histologic correlate of the clinical condition, acute respiratory distress syndrome) is characterized by the formation of hyaline membranes (arrow) on the alveolar septae. These hyaline membranes impair oxygen exchanged between the alveoli and alveolar capillaries, producing an acute restrictive lung disease. Hematoxylin and eosin, 40×.

**TABLE 13-2.** Causes of Chronic Restrictive Lung Disease

General Category	Specific Causes
Autoimmune	Systemic lupus erythematosus Wegener granulomatosis Rheumatoid arthritis
Idiopathic	Idiopathic pneumonias (e.g., UIP, DIP) Sarcoidosis
Work related	Asbestosis Silica-induced lung disease Coal-induced lung disease
Drug related	Bleomycin Busulfan Amiodarone Methotrexate

UIP, usual interstitial pneumonia; DIP, desquamative interstitial pneumonia.

- **Drug-related causes:** Bleomycin, busulfan, methotrexate, amiodarone, oxygen therapy.
- **Occupational causes:** Asbestosis, silicosis.
- **Autoimmune causes:** Systemic lupus erythematosus (SLE), Wegener granulomatosis, rheumatoid arthritis.
- **Idiopathic causes:** Idiopathic pneumonias, sarcoidosis.

**Pathogenesis of interstitial lung disease:** Exposure to the inciting agent eventually causes alveolitis that leads to the release of cellular mediators, causing injury and eventually fibrosis of the alveolar septae. The resultant appearance of the fibrotic lung parenchyma is referred to as **honeycomb lung** (Figure 13-6 A and B).

#### Clinical presentation of interstitial lung disease

- **Symptoms:** Insidious onset of dyspnea on exertion and dry nonproductive cough; tachypnea.
- **Signs:** Fine bibasilar end-inspiratory crackles; clubbing of fingers. Signs and symptoms of right-sided heart failure may be present.
- **Chest radiograph:** Reticular or reticulonodular pattern with diminished lung volumes.
- **Diagnosis:** Lung biopsy.

### CAUSES OF CHRONIC RESTRICTIVE LUNG DISEASE

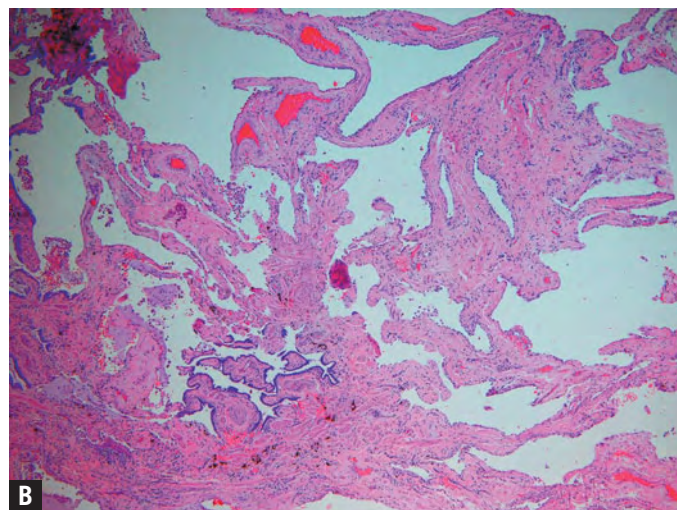
**Overview:** As described above, the causes of chronic restrictive lung disease (i.e., interstitial lung disease) can be divided into four categories: drug-related, occupational, autoimmune, and idiopathic. The term **pneumoconiosis** describes lung disease, including chronic restrictive lung disease arising due to exposure to inorganic or organic dust or to chemical fumes or vapors. Discussed below are asbestosis, other pneumoconioses, sarcoidosis, idiopathic pulmonary fibrosis, and hypersensitivity pneumonitis, which represent some of the more common forms of chronic restrictive lung disease (see Table 13-2).

#### ASBESTOSIS (FIGURE 13-7 A-C)

**Basic description:** Chronic restrictive lung disease occurring with evidence of exposure to asbestos.

#### Other features of asbestos exposure

- Pleural plaques or pleural effusions.
- Increased risk for development of bronchogenic carcinoma: If the patient has asbestosis and a bronchogenic carcinoma, the bronchogenic carcinoma may be considered to have been caused by the asbestos exposure and not by another source such as smoking. However, it is also important to understand that smoking and asbestos exposure are synergistic risk factors for bronchogenic carcinoma; that is, the risk for development of a bronchogenic lung carcinoma in a patient with exposure to both toxins is markedly increased over the simple additive risk of exposure to both toxins.



**Figure 13-6.** Chronic restrictive lung disease due to amiodarone exposure. **A**, Note the cobblestone appearance of the pleural surface (from fibrosis retracting the pleura). **B**, Note the prominent fibrosis of the alveolar septae. This fibrosis produces the honeycomb lung that is associated with chronic restrictive lung disease. In the lower left corner is type II pneumocyte hyperplasia, a reactive change. Hematoxylin and eosin, 40 $\times$ .



- **Mesothelioma:** Only seen due to exposure to amphibole fibers (see types of asbestos fibers below). Smoking does not increase the risk for development of mesothelioma in patients with asbestos exposure.
- **Ferruginous bodies:** Asbestos particles coated with iron by macrophages.

#### Types of asbestos fibers

- **Amphibole fibers:** Straight and less soluble; therefore, they penetrate deeper into the lungs and are more damaging.
- **Chrysotile fibers:** Curvy and more soluble; the curved nature does not allow them to penetrate as deeply into the lungs, and thus they are cleared by the mucociliary escalator.

### OTHER PNEUMOCONIOSES

**Basic description:** Lung disease (not including asthma, emphysema or chronic bronchitis) arising due to exposure to inorganic or organic dust or to chemical fumes or vapors. Although there are many pneumoconioses other than asbestosis, only coal, silica, and beryllium-induced lung disease will be discussed below.

#### Coal-induced lung disease: three forms of the disease

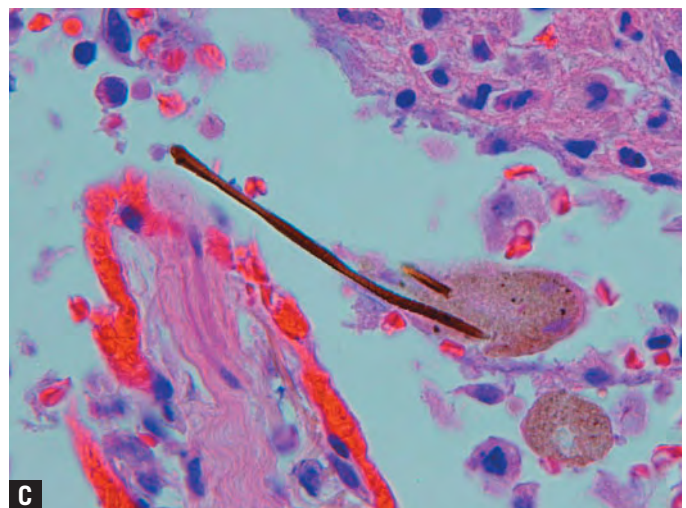
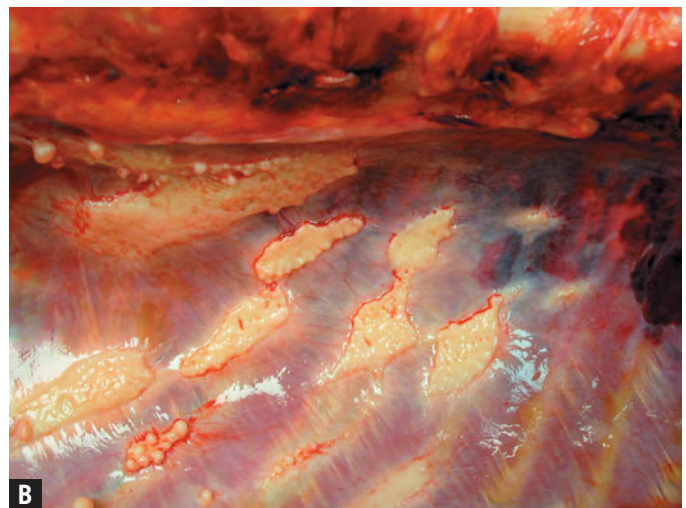
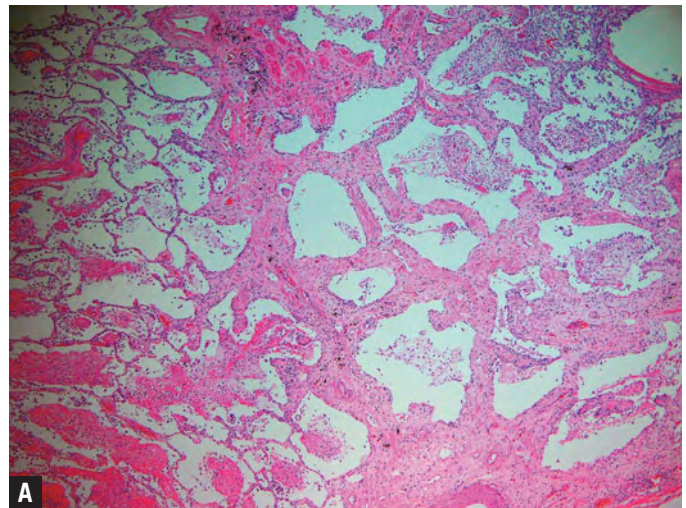
- **Anthracois:** Collections of anthracotic pigment-laden macrophages in the lymphatics.
- **Simple coal workers' pneumoconiosis:** Coalescence of pigment-laden macrophages into 1–2 mm macules and slightly larger nodules.
- **Complicated coal workers' pneumoconiosis** (also referred to as **progressive massive fibrosis**, a general term for the end stage of many work-related pneumoconioses): Development of large scars (2–10 cm or larger) in the pulmonary parenchyma.

#### Silica-induced lung disease

- **Forms: Acute and chronic silicosis.**
- **Morphology of silica-induced lung disease**
  - **Acute silicosis:** Appears similar to **pulmonary alveolar proteinosis** (i.e., alveoli are filled with eosinophilic, fine, proteinaceous-like material).
  - **Chronic silicosis:** Nodular fibrosis (Figure 13-8), progressing to progressive massive fibrosis.
- **Important points**
  - Classic radiologic appearance of chronic silicosis: Involvement of upper lobe with nodules and “eggshell-like” calcification of hilar nodes.
  - Silicosis predisposes to infection with mycobacteria (**silicoc tuberculosis**).

#### Beryllium-induced lung disease

- **Acute berylliosis:** Intense inflammatory reaction resembles a chemical pneumonia.
- **Chronic berylliosis:** Granulomas in the alveolar septae.



**Figure 13-7.** Asbestos exposure. **A**, Asbestosis, a chronic restrictive lung disease, is due to asbestos exposure. Note the thick and fibrotic alveolar septae. **B**, Multiple flat yellow-tan plaques line the parietal pleura. Pleural plaques are seen in patients with asbestos exposure, but are not specific to the condition. **C**, A ferruginous body. Macrophages engulf the asbestos fibers but cannot degrade them and, therefore, coat them with iron. Hematoxylin and eosin, A, 40 $\times$ ; C, 1000 $\times$ .



## SARCOIDOSIS

**Basic description:** Multisystem disease of uncertain (possibly autoimmune) etiology that produces noncaseating granulomas.

### Organ involvement

- Lungs: 90% of cases; can lead to diffuse interstitial fibrosis and pulmonary hypertension.
- Lymph nodes: 75–90% of cases.
- Eye: 20% of cases; uveitis, iritis, and iridocyclitis, leading to glaucoma, cataracts, and possible visual loss.
- Heart: 30% of cases; leading to arrhythmias.
- Skin: 25% of cases; **erythema nodosum** (i.e., raised tender red nodules on the anterior surface of the legs).
- Spleen, liver, and bone marrow.

**Epidemiology:** Younger than 40 years of age; African Americans have a 10 to 15 times higher incidence of being diagnosed with the disease than do whites; increased incidence in nonsmokers.

**Microscopic morphology of sarcoidosis:** Noncaseating granulomas, **asteroid bodies** (eosinophilic, star-shaped inclusions), and **Schaumann bodies** (concentrically calcified bodies). Sarcoidosis can lead to alveolar septal fibrosis (Figure 13-9 A–C).

**Clinical presentation:** There are three manners by which sarcoidosis can present clinically.

- **Asymptomatic patients** with abnormal chest radiograph (hilar lymphadenopathy).
- Patients with **pulmonary symptoms** (e.g., nonproductive cough and dyspnea).
- Patients with **extrapulmonary manifestations** (e.g., uveitis, lupus pernio, erythema nodosum).

### Important points

- Sarcoidosis is a diagnosis of exclusion; thus all other causes of the granulomas should be excluded.
- The mononuclear cells can produce the active form of vitamin D, causing hypercalcemia.
- **Laboratory studies:** Patients may have an elevated level of angiotensin-converting enzyme (ACE).
- Circulating CD4<sup>+</sup> lymphocytes are decreased.
- Sarcoidosis is associated with pure thymic hyperplasia.

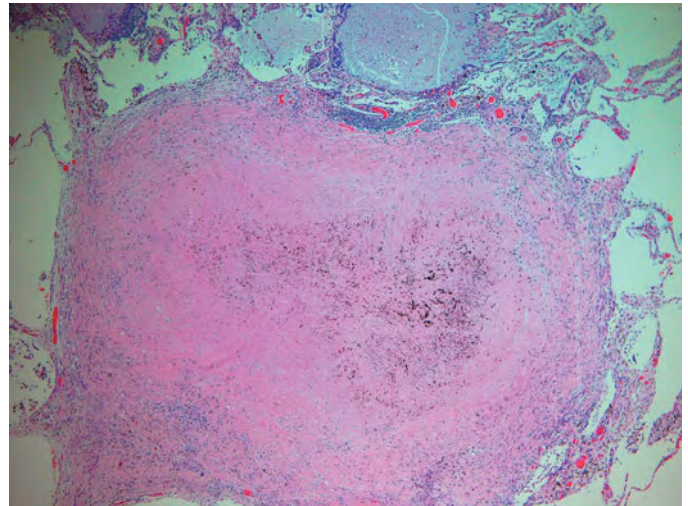
## IDIOPATHIC PULMONARY FIBROSIS

**Basic description:** Chronic restrictive lung disease occurring with no identifiable etiology, such as exposure to asbestos or drugs (e.g., amiodarone).

**Pathogenesis of idiopathic pulmonary fibrosis:** Idiopathic pulmonary fibrosis is usually an end stage of a form of idiopathic pneumonia, most commonly the end stage of **usual interstitial pneumonia**. The likely pathogenesis for the idiopathic pneumonias is repeated cycles of alveolitis by an unknown agent.

### Five types of idiopathic pneumonia

- Usual interstitial pneumonia (UIP)
- Desquamative interstitial pneumonia (DIP)



**Figure 13-8.** Silicotic nodule. The acellular fibrotic nodule in this image is due to exposure to silica. Large nodules can merge, leading to progressive massive fibrosis. Hematoxylin and eosin, 40×.

- Respiratory bronchiolitis with interstitial lung disease (RB-ILD)
- Acute interstitial pneumonia (AIP)
- Nonspecific interstitial pneumonia

#### Microscopic morphology of usual interstitial pneumonia:

Temporally heterogeneous, with areas of fibrosis intermixed with areas of increased cellularity. The areas of increased cellularity are referred to as **fibroblastic foci** and likely represent exuberant wound healing.

**Important points regarding idiopathic pneumonia:** DIP is associated with cigarette smoking and responds to steroid therapy; AIP is rapidly fatal and rarely responds to treatment.

### HYPERSENSITIVITY PNEUMONITIS

**Basic description:** Disease occurring as a result of hypersensitivity to certain allergens. Unlike asthma, which affects the larger airways, hypersensitivity pneumonitis affects the alveolar septae. The various forms of hypersensitivity pneumonitis are named for the occupational or recreational activity associated with the exposure to the allergen.

#### Causes of hypersensitivity pneumonitis

- Pigeon serum—pigeon breeder's lung.
- Thermophilic actinomycetes—humidifier (air-conditioner) lung.
- *Micropolyspora faeni* (found in moldy hay)—farmer's lung.

#### General forms of hypersensitivity pneumonitis: acute, subacute, and chronic disease

- **Acute:** Intense exposure to an antigen, followed by symptoms of cough and dyspnea within 4–6 hours; symptoms last 18–24 hours.
- **Subacute:** More insidious onset.
- **Chronic:** Disease results in progressive fibrosis and restrictive lung disease.

#### Microscopic morphology of hypersensitivity pneumonitis:

Alveolar septae expanded by mononuclear infiltrate, in some cases with granulomas.

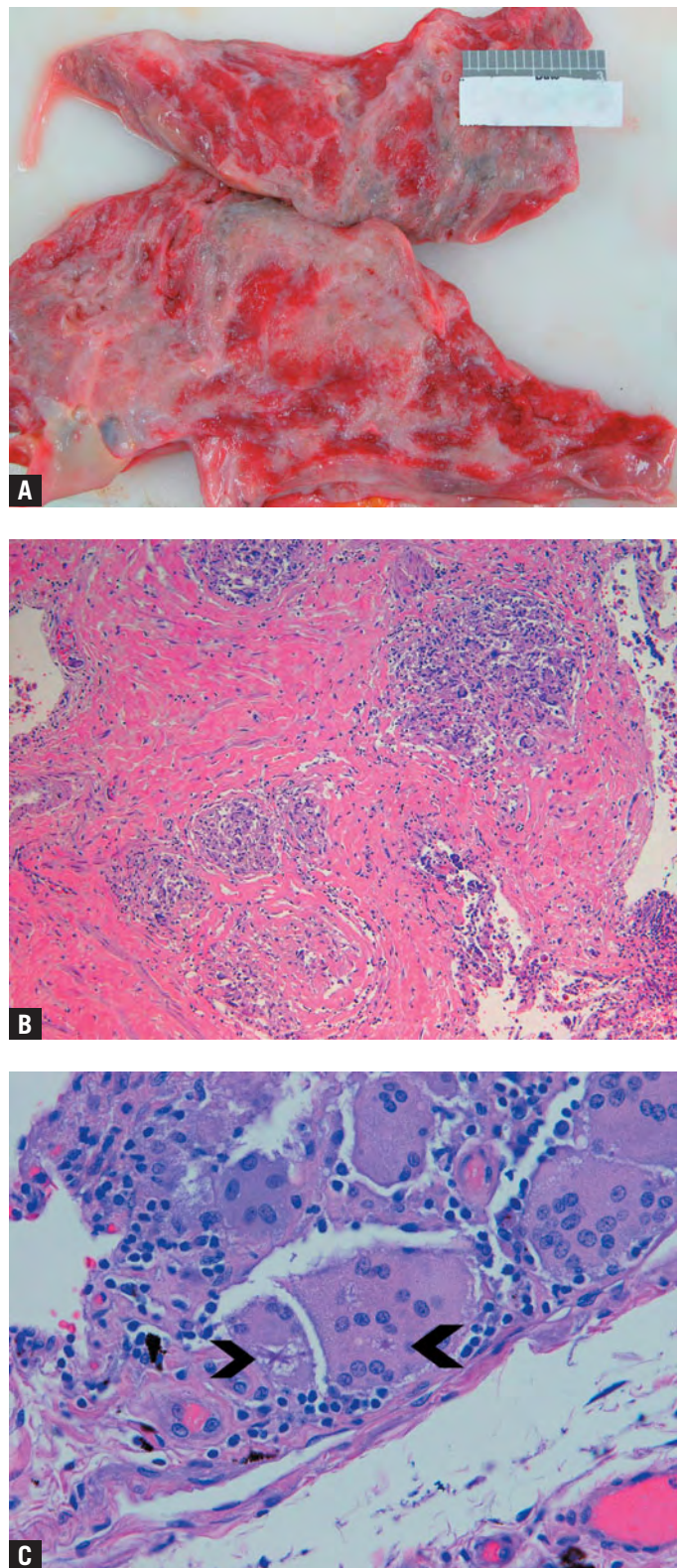
#### Clinical presentation of hypersensitivity pneumonitis

- **Symptoms:** Cough, dyspnea.
- **Signs:** Diffuse crackles.

**Important point:** Consider the diagnosis of hypersensitivity pneumonitis in any patient with restrictive lung disease, especially patients whose symptoms worsen after environmental exposure, such as at work.

### DIFFUSE PULMONARY HEMORRHAGE

**Overview:** Diffuse pulmonary hemorrhage is hemorrhage throughout the lung that may be secondary to many causes (e.g., coagulopathies, vasculitis, infections), or it may represent a primary disorder. Two specific causes of primary diffuse pulmonary hemorrhage are Goodpasture syndrome and idiopathic pulmonary hemosiderosis, which are discussed below.



**Figure 13-9.** Sarcoidosis. **A**, Cross-sections of lung from a patient with advanced sarcoidosis; note the prominent fibrosis of the pulmonary parenchyma. **B**, Fibrosis of the pulmonary parenchyma, with a few residual noncaseating granulomas with giant cells. **C**, A noncaseating granuloma, with multinucleated giant cells. Within the giant cells are asteroid bodies (arrowheads). Asteroid bodies are associated with sarcoidosis, but may be seen in other conditions as well. Hematoxylin and eosin, A, 200 $\times$ ; B, 400 $\times$ .



## GOODPASTURE SYNDROME

**Pathogenesis:** Type II hypersensitivity reaction with antibody versus alveolar and glomerular basement membranes; specifically, the  $\alpha$ -3 chain of type IV collagen.

**Epidemiology:** Male predominance.

**Clinical presentation of Goodpasture syndrome:** Hemoptysis; later, crescentic glomerulonephritis and renal failure, progressing to uremia and death.

**Idiopathic pulmonary hemosiderosis**

- No known cause.
- More common in children than in adults.

**Microscopic morphology of the lung in Goodpasture syndrome and idiopathic pulmonary hemosiderosis**

- Alveolar hemorrhage.
- Hemosiderin-laden macrophages; fibrosis and type II pneumocyte hyperplasia.

## PULMONARY HYPERTENSION

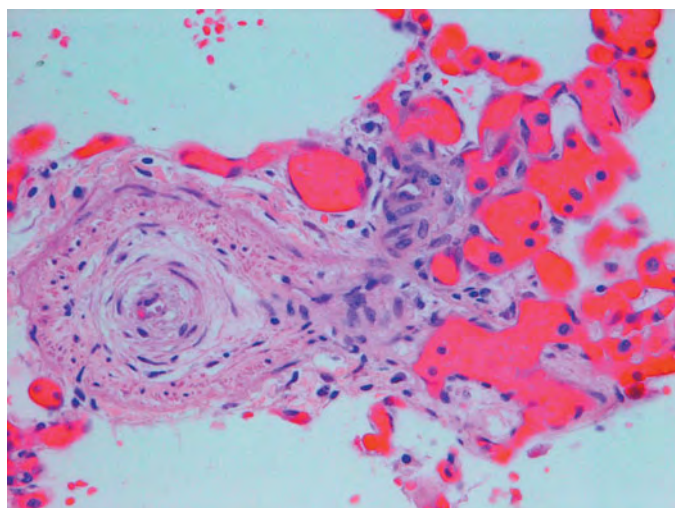
**Overview:** Pulmonary hypertension is an increase in blood pressure within the pulmonary circulation ( $> 20$  mm Hg), which can be primary, but is most often secondary to another condition.

**Secondary causes of pulmonary hypertension:** The conditions that increase the work done by the right side of the heart and cause secondary pulmonary hypertension fall into four general categories: cardiac, inflammatory, pulmonary, and vascular.

- **Cardiac causes:** Left-to-right shunts, mitral stenosis.
- **Inflammatory causes:** Connective tissue diseases.
- **Pulmonary causes:** COPD, chronic restrictive lung disease.
- **Vascular causes:** Recurrent thromboemboli.

**Primary pulmonary hypertension**

- **Basic description:** Pulmonary hypertension *not* in association with an underlying cause.
- **Epidemiology:** Age 20–40 years; female predominance.
- **Pathogenesis of primary pulmonary hypertension:** Possibly chronic vasoconstriction from vascular hyperreactivity; may be due to a mutation in the bone morphogenetic protein receptor 2 (*BMPR2*) gene, whose protein product causes inhibition of proliferation of vascular smooth muscle and favors apoptosis of the vascular smooth muscle.
- **Microscopic morphology of pulmonary hypertension**
  - Medial hypertrophy (grade 1).
  - Intimal hypertrophy (grade 2).
  - **Pipestem fibrosis**, with near obliteration of lumen of vessel (grade 3).
  - **Plexiform pulmonary arteriopathy** (grade 4) (Figure 13-10).



**Figure 13-10.** Pulmonary hypertension, angiomatoid lesion. The vessel to the left side of the image has prominent medial and intimal hypertrophy, resulting in almost complete obliteration of the lumen. To the right side of the vessel is a capillary proliferation. An angiomatoid lesion indicates high-grade pulmonary hypertension. Hematoxylin and eosin, 400 $\times$ .



## PULMONARY INFECTIONS

**Overview:** There are seven general categories of pulmonary infections; however, they are not completely separate entities, and one type can predispose to the development of another or they can coexist. The seven categories of pulmonary infections are community-acquired typical pneumonia, community-acquired atypical pneumonia, nosocomial pneumonia, aspiration pneumonia, necrotizing pneumonia, chronic pneumonia, and pneumonia in the immunocompromised patient, all of which are discussed below.

### COMMUNITY-ACQUIRED TYPICAL PNEUMONIA

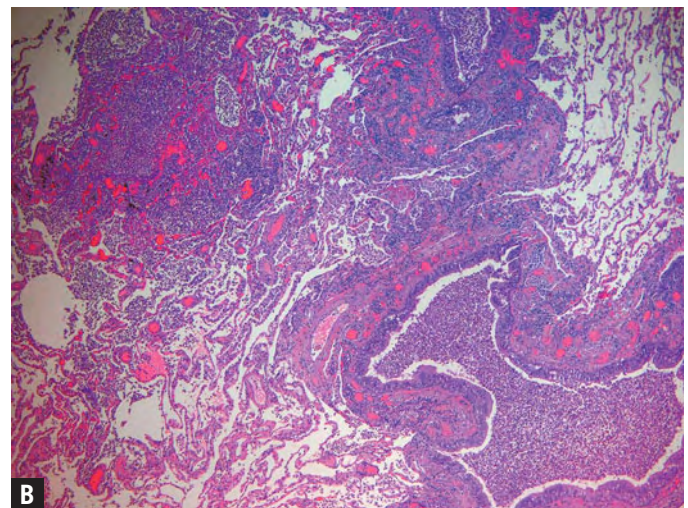
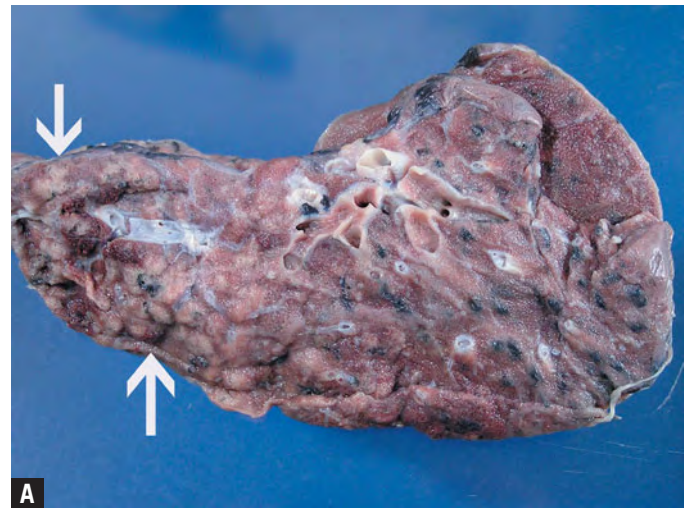
**Basic description:** Infection of the lung caused by a bacterial organism that was acquired outside the hospital setting and often follows a viral upper respiratory tract infection.

**Causative organisms:** Bacteria (e.g., *Streptococcus pneumoniae*, *Staphylococcus aureus*, *Haemophilus influenzae*, and *Klebsiella pneumoniae*, which occurs in chronic alcoholics).

**Two types of community-acquired typical pneumonia: bronchopneumonia and lobar pneumonia**

#### ■ Bronchopneumonia

- **Basic description:** Patchy distribution of neutrophilic infiltrate and bacterial organisms in one or many lobes (Figure 13-11 A and B).
- **Causative organisms:** Many, including *Streptococcus pneumoniae* and *Klebsiella pneumoniae*.
- **General mechanisms of development of bronchopneumonia** (i.e., conditions that predispose to the development of bronchopneumonia): Loss of the cough reflex, injury to the mucociliary escalator, dysfunction of alveolar macrophages, pulmonary edema and congestion, and accumulation of secretions. Loss of the cough reflex, injury to the mucociliary escalator, and dysfunction of alveolar macrophages represent loss of protective mechanisms; pulmonary edema and congestion and the accumulation of secretions represent production of a fertile environment for bacterial infection.
- **Specific risk factors for development of bronchopneumonia**
  - Underlying chronic medical condition (e.g., malignancy, cirrhosis, ischemic heart disease, neurodegenerative disease).
  - The extremes of life (very young and very old).
  - Immunoglobulin deficiency (e.g., leukemia, lymphoma).
  - Absent spleen: Patients who have undergone a splenectomy are more prone to develop infections caused by encapsulated organisms. Patients may be postsplenectomy status due to trauma, or they may have had an autopsplenectomy as a result of sickle cell anemia.



**Figure 13-11.** Acute bronchopneumonia. **A**, Note the patchy distribution of the pneumonia, affecting only part of one lobe. The arrows indicate the tan-yellow areas of consolidation. **B**, Note once again the patchy distribution of the pneumonia, with bronchiole involvement in the right lower corner. Hematoxylin and eosin, 40 $\times$ .

### ■ Lobar pneumonia

- **Basic description:** Pneumonia confined to one lobe of the lung (Figure 13-12).
- **Causative organisms:** Almost all cases are due to *Streptococcus pneumoniae*.
- **Risk factors:** None are necessary; lobar pneumonia can arise in an otherwise healthy individual.
- **Morphologic stages of lobar pneumonia in order of development**
  - Edema and congestion.
  - **Red hepatization:** Lobe is red and firm, and alveoli are filled with neutrophils, fibrin, and red blood cells.
  - **Grey hepatization:** Red blood cells have lysed; fibrin and macrophages remain.
  - Resolution.

### Complications of community-acquired typical pneumonia:

*Note, these complications can occur in many other types of pneumonia, not just community-acquired typical pneumonia.*

- Abscess (see pulmonary abscess below).
- **Empyema** (i.e., extension of infection through the pleural surface into the pleural cavity) (Figure 13-13).
- Fibrosis and scarring.
- Hematogenous dissemination resulting in meningitis, arthritis, and endocarditis.

### Clinical presentation of community-acquired typical pneumonia

- **Signs and symptoms:** Acute onset of fever, chills, rigors, productive cough, and pleuritic chest pain. Rales are often present, and dullness to percussion may indicate consolidation or a pleural effusion. Blood-tinged “currant jelly” sputum is classically associated with *Klebsiella pneumoniae*.
- **Chest radiograph:** Infiltrates; consolidation may be present, and pleural effusion is not uncommon.
- **Diagnosis:** Based upon symptoms and radiograph.
- **Note:** *Legionella pneumophila* is acquired by aerosols. Patients often have extrapulmonary symptoms such as headache, hyponatremia, bradycardia, and diarrhea.

## COMMUNITY-ACQUIRED ATYPICAL PNEUMONIA

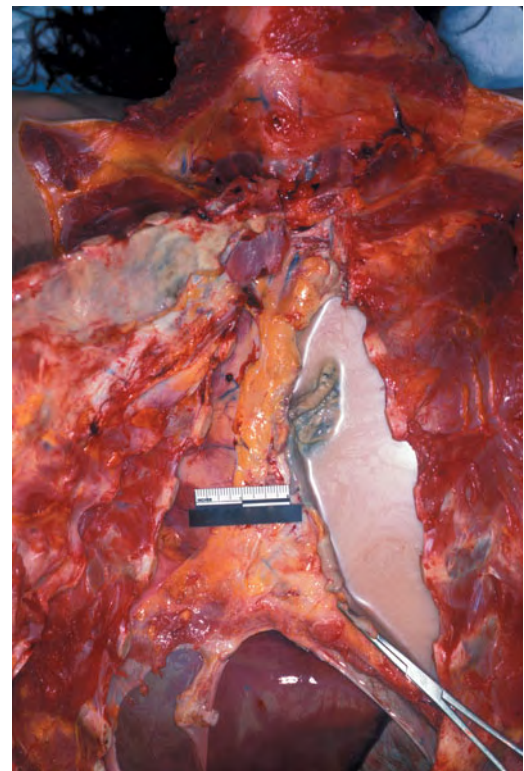
**Basic description:** Pulmonary infection, usually due to non-bacterial organism (excluding fungi) that was acquired outside the hospital setting. The condition is called atypical pneumonia because patients have only moderate sputum production, no physical findings of consolidation, lack of alveolar exudates, and only a moderate increase in the white blood cell count (unlike typical bacterial pneumonia).

**Causative organisms:** Viruses (e.g., influenza A and B, respiratory syncytial virus, and adenovirus), *Haemophilus parainfluenzae*, *Mycoplasma*, and *Chlamydia pneumoniae*.

**Complications of community-acquired atypical pneumonia:** Bacterial superinfection. Most deaths due to influenza are caused by a secondary *Staphylococcus aureus* infection.



**Figure 13-12.** Lobar pneumonia. The lower lobe of this lung is completely consolidated (firm, tan-yellow), and the upper lobe is virtually uninvolved.



**Figure 13-13.** Empyema. The left pleural cavity is filled with pus. Only a tip of one lobe of the left lung is visible within the cavity. Courtesy of Dr. Gary Dale, Forensic Science Division, Montana State Department of Justice, Missoula, MT.



**Microscopic morphology:** Interstitial lymphocytic infiltrate (Figure 13-14); may have diffuse alveolar damage.

#### Clinical presentation of community-acquired atypical pneumonia

- **Signs and symptoms:** Insidious onset of low-grade fever, nonproductive cough, headache, and myalgias. Symptoms may vary depending on the causative organism. Chest radiograph usually shows diffuse interstitial or alveolar infiltrates, and consolidation is less commonly observed than in typical pneumonia.
- **Important point:** SARS is caused by a coronavirus, and the course of the infection first affects the lower respiratory tract and then spreads throughout the body.

### NOSOCOMIAL PNEUMONIA

**Basic description:** Pulmonary infection acquired while hospitalized; usually bacterial, but sometimes fungal.

**Causative organisms:** Gram-negative bacilli, *Pseudomonas*, and, less commonly, *Staphylococcus aureus*.

**Important point regarding nosocomial pneumonia:** Organisms can be difficult to treat because they are often multidrug-resistant to antibiotics.

### ASPIRATION PNEUMONIA

**Basic description:** Pneumonia that occurs as a result of aspiration, usually in intoxicated or neuromuscularly impaired individuals.

**Causative organisms:** Mixed aerobic and anaerobic (oral flora) organisms, including aerobic and anaerobic streptococcus; *Staphylococcus aureus*, gram-negative organisms, and anaerobic organisms including *Bacteroides* species. Chemical injury also plays a role.

**Complication of aspiration pneumonia:** Lung abscess (Figure 13-15).

**Microscopic morphology of aspiration pneumonia:** Food material (e.g., skeletal muscle, vegetable matter) surrounded by neutrophils (Figure 13-16).

### NECROTIZING PNEUMONIA

**Basic description:** Pneumonia with prominent necrosis of the parenchyma and abscess formation.

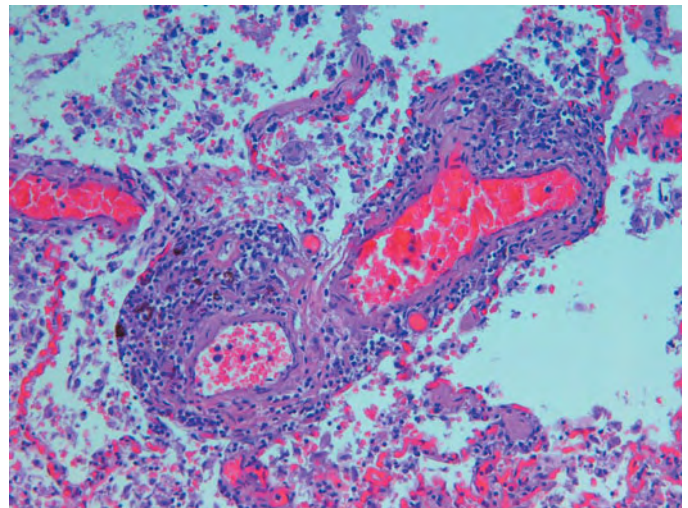
**Causative organisms:** *Streptococcus pneumoniae*, *Staphylococcus aureus*, *Klebsiella*, *Pseudomonas aeruginosa*, *Nocardia*.

**Morphology of necrotizing pneumonia:** Abscesses and focal destruction of parenchyma.

### CHRONIC PNEUMONIA

**Basic description:** Pneumonia of long duration.

**Causative organisms:** *Mycobacterium tuberculosis* and dimorphic fungi.



**Figure 13-14.** Interstitial pneumonia. Note the lymphocytic infiltrate within the tissue surrounding this vessel. Interstitial pneumonia is consistent with a viral or mycoplasmal etiology. Hematoxylin and eosin, 200 $\times$ .



**Figure 13-15.** Lung abscess in a patient with pneumonia. Note the loss of parenchyma in the center of the image. This area represents an abscess.



### Pulmonary tuberculosis (TB)

**Forms of TB:** include primary TB, secondary TB, primary progressive TB, and miliary TB

- **Primary TB:** Patients have **Ghon complex**, which is **Ghon focus** (i.e., granuloma at the periphery of the lung near the interlobar groove), plus enlarged and involved hilar lymph nodes. Primary TB is common. Lesions usually heal on their own and the granulomas become calcified; however, the organism is still present and held in check by the immune system. If the patient becomes immunocompromised, secondary TB can occur (Figure 13-17 A and B).
- **Secondary TB** (or **reactivation TB**): Granulomas occur at apices of the lung, because TB is aerophilic.
- **Primary progressive TB:** Morphologically, has the appearance of bronchopneumonia; usually due to primary TB infection occurring in a patient who is already immunocompromised.
- **Miliary TB:** Hematogenous dissemination of the organism to the lungs, liver, and spleen produces “millet seed” appearance.

### Complications of pulmonary tuberculosis

- Exsanguination, due to erosion of granulomas into the blood vessels.
- Basilar meningitis.
- **Pott disease:** Involvement of the vertebral column.
- Spread to other organs.

### Clinical presentation of pulmonary tuberculosis

- **Signs and symptoms:** Persistent productive cough, fever, chills, loss of appetite, night sweats, and weight loss. With blood vessel invasion, patients may have hemoptysis. With extensive involvement of the lung, patients may have dyspnea on exertion.
- **Testing:** Tuberculin skin test; culture of sputum.

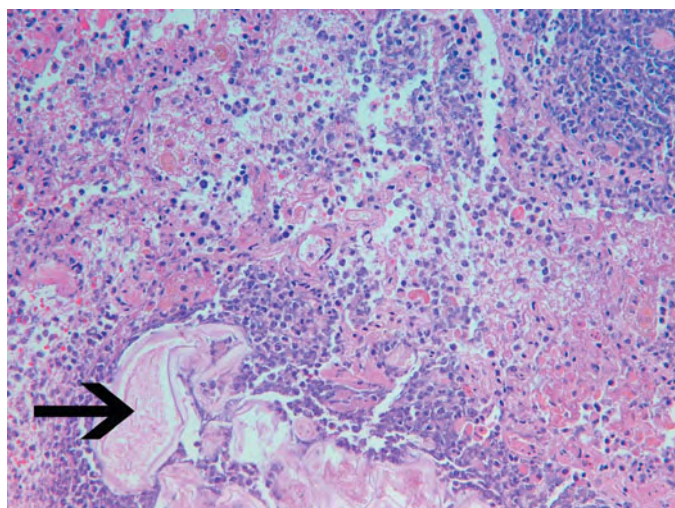
**Dimorphic fungi:** *Histoplasmosis capsulatum*, *Blastomyces dermatitidis*, and *Coccidioides immitis*.

### Geographic distribution of dimorphic fungi

- *Histoplasmosis capsulatum*: Ohio and Mississippi River Valleys. Usually associated with exposure to and subsequent inhalation of bird or bat droppings.
- *Blastomyces dermatitidis*: Distribution overlaps with *Histoplasmosis capsulatum* in central and southeastern United States.
- *Coccidioides immitis*: San Joaquin Valley in California and Arizona.

### Morphology of infection with dimorphic fungi

- **Gross:** Can appear similar to tuberculosis.
- **Microscopic**
  - *Histoplasmosis capsulatum*: 2–5  $\mu\text{m}$  organisms, in macrophages.
  - *Blastomyces dermatitidis*: Broad-based budding yeasts.
  - *Coccidioides immitis*: Spherules containing endospores.



**Figure 13-16.** Aspiration pneumonia. The arrow indicates foreign material within the pulmonary parenchyma. The neutrophilic infiltrate that dominates the remainder of the image is in response to the aspiration of this material. Hematoxylin and eosin, 200 $\times$ .

## PNEUMONIA IN THE IMMUNOCOMPROMISED PATIENT

### In HIV patients

- If CD4 count is  $> 200$  cells/ $\mu\text{L}$ , pneumonia is likely bacterial.
- If CD4 count  $< 200$  cells/ $\mu\text{L}$ , pneumonia is likely *Pneumocystis pneumonia*.
- If CD4 count is  $< 50$  cells/ $\mu\text{L}$ , pneumonia is likely cytomegalovirus (CMV) or *Mycobacterium avium-intracellulare*.

## PULMONARY ABSCESS

**Overview:** Pulmonary abscesses are a complication of several of the seven categories of pulmonary infections, including community-acquired typical and atypical pneumonias, aspiration pneumonia, and necrotizing pneumonia. Other causes of a pulmonary abscess include bronchial obstruction, neoplasms, and septic emboli due to hematogenous dissemination from another source (e.g., endocarditis).

**Location of abscess:** Usually lower lobes (right side more frequently than left side). The right main stem bronchus has a less acute angle than the left main stem bronchus; therefore, aspirated material enters the right bronchus more easily.

### Complications of lung abscess

- Pneumothorax, due to rupture into pleural cavity.
- Empyema, due to rupture into pleural cavity with subsequent extension of infection into the pleural cavity.

## PULMONARY NEOPLASMS

**Overview:** There are only two general categories of pulmonary neoplasms of clinical importance: small cell and non-small cell carcinoma. The importance of the small cell versus non-small cell designation is that small cell lung carcinoma is considered to have already metastasized at the time of diagnosis; therefore, it is treated with radiation and chemotherapy, and no further surgery. About 85–90% of lung tumors arise in active smokers or those who have recently stopped smoking, and the favored sites of metastases for pulmonary neoplasms are, in descending order, liver, brain, and bone. The three types of non-small cell carcinoma (squamous cell carcinoma, adenocarcinoma, and large cell carcinoma) as well as small cell carcinoma will be discussed below.

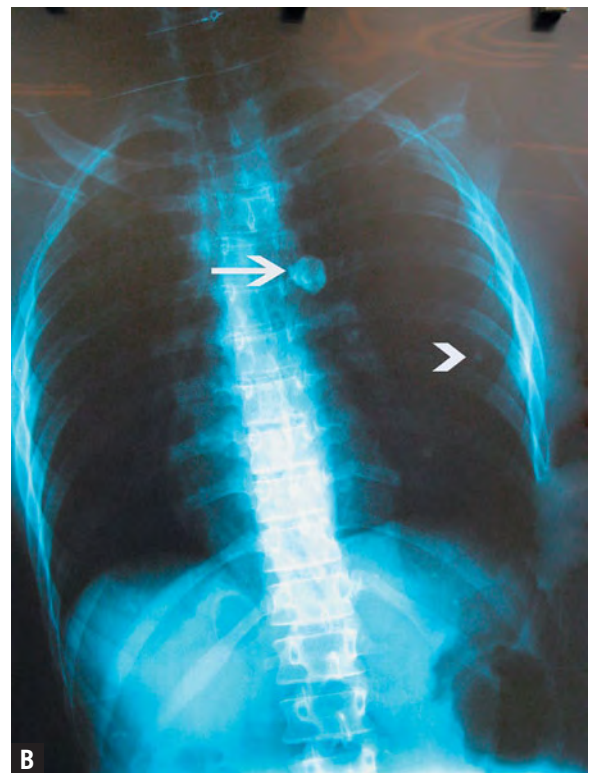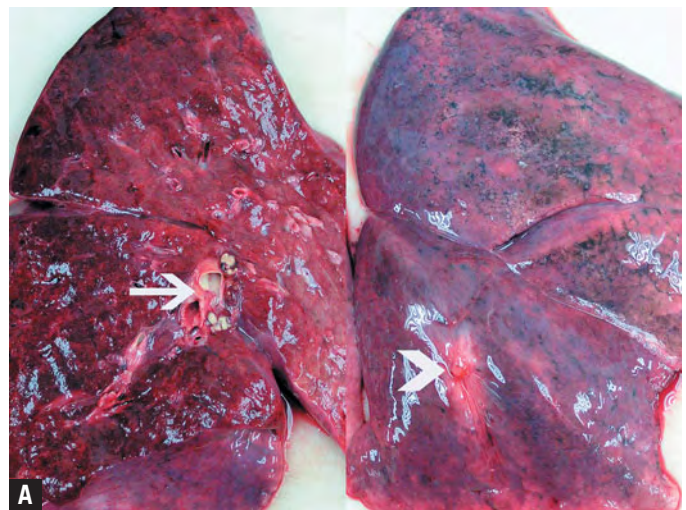
## SQUAMOUS CELL CARCINOMA

**Epidemiology:** Age 55–60 years or older; more common in males.

**Location:** Central or at or near the hilum of the lung (Figure 13-18).

**Risk factors for squamous cell carcinoma of the lung:** Cigarette smoking leads to squamous metaplasia, which can lead to squamous dysplasia, and then to carcinoma.

**Mutations:** Squamous cell carcinoma has the highest rate of *p53* mutations among lung tumors.



**Figure 13-17.** Healed primary pulmonary tuberculosis. **A**, A lung sectioned from superior to inferior, with the halves placed side-by-side on the table. The pleural surface has a contracted nodule, which represents the Ghon focus (arrowhead), and the hilum has multiple lymph nodes with calcified caseous necrosis (arrow). Together, the Ghon focus and the hilar lymphadenopathy are referred to as the Ghon complex. **B**, A chest radiograph of a patient with healed primary pulmonary tuberculosis. The hilar lymphadenopathy (arrow) and Ghon focus (arrowhead) will calcify, allowing them to be visualized by chest radiograph.



**Associated conditions:** Squamous cell carcinoma can produce parathormone-like protein, which can result in hypercalcemia.

### Morphology of squamous cell carcinoma

- **Gross:** Lung mass, which often cavitates due to necrosis.
- **Microscopic:** Keratin pearls and intercellular bridges.

## ADENOCARCINOMA

**Epidemiology:** Age younger than 45 years; female predominance.

**Location:** Peripheral or at or near the pleural surface (Figure 13-19).

**Risk factors for pulmonary adenocarcinoma:** Weakly linked to cigarette smoking.

### Pathogenesis of adenocarcinoma

- **Atypical adenomatous hyperplasia** can lead to bronchioalveolar carcinoma, which can lead to invasive adenocarcinoma.
- **Important points regarding bronchioalveolar carcinoma**
  - Grows along the alveolar septae (referred to as **lepidic growth**) (Figure 13-20).
  - No invasive component.
  - Can present in patchy distribution similar to pneumonia.
  - Classic symptom is bronchorrhea.

**Microscopic morphology of invasive adenocarcinoma:** Infiltrative glandular formations; architecture includes papillary and solid forms.

## LARGE CELL CARCINOMA

**Basic description:** Most likely a poorly differentiated squamous cell carcinoma or adenocarcinoma. Anaplasia inhibits determination of epithelial-type origin of tumor (Figure 13-21).

## SMALL CELL LUNG CARCINOMA

**Epidemiology:** Older males.

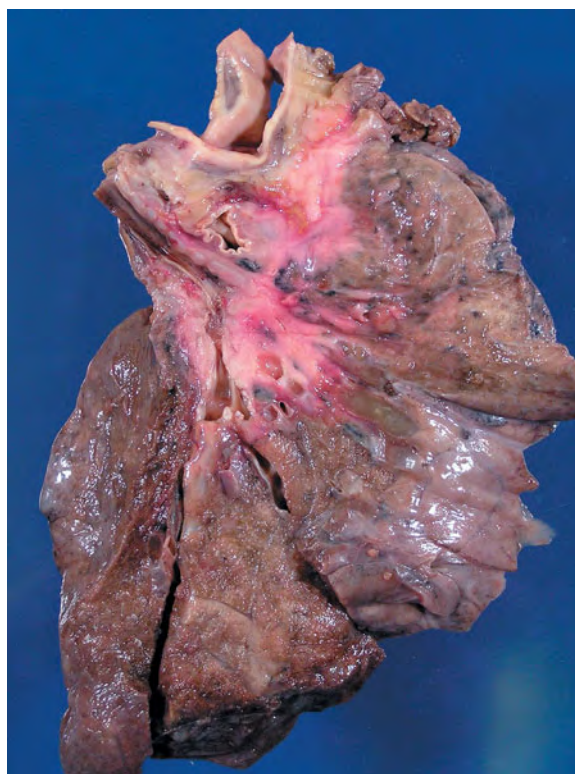
**Location:** Central, along bronchi.

**Risk factors for small cell lung carcinoma:** Smoking (only 1% of cases occurs in nonsmokers).

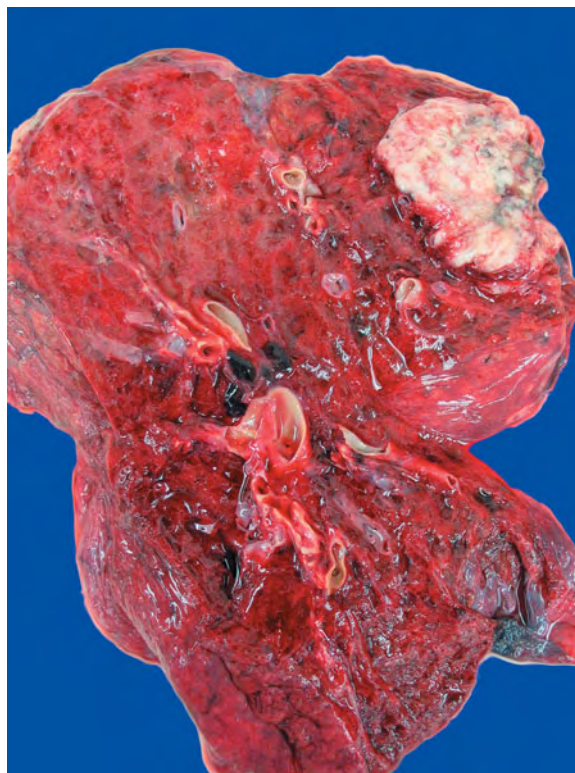
**Mutations:** *c-MYC*, *RB*.

### Associated paraneoplastic syndromes

- Small cell lung carcinoma can produce adrenocorticotrophic hormone (ACTH), antidiuretic hormone (ADH), and calcitonin-like substances.
- Clubbing of fingers.
- **Lambert-Eaton syndrome**, due to autoantibodies to neuronal calcium channels.



**Figure 13-18.** Squamous cell carcinoma of the lung. Note the white-tan contracted mass centered at the hilum of this lung. Characteristically, squamous cell carcinoma has a central location.



**Figure 13-19.** Adenocarcinoma of the lung. Note the white-tan nodule at the periphery of this lung. Characteristically, adenocarcinoma has a peripheral location.



**Microscopic morphology of small cell carcinoma:** Small cells with little cytoplasm that have nuclear molding. Cells are fragile and crush easily upon biopsy (Figure 13-22 A and B).

#### Complications of pulmonary neoplasms

- Partial obstruction of airway, predisposing to pneumonia.
- Complete obstruction of airway, leading to atelectasis.
- Suppurative bronchitis, can lead to bronchiectasis.
- Abscesses.
- Local extension can cause hoarseness (with involvement of recurrent laryngeal nerve); local extension can also cause pleuritis and pericarditis.

#### Important points regarding pulmonary neoplasms

- **Virchow node:** Enlarged supraclavicular node; its presence is worrisome for lung carcinoma.
- **Superior vena cava syndrome:** External compression of superior vena cava by the tumor obstructs blood return to the heart from the upper body, resulting in congestion and edema of the face and upper extremities.
- **Pancoast tumor:** Erosion of tumor through the apex of the lung can cause **Horner syndrome**, with involvement of the cervical and brachial sympathetic ganglia. The features of Horner syndrome are **ipsilateral enophthalmos** (i.e., recession of the eyeball within the orbit), **ptosis** (i.e., drooping of the eyelid), **meiosis** (i.e., pupil constriction), and **anhidrosis** (i.e., absence of sweating).

#### Important points regarding staging of pulmonary neoplasms

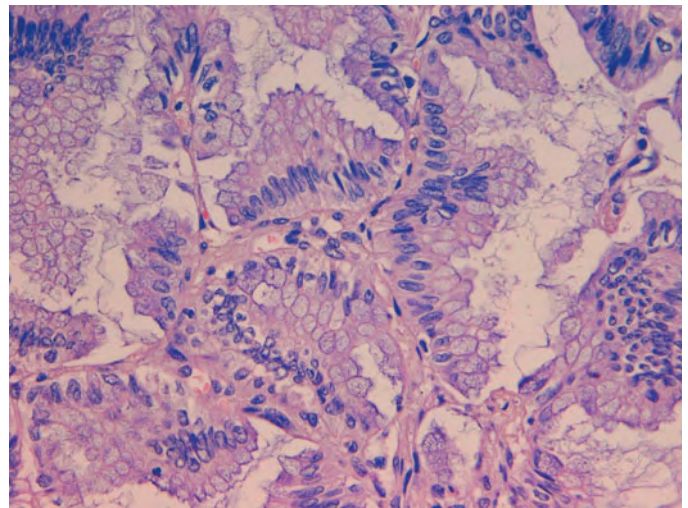
- Size of 3 cm is important (i.e., difference between T1 and T2).
- Involvement of pleura and/or mainstem bronchus is important (i.e., difference between T1 and T2).

#### Clinical presentation of pulmonary neoplasms

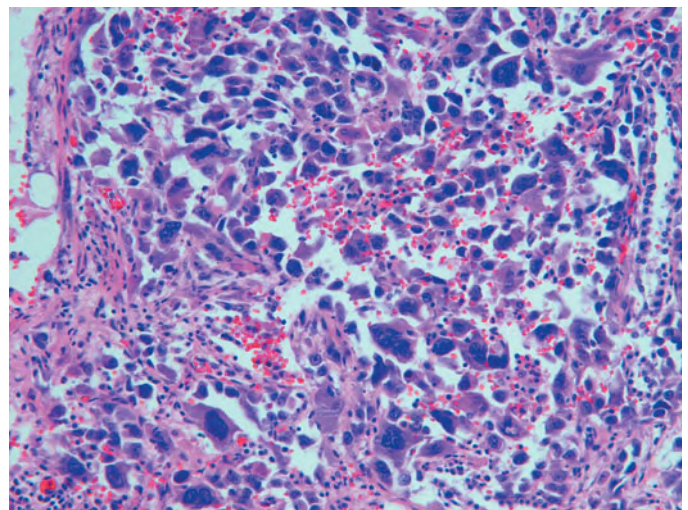
- Depends upon location, size, metastases, and paraneoplastic syndromes.
- **Signs and symptoms:** Cough, hemoptysis, dyspnea, obstructive pneumonia, wheezing and stridor due to airway obstruction, chest wall pain due to infiltration of chest wall and nerves, and hoarseness due to involvement of recurrent laryngeal nerve.
- **Symptoms of metastases:** Seizures, bone pain, weight loss.
- **Diagnosis:** CT scan, biopsy.

## MISCELLANEOUS PLEURAL CONDITIONS

**Overview:** Pleural effusions, pneumothorax, and mesothelioma are important pleural conditions that will be discussed below. Specifically, the evaluation of a pleural effusion to determine its origin will be stressed.



**Figure 13-20.** Bronchioalveolar carcinoma. The alveolar septae are lined by tall columnar neoplastic cells, which is referred to as lepidic growth. There is no invasion. Hematoxylin and eosin, 200×.



**Figure 13-21.** Large cell carcinoma. Note the marked pleomorphism, with no definitive squamoid or glandular differentiation apparent in this section. Most likely, large cell carcinomas represent a poorly differentiated squamous cell carcinoma or adenocarcinoma. Hematoxylin and eosin, 200×.

## PLEURAL EFFUSIONS

### Forms

- **Transudate:** Serous fluid; often due to left-sided heart failure.
- **Exudate:** Most commonly due to pulmonary infections, carcinoma, infarction, or viral pleuritis; occasionally due to connective tissue disorders and uremia.

### Differentiating transudate from exudate

- **Exudates have:** specific gravity  $> 1.016$ ; pleural fluid protein of  $> 3.0$  gm/dL; pleural fluid/serum protein ratio of  $> 0.5$ ; lactate dehydrogenase (LDH) of  $> 200$  U/L; or pleural/serum LDH ratio of  $> 0.6$ —any of these values can distinguish a pleural effusion as an exudate.
- *If the fluid is a transudate, no further testing is necessary.*

### Testing to determine source of exudate

- If elevated red blood cell count, consider traumatic or malignant origin.
- If elevated white blood cell count, consider empyema (see Figure 13-13).
- If elevated eosinophil count, consider collagen vascular disease, pleural air, or blood.
- If pH is  $< 7.2$ , consider malignancy, rheumatoid arthritis, or infection.
- If amylase is elevated, consider esophageal rupture or acute pancreatitis.
- If triglyceride level is  $> 100$  mg/dL, consider chylous effusion.

### Clinical presentation of pleural effusions

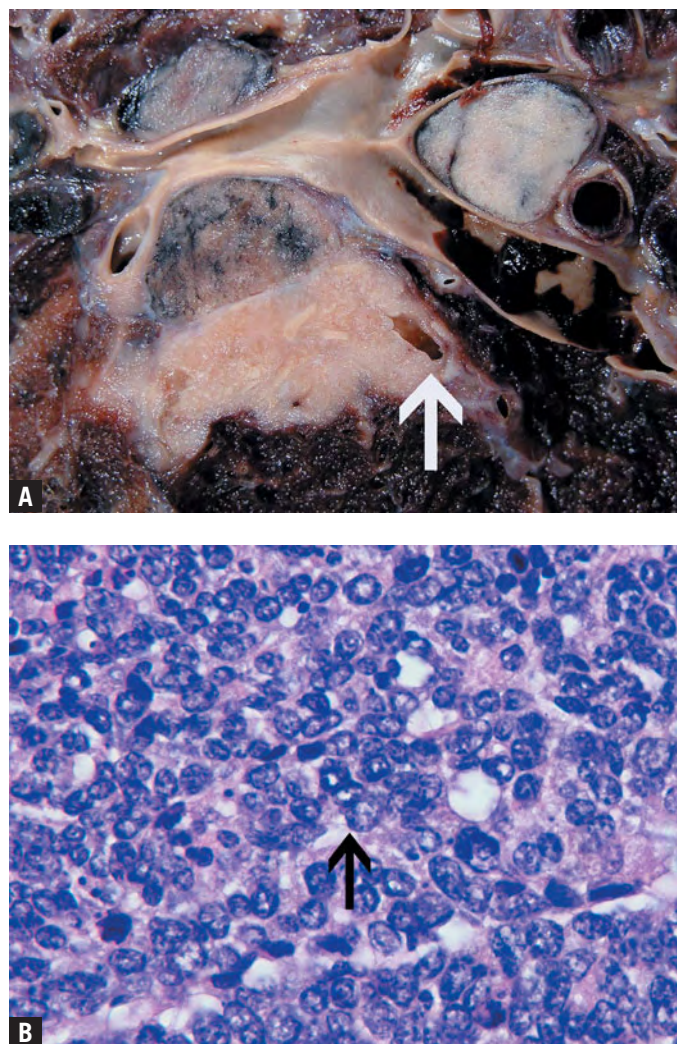
- **Symptoms:** Dyspnea; sharp chest pain due to involvement of the parietal pleura that is worsened by coughing or breathing; or dull chest pain due to involvement of the visceral pleura; or dry cough due to irritation of the pleural surfaces.
- **Signs:** Dullness to percussion, decreased breath sounds, and decreased tactile fremitus.
- **Diagnosis of pleural effusion:** Confirmed by physical examination and chest radiograph.
- Thoracentesis on a new pleural effusion (i.e., one that has no recognized or previously diagnosed etiology) can provide fluid for the above testing to determine its source.

## PNEUMOTHORAX

**Basic description:** Air within a pleural cavity.

**Two types** (listed in order of significance)

- **Tension pneumothorax:** Defect in the pleura acts as a one-way valve. Air enters the pleural cavity with inspiration but cannot leave it (ball-valve mechanism). This is a medical emergency, and if a tension pneumothorax is suspected, a needle thoracotomy is required to relieve the tension.
- **Nontension pneumothorax:** Air trapped in the pleural cavity; clinical consequences depend upon size; most resorb.
- **Important point:** Tension pneumothorax causes a mediastinal shift; a nontension pneumothorax does not.



**Figure 13-22.** Small cell carcinoma of the lung. **A**, Small cell carcinoma characteristically grows along the bronchi. In this photograph, the arrow indicates the lumen of the bronchus around which the tumor is growing. **B**, Small cell carcinoma is characterized histologically by cells with a high nuclear to cytoplasmic ratio, usually no nucleoli, and the cells have nuclear molding (i.e., indentation of the cells due to apparent pressure from adjacent cells, indicated by the arrow). Hematoxylin and eosin, 1000 $\times$ .



### Two types of pneumothorax (by etiology)

- **Spontaneous:** May be primary (no underlying lung disease) or secondary (patient has underlying lung disease). The classic spontaneous pneumothorax occurs in a tall, thin, young male patient.
- **Traumatic.**

### Clinical presentation of pneumothorax

- **Symptoms:** Sudden onset of sharp chest pain, worsened by inspiration; tachypnea. With a tension pneumothorax, patients also have hypotension and cyanosis.
- **Signs:** Hyperresonance to percussion, decreased tactile fremitus, and decreased breath sounds over the affected area. With a tension pneumothorax, patients will have elevated jugular venous pressure.

## MESOTHELIOMA

**Basic description:** Malignant tumor of the pleural cavity derived from mesothelial cells.

**Important point:** Almost always due to exposure to asbestos.

### Morphology of mesothelioma

- **Gross:** Tumor encases the lung.
- **Microscopic:** Epithelioid or sarcomatoid components.

## UPPER RESPIRATORY TRACT PATHOLOGY

**Overview:** Briefly discussed below are vocal cord nodules and squamous cell carcinoma of the larynx. The final entry of this section discusses the **field effect**, an important concept when considering the effects and treatment of smokers with a malignancy of the upper or lower respiratory tract.

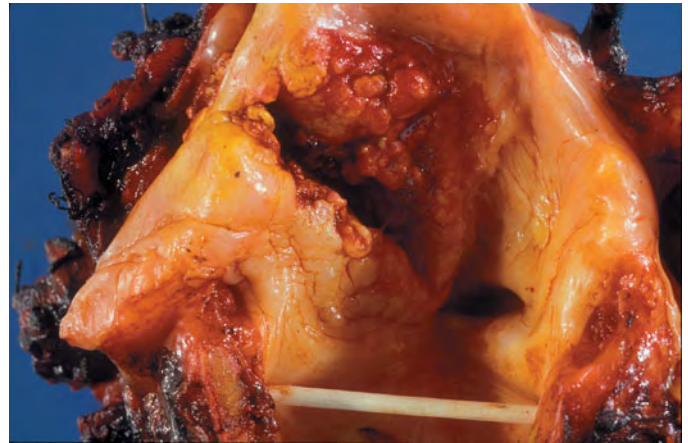**Vocal cord nodules:** Seen in singers and smokers.

**Squamous cell carcinoma of the larynx:** The type is based upon location of tumor and includes glottic, supraglottic, and subglottic ([Figure 13-23](#)).

- **Glottic:** Patients present earlier because the tumor produces symptoms earlier. There are fewer lymphatics on the true vocal cords, so these tumors are less likely to have metastasized. It is the most common location for squamous cell carcinoma of the larynx.
- **Supraglottic:** Area is rich in lymphatics; therefore, tumors in this site will metastasize sooner than those in other areas.
- **Subglottic:** Patients present late in the course of disease, because the tumor must cause significant obstruction of the upper airway to produce symptoms and thus to be diagnosed.

## FIELD EFFECT

**Basic description:** Cigarette smoke exposes multiple areas of the body to carcinogens; therefore, development of carcinoma in one area of the body may precede development in another area. For example, patients with squamous cell carcinoma of the larynx often develop squamous cell carcinoma of the lung at a later time. Patients can also have synchronous tumors (i.e., occurring at the same time) in different locations.



**Figure 13-23.** Laryngeal squamous cell carcinoma. Centered above the left true vocal cord is an ulcerated polypoid mass. The presentation of laryngeal squamous cell carcinoma depends upon its location. Tumors growing on the vocal cords present the earliest, due to changes in the voice induced by the growth of the neoplasm.





## CHAPTER 14

# GASTROINTESTINAL PATHOLOGY

### OVERVIEW

The main purpose of the gastrointestinal tract is the transport of food and the absorption of nutrients. Many pathologic conditions of the gastrointestinal tract impair either or both of these functions. The gastrointestinal tract, and especially the colon, is a common site of malignancy. The two main symptoms related to pathology of the gastrointestinal tract are abdominal pain and gastrointestinal hemorrhage.

The differential diagnosis for abdominal pain can be classified as either acute or chronic, based upon the length of time of the pain ([Table 14-1](#)). The four categories of the causes of acute abdominal pain are (1) inflammation, including appendicitis, cholecystitis, pancreatitis, and diverticulitis; (2) perforation; (3) obstruction; and (4) vascular disease, including acute ischemia and ruptured abdominal aortic aneurysm. The five categories of causes of chronic abdominal pain are (1) inflammation, including peptic ulcer disease, esophagitis, inflammatory bowel disease, and chronic pancreatitis; (2) vascular disease, including chronic ischemia; (3) metabolic disease, including porphyria; (4) abdominal wall pain; and (5) functional causes, including irritable bowel syndrome. The most frequent causes of chronic abdominal pain are functional.

The second main symptom of gastrointestinal pathology is bleeding ([Table 14-2](#)). The character of the blood can help identify the source: **hematemesis** (i.e., vomiting of bright red blood), if the source is gastrointestinal, is most likely due to a source proximal to the ligament of Treitz. **Melena** (i.e., black, tarry stool) is most often due to upper gastrointestinal bleeding. **Hematochezia** (i.e., bright red blood per rectum) usually indicates a lower gastrointestinal bleed (or very rapid upper gastrointestinal bleed). The differential diagnosis of upper gastrointestinal bleeding includes gastritis, esophageal varices, and peptic ulcer disease (as a result of erosion into a blood vessel). The diagnosis of the source of an upper gastrointestinal bleed is often made by endoscopy. The differential diagnosis of lower gastrointestinal bleeding includes a rapid upper gastrointestinal bleed, diverticulosis, infections (e.g., *Salmonella*, *Shigella*), cancer, inflammatory bowel disease, and anal fissures or hemorrhoids. The diagnosis of a lower gastrointestinal bleed is often determined by flexible sigmoidoscopy or colonoscopy.

This chapter will discuss pediatric gastrointestinal disorders, pathology of the oral cavity and salivary glands (including leukoplakia and salivary gland tumors); esophageal pathology (including motor disturbances, esophagitis, Barrett esophagus, and tumors); gastric pathology (including acute and chronic gastritis, peptic ulcer disease, and gastric tumors); and small and large intestinal pathology (including causes of diarrhea and constipation, malabsorption, celiac sprue and inflammatory bowel diseases, vascular disorders, causes of obstruction, diverticular disease, and intestinal tumors, including colonic adenocarcinoma and carcinoid tumors).

## PEDIATRIC GASTROINTESTINAL DISORDERS

**Overview:** Although there are many gastrointestinal disorders associated with the pediatric population, only some of the more common conditions will be discussed below. Some of the conditions discussed below, including congenital pyloric stenosis, duodenal atresia, Hirschsprung disease, and intussusception, most commonly present during infancy and childhood, whereas Meckel diverticulum, a congenital malformation, commonly presents during adulthood or may be asymptomatic throughout the patient's life.

### CONGENITAL PYLORIC STENOSIS

**Epidemiology:** 1 in 300–900 births; prevalence in males, with a 4:1 ratio of male to female.

**Association:** Turner syndrome, trisomy 18, erythromycin.

#### Clinical presentation of congenital pyloric stenosis

- **Symptoms:** Projectile nonbilious vomiting, which presents during the second or third week of life.
- **Signs:** Palpable mass (“olive-shaped”) in the area of the pylorus. Metabolic alkalosis from vomiting.
- **Treatment:** Surgical incision (pylorotomy).

#### Microscopic morphology of congenital pyloric stenosis:

Hypertrophy of the smooth muscle of the pylorus; may have inflammation of the overlying mucosa and submucosa.

### DUODENAL ATRESIA

**Basic description:** Failure of recanalization of the duodenal lumen during weeks 3–7 of embryologic development.

**Epidemiology:** 1 in 6000 births; more common in patients with Down syndrome.

#### Clinical presentation of duodenal atresia

- **Symptoms:** Bilious vomiting in the first 24 hours of life.
- **Diagnosis:** “Double-bubble” sign and absence of gas distal to the duodenum on plain films.

**TABLE 14-1.** Causes of Abdominal Pain

Time Course	General Category	Specific Causes
Acute	Inflammation	Appendicitis, cholecystitis, acute pancreatitis
	Perforation	Peptic ulcer
	Obstruction	Volvulus
	Vascular	Acute ischemia, ruptured abdominal aortic aneurysm
Chronic	Inflammation	Peptic ulcer, esophagitis, IBD, chronic pancreatitis
	Vascular	Chronic ischemia
	Metabolic	Porphyria
	Abdominal wall pain Functional	Irritable bowel syndrome

IBD, inflammatory bowel disease.

**TABLE 14-2.** Causes of Gastrointestinal Bleeding

Upper GI bleeding	Esophageal varices, esophageal neoplasms, Mallory-Weiss laceration, gastritis, peptic ulcer disease
Lower GI bleeding	Rapid upper GI bleeding, diverticulosis, infectious colitis, angiodysplasia, IBD, neoplasm, anal fissure, hemorrhoids

GI, gastrointestinal tract; IBD, inflammatory bowel disease.

## HIRSCHSPRUNG DISEASE

**Epidemiology:** 1 in 5000 live births; more common in males, with male to female ratio of 4:1. Commonly associated with Down syndrome.

**Pathogenesis of Hirschsprung disease:** Aganglionosis of a segment of the intestinal tract as a result of dysfunctional migration of neural crest cells.

**Mutation:** 50% of cases associated with *RET*.

### Types of Hirschsprung disease

- **Long-segment disease:** Involves entire colon.
- **Short-segment disease:** Involves rectum and sigmoid colon.

**Complications of Hirschsprung disease: Toxic megacolon** (i.e., markedly distended segment of bowel), which can lead to thinning and rupture of the wall.

**Clinical presentation:** Failure to pass meconium by newborns, followed by constipation. If only a very short segment of intestine is involved, built-up pressure may cause diarrhea.

## INTUSSUSCEPTION

**Basic description:** Collapse of a proximal portion of bowel into a distal portion.

**Incidence:** 2 in 1000 births.

### Clinical presentation of intussusception

- **Symptoms and signs:** Occurs mostly in children aged 2 months to 5 years. Presents with a classic triad of colicky abdominal pain, bilious vomiting, and “currant jelly” stools. A sausage-shaped right upper quadrant mass may be palpated.
- **Diagnosis:** Concentric circles of bowel wall may be visualized on ultrasound (“**target sign**”). Contrast enema is usually diagnostic and may be therapeutic as well.

## MECKEL DIVERTICULUM

**Basic description:** Congenital abnormality of the small intestine resulting from persistence of the omphalomesenteric duct; a true diverticulum containing all three layers of bowel wall.

**Incidence:** Present in 2% of the general population.

### Clinical presentation of Meckel diverticulum

- **Symptoms:** Most are asymptomatic. May present as obstruction or intussusception.
- **Diagnosis:** Meckel scan (technetium scintiscan).

**Important point:** Rule of Two’s (all of which apply to Meckel diverticulum): 2% of the population, 2 inches long, 2 feet from ileocecal valve, child younger than age 2, and 2 types of tissue (ectopic stomach or pancreas).



## PATHOLOGY OF THE ORAL CAVITY AND SALIVARY GLANDS

**Overview:** Only some of the more common and important conditions that affect the oral cavity and salivary glands, including hairy leukoplakia, leukoplakia, squamous cell carcinoma of the oral cavity, and various salivary gland tumors, will be discussed here.

### HAIRY LEUKOPLAKIA

#### Morphology

- **Gross:** White patches of “hairy” hyperkeratotic thickening on the lateral surface of the tongue.
- **Microscopic:** Hyperparakeratosis, acanthosis; “balloon cells” in the stratum spinosum.

**Association:** Immunosuppression

- About 80% of patients with hairy leukoplakia have human immunodeficiency virus (HIV) infection.
- About 20% have immunosuppression due to other causes, including cancer therapy.

**Cause of hairy leukoplakia:** Epstein-Barr virus (EBV) infection.

### LEUKOPLAKIA

**Basic description:** White patch on oral mucosa that cannot be scraped off (i.e., it is *not* candidiasis).

**Importance:** 5–25% of cases are premalignant. Tobacco use is a major risk factor.

### SQUAMOUS CELL CARCINOMA OF THE ORAL CAVITY

**Incidence:** About 95% of head and neck tumors are squamous cell carcinoma.

**Risk factors:** Alcohol and tobacco use.

**Mutations:** Loss of heterozygosity of 9p21 involving the *p16* gene.

### SALIVARY GLAND TUMORS

**Overview:** The smaller the gland involved, the more likely the tumor in it will be malignant. The two types of salivary gland tumors discussed here are pleomorphic adenoma and mucoepidermoid carcinoma.

#### PLEOMORPHIC ADENOMA

**Epidemiology:** About 60% of tumors of the parotid gland are pleomorphic adenomas. Pleomorphic adenomas are rare in the minor salivary glands.

**Risk factor:** Radiation.

#### Morphology of pleomorphic adenoma

- **Gross:** Round, well demarcated.

- **Microscopic:** Three components are ductal cells, myoepithelial cells, and matrix (myxoid, hyaline, or chondroid). Each component forms a variable amount of the tumor (Figure 14-1).

**Clinical presentation of pleomorphic adenoma:** Slow growing; painless.

#### Important points

- Although pleomorphic adenomas are benign, they must be completely excised with a wide margin. If the tumor is “shelled out” during surgery (i.e., removed intact with no margins of non-neoplastic tissue), it has a high rate of recurrence.
- Carcinoma can occasionally arise within a pleomorphic adenoma. Termed **carcinoma ex pleomorphic adenoma**, patients with these tumors have a poor survival rate (40% mortality at 5 years).

### MUCOEPIDERMOID CARCINOMA

**Basic description:** Malignant tumor of the salivary glands.

**Incidence:** Most common malignant tumor of the salivary glands; 65% are found in the parotid gland.

#### Microscopic morphology of mucoepidermoid carcinoma

- Cords and sheets of squamous, mucinous, and intermediate cells. Mucinous cells stain positive with a mucin stain.
- **Differentiation:** Vary from bland cells to very anaplastic cells, resulting in low to intermediate to high-grade tumors.

### MOTOR DYSFUNCTION OF THE ESOPHAGUS

**Overview:** Two conditions that cause motor dysfunction of the esophagus are **hiatal hernia** and **achalasia**.

#### HIATAL HERNIA

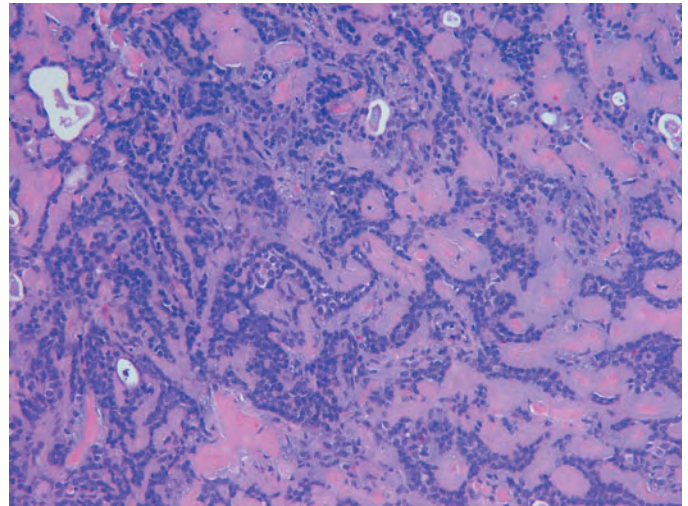
**Basic description:** Condition in which a segment of the stomach protrudes through the diaphragm into the mediastinum.

#### Types of hiatal hernia: sliding and paraesophageal

- **Sliding:** A segment of stomach is above the gastroesophageal junction. In effect, the gastroesophageal junction is positioned higher than normal and some stomach is above the diaphragm. A hiatal hernia is due to separation of the diaphragmatic crux.
- **Paraesophageal:** A small pouch of stomach protrudes through the esophageal hiatus adjacent to the gastroesophageal junction.

#### Complications of hiatal hernia

- Gastroesophageal reflux: Many patients with gastroesophageal reflux have hiatal hernias and many patients with hiatal hernias have reflux, but the two may or may not be related.



**Figure 14-1.** Pleomorphic adenoma. The background is a variably eosinophilic and myxoid acellular matrix. Interspersed within the background matrix are myoepithelial cells. The third component of pleomorphic adenomas is ductules. Hematoxylin and eosin, 40×.

- Ulcers, bleeding, and perforation can occur in patients with gastroesophageal reflux.
- Paraesophageal hernias can undergo strangulation or obstruction.

### ACHALASIA

**Basic description:** Achalasia is a condition caused by increased tone of the lower esophageal sphincter with subsequent failure to relax, and is associated with aperistalsis and distal esophageal dilation.

**Mechanism:** Loss of intrinsic vasoactive intestinal polypeptide (VIP) and nitric oxide inhibitory innervation of the lower esophageal sphincter; may be primary or secondary. Secondary achalasia is often due to Chagas disease, malignancy, or sarcoidosis.

#### Complications of achalasia

- Dysphagia, with regurgitation and aspiration of food.
- Squamous cell carcinoma, *Candida* infection, diverticuli.

#### Morphology of achalasia

- **Gross:** Dilation of upper esophagus.
- **Microscopic:** Inflammation of the esophageal myenteric plexus.

**Clinical presentation of achalasia:** Progressive dysphagia of solids and liquids. “Bird-beak” esophagus on barium swallow is classic.

## NON-NEOPLASTIC DISORDERS OF THE ESOPHAGUS ASSOCIATED WITH ALCOHOL USE

**Overview:** Two non-neoplastic disorders of the esophagus associated with alcohol use are **Mallory-Weiss lacerations** and **esophageal varices**.

### MALLORY-WEISS LACERATION

**Basic description:** Tear in the esophagus at the gastroesophageal junction.

**Mechanism of Mallory-Weiss laceration:** Reflex relaxation of the lower esophageal sphincter prior to antiperistalsis is overcome by prolonged vomiting.

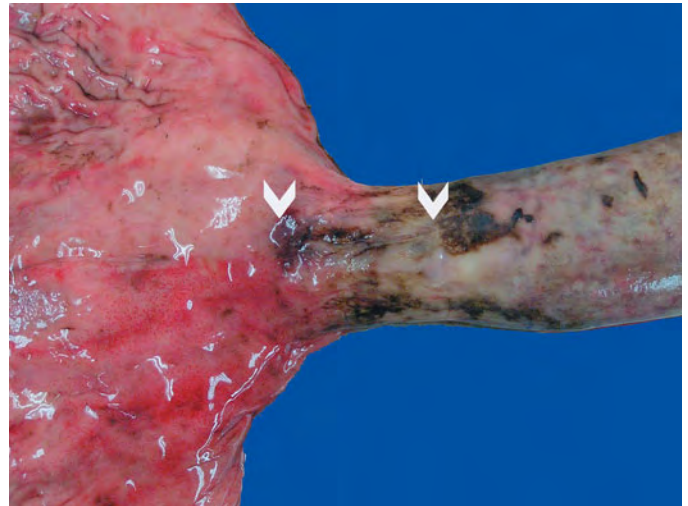
**Risk factors:** Alcoholism; hiatal hernia.

#### Complications of Mallory-Weiss laceration

- Gastrointestinal bleeding.
- Ulcer.
- Perforation of the esophagus with resultant mediastinitis (note: complete rupture of the esophagus is referred to as **Boerhaave syndrome**).

**Gross morphology:** Longitudinal tears at the gastroesophageal junction (Figure 14-2).

**Clinical presentation of Mallory-Weiss laceration:** Hematemesis after prolonged vomiting.



**Figure 14-2.** Mallory-Weiss tear. Between the arrowheads is a tear at the gastroesophageal junction. Mallory-Weiss tears are the result of prolonged vomiting and are often associated with alcoholism.



### ESOPHAGEAL VARICES

**Basic description:** Dilated submucosal esophageal veins.

**Mechanism:** Occur in association with cirrhosis of the liver and portal hypertension. The esophageal veins represent an alternative path for bloodflow on its return to the heart, which occurs in patients with cirrhosis. Increased flow through the vessels results in vessel dilation.

**Complications of esophageal varices:** Gastrointestinal bleeding.

**Gross morphology:** Dilated veins within the submucosa of the distal esophagus (Figure 14-3).

**Clinical presentation of esophageal varices:** Hematemesis; melena (black, tarry stool).

### ESOPHAGITIS AND RELATED CONDITIONS

**Overview:** Reflux esophagitis, infectious and noninfectious esophagitis, and Barrett esophagus, an important complication of long-term reflux, are discussed in this section.

#### REFLUX ESOPHAGITIS (GASTROESOPHAGEAL REFLUX DISEASE, OR GERD)

**Basic description:** Inflammation of the esophageal mucosa as a result of reflux of the stomach contents.

##### Mechanisms of GERD

- Increased gastric volume.
- Impaired regenerative capacity of esophageal mucosa and decreased function of antireflux mechanisms.
- Delayed esophageal clearance.

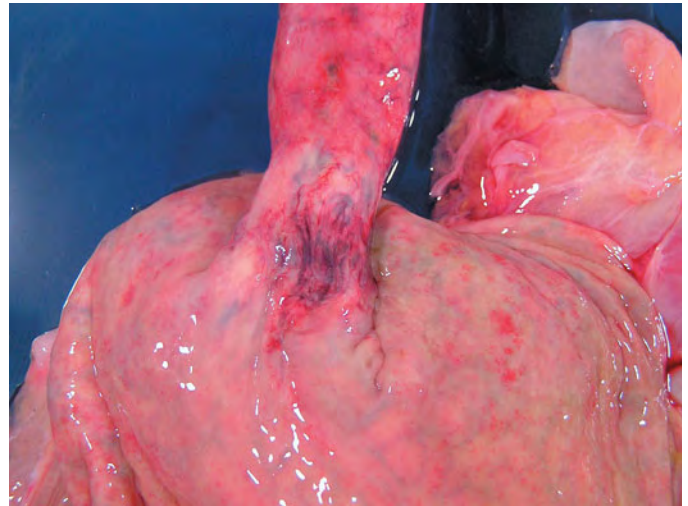**Specific causes of GERD:** Alcohol use, central nervous system depressants, hypothyroidism; possibly hiatal hernia with the potential mechanism of removal of the added constriction of the diaphragmatic crura.

##### Complications of GERD

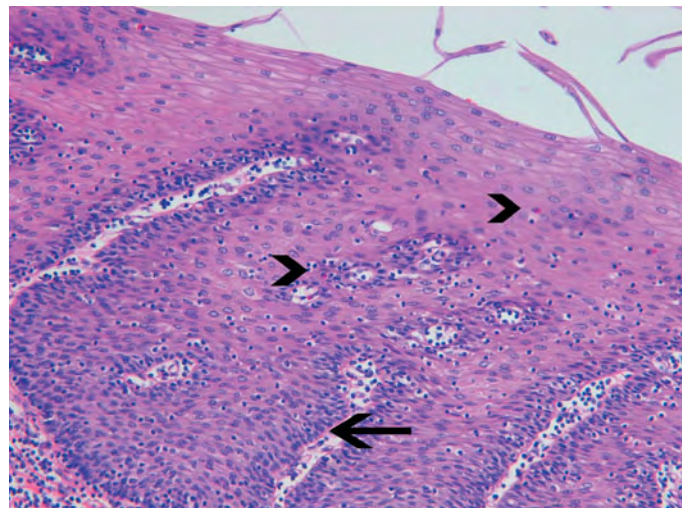
- Bleeding.
- Stricture formation.
- Ulcer.
- Barrett esophagus (i.e., glandular metaplasia), with resultant risk of adenocarcinoma (see esophageal neoplasms, below).

**Microscopic morphology of GERD:** Eosinophils, basal zone hyperplasia, and elongation of the lamina propria papilla (Figure 14-4).

**Clinical presentation of GERD:** Heartburn that occurs after meals or when the patient is supine. The heartburn may be accompanied by a bitter taste or excessive salivation (i.e., **water brash**) due to a vagal reflex induced by acid in the esophagus. Often, a chronic nonproductive cough is the only symptom of gastroesophageal reflux.



**Figure 14-3.** Esophageal varices. Multiple prominently dilated esophageal veins are at the gastroesophageal junction. Esophageal varices are a complication of cirrhosis and can be the cause of upper gastrointestinal bleeding.



**Figure 14-4.** Reflux esophagitis. Gastric reflux produces changes in the esophageal mucosa, notably basal cell hyperplasia (arrow) and an eosinophilic infiltrate (arrowheads). Hematoxylin and eosin, 200 $\times$ .

### Other causes of esophagitis

- Prolonged gastric intubation, uremia, ingestion of corrosive substances, radiation.
- Nonbacterial causes of esophagitis: Most common causes are infection caused by cytomegalovirus (CMV), herpes simplex virus (HSV), or *Candida albicans*, and all are associated with patients who are debilitated and have decreased immune function (Figures 14-5 and 14-6).
- **Gross morphology:** CMV has linear ulcers, HSV has punched out ulcers, and *Candida* has a white plaque.
- **Clinical presentation:** Dysphagia and odynophagia.

### BARRETT ESOPHAGUS

**Basic description:** Glandular metaplasia that occurs in the distal esophagus as a result of chronic reflux of gastric acid into the esophagus.

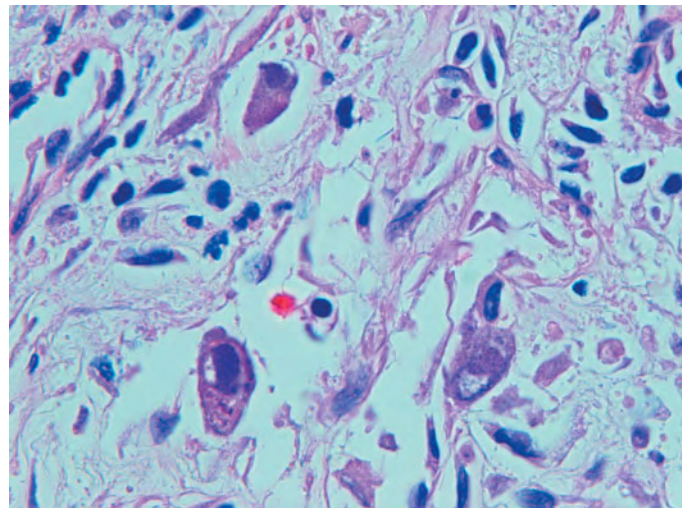
**Pathogenesis:** The normal squamous cell lining of the esophagus cannot handle gastric acid, so the epithelium converts to glandular epithelium (metaplasia). If the cause of the reflux is removed, the metaplasia will regress. If the reflux continues, metaplasia can lead to dysplasia, which leads to carcinoma.

### Complications of Barrett esophagus

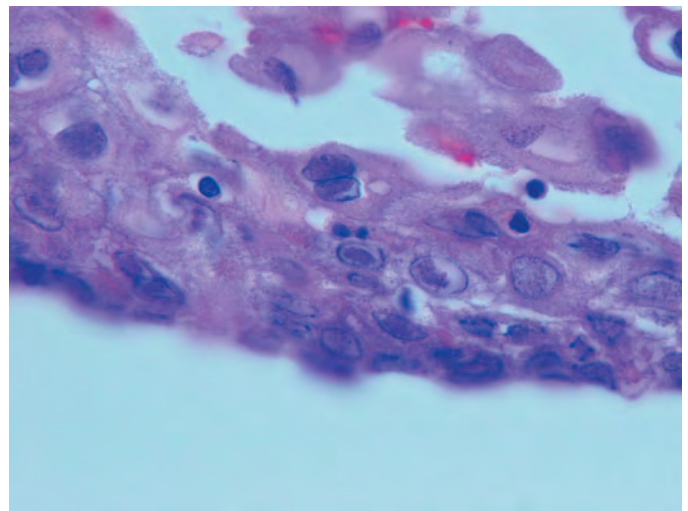
- Ulcer and stricture.
- Esophageal adenocarcinoma: Patients with Barrett esophagus have 30–40 times greater risk than the normal population for the development of esophageal adenocarcinoma. The lifetime risk is 10%.
- Treatment of reflux does not induce regression of Barrett esophagus, and has not been demonstrated to reduce subsequent risk of developing adenocarcinoma.

### Morphology of Barrett esophagus (Figure 14-7 A and B)

- **Gross:** Velvety, gastric-type mucosa above the gastroesophageal junction.
- **Microscopic:** Columnar glandular epithelium with goblet cells.



**Figure 14-5.** Cytomegalovirus (CMV) esophagitis. CMV is one of the three common nonbacterial infectious causes of esophagitis, usually occurring in patients who are immunosuppressed. Three enlarged cells that have intranuclear inclusions, with a clear peripheral halo, are present in this photomicrograph. Hematoxylin and eosin, 400×.



**Figure 14-6.** Herpes simplex virus (HSV) esophagitis. HSV is one of the three common nonbacterial infectious causes of esophagitis, usually occurring in patients who are immunosuppressed. These esophageal squamous cells are not enlarged; however, the nuclei have intranuclear inclusions, with a clear halo. These represent Cowdry type A HSV inclusions. Hematoxylin and eosin, 1000×.



## OTHER NON-NEOPLASTIC LESIONS OF THE ESOPHAGUS

**Overview:** Although the common non-neoplastic disorders of the esophagus have been discussed above, four more conditions worthy of brief mention are esophageal webs, esophageal rings, true diverticula, and esophageal stenosis.

### Esophageal webs

**Pathogenesis:** Esophageal webs form as a result of reflux or they may be congenital.

### Important associated condition: Plummer-Vinson syndrome

- Tetrad of esophageal webs, iron deficiency anemia, glossitis, and cheilosis.
- Patients are at risk for squamous cell carcinoma.

**Esophageal rings:** Two types, A and B.

**Location:** A rings are located above the squamocolumnar junction; B rings (also called **Schatzki ring**) are located at the squamocolumnar junction.

**Clinical presentation of webs and rings:** Intermittent dysphagia.

### True diverticula

#### Types of true diverticula

- **Zenker diverticulum:** Location is the proximal esophagus.
- **Traction diverticulum:** Location is the mid esophagus.
- **Epiphrenic diverticulum:** Location is near the gastroesophageal junction.

**Esophageal stenosis:** Causes include gastric reflux, radiation, caustic ingestion, and scleroderma.

## ESOPHAGEAL NEOPLASMS

**Overview:** The two main types of esophageal neoplasms are squamous cell carcinoma and adenocarcinoma.

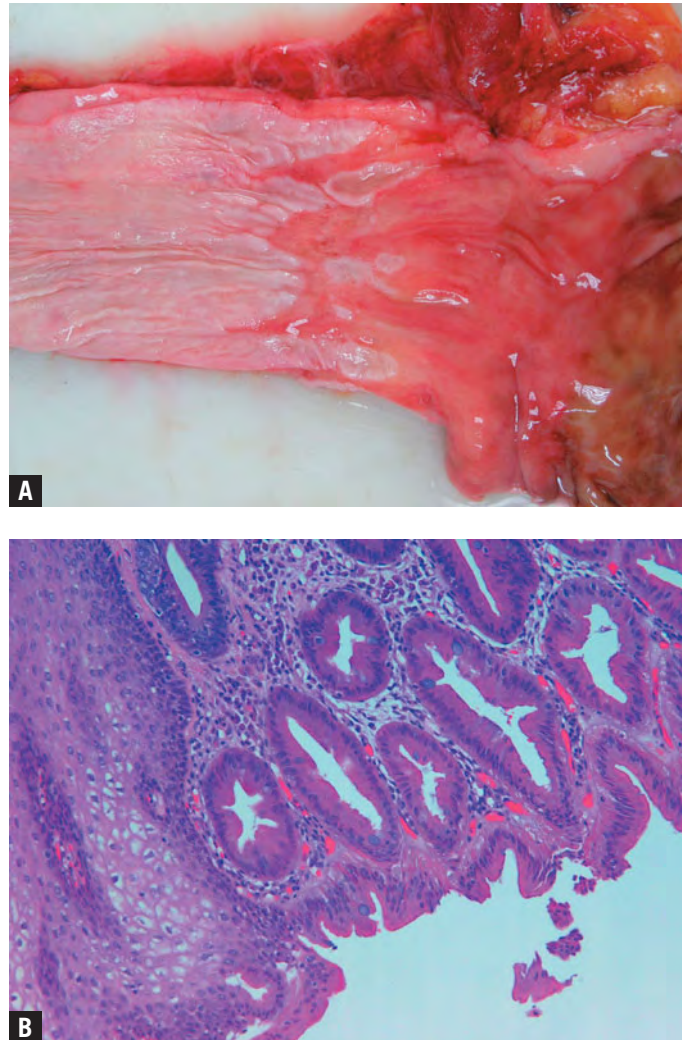
### SQUAMOUS CELL CARCINOMA

**Epidemiology:** Squamous cell carcinoma is the most common type of carcinoma of the esophagus worldwide, and in the United States, its incidence equals that of adenocarcinoma. Predominance of male to female in a ratio of 2:1; African Americans have a higher risk than whites.

**Location:** Anywhere along the length of the esophagus.

#### Risk factors

- Smoking and alcohol use.
- Dysphagia due to esophagitis or achalasia, which increases exposure of mucosa to toxins.
- Plummer-Vinson syndrome.
- Deficiency of vitamin A.



**Figure 14-7.** Barrett esophagus. **A**, The pale smooth tan-white lining of this opened esophagus (left side of image) is interrupted above the gastroesophageal junction by multiple tongues of glistening red-tan gastric-like mucosa. **B**, The characteristic intestinal-type metaplasia of Barrett esophagus. The squamous epithelium of the normal esophagus is present in the left lower quadrant, and the remainder of the image shows glandular-type epithelium, with a prominent number of goblet cells. Hematoxylin and eosin, 200 $\times$ .



### Features of squamous cell carcinoma of the esophagus

#### ■ Metastases

- Squamous cell carcinoma in the upper third of the esophagus spreads to the cervical lymph nodes.
- Squamous cell carcinoma in the middle third of the esophagus spreads to the mediastinal, paratracheal, and tracheobronchial nodes.
- Squamous cell carcinoma in the lower third of the esophagus spreads to the gastric and celiac lymph nodes.

■ **Mutations:** Mutations of *p53* occur in 50% of tumors. Mutations of *p16INK-4*. *K-ras* mutations are rare.

### ADENOCARCINOMA

**Epidemiology:** Predominance in males; whites more commonly affected than African Americans.

**Locations:** Occurs almost exclusively in association with Barrett esophagus (therefore, in the distal esophagus). Rarely, submucosal esophageal glands may give rise to an adenocarcinoma.

### MORPHOLOGY OF ESOPHAGEAL NEOPLASMS

**Gross:** Both squamous cell carcinoma and adenocarcinoma can be polypoid, ulcerative, or flat (i.e., diffuse).

#### Microscopic

- Squamous cell carcinoma: Keratin pearls, intercellular bridges.
- Adenocarcinoma: Invasive glandular structures.

#### Clinical presentation of esophageal neoplasms

- **Symptoms:** Progressive dysphagia (i.e., to solid foods first then liquid), odynophagia (i.e., burning sensation while swallowing), and weight loss.
- **Diagnosis:** Endoscopic biopsy.
- **Prognosis for esophageal carcinoma:** By the time symptoms present, most tumors are incurable. There is no significant difference between survival rates for squamous cell carcinoma and adenocarcinoma.

## GASTRITIS

**Overview:** The two types of gastritis are acute gastritis and chronic gastritis.

### ACUTE GASTRITIS

**Basic description:** Infiltration of edematous gastric mucosa predominantly by neutrophils.

#### Causes of acute gastritis

- Aspirin and nonsteroidal anti-inflammatory drugs (NSAIDs) cause decreased prostaglandin production, which leads to decreased mucus production, impaired blood flow, and decreased secretion of bicarbonate, all of which predispose to epithelial injury.

- Smoking and alcohol.
- Severe physiologic stress (e.g., burns, trauma) and shock. Evidence of some degree of mucosal bleeding can be found in 80–90% of all critically ill, hospitalized patients.
- Uremia.

#### Pathogenesis of acute gastritis

- Disruption of mucous layer.
- Stimulation of acid secretion and decreased production of bicarbonate.
- Direct damage to the epithelium.

#### Complications of acute gastritis

- Gastrointestinal bleeding.
- Perforation of the stomach wall.

#### Morphology of acute gastritis

- **Gross:** A spectrum from petechial hemorrhages to superficial ulcers.
- **Microscopic:** Neutrophils in the interstitium and within glands (Figure 14-8).

#### Clinical presentation of acute gastritis

- **Symptoms:** Dyspepsia, mid epigastric pain.
- **Signs:** Blood in the nasogastric tube; “coffee ground” emesis.
- **Diagnosis:** Endoscopy.

### CHRONIC GASTRITIS

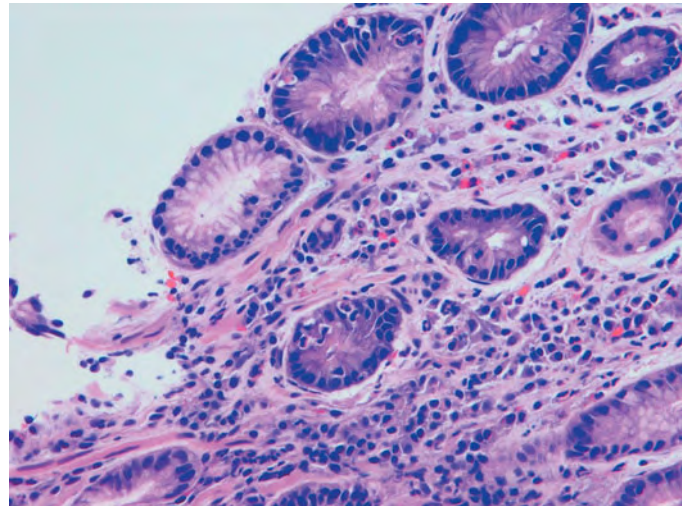
**Basic description:** Infiltration of gastric mucosa with chronic inflammatory cells (e.g., lymphocytes), with associated mucosal atrophy and intestinal metaplasia. There are two main types of chronic gastritis: type A (i.e., fundal), with an autoimmune etiology; and type B (i.e., antral), caused by *Helicobacter pylori* infection.

#### 1. *Helicobacter pylori* infection

##### Mechanisms by which *H pylori* damages gastric mucosa

- Induction of interleukin-8 (IL-8), which recruits neutrophils.
- Production of urease, which cleaves urea to ammonia and carbon dioxide, creating a buffer against the hydrochloric acid (HCl).
- Enhancement of gastric acid secretion and impairment of duodenal bicarbonate production.
- Adheres to surface epithelial cells and secretes phospholipases and proteases.
- Production of VacA, which is a passive urea transporter that causes cell injury (i.e., vacuolization); VacA requires the presence of the *CagA* gene.

**Important point:** Infection due to *H pylori* does not cause as extensive a loss of parietal cells as autoimmune gastritis does; therefore, achlorhydria is *NOT* a feature.



**Figure 14-8.** Acute gastritis. The gastric mucosa is infiltrated by inflammatory cells, including a prominent number of neutrophils. Some of the neutrophils are present in the epithelium lining the gland in the center of the image. Hematoxylin and eosin, 400×.

### Testing for *H pylori*

- **Noninvasive testing:** Serology, urea breath test, stool antigen test.
- **Invasive testing:** Biopsy urease test, culture, histology.

### 2. Autoimmune gastritis (also known as **atrophic gastritis or pernicious anemia**)

**Mechanism of autoimmune gastritis:** Autoimmune disorder with antibodies to parietal cells, resulting in decreased gastric acid secretion and decreased intrinsic factor production.

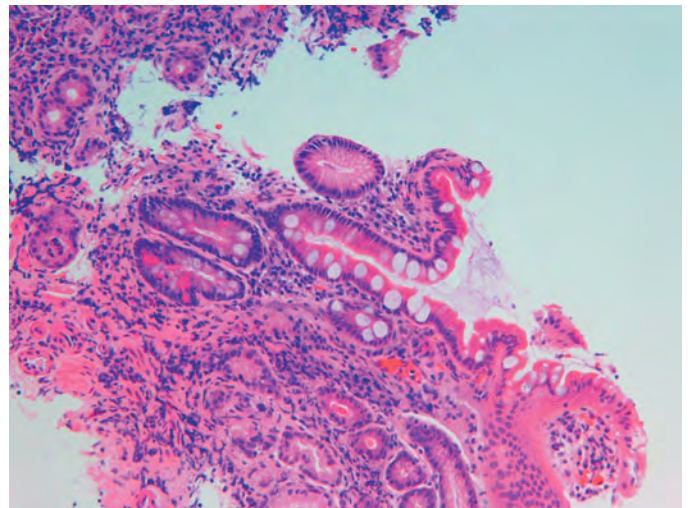
#### Associated conditions

- **Megaloblastic anemia** due to decreased production of intrinsic factor, resulting in vitamin B<sub>12</sub> deficiency. The vitamin B<sub>12</sub> deficiency causes megaloblastic anemia and neurologic defects.
- **Other autoimmune disorders:** Includes Hashimoto thyroiditis.

**Other causes of chronic gastritis:** Alcohol use, smoking, radiation, amyloidosis.

#### Complications of chronic gastritis

- With autoimmune gastritis: Hypochlorhydria, achlorhydria, hypergastrinemia.
- Peptic ulcer disease, as a result of hypergastrinemia.
- Chronic gastritis can lead to intestinal metaplasia (Figure 14-9), which can lead to gastric carcinoma.



**Figure 14-9.** Intestinal metaplasia. As a complication of chronic gastritis, the stomach can develop intestinal metaplasia. In this photomicrograph of the stomach, note the intestinal-type epithelium, with a prominent number of goblet cells. Intestinal metaplasia can be an early precursor lesion for gastric adenocarcinoma. Hematoxylin and eosin, 200×.

## PEPTIC ULCER DISEASE

**Overview:** A **peptic ulcer** is a defect in the mucosal surface of the stomach or duodenum that extends through the muscularis mucosa into the submucosa or into deeper layers. An **erosion** is just a mucosal defect, with no penetration of the muscularis mucosa (Figure 14-10 A, B, C).

**Epidemiology:** Approximately 70% of ulcers occur in patients between the ages of 25 and 64 years.

#### Mechanisms of peptic ulcer formation

- Mucosal exposure to gastric acid and pepsin.
- Most are associated with *H pylori* infection (virtually all duodenal ulcers and 70% of gastric ulcers). NSAIDs are the second most common cause of gastric peptic ulcers. Smoking increases the risk for peptic ulcer disease.
- Peptic ulcers arise from an imbalance between the forces protecting the gastric or duodenal mucosa and those trying to damage the mucosa. In many patients, acid secretion is normal.

**Risk factors** (see acute and chronic gastritis above): In the stomach, 70% of peptic ulcers are associated with *H pylori* infection. In the duodenum, almost 100% of peptic ulcers are associated with *H pylori* infection. In the stomach, peptic ulcers are also associated with other causes of gastritis, including aspirin and NSAID use.



### Complications of peptic ulcer disease

- Hemorrhage into the gastrointestinal tract in 15–20% of cases.
- Perforation causing peritoneal hemorrhage or peritonitis in 5% of cases.
- Obstruction in 2% of cases.
- Malignant transformation is very rare.

### Important associated condition: Zollinger-Ellison syndrome

- **Cause:** Gastrin-secreting tumor.
- **Location of tumor:** “Gastrinoma triangle” (i.e., at the second and third portions of the duodenum, junction of the head and neck of the pancreas, and cystic duct).
- Approximately 75% of tumors are sporadic; 25% are a component of multiple endocrine neoplasia type 1 (MEN 1) syndrome.
- Suspect Zollinger-Ellison syndrome in patients with recurrent peptic ulcers without *H pylori* infection or NSAID use; or in patients with multiple duodenal ulcers; or in patients with ulcers in unusual locations (e.g., jejunum).

### Morphology of peptic ulcer disease

- **Gross:** Punched out ulcer (i.e., edges are not piled up) (see gastric neoplasms below).
- **Microscopic:** The four levels of an ulcer recapitulate the stages of acute inflammation to chronic inflammation and fibrosis. Fibrin is the most superficial layer, followed by neutrophils, granulation tissue, and, the deepest layer, fibrosis.

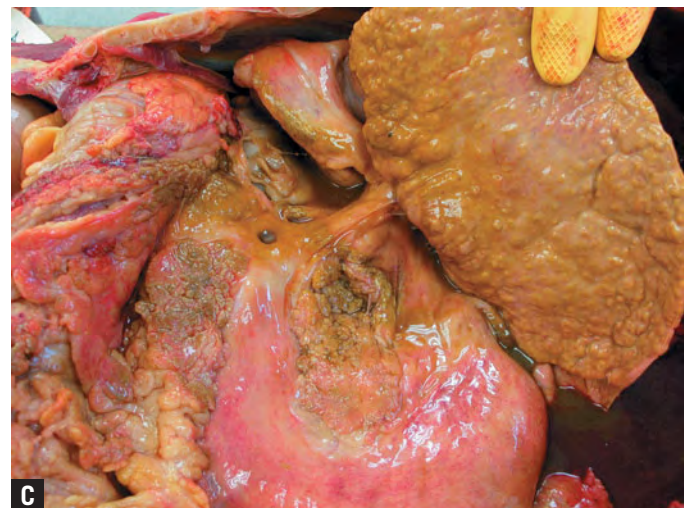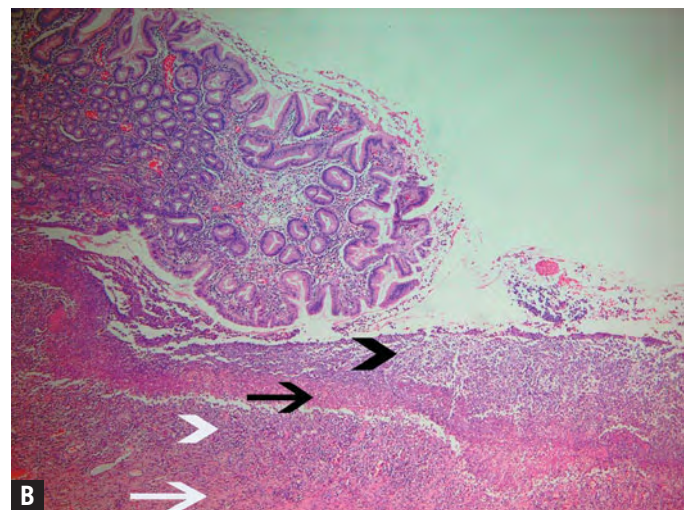
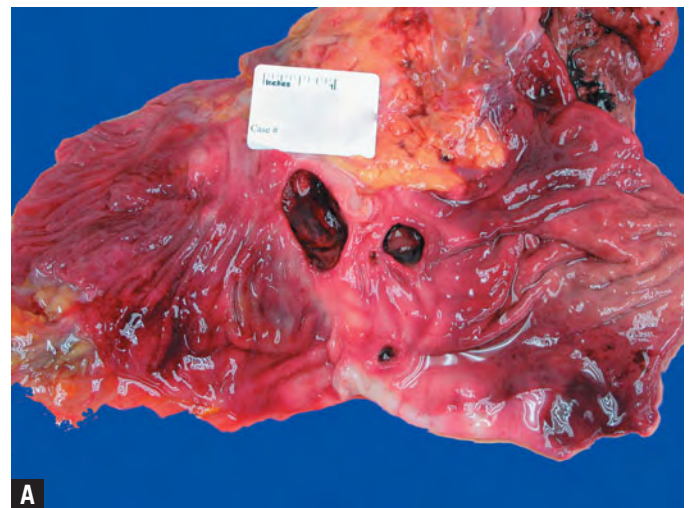
### Clinical presentation of peptic ulcer disease

- **Symptoms:** Chronic, gnawing epigastric pain and tenderness with radiation to the back; bleeding (melena or “coffee ground” hematemesis). Timing of pain in relation to food consumption is not reliable. If there is perforation of the ulcer, patients will have abrupt abdominal pain and a rigid abdomen upon physical examination (peritoneal signs).
- **Diagnosis:** Endoscopy and biopsy to rule out a gastric carcinoma.

## ACUTE GASTRIC ULCERS

**Causes:** NSAIDs, severe stress (referred to as **Cushing ulcers**), and burns (referred to as **Curling ulcers**).

**Pathogenesis:** In head trauma, increased intracranial pressure produces increased vagal stimulation, which results in excess gastric acid production. In shock and sepsis, decreased mucosal perfusion, ischemia, and reperfusion play a prominent role in the development of the ulcer. In normal gastric mucosa, nitric oxide promotes blood flow and perfusion. Hypoperfusion causes the production of greater than physiologic amounts of nitric oxide, resulting in reperfusion injury and cell death.



**Figure 14-10.** Peptic ulcers. **A**, The stomach is opened and laid flat, revealing several large punched-out gastric ulcers. **B**, A cross-section of a peptic ulcer, illustrating the four layers: fibrin (black arrowhead), neutrophils (black arrow), granulation tissue (white arrowhead), and fibrosis (white arrow). **C**, A duodenal peptic ulcer that has perforated the wall, producing peritonitis. The liver is cirrhotic (an incidental finding unrelated to the duodenal peptic ulcer). **A**, Courtesy of Dr. Jill Urban, Dallas County Medical Examiner's Office, Dallas, TX. **B**, Hematoxylin and eosin, 200 $\times$ .

## GASTRIC NEOPLASMS

**Overview:** The majority of gastric neoplasms are adenocarcinomas of intestinal and diffuse types. Mesenchymal tumors (e.g., gastrointestinal stromal tumors) are much less common. Gastric polyps, adenocarcinoma, and gastrointestinal stromal tumors are discussed below.

### GASTRIC POLYPS

**Basic description:** Nodule or mass projecting above the surface of the mucosa.

**Types:** **Hyperplastic** (90%), **fundic gland** (rare), and **adenomatous** (10%).

### ADENOCARCINOMA

**Two classification schemes:** Lauren classification includes intestinal and diffuse types, and World Health Organization (WHO) classification includes papillary, tubular, mucinous, signet-ring cell (if > 50% of tumor), undifferentiated, and adenosquamous types.

#### 1. Intestinal-type adenocarcinoma (Figure 14-11)

**Epidemiology:** Predominance in males; older than 50 years of age.

**Mechanism of formation:** Tumors arise from a precursor lesion (e.g., from intestinal metaplasia occurring in the background of chronic gastritis).

#### Risk factors

- Nitrites; smoked and salted food.
- Cigarette smoke.
- Chronic gastritis with intestinal metaplasia.

#### Important point regarding intestinal-type adenocarcinoma:

Depth of invasion into the wall of the stomach is vital to staging. Early gastric carcinoma invades no deeper than the submucosa. Late gastric adenocarcinoma has invaded into the muscular wall.

#### Morphology of intestinal-type adenocarcinoma

##### ■ Gross

- Ulcer with heaped up margins.
- Polypoid projection.
- Flat or depressed.

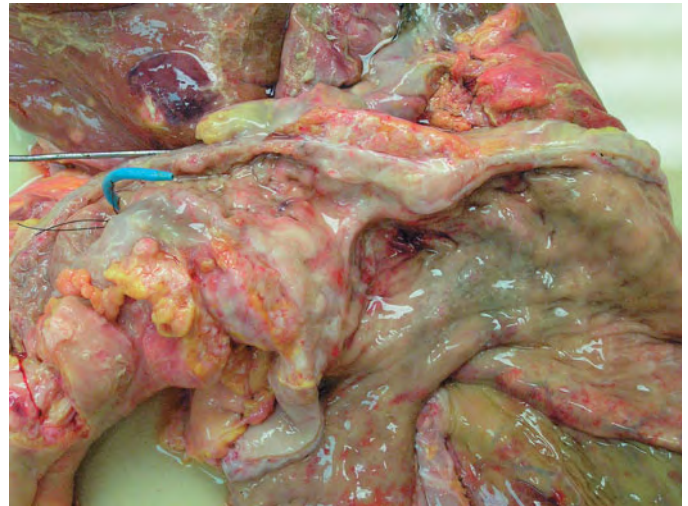
■ **Microscopic:** Neoplastic and invasive intestinal-type epithelium.

#### 2. Diffuse (signet-ring cell) type adenocarcinoma

**Epidemiology:** No male-female predominance; patients usually present younger than 50 years of age.

**Mechanism of formation:** No precursor lesion; signet ring cell tumors do not arise from intestinal metaplasia.

**Risk factors:** Unknown.



**Figure 14-11.** Gastric adenocarcinoma, intestinal-type. The opened stomach is to the right of the image, and the opened duodenum is at the left side. The blue plastic tube is a stent in the ampulla of Vater. Centered at the pylorus is an ulcerated gastric adenocarcinoma. Note the tan-yellow discoloration and focal thickening of the surrounding infiltrated gastric wall.



**Morphology of diffuse-type adenocarcinoma** (Figure 14-12 A and B)

- **Gross:** Diffuse thickening of mucosa with no well-defined mass. Thickening of the stomach wall (referred to as **linitis plastica**).
- **Microscopic:** Signet-ring cells (i.e., eccentric nucleus with vacuole).

**Components used to categorize gastric carcinomas:** The three features used to describe and categorize gastric carcinomas are depth of invasion, macroscopic appearance, and histology.

- **Depth of invasion:** **Early gastric carcinoma** involves the mucosa and submucosa; **late gastric carcinoma** has infiltrated into the muscularis propria.
- **Macroscopic appearance:** Exophytic, flat, or excavated.
- **Histology (intestinal-type or diffuse).**

**Important points regarding gastric carcinomas**

- **Virchow node:** Metastasis to supraclavicular lymph node.
- **Sister Mary Joseph nodule:** Metastatic periumbilical nodule.

**Clinical presentation of gastric carcinoma:** Abdominal discomfort, early satiety, and nausea and vomiting; gastrointestinal hemorrhage.

### GASTROINTESTINAL STROMAL TUMOR

**Basic description:** Sarcoma of the stomach.

**Important points**

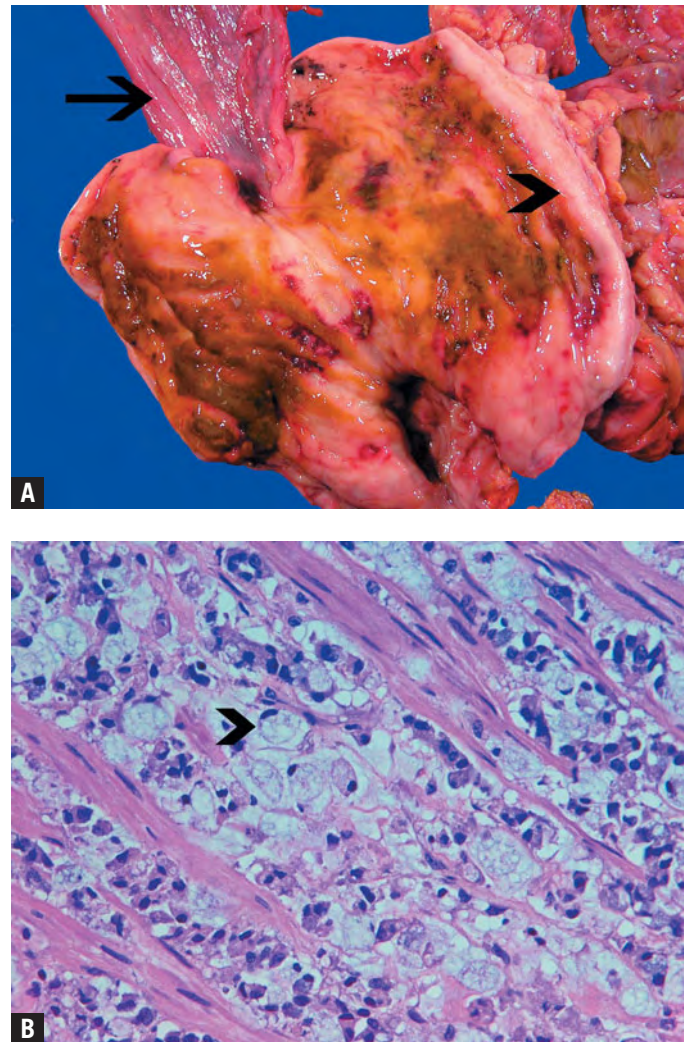
- Derived from interstitial cells of Cajal.
- CD117+ (*c-kit*).

### CONSTIPATION AND DIARRHEA

**Overview:** **Constipation, diarrhea, and dysentery** are common symptoms of small and large intestinal pathology. Constipation may be acute or chronic. Causes of acute constipation include bowel obstruction and **ileus** (due to trauma or peritoneal irritation). Causes of chronic constipation include neurologic disorders (e.g., inflammatory bowel disease, Hirschsprung disease), electrolyte disturbances (e.g., hyperglycemia, hypercalcemia), and psychological states. Diarrhea and dysentery are different conditions. Diarrhea is an increase in stool mass, frequency, or fluidity. Stool weight exceeds 200 grams within a 24-hour period. Dysentery is low volume and painful and bloody diarrhea, often due to infectious organisms such as *Escherichia coli* and *Shigella*. Classification of diarrhea is based upon one of five mechanisms as secretory, osmotic, exudative, malabsorption, and altered motility forms.

### MECHANISMS OF DIARRHEA (TABLE 14-3)

**Secretory diarrhea:** Isotonic fluid secretion that persists with fasting. Something such as viral damage of the epithelium, a bacterial toxin, or protein produced by a tumor causes the bowel to secrete liquid.



**Figure 14-12.** Gastric adenocarcinoma, signet-ring cell type. **A**, The specimen is an opened stomach with attached esophagus. The gastroesophageal junction is indicated by the arrow. Note that the mucosa of the stomach has no ulcer or polypoid mass; however, the wall of the stomach is diffusely thickened (arrowhead), a condition called linitis plastica. **B**, A high-power view of the neoplasm. Note the characteristic signet-ring cell appearance of the neoplastic cells (arrowhead). Hematoxylin and eosin, 400 $\times$ .

**TABLE 14-3.** Mechanisms of Diarrhea

Mechanism	Causes
Secretory	Rotavirus, <i>Vibrio cholerae</i> , <i>Giardia lamblia</i>
Osmotic	Disaccharidase deficiency, lactulose therapy
Exudative	<i>Shigella</i> , <i>Salmonella</i> , IBD
Malabsorption	Celiac sprue, IBD
Altered motility	Diabetes mellitus, hyperthyroidism

IBD, inflammatory bowel disease.



### Causes

- **Viral:** Rotavirus, Norwalk virus, Enteric adenoviruses.
- **Bacterial:** *Vibrio cholerae*, *Bacillus cereus*, or *Clostridium perfringens* due to toxin production.
- **Parasitic:** *Giardia lamblia* (Figure 14-13).

**Morphology of secretory diarrhea:** Nonspecific as to etiologic agent. The diarrhea is caused by viral damage of the epithelium or a bacterial toxin, so the gross and histologic changes may be minimal (e.g., edema, mild inflammatory infiltrate).

**Complications:** Metabolic acidosis; dehydration.

**Clinical presentation of secretory diarrhea:** High output ( $> 1$  L per day), persistence of diarrhea during fasting, and minimal stool osmotic gap ( $< 50$  mOsm).

**Osmotic diarrhea:** Solutes in the bowel (e.g., disaccharidase deficiency or lactulose therapy) draw fluid into the lumen. This form of diarrhea will stop with fasting. Patients have an elevated osmotic gap.

**Exudative diarrhea:** Damage to the epithelial layer through production of cytotoxin or invasion of mucosa; usually caused by bacterial organisms.

### Causes

- **Bacterial:** *Shigella*, *Salmonella*, and *Campylobacter*.
- **Idiopathic inflammatory bowel disease.**

**Morphology of exudative diarrhea:** Nonspecific (as to etiologic agent). However, if the diarrhea is bacterial in origin because the bacteria are invasive, the mucosa may have erosions (i.e., loss of mucosa), ulcers, and severe inflammation.

**Complications:** Dehydration, sepsis, perforation.

**Malabsorption:** Diarrhea due to a defect in digestion (e.g., absence of enzyme or decreased surface area) increases osmolality of luminal contents, thereby drawing water into the bowel.

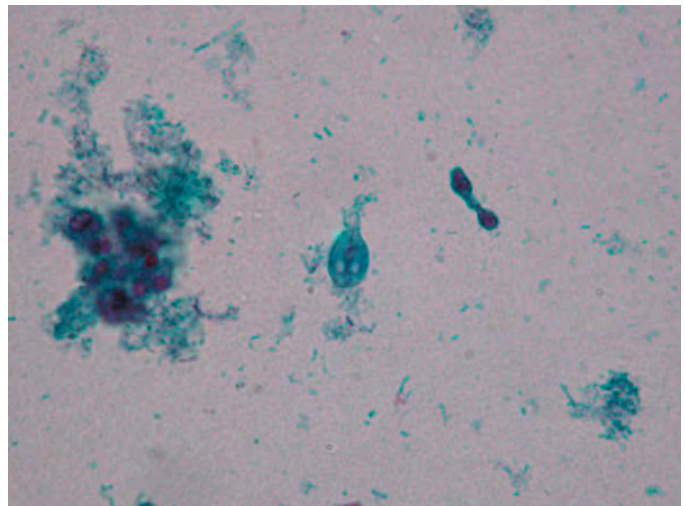
**Altered motility:** Conditions that can cause diarrhea through an alteration of motility include diabetes mellitus (due to neuropathy) and hyperthyroidism.

### Important points regarding diarrhea

- Acute diarrhea ( $< 4$  months in duration) is most likely to be infectious.
- Chronic diarrhea ( $> 4$  months in duration) is most likely noninfectious.
- Large volume diarrhea suggests small bowel or proximal colonic disease.
- Small stools associated with urgency suggest left-sided colon or rectal disease.

### Morphology of bacterial diarrhea

- **Nonspecific changes** (as to determination of etiologic organism): Edema, hyperemia, reactive changes in mucosa, and neutrophilic infiltrate.



**Figure 14-13.** *Giardia lamblia*. Giardiasis is a complication occurring from drinking nonsterilized water from creeks and streams. Infection with *Giardia* produces a watery diarrhea. Courtesy of Dr. Dominick Cavuoti, University of Texas Southwestern Medical Center, Dallas, TX. Wheatley's trichrome, 1000 $\times$ .

### Specific changes

- *Shigella*: Affects the distal colon, causing inflammation, erosions, exudates, and ulcers.
- *Salmonella*: Affects the ileum and colon, causing oval-shaped ulcers along the long axis.

**Specific conditions related to diarrhea: pseudomembranous colitis and *Entamoeba histolytica* infection**

### PSEUDOMEMBRANOUS COLITIS

**Organism:** *Clostridium difficile*.

**Pathogenesis:** *C difficile* is a normal inhabitant of the gut flora of many patients; however, antibiotic use can kill the normal flora and allow the proliferation of *C difficile*. *C difficile* produces a toxin that mediates its effects on the gastrointestinal tract.

#### Morphology of pseudomembranous colitis

- **Gross:** Thin layer of fibrinopurulent debris (i.e., **pseudomembrane**) on the mucosa surface (Figure 14-14).
- **Microscopic:** Pseudomembranes are composed of necrotic epithelial cells, inflammatory cells, and fibrin.

#### Clinical presentation of pseudomembranous colitis

- **Symptoms:** Onset is usually more than 1 week after initiation of antibiotic therapy. Cramping abdominal pain, fever, leukocytosis, and green or bloody, foul-smelling diarrhea.
- **Diagnosis:** *C difficile* antigen in the stool or by endoscopy and biopsy.

**Other causes of pseudomembranes:** Ischemia; *Staphylococcus* and *Shigella* infections.

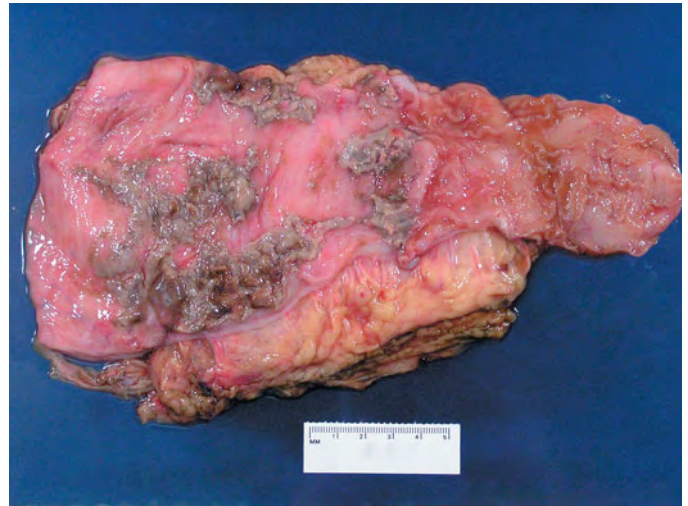### ENTAMOEBIA HISTOLYTICA INFECTION

**Mechanism:** Amoebae invade the crypts and into the submucosa.

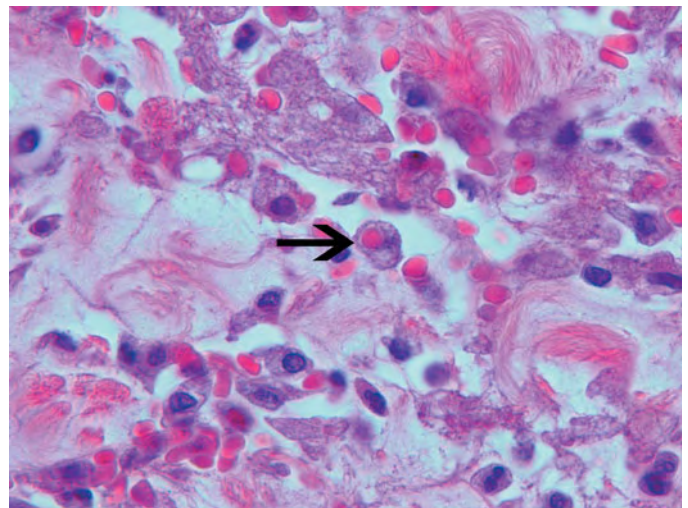
**Complications:** *Entamoeba histolytica* can invade the portal vessels and embolize to the liver, lung, kidneys, heart, and brain.

#### Morphology of *Entamoeba histolytica* infection

- **Gross:** “Flask-shaped ulcer” in the colon; “anchovy paste”-like mass in the liver.
- **Microscopic:** Amoebae with engulfed red blood cells (Figure 14-15).



**Figure 14-14.** Pseudomembranous colitis. Note the adherent green-tan membranes focally present on the mucosa of this opened colon.



**Figure 14-15.** *Entamoeba histolytica*. This patient has colonic amebiasis. Although some *Entamoeba* species are nonpathogenic, the engulfment of red blood cells (arrow) by this amoeba confirms that it is pathogenic. Hematoxylin and eosin, 400×.

## MALABSORPTION

**Overview:** Malabsorption is due to failed absorption of nutrients by the small and large intestine. The mechanisms of malabsorption, clinical presentation of malabsorption, laboratory studies used in the evaluation of steatorrhea, and four of the common conditions causing malabsorption—celiac sprue, disaccharidase deficiency, inflammatory bowel disease, and Whipple disease—are discussed below.

### Mechanisms of malabsorption (Table 14-4)

- Impaired intraluminal digestion due to absence or deficiency of required enzymes or bile salts; causes include pancreatic insufficiency and defective bile secretion.
- Primary mucosal cell abnormalities; causes include lactose intolerance due to disaccharidase deficiency, and bacterial overgrowth.
- Reduced surface area; causes include celiac sprue, Crohn disease, and surgical resection of a segment of the small intestine.
- Obstruction of lymphatics; causes include lymphoma and tuberculosis.
- Infection; causes include enterocolitis (i.e., bacterial infection) and parasitic infections.

### Clinical presentation of malabsorption

- Nonspecific (as to etiologic agent): Change in bowel habits (e.g., diarrhea) and weight loss; later, nutritional symptoms.
- Bulky, oily stool indicates **steatorrhea** from fat malabsorption.
- Bloating and soft diarrheal movements are due to carbohydrate malabsorption.

## STUDIES USED IN THE EVALUATION OF STEATORRHEA

1. **Fecal fat analysis:** A positive Sudan black stain of stool indicates moderate to severe steatorrhea. If fecal fat analysis indicates an abnormality, then D-xylose testing is performed.
2. **D-xylose test:** D-xylose is transported by passive diffusion. The presence of D-xylose in urine indicates adequate intestinal transport and surface area. If the D-xylose test is abnormal, the cause is intestinal disease and a biopsy is warranted. If the D-xylose test is normal, measurement of the pancreatic enzymes, the Schilling test, breath tests, and small intestinal biopsy are performed as indicated.
3. **Measurement of pancreatic enzymes (trypsinogen, chymotrypsin).**
4. **Schilling test for vitamin B<sub>12</sub> deficiency**
  - Stage 1: Give radioactive vitamin B<sub>12</sub>; a reduced amount of vitamin B<sub>12</sub> in urine suggests malabsorption with no specific diagnosis.
  - Stage 2: Add oral intrinsic factor; if the reduced amount of vitamin B<sub>12</sub> is corrected, the testing has confirmed the diagnosis is pernicious anemia.

**TABLE 14-4.** Mechanisms of Malabsorption

Mechanism	Causes
Impaired intraluminal digestion	Pancreatic insufficiency, defective bile secretion
Primary mucosal cell abnormality	Lactose intolerance, bacterial overgrowth
Reduced surface area	Celiac sprue, IBD
Obstruction of lymphatics	Lymphoma, tuberculosis
Infections	Enterocolitis, parasitic infection

IBD, inflammatory bowel disease



- Stage 3: Add antibiotics; if the reduced amount of vitamin B<sub>12</sub> is corrected, the testing has confirmed the diagnosis is bacterial overgrowth.
- Stage 4: Add pancreatic enzymes; if the reduced amount of vitamin B<sub>12</sub> is corrected, the testing has confirmed the diagnosis is pancreatic insufficiency.

5. **Small intestinal biopsy:** Important for processes that affect the cellular phase of digestion.

**Specific causes of malabsorption: celiac sprue, disaccharidase deficiency, inflammatory bowel disease, and Whipple disease**

### CELIAC SPRUE

**Epidemiology:** Celiac sprue is most common in whites.

**Pathogenesis of celiac sprue:** Due to hypersensitivity to gluten, a protein found in wheat products.

**Genetics:** Associated with HLA-DQ2 and HLA-DQ8. Laboratory testing shows the presence of anti-gliadin, anti-tissue transglutaminase, and anti-endomysial antibodies in patients.

**Complications of celiac sprue**

- Diarrhea.
- Increased risk for development of intestinal (T-cell) lymphomas.
- Associated with development of small intestinal adenocarcinoma and squamous cell carcinoma of the esophagus.

**Differential diagnosis of celiac sprue versus tropical sprue**

- **Pathogenesis of tropical sprue:** Possibly due to overgrowth with *Escherichia coli* or *Haemophilus*.
- Tropical sprue occurs in tropical regions.
- The small intestine is involved throughout its length in tropical sprue.
- Patients with tropical sprue have *no* risk for developing lymphoma.

**Microscopic morphology of celiac sprue:** Small intestinal mucosa with flattened villi, lymphocytic infiltrates, and crypt hyperplasia. Changes are worse in the duodenum and the proximal small intestine.

**Clinical presentation of celiac sprue:** Bloating, chronic diarrhea, and malabsorption. Extraintestinal manifestations are common. Dermatitis herpetiformis, a pruritic papular and vesicular rash on the extensor surface of the forearms, elbows, back, and buttocks is classic.

### DISACCHARIDASE DEFICIENCY (LACTOSE INTOLERANCE)

**Epidemiology:** Found in 90% of Asians and 45% of African Americans; the condition develops after childhood.

Clinical presentation of disaccharidase deficiency

- **Symptoms:** Bloating, flatus, abdominal discomfort.
- **Diagnosis:** Confirmed by the presence of high hydrogen gas levels after the patient is given a test dose of lactose. The hydrogen is a byproduct of bacterial breakdown of the lactose.

INFLAMMATORY BOWEL DISEASE

**Basic description:** Conditions characterized by mucosal (and deeper) damage to the gastrointestinal tract, the etiology of which is uncertain.

**Epidemiology:** Bimodal, two age peaks; one in the second to fourth decades and one about the sixth decade; occurs equally in males and females; whites from northern climates in the United States and Europe.

**Pathogenesis:** Possible dysfunction of immune response toward normal intestinal flora. *NOD2* gene on chromosome 16 plays a role in the development of inflammatory bowel disease.

**Two types of inflammatory bowel disease: ulcerative colitis and Crohn disease.** Ulcerative colitis is confined to the colon, and the inflammation affects only the mucosa. Crohn disease can affect any portion of the gastrointestinal tract, and the inflammation is transmural (Table 14-5).

TABLE 14-5. Comparison and Contrast of Crohn Disease and Ulcerative Colitis

Feature	Crohn Disease	Ulcerative Colitis
Region affected	From mouth to colon	Colon
Location of inflammation	Transmural	Mucosal
Extraintestinal manifestations	Migratory polyarthritis, iritis, uveitis, sclerosing cholangitis	Migratory polyarthritis, iritis, uveitis, sclerosing cholangitis
p-ANCA	11% of cases	75% of cases
Anti- <i>Saccharomyces cerevisiae</i>	Common	Rare
Increased risk of colonic adenocarcinoma (above normal)	5–6x	10–20x
Anatomic features	Fistula formation, skip lesions, creeping fat, cobblestoning of mucosa	Pseudopolyps, crypt abscesses
Submucosal granulomas	Yes	No
Rectal involvement	No	Yes

## CROHN DISEASE

**Location:** Can affect any region of the gastrointestinal tract from mouth to anus. The forms of Crohn disease are based upon the location and include ileocecal (most common form), terminal ileum, colon only, and other sites (rare).

### Theories of pathogenesis of Crohn disease

1. Crohn disease may be an immune response to normal gastrointestinal flora, and there is epithelial barrier malfunction.
2. The NOD2 protein is an intracellular receptor for microbes and triggers NF- $\kappa$ B. The NOD2 protein has decreased function in Crohn disease.
3. T-cell hyperreactivity.

**Extraintestinal associations of Crohn disease:** Migratory polyarthritides (most common), iritis, uveitis, erythema nodosum, primary sclerosing cholangitis, and obstructive uropathy.

### Important points regarding Crohn disease

- p-ANCA is positive in 11% of cases; anti-*Saccharomyces cerevisiae* antibody is common (rare in ulcerative colitis).
- Approximately 30–50% concordance among monozygotic twins.
- Differential diagnosis of lower right quadrant pain and fever: Crohn disease, acute appendicitis, and *Yersinia enterocolitica* infection.

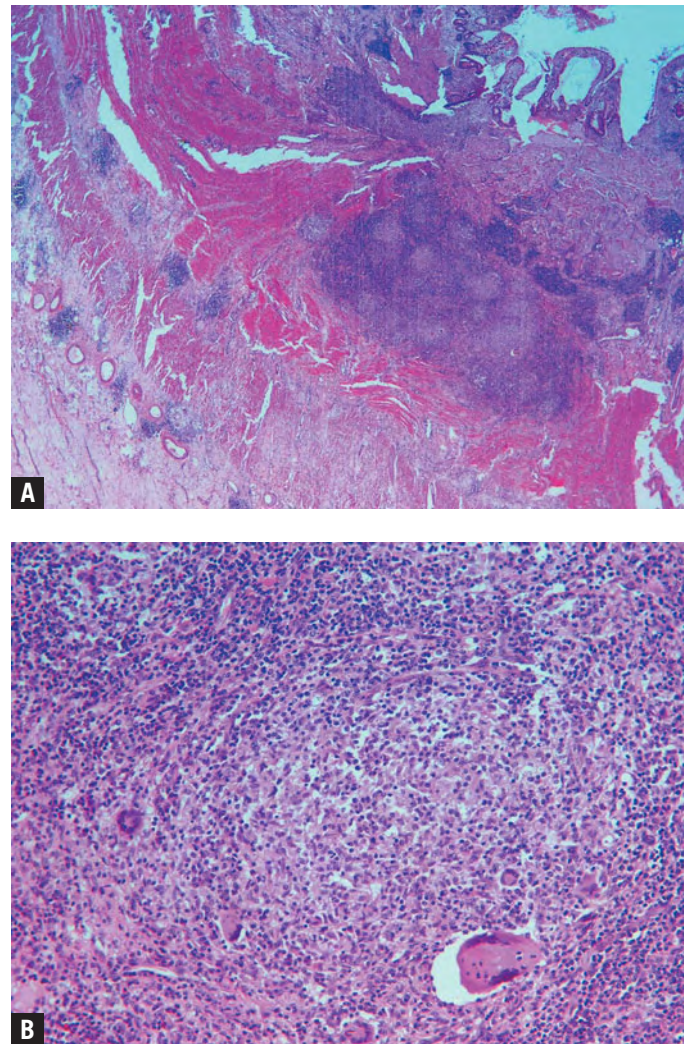
### Complications of Crohn disease

- Risk of colonic adenocarcinoma: 5–6 times higher versus the normal population, which is not as much of an increase as seen in patients with ulcerative colitis.
- Fistula formation.
- Abdominal abscesses, intestinal stricture, and toxic megacolon.
- Extensive ileal mucosal damage, leading to vitamin B<sub>12</sub> deficiency and malabsorption of bile salts.
- Urinary calcium oxalate stones from chronic fat malabsorption, leading to binding of free fatty acids to calcium and allowing oxalate to be absorbed (normally oxalate is excreted bound to the calcium).

### Gross morphology of Crohn disease

- Long, linear, serpentine ulcers and fissures with no rectal involvement.
- Skip lesions: Unaffected bowel mucosa between lesions, with sharp demarcation between normal and abnormal mucosa.
- Fistula formation.
- Mesenteric fat wraps around the bowel (i.e., “creeping fat”).
- Thick wall with stenotic lumen, which is responsible for the “string sign” on barium enema.

**Microscopic morphology of Crohn disease:** Has transmural inflammation, submucosal granulomas, and mural thickening (Figure 14-16 A and B).



**Figure 14-16.** Crohn disease. **A**, Note the transmural nature of the inflammatory infiltrate. Within the muscularis propria and submucosa is a large cluster of lymphocytes associated with multiple granulomas. **B**, A high-power view of one of the granulomas. Hematoxylin and eosin, A, 40 $\times$ ; B, 400 $\times$ .



### Clinical presentation of Crohn disease

- **Symptoms:** Diarrhea, abdominal pain, weight loss, and fever; bloody diarrhea; also associated with psychiatric symptoms.
- **Diagnosis:** Colonoscopy reveals longitudinal ulcerations and cobblestoning; granulomas may be present on biopsy (50%). “String sign” on barium contrast studies. “Creeping fat” on CT scan.

### ULCERATIVE COLITIS

**Location:** Affects only the colon. Ulcerative colitis is divided into four forms: proctitis, proctosigmoiditis, left-sided colitis, and pancolitis. The form of colitis a patient has is important for prognosis.

**Extraintestinal manifestations:** Migratory polyarthritis, uveitis, iritis, erythema nodosum, sclerosing cholangitis, and pyoderma gangrenosum.

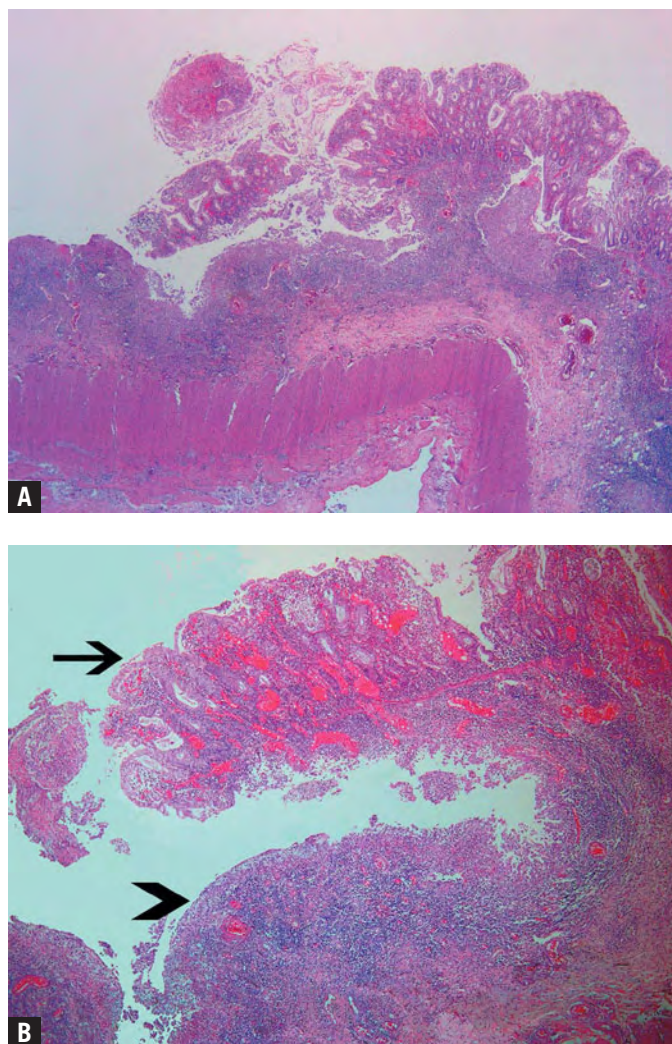
**Important point:** p-ANCA positive in 75% of cases.

### Complications of ulcerative colitis

- Risk of colonic carcinoma: 10–20 times normal risk for carcinoma. Proctitis is not associated with increased risk for carcinoma.
- Hemorrhage with or without resultant anemia; toxic megacolon with possible perforation, and resultant sepsis and death.
- Intestinal stenosis.

### Morphology of ulcerative colitis

- **Gross:** Involvement of only the colon. The involvement is continuous from the rectum. Residual mucosa forms **pseudopolyps**. There is no mural thickening, and there are ulcers but no serpentine ulcers.
- **Microscopic:** Inflammation confined to the mucosa; **crypt abscesses** (i.e., mucosal crypts filled with neutrophils) (Figure 14-17 A and B).



**Figure 14-17.** Ulcerative colitis. **A** and **B**, The mucosal nature of the inflammatory infiltrate and the near complete loss of mucosa. The residual mucosa is polypoid in appearance, but only because of the loss of the surrounding mucosa; hence, the designation of “pseudopolyp.” **B**, The arrowhead indicates the loss of mucosa, and the arrow indicates a pseudopolyp. Hematoxylin and eosin, A, 40 $\times$ ; B, 100 $\times$ .

### Clinical presentation of inflammatory bowel disease

- **Symptoms:** Profuse watery diarrhea with blood, mucus, and pus; abdominal pain; and hematochezia (bright red blood per rectum). Pyoderma gangrenosum initially presents similar to cellulitis but fails to respond to antibiotics; typically causes deep ulceration with a violaceous border.
- **Diagnosis:** Barium enema shows loss of haustra; colonoscopy with biopsy.

### WHIPPLE DISEASE

**Epidemiology:** Occurs in the fourth to fifth decades; Caucasians; male predominance with a male-female ratio of 10:1.

**Causative organism:** Gram-positive bacterium *Tropheryma whippelii*.

**Organs involved:** Systemic infection involving multiple organ systems; primarily, the intestine, central nervous system, and joints.

**Microscopic morphology of Whipple disease:** PAS-positive macrophages distending the intestinal lamina propria.

**Clinical presentation of Whipple disease:** Diarrhea and weight loss, arthropathy, and central nervous system disease; may cause blindness.

**Diagnosis:** Biopsy.

### VASCULAR DISORDERS OF THE SMALL AND LARGE INTESTINE

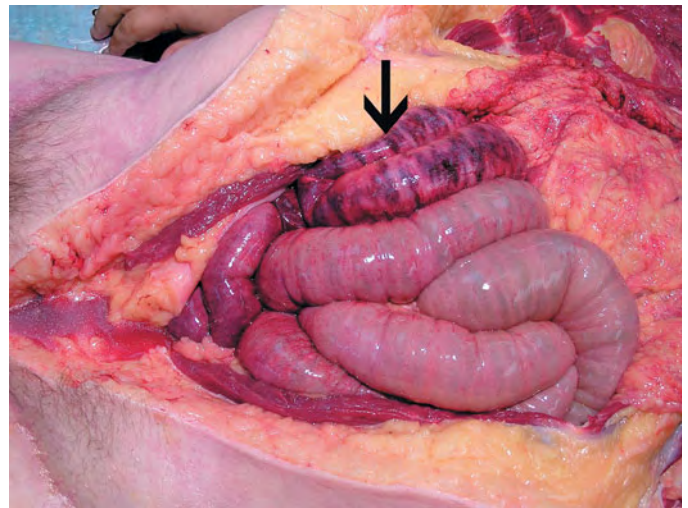
**Overview:** Although there are other vascular disorders of the small and large intestine, the two more common conditions, ischemic bowel disease and angiodysplasia, are discussed below.

#### ISCHEMIC BOWEL DISEASE (Figure 14-18)

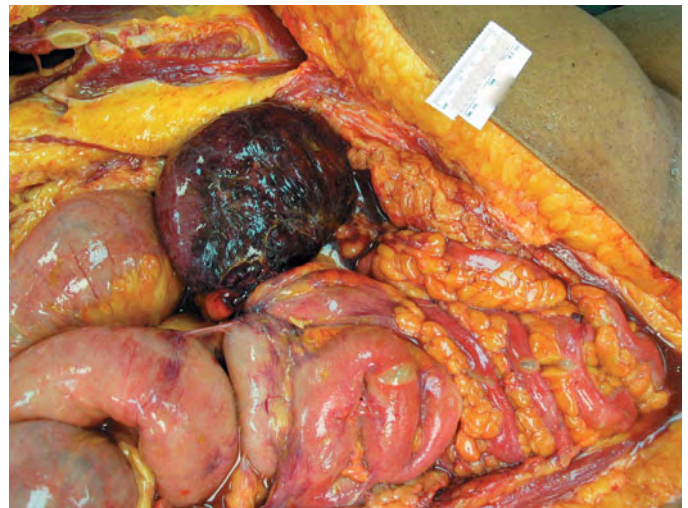**Basic description:** Damage to the bowel due to decreased blood flow.

#### Mechanisms for development of ischemic bowel disease

- Arterial thrombosis; causes include atherosclerosis, vasculitis, and hypercoagulable states.
- Arterial emboli; causes include endocarditis and atherosclerosis.
- Venous thrombosis; causes include hypercoagulable states and abdominal trauma.
- Generalized hypoperfusion; causes include shock, cardiac failure, and dehydration.
- Miscellaneous causes are stricture and volvulus (Figure 14-19).



**Figure 14-18.** Intestinal ischemia. Note the red discoloration of the wall of the ischemic segment of the colon (arrow). Colonic ischemia can result from a variety of causes; in this case, the patient had a thrombus that developed within the superior mesenteric artery.



**Figure 14-19.** Volvulus. Note the red-black discolored segment of small intestine. At the base of the red-black discolored segment, the bowel is twisted upon itself (a volvulus). The red-black discoloration of the wall is from hemorrhage. Often, the volvulus will compress the venous drainage, but not the arterial circulation. Thus, blood reaches the twisted segment of bowel but cannot drain from it, causing a “red” or “venous” infarct.



### Types of ischemic bowel disease

- **Transmural infarct:** Due to occlusion of vessel.
- **Mural and mucosal infarcts:** Commonly due to hypoperfusion. Occurs in two phases: initial hypoxic injury and secondary reperfusion injury. Most damage occurs in the second phase through the production of free radicals, infiltrate of inflammatory cells, and subsequent release of mediators.

### Morphology of ischemic bowel disease

- **Gross:** Hemorrhage within the mucosa; formation of pseudomembrane on the surface of the mucosa.
- **Microscopic:** Hemorrhage within the mucosa or within the wall in general.

**Clinical presentation of ischemic bowel disease:** Abdominal pain, hematochezia, fever, and tachycardia. Chronic ischemic injury can mimic inflammatory bowel disease. Patients can progress to shock. Mesenteric infarction is one of the classic causes of abdominal pain out of proportion to physical examination findings. Diagnosis of ischemic bowel disease is confirmed with angiography.

## ANGIODYSPLASIA

**Basic description:** Dilation of submucosal and mucosal blood vessels in elderly individuals. Bleeding can be acute or chronic or intermittent or massive.

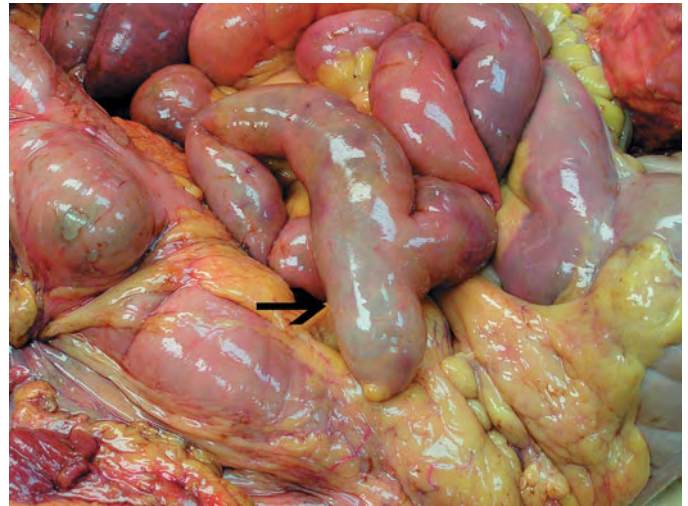**Important point:** Can cause massive gastrointestinal bleeding (referred to as **painless hematochezia**).

## DIVERTICULAR DISEASE

**Overview:** A **diverticulum** is a pouch in the wall of the gastrointestinal tract. **Diverticulosis** is a condition characterized by many diverticuli. **Diverticulitis** is a condition characterized by infection of a diverticulum. When discussing diverticular disease, it almost always refers to false diverticula.

### Two types of diverticula

- **True diverticulum:** A true diverticulum is composed of all four layers of the wall. For example, a **Meckel diverticulum**, which is a remnant of the omphalomesenteric duct occurring near the terminal ileum. It can have ectopic gastric mucosa or pancreatic mucosa and, therefore, ulcers and hemorrhage can occur in these patients (Figure 14-20).
- **False diverticulum:** Herniation of the mucosa and submucosa through a defect in the muscularis propria of the intestine.



**Figure 14-20.** Meckel diverticulum. A Meckel diverticulum (*arrow*), a common incidental finding at autopsy, is a true diverticulum (with all four layers of the wall). Although usually asymptomatic, a patient with a Meckel diverticulum can have ectopic gastric or pancreatic tissue and present with pain or signs of a gastrointestinal hemorrhage, due to ulcer formation.



**Location of false diverticula:** Common in the large intestine (e.g., rectum and descending colon), but can also occur in the right colon and small intestine (Figure 14-21 A and B).

#### Complications of false diverticula

- Can become infected (i.e., diverticulitis), which thickens the wall of the bowel and can produce an “apple-core” lesion on barium enema, thereby mimicking adenocarcinoma of the colon.
- Gastrointestinal bleeding.
- Perforation, peritonitis, abscess, intestinal stenosis, and obstruction.

**Clinical presentation of diverticulosis:** Painless rectal bleeding.

**Clinical presentation of diverticulitis:** Crampy and dull left lower quadrant abdominal pain; fever, nausea and vomiting; and diarrhea or constipation.

## INTESTINAL OBSTRUCTION

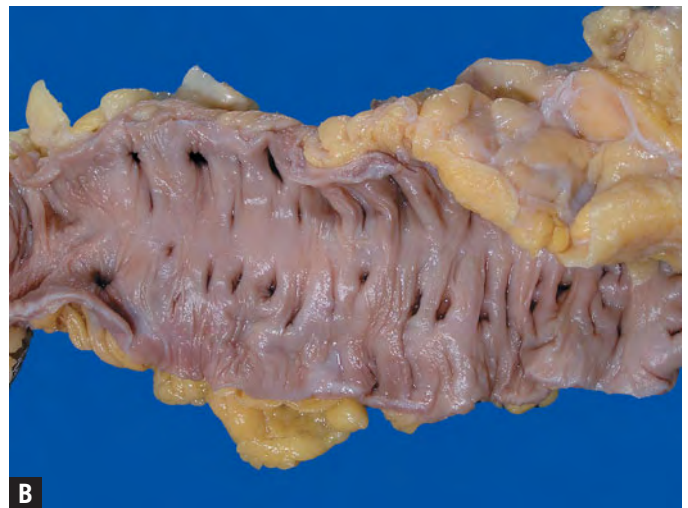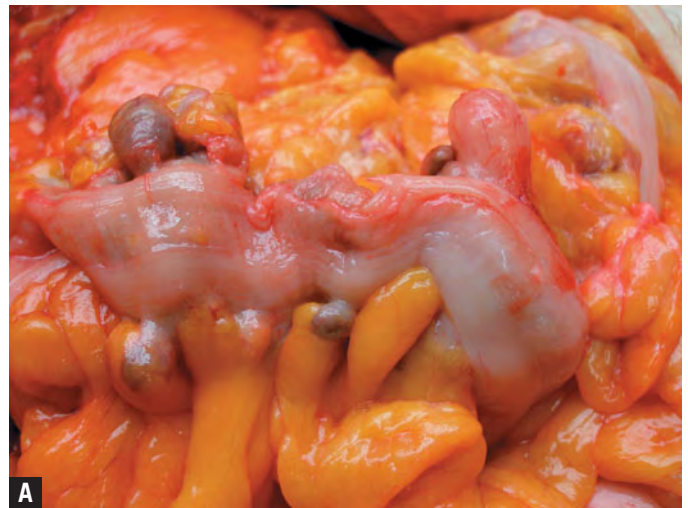**Overview:** **Obstruction** is blockage of the intestinal tract, whereas an **ileus** is absence of motility.

#### Types of obstruction

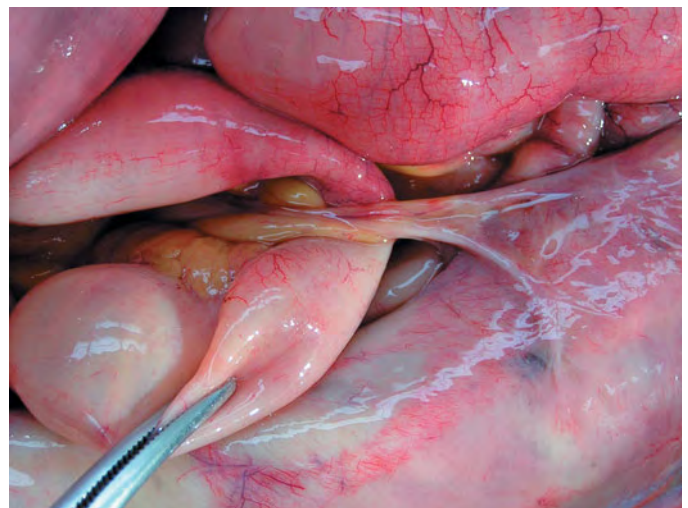
- Mechanical obstruction
  - About 80% of cases of mechanical obstruction are caused by hernias and adhesions, such as occur after surgery (Figure 14-22).
  - Malignancies cause 15% of cases of mechanical obstruction.
  - Other causes of mechanical obstruction include gallstones, strictures, intussusception, which is telescoping of one bowel segment into a distal segment, and volvulus, which is twisting of the bowel on itself (see Figure 14-19).
- Pseudo-obstruction; causes include paralytic ileus, which often occurs postsurgery, and ischemic bowel disease.

#### Clinical presentation of intestinal obstruction

- **Symptoms:** Abdominal distension, pain out of proportion to physical examination findings, vomiting, and inability to pass gas or stool.
- **Signs:** Hyperactive, high-pitched bowel sounds (“rushes and tinkles”) in obstruction, and air fluid levels on plain film radiographs. Serum amylase and lipase are usually elevated, and leukocytosis is common. Absence of bowel sounds is characteristic of ileus.



**Figure 14-21.** Diverticulosis. **A**, Note the diverticula bulging outward from the serosal surface of this segment of colon. **B**, This segment of distal colon was opened longitudinally, and all the spaces within the mucosa represent ostia for the colonic diverticula.



**Figure 14-22.** Fibrous adhesion causing bowel obstruction. This patient had an appendectomy many years prior to his death. A fibrous adhesion developed between the site of the appendectomy and the abdominal wall. The resultant fibrous band entrapped a segment of small intestine and led to a bowel obstruction.

## ACUTE APPENDICITIS

**Overview:** Infectious process involving the appendix. It may be due to obstruction of the appendix with a fecalith. Patients present with acute crampy and steady periumbilical pain that migrates to the right lower quadrant of the abdomen and is associated with nausea and vomiting, fever, and leukocytosis. Rupture of the appendix leads to peritonitis and death (Figure 14-23).

## TUMORS OF THE SMALL AND LARGE INTESTINE

**Overview:** Tumors of the small and large intestine include non-neoplastic polyps, adenomas, adenocarcinoma, and carcinoid tumor, which will be discussed in this section.

### NON-NEOPLASTIC POLYPS

#### 1. Hyperplastic polyps

- **Basic description:** Common polyp of the large intestine, composed of hyperplastic colonic mucosa.

#### 2. Peutz-Jeghers polyps

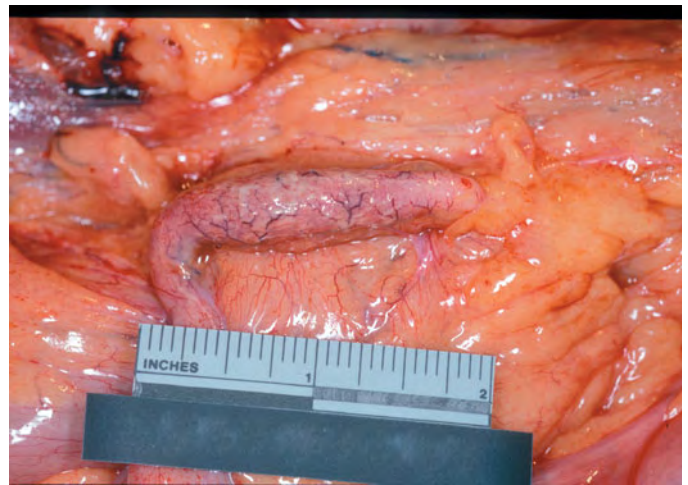- **Basic description:** Hamartomatous polyps, which include muscularis mucosa.
- **Features of Peutz-Jeghers syndrome**
  - Autosomal dominant.
  - Many gastrointestinal polyps.
  - Increased pigmentation of the lips and oral mucosa.
  - Patients have increased risk for developing pancreatic, breast, lung, and ovarian cancers.

### ADENOMAS

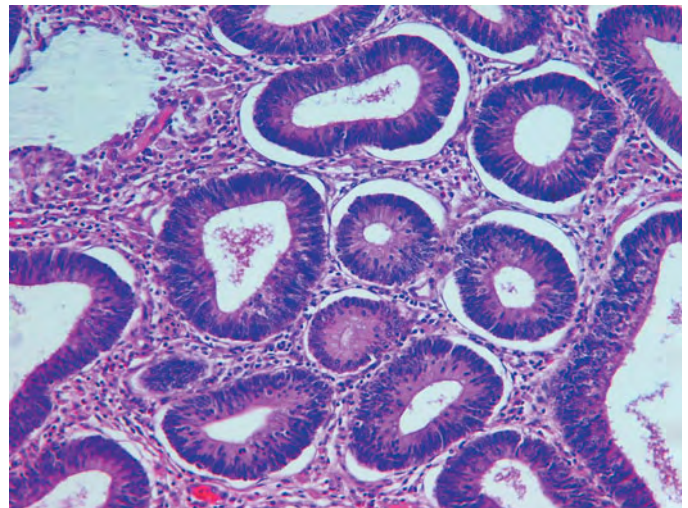
**Types:** Tubular, villous, and tubulovillous.

#### Morphology of adenomas

- **Gross:** Tubular adenomas tend to be polypoid, and villous adenomas are more sessile.
- **Microscopic:** Adenomas composed of dysplastic epithelium with a tubular architecture are called tubular adenomas (Figure 14-24). Adenomas with fine finger-like projections are called villous adenomas (Figure 14-25). Or, adenomas may have a combination of tubular and villous architecture and are called tubulovillous adenomas.



**Figure 14-23.** Early acute appendicitis. Note the swelling of the appendix and the creamy yellow exudate on the surface (pus). Rupture of an inflamed appendix will lead to seeding of the peritoneal cavity with bacteria and a resultant peritonitis, which has a high mortality rate. Courtesy of Dr. Gary Dale, Forensic Science Division, Montana State Department of Justice, Missoula, MT.



**Figure 14-24.** Tubular adenoma. Note the dysplastic epithelial cells with a tubular architecture. Tubular adenomas are less prone to malignant degeneration than are villous adenomas. Hematoxylin and eosin, 200X.



**Important points regarding adenomas**

- Adenomas themselves are benign, but they are precursors of malignancy.
- In general, villous adenomas are more likely to progress to or contain foci of invasive adenocarcinoma than are tubular adenomas. If a villous adenoma is  $> 4.0$  cm in size, the risk of harboring a malignant neoplasm is greatly increased (i.e.,  $> 40\%$ ).

**COLONIC ADENOCARCINOMA**

**Epidemiology:** Older adults ( $> 50$  years of age).

**Pathogenesis:** Small polyps (adenomas) are dysplastic, and dysplasia can progress to neoplasia.

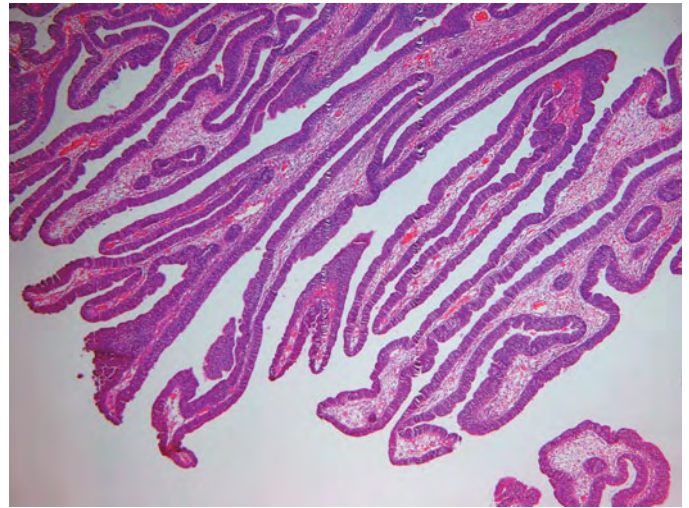
**Risk factors for colonic adenocarcinoma**

- High fat, high refined carbohydrate diet.
- **Familial adenomatous polyposis (FAP)**
  - **Mutation:** *APC* gene on chromosome 5q21. Normal *APC* gene promotes the degradation of  $\beta$ -catenin;  $\beta$ -catenin activates the *MYC* and *cyclin D1* genes.
  - **Inheritance pattern:** Autosomal dominant.
  - **Importance:** High risk for progression to invasive adenocarcinoma (100% of patients by age 50 years).
  - **Gross morphology of FAP:** Colon has hundreds of adenomas.
  - **Treatment:** Colectomy.
- **Hereditary nonpolyposis colon cancer (HNPCC)**
  - **Mutation:** One of five DNA mismatch repair genes.
  - **Gross morphology:** No increased numbers of polyps.

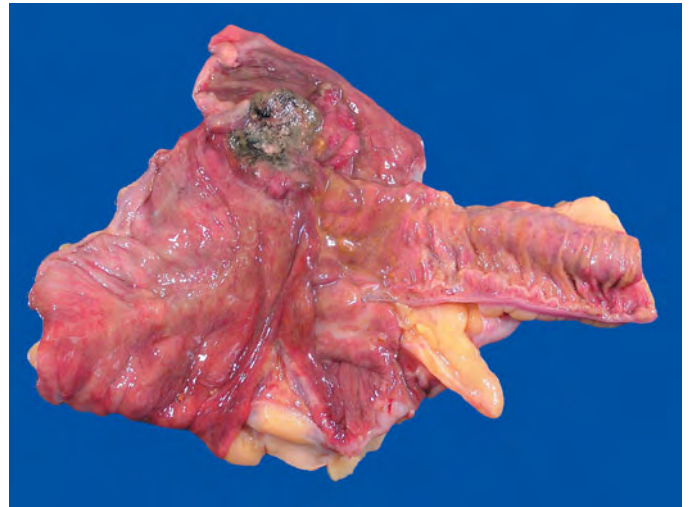**Other risk factors for colonic adenocarcinoma:** Increasing age, adenomas, inflammatory bowel disease, and decreased intake of antioxidants.

**Important points regarding colonic adenocarcinoma****■ Location is important for presentation**

- Left-sided tumors present sooner by causing more of an obstruction as fecal material is more solid at that point. Right-sided tumors (i.e., cecal) present later because they do *not* cause an obstruction and because fecal material is more liquid at that point in transit ([Figures 14-26 and 14-27](#)).
- Adenocarcinoma is uncommon in the small intestine.



**Figure 14-25.** Villous adenoma. Note the dysplastic epithelial cells with a villous (“finger-like”) architecture. Villous adenomas are more likely than tubular adenomas to harbor an invasive adenocarcinoma. Hematoxylin and eosin, 40 $\times$ .



**Figure 14-26.** Colonic adenocarcinoma of cecum. In this opened segment of terminal ileum and cecum, note the polypoid adenocarcinoma in the cecum (green mass at the top of the image). Cecal adenocarcinomas can often grow to a greater size than rectal adenocarcinomas before causing obstruction because of the fluid nature of feces in the cecum.



- Depth of invasion into the wall is vital to staging; midway through the muscularis propria is an important boundary (Figure 14-28).
- Colonic adenocarcinoma often results in metastases to the liver.
- Some colonic and intestinal adenocarcinomas can produce a large amount of mucus (Figure 14-29).

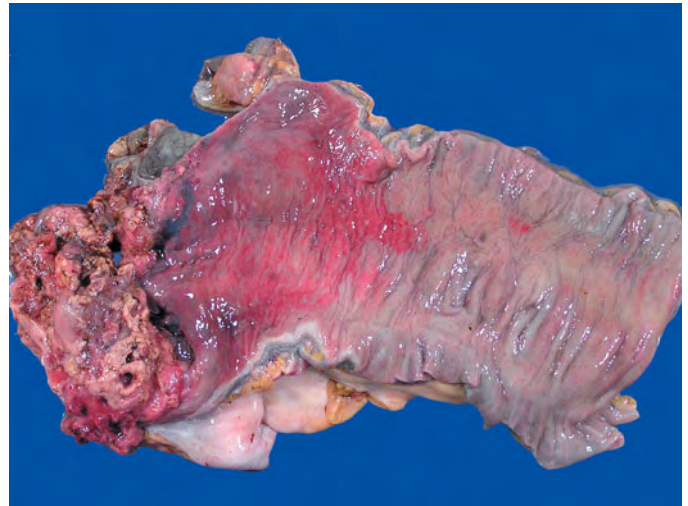#### Clinical presentation of colonic adenocarcinoma

- **Signs and symptoms:** Right-sided lesions are most often associated with pain and change in the stool caliber, whereas left-sided lesions more commonly present as iron deficiency anemia secondary to occult bleeding.
- **Diagnosis:** Colonoscopy with biopsy. Left-sided tumors can produce “apple-core” lesion on barium enema.
- **Important point:** The earliest sign of colonic adenocarcinoma is occult bleeding, and all iron deficiency anemia in patients older than 50 years is considered colon cancer until proven otherwise.

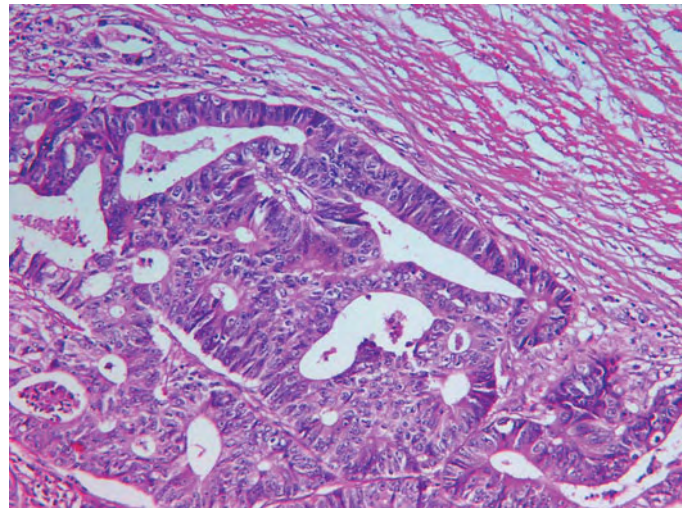
#### CARCINOID TUMOR (Figure 14-30)

**Location:** Appendix, ileum, rectum, bronchi.

**Epidemiology:** Usually older patients.



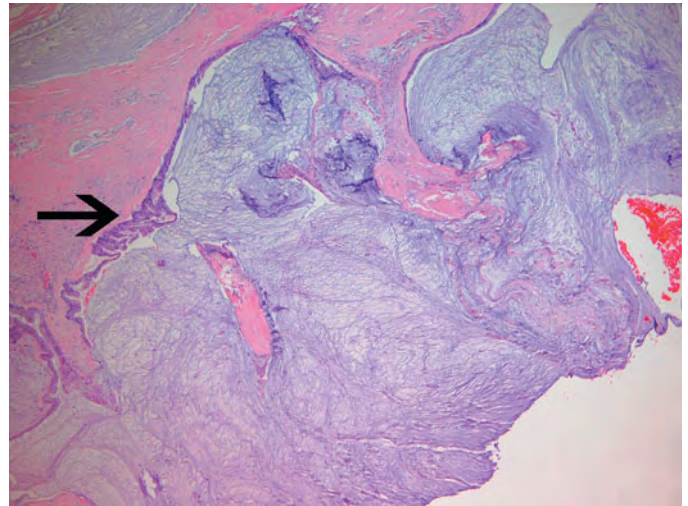
**Figure 14-27.** Colonic adenocarcinoma of rectum. In this opened segment of rectum, note the friable, polypoid mass. Rectal adenocarcinomas can produce obstruction sooner in their clinical course than cecal adenocarcinomas because of the solid nature of feces in the rectum.



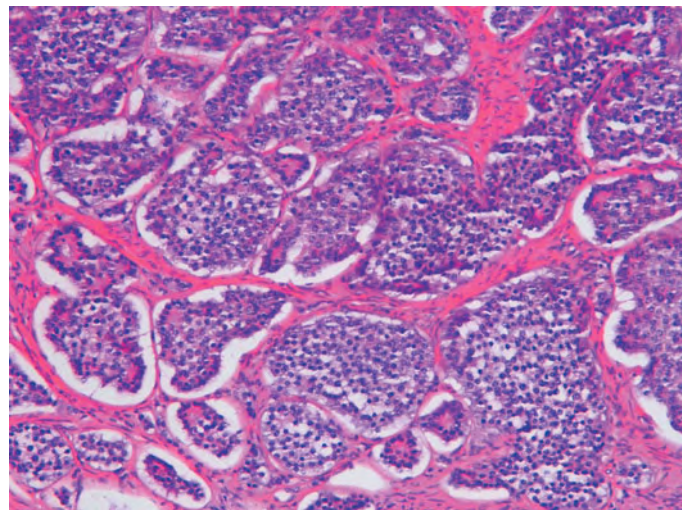
**Figure 14-28.** Invasive colonic adenocarcinoma. Note the glandular architecture of this invasive colonic adenocarcinoma. Depth of invasion into the muscularis propria is an important feature when staging these neoplasms. Hematoxylin and eosin, 200 $\times$ .

**Important points regarding carcinoid tumor**

- Carcinoid tumors can secrete gastrin, somatostatin, insulin, serotonin, or other hormone-like proteins.
- Carcinoid tumors are relatively benign tumors, but are still capable of metastases.
- Can produce gastrin, resulting in Zollinger-Ellison syndrome.
- One third of tumors metastasize, one third of patients present with a second malignancy, and one third of patients have multiple carcinoid tumors.
- If tumors metastasize to the liver, the serotonin released by the tumor is not metabolized and reaches the systemic circulation producing **carcinoid syndrome**. Features of carcinoid syndrome are flushing, diarrhea, wheezing, and endocardial fibrosis, predominantly involving the tricuspid valve.



**Figure 14-29.** Mucinous adenocarcinoma. Some variants of colonic adenocarcinoma can produce a prominent amount of mucin. In this image, the acellular, myxoid material is mucous and only a few neoplastic cells are present (*arrow*). The mucin produced by one of these tumors can fill the peritoneum, causing a condition referred to as pseudomyxoma peritonei. Often, the source of malignancy for this condition is an appendiceal tumor. Hematoxylin and eosin, 40 $\times$ .



**Figure 14-30.** Carcinoid tumor. Carcinoid tumors are low-grade neoplasms found within the gastrointestinal system (as well as in other anatomic systems). Their characteristic histologic features are monotonous bland cells in nests. The nuclei have a "salt and pepper" appearance to them. Gastrointestinal carcinoid tumors, which metastasize to the liver, can produce the carcinoid syndrome. Hematoxylin and eosin, 200 $\times$ .

*This page intentionally left blank*



# CHAPTER 15

## PATHOLOGY OF THE LIVER, GALLBLADDER, AND PANCREAS

### OVERVIEW

Abnormalities in laboratory tests are frequently the first or only sign of liver disease, and the pattern of abnormality is often suggestive of the underlying disease process. Gamma-glutamyl-transferase (GGT) is particularly sensitive for liver disease. If the level of GGT is normal, there is only a 1–2% chance of liver disease. The levels of aspartate aminotransferase (AST) and alanine aminotransferase (ALT) are also very useful for the diagnosis of liver disease. An AST > 3000 U/L suggests a severe hypotensive episode causing centrilobular necrosis, a toxic injury such as acetaminophen overdose, or acute viral hepatitis. On the other hand, chronic diseases of the liver such as alcoholic liver disease and chronic viral hepatitis are typically associated with smaller elevations of transaminases, in the 100–300 U/L range. Elevated ALT and AST with an AST/ALT ratio > 2:1 is classically associated with alcoholic hepatitis. Elevated alkaline phosphatase (ALP) can be seen in both liver and bone disease, whereas a concomitant elevation of ALP and GGT is consistent with cholestatic liver disease.

While the above enzymes (GGT, AST, ALT and ALP) indicate damage to the hepatocytes, prothrombin time (PT) and serum albumin are more reflective of the functional status of the liver, since both albumin and clotting factors are produced by hepatocytes. Factor VII has a serum-half life of about 4 hours, making the PT a good assessment of an acute change in liver function, whereas albumin is more accurate at assessing a chronic change in liver function. Also, assessment of gamma globulins is useful for determining an acute versus chronic pathologic liver process. In acute processes, the gamma globulin level is normal, and in chronic processes, it is elevated (> 3 g/dL).

When assessing liver function tests, four general patterns are apparent: (1) acute hepatitis pattern, which has elevated transaminase levels and variable increases in other enzymes; (2) cirrhosis pattern, which has decreased albumin, elevated gamma globulins (with  $\beta$ – $\gamma$  bridging on serum electrophoresis) and elevated PT; (3) chronic hepatitis pattern, which has a combination of changes seen in acute hepatitis and cirrhosis patterns; and (4)

obstructive liver disease pattern, also called **cholestasis**, which has an elevated ALP and bilirubin (Table 15-1).

Ascites is often associated with cirrhosis; however, both transudative ascites (seen in patients with cirrhosis, alcoholic hepatitis, or congestive heart failure) and exudative ascites (seen in patients with peritoneal carcinomatosis or tuberculosis) may occur. Differentiating between the two types requires a determination of gradient (i.e., difference between serum albumin and ascitic fluid albumin). Transudative ascites has a high gradient ( $> 1.1$  g/dL), and exudative ascites has a low gradient ( $< 1.1$  g/dL).

This chapter discusses liver pathology, including jaundice and cholestasis, hepatic failure, cirrhosis, vascular and circulatory disorders, alcoholic liver disease, metabolic diseases, obstructive biliary tract disorders, and hepatic tumors; gallbladder pathology, including gallstones and acute and chronic cholecystitis; and pancreatic pathology, including pancreatitis and pancreatic adenocarcinoma.

## GENERAL RESPONSES OF THE LIVER TO INJURY

**Overview:** Although many different toxins, infections, and other conditions affect the liver, the liver only has five general responses to injury: inflammation, cellular accumulations, cell death, fibrosis, and regeneration. **Cirrhosis** results from a combination of fibrosis and regeneration after cell death. Of the five general responses of the liver, only cellular accumulations and cell death will be discussed here.

### Cellular accumulations

- **Macrovesicular steatosis:** One large fat vacuole in hepatocytes; associated with alcohol use, obesity, and diabetes mellitus.
- **Microvesicular steatosis:** Many small vacuoles in hepatocytes; associated with acute fatty liver of pregnancy, Reye syndrome (occurs in children with viral illness when given aspirin), alcohol, and certain drugs (e.g., tetracycline).

**Cell death** (i.e., necrosis and apoptosis): Several patterns of necrosis are specific to the liver.

- **Spotty necrosis:** Focal areas of necrosis in the lobular parenchyma.
- **Interface hepatitis:** Necrosis at the edge of the limiting plate.
- **Bridging necrosis:** Necrosis spanning between the portal tracts and from the portal tracts to the centrilobular hepatocytes.
- **Submassive necrosis:** Necrosis of entire lobules.
- **Massive necrosis:** Necrosis of almost the entire liver.

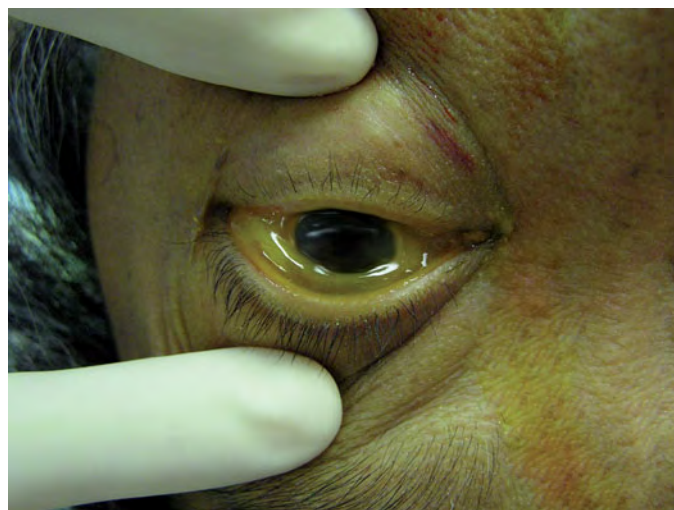
## JAUNDICE AND CHOLESTASIS

**Overview: Jaundice** is an accumulation of unconjugated or conjugated bilirubin in skin that produces a golden yellow color. Jaundice is evident in skin when the serum bilirubin level is 2.5–3 mg/dL or higher. Yellow discoloration of the sclerae is referred to as **icterus** (Figure 15-1). **Cholestasis** is an accumulation of bile. Bile contains much more than just bilirubin, including bile salts and cholesterol.

**TABLE 15-1.** Laboratory Studies and Patterns of Liver Disease

Patterns of Liver Disease	Laboratory Studies
Acute hepatitis pattern	↑ AST, ALT
Cirrhosis pattern	↓ albumin, ↑ gamma globulins
Chronic liver disease pattern	↑ AST, ALT ↓ albumin, ↑ gamma globulins
Obstructive liver disease pattern	↑ ALP, bilirubin

AST, aspartate aminotransferase; ALT, alanine aminotransferase; ALP, alkaline phosphatase.



**Figure 15-1.** Scleral icterus. Note the yellow discoloration of this patient's conjunctivae. Scleral icterus is a manifestation of jaundice, and can be seen in patients with elevated levels of bilirubin.

**TABLE 15-2.** Mechanisms of Jaundice and Cholestasis and Their Causes

Mechanism of Jaundice and Cholestasis	Form of Hyperbilirubinemia	Causes
Increased bilirubin production	Unconjugated	Hemolytic anemia, ineffective hematopoiesis
Decreased hepatic uptake	Unconjugated	Gilbert syndrome, rifampin use
Impaired conjugation	Unconjugated	Physiologic jaundice of newborn, Crigler-Najjar syndrome, diffuse hepatocellular disease
Decreased hepatic excretion	Conjugated	Dubin-Johnson syndrome, diffuse hepatocellular disease
Impaired intrahepatic bile flow	Conjugated	Primary biliary cirrhosis, primary sclerosing cholangitis
Impaired extrahepatic bile flow	Conjugated	Gallstone, pancreatic carcinoma

**Mechanisms of jaundice and cholestasis** (Table 15-2)

- Excessive production of bilirubin results in unconjugated hyperbilirubinemia (causes: hemolytic anemias and ineffective erythropoiesis, such as in megaloblastic anemia).
- Reduced hepatic uptake results in unconjugated hyperbilirubinemia (causes: rifampin, which competes for bilirubin uptake; Gilbert syndrome).
- Impaired conjugation results in unconjugated hyperbilirubinemia (causes: physiologic jaundice of the newborn, Crigler-Najjar syndrome, diffuse hepatocellular damage).
- Decreased hepatocellular excretion causes conjugated hyperbilirubinemia (causes: Dubin-Johnson syndrome, diffuse hepatocellular damage).
- Impaired bile flow (from intrahepatic or extrahepatic obstruction) results in conjugated hyperbilirubinemia.
  - Causes of intrahepatic obstruction: primary biliary cirrhosis, primary sclerosing cholangitis.
  - Causes of extrahepatic obstruction: gallstones, carcinoma of the pancreas, extrahepatic biliary atresia or biliary strictures, and extrahepatic primary sclerosing cholangitis.

**SPECIFIC CONDITIONS CAUSING JAUNDICE AND CHOLESTASIS**

**Overview:** Although there are many causes of jaundice and cholestasis, the five conditions that will be discussed in this section are hereditary conditions or conditions associated with the neonate. These conditions are physiologic jaundice of the newborn, Gilbert syndrome, Crigler-Najjar syndrome, Dubin-Johnson syndrome, and neonatal cholestasis.

**PHYSIOLOGIC JAUNDICE OF THE NEWBORN**

**Basic description:** The enzymes that conjugate bilirubin do not mature for a few weeks after birth; therefore, neonates are prone to development of unconjugated hyperbilirubinemia.

**GILBERT SYNDROME**

**Epidemiology:** Common (> 5% of the population); male predominance.



**Mechanism:** Mutations of the *UGT* gene lead to decreased levels of uridine diphosphate-glucuronyl transferase (at 30% of normal level), which causes decreased ability to conjugate bilirubin with glucuronic acid.

**Clinical presentation of Gilbert syndrome:** Patients become jaundiced when stressed (e.g., illness, exercise).

### CRIGLER-NAJJAR SYNDROME (TYPES I AND II)

**Inheritance pattern:** Both types I and II are autosomal recessive.

**Mechanism:** Type I has a complete lack of enzyme needed for the conjugation of glucuronic acid to bilirubin; type II has partial lack of the enzyme.

### DUBIN-JOHNSON SYNDROME

**Mechanism:** Absence of canalicular protein multidrug-resistant protein 2 (MRP2), which transports bilirubin glucuronides.

**Gross morphology:** Black liver.

### NEONATAL CHOLESTASIS

**Causes:** Bile duct obstruction, infections (e.g., caused by cytomegalovirus, sepsis), toxins, metabolic (e.g.,  $\alpha_1$ -antitrypsin deficiency), and idiopathic (50% of cases).

**Microscopic morphology of neonatal cholestasis:** Giant cells, cholestasis, mononuclear cells in portal tracts, and extramedullary hematopoiesis.

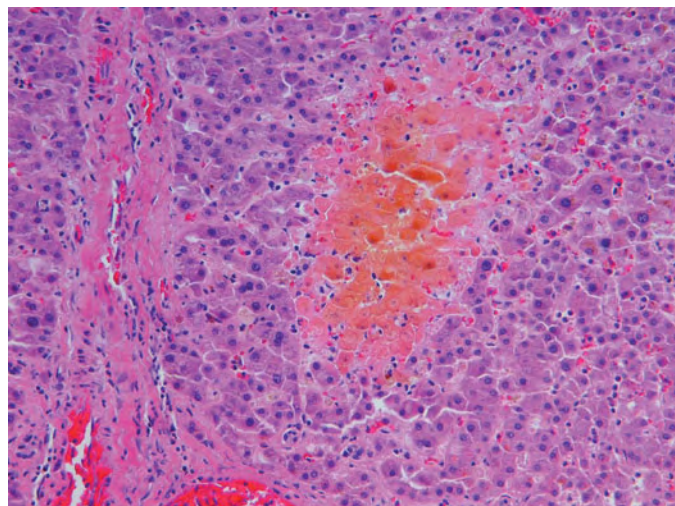
**Gross morphology of jaundice and cholestasis:** Scleral icterus; skin xanthomas due to impaired excretion of cholesterol.

**Microscopic morphology of jaundice and cholestasis** (Figures 15-2 and 15-3)

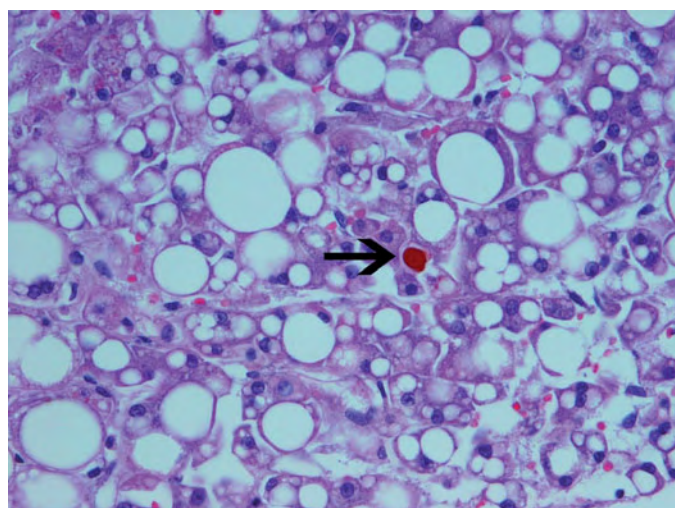
- Bile plugs within canaliculi (seen in cholestasis).
- Foamy degeneration of hepatocytes (due to intracellular accumulation of bile).
- If cholestasis is due to intra- or extrahepatic bile duct obstruction:
  - Distension of upstream bile ducts; proliferation and edema of bile ducts.
  - Bile lakes (i.e., focal destruction of parenchyma with accumulation of bile).
  - Cirrhosis due to portal tract fibrosis.

### Clinical presentation of jaundice and cholestasis

- **Symptoms:** Patients with cholestasis have pruritus as a result of deposition of bile salts in tissue, and may have clay-colored stools resulting from failure of bile to reach the intestines.
- **Signs:** Elevated bilirubin (unconjugated or conjugated, depending upon the cause of jaundice); also increased concentration of ALP in cholestasis. ALP is produced by bile duct epithelium and canalicular hepatocytes and is released by detergent action of bile. ALP is increased to three to four times the normal level, and the AST and ALT are increased more than five to ten times the normal levels.



**Figure 15-2.** Bile lake. In the center of the photomicrograph is a yellow-green pool of bile, which has displaced the surrounding hepatocytes. Bile lakes can be seen in patients with obstruction of the bile ducts. Hematoxylin and eosin, 200 $\times$ .



**Figure 15-3.** Bile plug. At the tip of the black arrow is a bile ductule plugged with bile. This histologic feature is indicative of cholestasis. Hematoxylin and eosin, 400 $\times$ .

**Laboratory studies to differentiate causes of jaundice and cholestasis**

- **Hemolytic causes:** No urine bilirubin, elevated urine urobilinogen, and elevated unconjugated bilirubin.
- **Hepatocellular cause:** Increased urine bilirubin, normal urine urobilinogen, and elevated unconjugated and conjugated bilirubin.
- **Obstructive causes:** Increased urine bilirubin, decreased urine urobilinogen, and elevated conjugated bilirubin.

**Diagnosis of cause of jaundice and cholestasis:** Biopsy of liver; radiographic imaging to determine location and source of obstruction.

## HEPATIC FAILURE

**Overview:** For liver failure to occur, there must be a loss of 80–90% of hepatic parenchyma. Hepatic failure occurs in one of three situations: massive hepatic necrosis, chronic liver disease, or widespread but nonfatal injury to the hepatocytes. Hepatic failure as a result of chronic liver disease is most often due to the end stage of cirrhosis. Widespread damage to hepatocytes, which maintain viability, has several causes, including acute fatty liver of pregnancy. Massive hepatic necrosis as a cause of hepatic failure will be discussed below.

### MASSIVE HEPATIC NECROSIS

**Basic description:** Massive hepatic necrosis is often the result of fulminant hepatitis or toxic injury. The definition of fulminant hepatic failure is the onset of **encephalopathy** within 8 weeks of the onset of jaundice in a patient with hepatic injury and no history of prior liver disease.

**Causes of massive hepatic necrosis**

- Acetaminophen toxicity (35–40% of cases).
- Other toxins: Halothane, isoniazid.
- Acute hepatitis A (4% of cases).
- Acute hepatitis B (8% of cases).
- **Others causes:** Acute fatty liver of pregnancy, Wilson disease, hepatic ischemia, *Amanita* mushroom poisoning.
- **Specific cause: Reye syndrome** (clinical presentation in children: Reye syndrome presents as vomiting a few days after treatment of a viral infection with aspirin; patients progress to seizures, cloudy sensorium, and coma).

### COMPLICATIONS OF HEPATIC FAILURE

**Overview:** Include hepatic encephalopathy, hepatorenal syndrome, jaundice, hyperammonemia, coagulopathy, hypoglycemia, and infections. Several of these complications are simply due to loss of normal liver functions. Coagulopathy is a result of deficiency of vitamin K–dependent factors II, VII, IX, and X. Hypoglycemia is a result of impaired gluconeogenesis. Infections are one of the leading causes of death in patients with fulminant hepatic failure. Hepatic encephalopathy and hepatorenal syndrome are discussed below.

### HEPATIC ENCEPHALOPATHY

**Basic description:** Complex neuropsychiatric syndrome that complicates advanced liver disease.

**Forms: acute and chronic**

■ **Acute hepatic encephalopathy:** Occurs in the setting of fulminant hepatic failure. Cerebral edema is more prominent in acute hepatic encephalopathy than in the chronic form.

■ **Chronic hepatic encephalopathy:** Occurs with chronic liver disease; is reversible.

**Pathogenesis of hepatic encephalopathy:** Inadequate removal of nitrogenous compounds or other toxins that are ingested or formed in the gastrointestinal tract. Common precipitants include gastrointestinal bleeding and gastrointestinal protein loading, portosystemic shunting, and infections.

**Microscopic morphology:** Characterized by Alzheimer type II astrocytes in the central nervous system (CNS).

**Clinical presentation of hepatic encephalopathy**

- Disturbance of sleep is often the earliest sign of hepatic encephalopathy.
- **Asterixis** and hyperreflexia.
- **Fetor hepaticus** (musty odor of breath).
- Alterations in personality and cognitive function.

### HEPATORENAL SYNDROME

**Pathogenesis:** Severe cortical vasoconstriction.

**Clinical presentation of hepatorenal syndrome**

- **Signs and symptoms:** Decreased glomerular filtration rate (GFR), oliguria, low urine sodium and disproportionately high ratio of blood urea nitrogen (BUN) to creatinine (i.e., prerenal pattern of acute renal failure).
- **Clinical course:** Often progressive and fatal, with mortality rate of 95%.

**Important point:** Kidneys are histologically normal.

## CIRRHOSIS OF THE LIVER

**Basic description:** Diffuse scarring of the liver with nodular regeneration of hepatocytes, resulting in severe disruption of hepatic architecture (Figure 15-4).

**Causes of cirrhosis in the Western world (Table 15-3)**

- Viral hepatitis; hepatitis C (about 50% of patients with hepatitis C infection develop cirrhosis). Hepatitis C has now surpassed alcoholism as the leading cause of cirrhosis in the United States. Hepatitis B is less likely to progress to cirrhosis.
- Alcohol abuse (6–15% of chronic alcoholics develop cirrhosis).
- Nonalcoholic fatty liver disease (NAFLD) or nonalcoholic steatohepatitis (NASH). Incidence is rising dramatically. Up to 10% of patients with NAFLD/NASH will go on to develop cirrhosis.



**Figure 15-4.** Cirrhosis. This cross-section of the liver reveals parenchyma that is effaced by innumerable nodules, most of which are > 3 mm in size.

**TABLE 15-3.** Causes of Cirrhosis

Source of Cirrhosis	Causes
Infectious	Viral (hepatitis B, C, D)
Toxins	Ethanol
Metabolic	Hereditary hemochromatosis, Wilson disease, $\alpha_1$ -antitrypsin deficiency
Biliary disease	Primary biliary cirrhosis, primary sclerosing cholangitis
Other	Autoimmune, cryptogenic



■ Sclerosing cholangitis, primary biliary cirrhosis, biliary atresia, autoimmune hepatitis, hereditary hemochromatosis, Wilson disease, and  $\alpha_1$ -antitrypsin deficiency are less common causes of cirrhosis.

■ **Cryptogenic cirrhosis:** Term used when there is no recognizable cause for the cirrhosis.

**Mechanism of cirrhosis:** Chronic inflammation causes the release of transforming growth factor- $\beta$  (TGF- $\beta$ ), which promotes collagen synthesis by stellate cells, leading to fibrosis. Cycles of cell death, fibrosis, and regeneration result in cirrhosis of the liver; reorganization of vascular microarchitecture plays a role.

**Complications of cirrhosis** include portal hypertension, ascites, hepatocellular dysfunction, portal vein thrombosis, and hepatocellular carcinoma (Figure 15-5 A–D).

■ **Portal hypertension:** The portal vein normally drains into the liver. If the liver is scarred, intrahepatic vascular tone increases, causing an increased resistance to portal venous flow and thus an increase in portal venous pressure. Portal hypertension forces blood returning to the heart to take alternate routes such as esophageal varices, hemorrhoids, and **caput medusae** (i.e., dilated veins in abdominal wall). Portal hypertension contributes to the development of ascites and splenomegaly. Splenomegaly also traps red blood cells and platelets. *Note: The cause of portal hypertension can be prehepatic, intrahepatic, or posthepatic, depending upon the site of the pathology.* Cirrhosis is an intrahepatic cause of portal hypertension.

■ Rupture of esophageal varices can lead to massive gastrointestinal hemorrhage.

■ **Ascites:** Occurs as a result of portal hypertension (increased hydrostatic pressure) and hypoalbuminemia (decreased osmotic pressure).

○ **Important points**

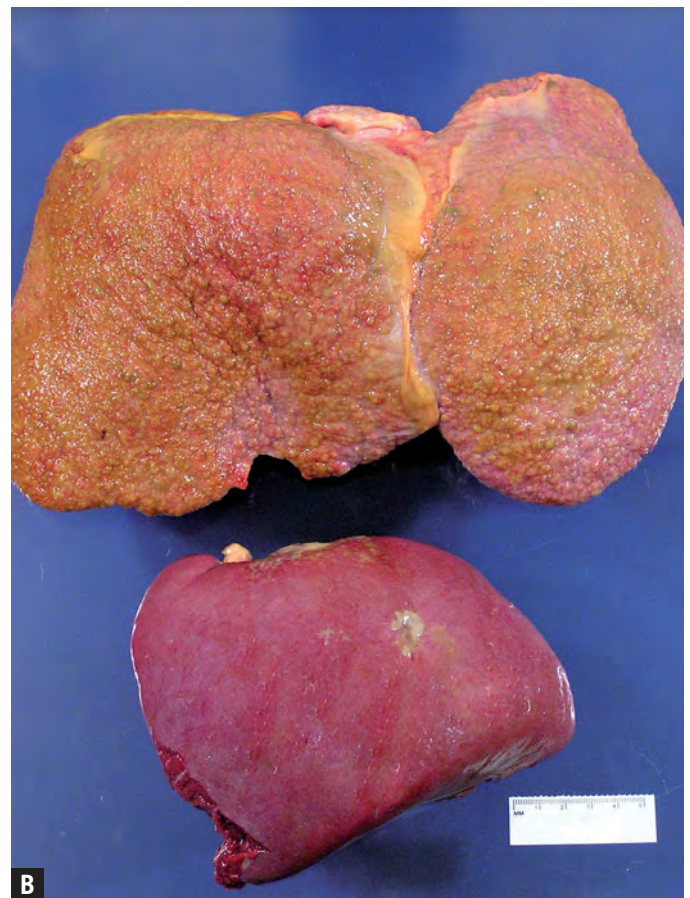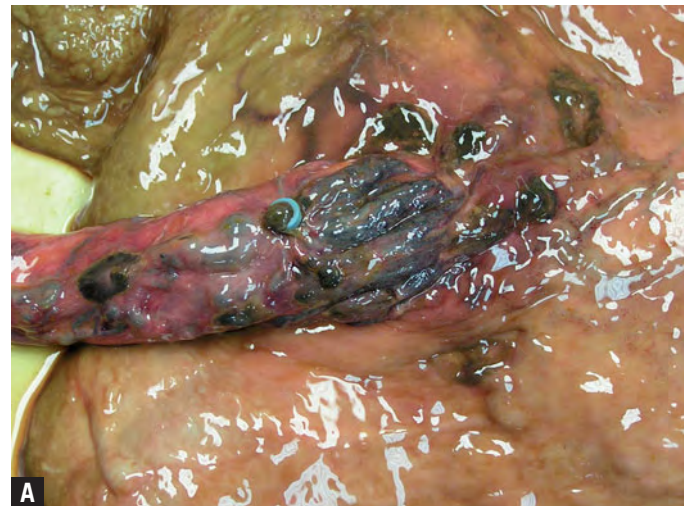
- Ascites is detectable on physical examination (shifting dullness and fluid wave) at amounts of  $> 500$  mL.
- Serum-ascites albumin gradient (SAAG)  $> 1.1$  is diagnostic of portal hypertension.

○ **Spontaneous bacterial peritonitis**

- **Basic description:** Infection of ascitic fluid, usually by *Enterobacteriaceae* or *Pneumococcus*.
- **Symptoms and signs:** Fever, abdominal pain, and tenderness; rebound tenderness and guarding; and leukocytosis.
- **Outcomes:** Can precipitate hepatic encephalopathy or renal insufficiency.

■ **Hepatocellular dysfunction,** leading to impaired protein synthesis (e.g., decreased albumin and clotting factors), which causes bleeding tendencies and contributes to ascites. Hepatocellular dysfunction also leads to low BUN levels and elevated ammonia levels.

■ **Other complications of cirrhosis:** Portal vein thrombosis, hepatocellular carcinoma, hyperestrinism leading to testicular atrophy and gynecomastia.



**Figure 15-5.** Complications of cirrhosis. **A**, Esophageal varices. The blue ring is attempted ligation of the varices by the patient's physician. **B**, Congestive splenomegaly. With portal hypertension, blood return through the splenic vein is impaired. Normally, the spleen is about one tenth the size of the liver; in the photograph, the spleen is about one third the size of the cirrhotic liver.



- **Note:** Remember, cirrhosis is one of the main causes of hepatic failure.

### Morphology of cirrhosis

- **Gross:** Diffusely nodular liver, with a micronodular (< 3 mm nodules) or macronodular (> 3 mm nodules) architecture. Macronodular cirrhosis is associated with hepatitis, autoimmune diseases, and end-stage cirrhosis of all etiologies. Micronodular cirrhosis is associated with alcohol use and with other causes such as  $\alpha_1$ -antitrypsin deficiency and hemochromatosis.
- **Microscopic:** Bridging fibrosis between the portal tracts and central veins, which divide residual and regenerating hepatocytes into nodules. Other features depend upon the cause of cirrhosis.

## ACUTE AND CHRONIC HEPATITIS

**Overview:** Acute and chronic hepatitis are nonspecific terms relating to the time course of the disease within the liver. The basic description of acute and chronic hepatitis, causes, clinical presentation, and important distinguishing points are discussed below.

### ACUTE HEPATITIS (FIGURE 15-6)

**Basic description:** Inflammation of the liver lasting < 6 months.

#### Causes of acute hepatitis

- **Viral:** Hepatitis A, B, C, D, and E, Epstein-Barr virus (EBV), and cytomegalovirus (CMV).
- **Toxins:** Alcohol, acetaminophen, isoniazid, halothane, and phenytoin.

#### Clinical presentation

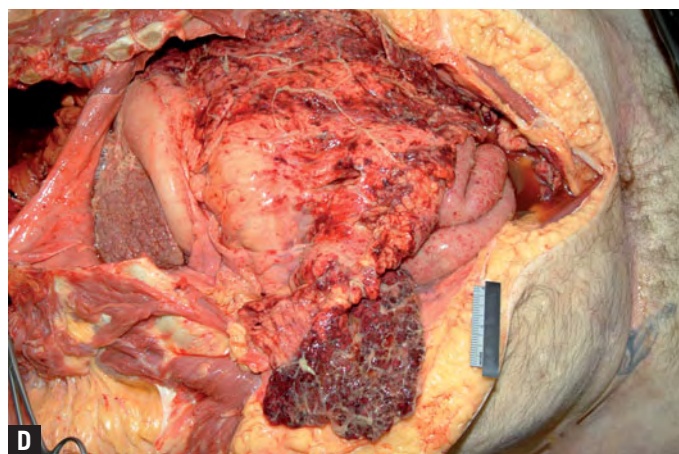
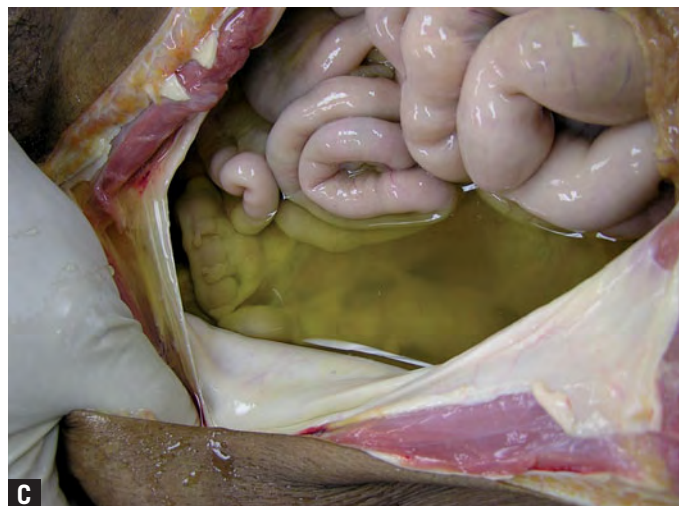- **Signs and symptoms:** Enlarged and tender liver; AST and ALT increased 20–100 times normal levels.
- **Results of acute hepatitis:** Vary from complete resolution to rapid progression, with extensive necrosis and fatal outcome.

### CHRONIC HEPATITIS (FIGURE 15-7)

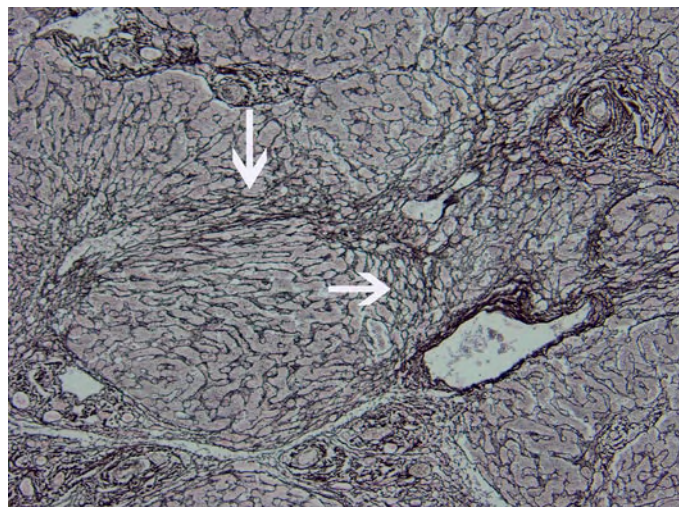
**Basic description:** Sustained inflammation of the liver lasting > 6 months.

#### Important points

- It is difficult to distinguish acute from chronic hepatitis on a histologic basis. The diagnosis of chronic hepatitis requires histologic evidence of progression toward cirrhosis.
- Classification of chronic hepatitis is based upon the etiologic agent; the grade of injury, which depends upon numbers and locations of inflammatory cells; the stage of disease, which depends upon the degree, location, and extent of fibrosis; and the distortion of normal architecture.
- Alcohol abuse and chronic viral hepatitis are rarely associated with AST or ALT values > 1000 U/L. Values > 1000 U/L are suggestive of acute viral, toxic, or ischemic causes of liver damage.



**Figure 15-5.** (Continued) **C**, Ascites. Ascites occurs in patients with cirrhosis because of increased vascular pressure caused by portal hypertension, and also because of decreased plasma osmotic pressure caused by hypoalbuminemia. **D**, Spontaneous bacterial peritonitis. Patients with cirrhosis are prone to development of peritonitis, with no other underlying risk factors identified (e.g., perforated gastric ulcer, diverticulitis).



**Figure 15-6.** Acute hepatitis. This photomicrograph exhibits collapse of the hepatic parenchyma (bridging necrosis indicated by the arrows). Bridging necrosis is a histologic feature of acute hepatitis. Elastin, 100 $\times$ .

## VIRAL HEPATITIS

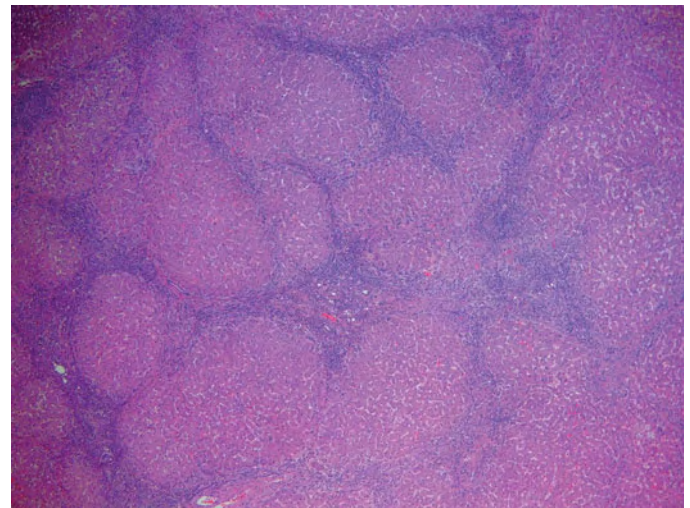
### Important clinical points

- Hepatitis A (HAV) and hepatitis E (HEV): Have no chronic carrier state so there is no risk of cirrhosis; rarely can HAV cause fulminant hepatic failure. When HEV causes fulminant hepatic failure, it is most commonly associated with Southeast Asian pregnant females.
- Of the forms of viral hepatitis, acute hepatitis B (HBV) is most likely to cause fulminant hepatic failure, especially if the patient is co-infected with hepatitis D (HDV).
- Immune response is critical in the pathogenesis of acute hepatitis. A vigorous immune response on exposure to HBV increases the risk of acute hepatitis and fulminant hepatic failure but decreases the risk of subsequent development of the chronic carrier state.
- The immune response to chronic viral hepatitis (e.g., TGF- $\beta$ ) is responsible for most of the damage to the liver.
- HAV is transmitted by the fecal-oral route. HBV is transmitted by exposure to blood or body fluid, sexual contact, or congenital transmission. Transmission of hepatitis C (HCV) requires exposure to blood, and conclusive evidence of routine sexual or congenital transmission is lacking.

**Serologic testing in HBV:** In the acute phase of HBV infection, HBV surface antigen (HBsAg) and antibodies to HBV core antigen (anti-HBc) are detected in the serum. HBsAg disappears within 3–5 months, and antibodies to HBV surface antigen (HBsAb) do not appear until 6 months after infection. During this variable length “window period,” anti-HBc antibody is the only serologic marker of infection. Immunity to HBV is conferred by anti-HBV surface antibodies (HBsAb) and is seen in resolved acute infection (Table 15-4).

### Outcomes of viral hepatitis

- **Carrier state:** Patients have *no* symptoms but can transmit the disease; a carrier state is not seen with HAV. HBe antigen is associated with a highly infectious state.
- **Asymptomatic infection:** No symptoms.



**Figure 15-7.** Chronic hepatitis. Acute and chronic hepatitis can often appear similar histologically. Chronic hepatitis can be separated from acute hepatitis by demonstration of scarring. In the photomicrograph, the hepatic parenchyma is vaguely divided into nodules, due to early bridging fibrosis. The early bridging fibrosis is associated with a prominent lymphocytic infiltrate. Hematoxylin and eosin, 40 $\times$ .

**TABLE 15-4.** Serologic Diagnosis of Viral Hepatitis

Stage of Infection	HBsAg	HBsAb	Anti-HBc	HBe Antigen
Acute infection	+	–	+	+
Acute infection, window period	–	–	+	+
Chronic infection	+	–	+	+/–
Resolved infection	–	+	+	–
Immunized	–	+	–	–

HBsAg, hepatitis B surface antigen; HBsAb, hepatitis surface antigen antibody; anti-HBc, antibody versus hepatitis B core antigen; HBe, hepatitis B envelope antigen.



### ■ Acute hepatitis

- Possibly resulting in fulminant hepatic failure (i.e., patients progress to encephalopathy within 2–3 weeks) or subfulminant hepatic failure (i.e., patients progress to encephalopathy in up to 3 months).
- Fulminant hepatitis occurs in < 1% of patients.

### ■ Cholestatic hepatitis

- Most common in infections with HAV.
- Markedly elevated level of conjugated bilirubin and ALP.
- Can be difficult to distinguish from an obstruction of the biliary tree.

■ **Chronic hepatitis:** Not seen in patients with HAV or HEV.

■ **Cirrhosis:** Not seen in patients with HAV.

### Microscopic morphology of acute viral hepatitis

- Ballooning degeneration, hepatocyte necrosis (i.e., **acidophil bodies**), and lobular disarray (i.e., loss of architecture).
- Portal tract inflammation: Mononuclear infiltrate with or without spillover into the surrounding parenchyma.
- Spotty or bridging necrosis (see Figure 15-6).
- Possible cholestasis.

### ■ Important points

- HBV infection is associated with “ground-glass” hepatocytes.
- HCV infection is associated with mild fatty change (macrovesicular steatosis in sublobular region), lymphoid aggregates, and reactive bile duct epithelium.

### Microscopic morphology of chronic viral hepatitis

- Evidence of hepatocyte injury (e.g., ballooning degeneration), necrosis, and regeneration.
- Portal tract inflammation with or without spillover; portal tract inflammation with spillover is referred to as **interface hepatitis**.
- Fibrosis: Portal, periportal, or bridging (see Figure 15-7).

### Clinical presentation of acute viral hepatitis

- **Symptoms:** Constitutional and gastrointestinal symptoms (e.g., malaise, fatigue, nausea, vomiting, myalgia, and headache).
- **Signs:** AST and ALT are 20–100 times normal levels; ALP is usually less than three times the normal level.

## AUTOIMMUNE HEPATITIS

**Epidemiology:** 70% of cases occur in females; most common in whites and Northern Europeans.

**Mechanism:** Evidence of immune dysfunction with elevated IgG. The disease is associated with other autoimmune conditions, and patients have anti-smooth muscle antibodies (most common type; also called type I autoimmune hepatitis) or anti-liver- kidney antibodies (also called type II autoimmune hepatitis).

**Complications:** Small number of cases progress to cirrhosis.

**Microscopic morphology of autoimmune hepatitis:** Same as chronic hepatitis (i.e., increased lymphocytes in the portal tracts).

## DRUGS AFFECTING THE LIVER

**Overview:** Many drugs can harm the liver, causing hepatocellular damage, cholestasis, vascular changes, or tumors.

### Important associations

- Acetaminophen: Causes necrosis of the centrilobular hepatocytes. Massive doses overwhelm the body's ability to reduce damaging substances, resulting in the accumulation of toxic metabolites. The time course is important to know relative to the level of the drug. A high drug level occurring farther from the time of ingestion will more likely indicate the possibility of severe liver damage.
- Vinyl chloride, thorotrast—angiosarcoma.
- Oral contraceptives—hepatic adenomas.
- Chlorpromazine—cholestasis.
- Halothane—fulminant hepatitis.
- Phenytoin, isoniazid—acute and chronic hepatitis.
- Methotrexate, amiodarone—fibrosis and cirrhosis.
- Sulfonamides—granulomas.

## ALCOHOLIC LIVER DISEASE

**Overview:** The three manifestations of alcoholic liver disease include hepatic steatosis, alcoholic hepatitis, and cirrhosis. Features of hepatic steatosis and alcoholic hepatitis are described below.

### HEPATIC STEATOSIS

**Overview:** Focal or diffuse; macrovesicular steatosis with chronic exposure or microvesicular steatosis with acute exposure.

#### Morphology of hepatic steatosis

- **Gross:** Yellow discoloration of liver parenchyma; can be patchy or involve entire liver (i.e., **diffuse fatty liver**) (Figure 15-8).
- **Microscopic:** Macrovesicular, microvesicular, or both (Figure 15-9).

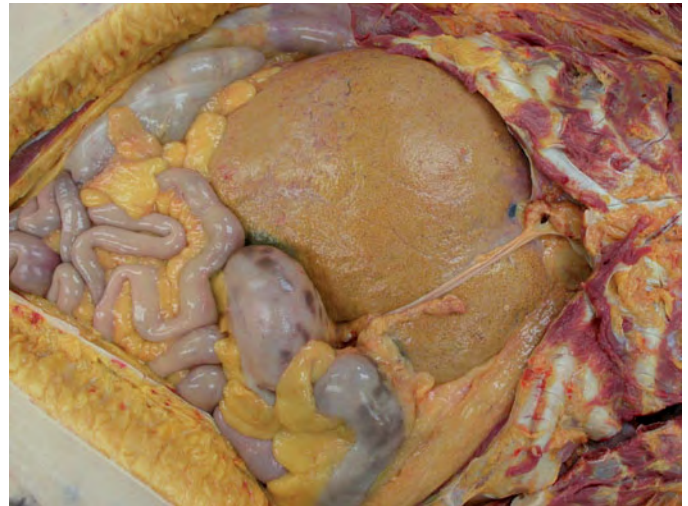
#### Clinical presentation of hepatic steatosis

- **Symptoms:** Can cause right upper quadrant tenderness and a sense of abdominal fullness.
- **Signs:** ALT and AST are more than five times normal levels.
- **Important point:** Hepatic steatosis is reversible.

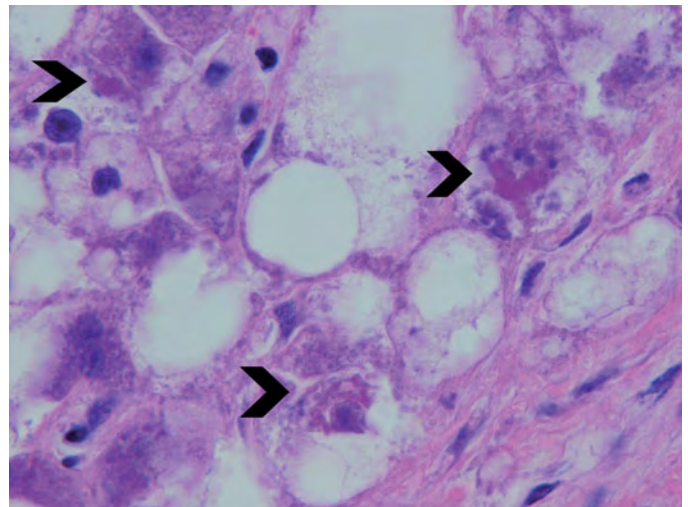
### ALCOHOLIC HEPATITIS

#### Microscopic morphology (Figure 15-10)

- Ballooning degeneration.
- Neutrophilic infiltrate.
- Sinusoidal and perivenular fibrosis.



**Figure 15-8.** Fatty liver. In some cases, the fatty change seen in alcoholics will involve the entire liver (i.e., diffuse fatty liver). Fatty liver can also occur with other processes producing hepatic steatosis, such as diabetes mellitus and obesity, and is referred to as nonalcoholic fatty liver disease.



**Figure 15-9.** Macrovesicular steatosis and Mallory hyaline. The ropey eosinophilic intracellular accumulations at the tip of the arrowheads are Mallory hyaline. Mallory hyaline is frequently associated with alcoholic liver disease, but can occur in other conditions as well. Some of the hepatocytes also have macrovesicular steatosis (i.e., one large fat vacuole in the cell). Hematoxylin and eosin, 1000 $\times$ .

- Mallory hyaline (i.e., accumulations of intermediate filaments) (see Figure 15-9). Mallory hyaline occurs in the liver of alcoholics other than just those with alcoholic hepatitis. Although Mallory hyaline is commonly associated with alcoholic liver disease, it does occur in other conditions as well.

#### Clinical presentation of alcoholic hepatitis

- **Symptoms:** Anorexia, nausea, vomiting, abdominal pain, jaundice.
- **Laboratory findings:** AST and ALT range from 200–400 U/L, with an AST to ALT ratio of 2:1 (in viral hepatitis, the two are increased in parallel).

### METABOLIC LIVER DISEASE

**Overview:** Metabolic liver diseases include nonalcoholic fatty liver disease, hemochromatosis, Wilson disease, and  $\alpha_1$ -antitrypsin deficiency. Features of these conditions will be discussed in this section.

#### NONALCOHOLIC FATTY LIVER DISEASE (NAFLD)

**Basic description:** Steatosis in the hepatocytes is not due to alcohol use.

**Causes:** Obesity, dyslipidemia, type 2 diabetes mellitus.

#### Complications of nonalcoholic fatty liver disease

- Hepatitis, referred to as **nonalcoholic steatohepatitis** (NASH); NASH is the most common cause of chronic hepatitis in the United States and Western Europe (Figure 15-11).
- Cirrhosis.

**Important point:** NAFLD may be an underlying cause of many cases of cirrhosis otherwise termed **cryptogenic cirrhosis**. The incidence of cases of NAFLD and NASH is dramatically rising in the United States.

#### HEREDITARY HEMOCHROMATOSIS

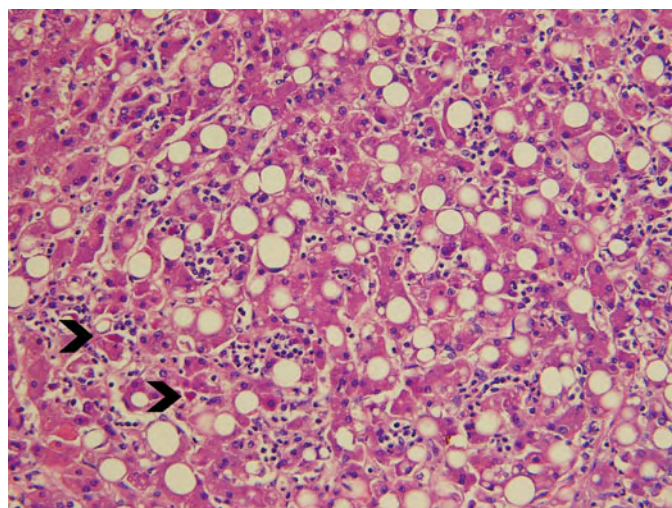
**Mutation:** *HFE* gene on chromosome 6 (6p21.3); only homozygous patients will develop complications.

**Epidemiology:** Whites; males of Northern European descent; male to female ratio of 5:1.

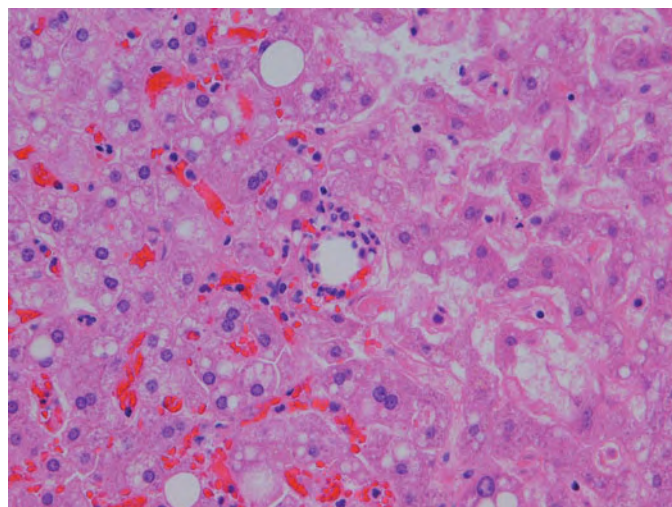
**Mechanism:** Increased absorption of iron from the intestines. *HFE* is an HLA class I-like molecule that regulates intestinal absorption of iron.

#### Complications of hereditary hemochromatosis

- Bronze discoloration of skin (caused by iron build-up in skin).
- Cirrhosis (Figure 15-12).
- Hepatocellular carcinoma (200 times greater risk than that of normal population).
- Damage to pancreas, causing diabetes mellitus.
- Arthropathy
- Accumulation of iron in the heart, causing either restrictive or dilated cardiomyopathy.



**Figure 15-10.** Alcoholic hepatitis. This low-power view of the liver exhibits a prominent neutrophilic infiltrate, macrovesicular steatosis, and Mallory hyaline (arrowheads), features that are consistent with the diagnosis of alcoholic hepatitis. Hematoxylin and eosin, 200 $\times$ .



**Figure 15-11.** Steatohepatitis. In the center of the photomicrograph is a fat vacuole in a hepatocyte surrounded by a ring of neutrophils. This is the characteristic histologic appearance of steatohepatitis. Nonalcoholic steatohepatitis is associated with conditions that include diabetes mellitus and obesity. Hematoxylin and eosin, 400 $\times$ .



**Important point regarding hereditary hemochromatosis:** The classic early symptoms of hemochromatosis are fatigue, loss of libido and impotence, and arthralgias or arthritis.

### SECONDARY HEMOCHROMATOSIS

**Causes:** Iron overload (e.g., chronic blood transfusions in anemic patients).

**Complications:** Similar to hereditary hemochromatosis.

### WILSON DISEASE

**Mutation:** *ATP7B* gene on chromosome 13.

**Mechanism:** Defective biliary excretion of copper.

#### Complications of Wilson disease

- **Liver pathology:** Fatty change, acute and chronic hepatitis, cirrhosis.
- **CNS pathology:** Atrophy and possible cavitation of the basal ganglia, especially the putamen. Psychiatric symptoms and extrapyramidal signs due to basal ganglia involvement are common.
- **Kayser-Fleischer rings:** Copper accumulation in Descemet membrane of the eye.

### $\alpha_1$ -ANTITRYPSIN DEFICIENCY

#### Complications

- Emphysema
- Cirrhosis: In all patients, the protein  $\alpha_1$ -antitrypsin accumulates in the liver, but only a small percentage of patients develop cirrhosis because they have impaired degradation of the protein.

**Microscopic morphology:** PAS-positive, diastase-resistant eosinophilic globules on liver biopsy.

## OBSTRUCTIVE BILIARY TRACT DISORDERS

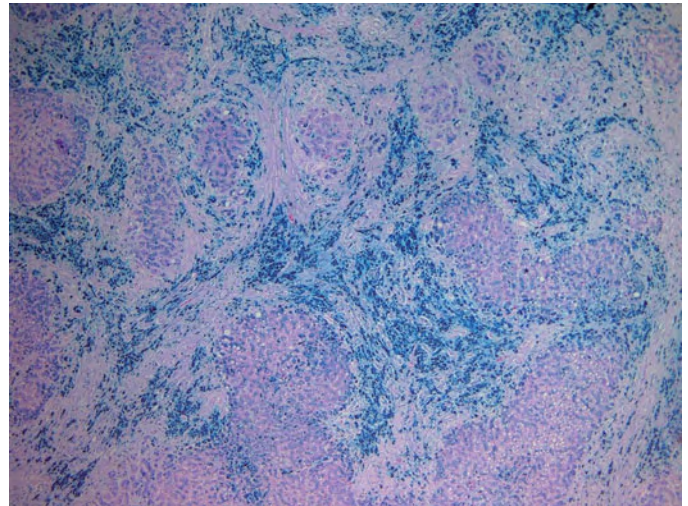
**Overview:** Obstruction of the biliary tract can be extrahepatic or intrahepatic. The most common cause of extrahepatic biliary tract disease is gallstones. Obstruction of the biliary tract with gallstones causes prominent bile stasis in bile ducts and bile duct proliferation. These changes can lead to **secondary biliary cirrhosis**. Two of the major causes of intrahepatic biliary tract disease are primary biliary cirrhosis and primary sclerosing cholangitis, which are discussed below.

### PRIMARY BILIARY CIRRHOSIS (TABLE 15-5)

**Epidemiology:** Middle-age females.

**Mechanism:** Autoimmune condition causing destruction of intrahepatic bile ducts, leading to inflammation and scarring.

**Associated antibody:** Antimitochondrial antibody; serum immunoglobulin M levels are also increased.



**Figure 15-12.** Cirrhosis due to hereditary hemochromatosis. In this section, the hepatic parenchyma is divided into nodules by fibrous septae. Within the fibrous septae are hemosiderin-laden macrophages (*blue staining cells*). Prussian blue, 40 $\times$ .

**TABLE 15-5.** Primary Biliary Cirrhosis Versus Primary Sclerosing Cholangitis

Feature	Primary Biliary Cirrhosis	Primary Sclerosing Cholangitis
Epidemiology	Female predominance	Male predominance
Associated antibody	Anti-mitochondrial	p-ANCA
Histology	Scarring of intrahepatic bile ducts	Fibrosis around bile ducts within portal tracts
Clinical features	Jaundice, pruritus	Fever, chills 70% of patients have ulcerative colitis

**Microscopic morphology of primary biliary cirrhosis**

- Lymphocytic infiltrate in portal tracts sometimes with granuloma formation, resulting in destruction of ducts (Figure 15-13).
- Bile duct proliferation.
- Cirrhosis, with hepatocyte nodules in a “jigsaw”-like pattern.

**Clinical presentation of primary biliary cirrhosis:** Fatigue, jaundice, and pruritus (due to cholestasis); elevated ALP, GGT, and bilirubin.

### PRIMARY SCLEROSING CHOLANGITIS (SEE TABLE 15-5)

**Epidemiology:** Male predominance; third to fifth decades.

**Mechanism:** Inflammation and fibrosis of intrahepatic and extrahepatic bile ducts, which leads to secondary biliary cirrhosis.

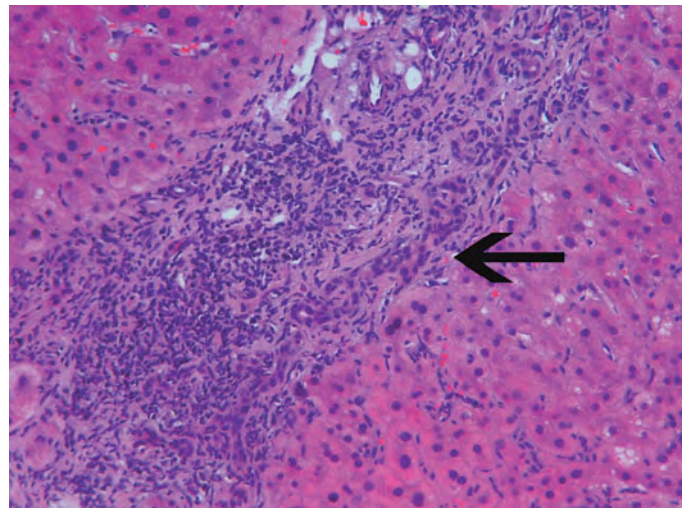
**Associated antibody:** p-ANCA.

**Associations:** Coexisting ulcerative colitis in 70% of patients.

**Microscopic morphology of primary sclerosing cholangitis:** Fibrosis around the bile ducts in the portal tract; segments of stenosis in the extrahepatic bile ducts.

**Clinical presentation of primary sclerosing cholangitis**

- **Signs and symptoms:** Vary from asymptomatic patients with abnormal liver enzymes to patients with recurring episodes of fever, chills, abdominal pain, and jaundice.
- **Diagnosis:** Alternating strictures produce “beads on a string” appearance on endoscopic retrograde cholangiopancreatography (ERCP).



**Figure 15-13.** Primary biliary cirrhosis. Note the prominent chronic lymphocytic infiltrate within the portal tract and the resultant damage of the bile duct (arrow). Hematoxylin and eosin, 400×.

## CIRCULATORY DISORDERS OF THE LIVER

**Overview:** There are three main mechanisms by which circulatory disorders of the liver occur: impairment of blood flow to the liver, through the liver, or out of the liver.

**Impaired blood flow into the liver**

**Causes:** Portal vein obstruction, hepatic artery compromise, polyarteritis nodosa, emboli.

**Specific cause: Portal vein thrombosis**

- **Causes of portal vein thrombosis:** Cirrhosis, peritoneal sepsis, tumor metastases, trauma.
- **Complications of portal vein thrombosis:** Features of portal hypertension (see above discussion of complications of cirrhosis).

**Causes of impaired blood flow through the liver**

- Cirrhosis, because of portal hypertension.
- Occlusion of sinusoids by thrombi in disseminated intravascular coagulation (DIC) and by sickled cells in sickle cell anemia.
- **Peliosis hepatitis:** Primary dilation of sinusoids due to anabolic steroid use.
- Passive congestion and centrilobular necrosis due to right-sided heart failure; shock.

**Cause of hepatic vein outflow obstruction: Budd-Chiari syndrome and veno-occlusive disease****Hepatic vein thrombosis (also called Budd-Chiari syndrome)**

- **Causes of Budd-Chiari syndrome:** Polycythemia rubra vera, pregnancy, oral contraceptives, coagulation disorders, and factor V Leiden.
- **Morphology of Budd-Chiari syndrome:** Thrombi in hepatic veins and inferior vena cava; severely congested parenchyma.
- **Clinical presentation of Budd-Chiari syndrome**
  - **Acute form:** Right upper quadrant pain, hepatomegaly, and ascites.
  - **Chronic form:** Features of portal hypertension (see above discussion of complications of cirrhosis).

**Veno-occlusive disease**

**Epidemiology:** Most commonly occurs in bone marrow transplantation patients.

**Clinical findings:** Tender hepatomegaly, ascites, weight gain, and jaundice. Diagnosis is made presumptively, not wishing to risk liver biopsy.

**Mechanism of veno-occlusive disease:** Obliteration of hepatic vein radicles by fibrosis.

## LIVER NEOPLASMS

**Overview:** The most common neoplasm affecting the liver is a metastasis. In decreasing order of occurrence, the common sources of the liver metastases are lung, colon, pancreas, breast, and stomach carcinomas.



**Types of primary liver tumors:** Seven types of primary liver tumors, all discussed below, are hepatocellular carcinoma, cholangiocarcinoma, focal nodular hyperplasia, hepatic adenoma, hemangioma, hepatoblastoma, and angiosarcoma.

### HEPATOCELLULAR CARCINOMA (HCC)

**Epidemiology:** Usually occurs in older patients (> 60 years), but depends upon risk factors.

#### Risk factors for development of hepatocellular carcinoma

- In almost all cases (85–90%), HCC arises in the background of cirrhosis; therefore, HBV and HCV, Wilson disease, hemochromatosis, and chronic alcoholism are risk factors.
- *Aspergillus flavus* (produces aflatoxin)

**Important points:** HCC is known for its propensity for blood vessel invasion (e.g., portal vein and inferior vena cava).

**Complications of hepatocellular carcinoma:** Death occurs through cachexia, gastrointestinal hemorrhage, rupture of tumor, liver failure, and hepatic coma.

#### Morphology of hepatocellular carcinoma (Figure 15-14 A and B)

- **Gross:** Tumor may be unifocal, multifocal, or diffuse.
- **Microscopic:** The more well-differentiated forms look like hepatocytes and can produce bile as well as manifest accumulations of fat (steatosis) and Mallory hyaline.

#### Clinical presentation of hepatocellular carcinoma

- **Symptoms:** Abdominal pain, abdominal mass, weight loss, and deterioration of liver function.
- **Signs:** Increased  $\alpha$ -fetoprotein (> 400 ng/mL).

### CHOLANGIOCARCINOMA (FIGURE 15-15)

**Basic description:** Tumor of the bile ducts.

#### Risk factors

- Primary sclerosing cholangitis.
- *Opisthorchis sinensis* infection.
- Thorotrast.

**Important point:** Cholangiocarcinoma in combination with HCC can occur in patients in one of three forms: (1) two separate tumors; (2) a collision tumor; or (3) a mixed tumor.

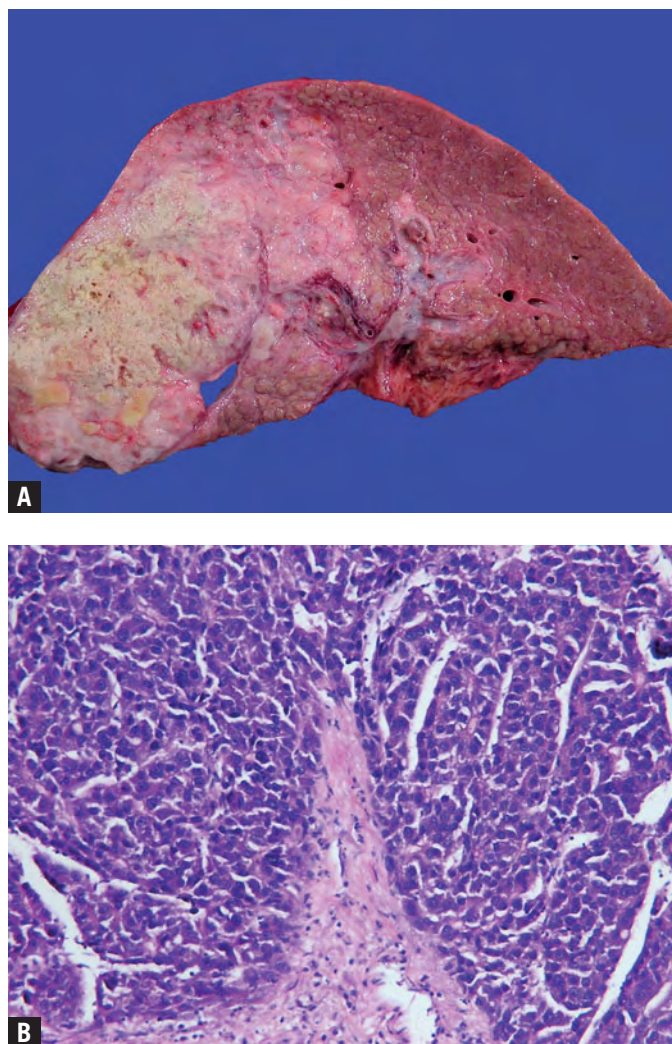
### FOCAL NODULAR HYPERPLASIA

**Basic description:** Benign tumor; has histologic features similar to cirrhosis.

**Epidemiology:** Female predominance; young to middle-aged adults.

#### Morphology of focal nodular hyperplasia

- **Gross:** Nodule with central scar (Figure 15-16).
- **Microscopic:** Nodules of hepatocytes, divided by fibrous septae with bile ductular proliferation within the fibrous septae.



**Figure 15-14.** Hepatocellular carcinoma. **A**, A cross-section of a cirrhotic liver, with a hepatocellular carcinoma that occupies the majority of the left side of the section. **B**, Hepatocellular carcinoma is a highly aggressive malignant neoplasm, but histologically may resemble its cell of origin (i.e., the hepatocyte). Some hepatocellular carcinomas produce fat, bile, and even Mallory hyaline. Hematoxylin and eosin, 200 $\times$ .

### HEPATIC ADENOMA

**Basic description:** Benign proliferation of hepatocytes.

**Epidemiology:** Young women using oral contraceptives.

**Complications:** Can rupture and can harbor hepatocellular carcinoma.

**Microscopic morphology of hepatic adenoma:** Nodules of hepatocytes with fibrous septae; no bile duct proliferation within fibrous septae.

### HEMANGIOMA

#### Important points

- Common incidental tumor of the liver.
- Could rupture, causing hemoperitoneum.

**Microscopic morphology of hemangioma:** Usually cavernous type (i.e., large spaces filled with red blood cells) (Figure 15-17 A and B).

### HEPATOBLASTOMA

**Epidemiology:** Children.

**Genetic abnormality:** Activation of Wnt/ $\beta$ -catenin signaling pathway by a mutation of the  $\beta$ -catenin gene in 80% of tumors.

**Microscopic morphology of hepatoblastoma:** There are two types of hepatoblastoma, each with a different microscopic appearance.

- **Epithelial type:** Composed of small cells resembling fetal and embryonal cells.
- **Mixed epithelial and mesenchyma type:** Have epithelial cells and mesenchymal stroma (e.g., bone, cartilage, muscle).

### ANGIOSARCOMA

**Basic description:** Malignant tumor of blood vessels.

**Causes:** Vinyl chloride, thorotrast, arsenic.


### CHOLELITHIASIS

**Overview:** Cholelithiasis is stones (calculi) in the gallbladder. There are two types of gallstones, cholesterol and pigment (bilirubin and calcium salts), or gallstones can be a mixture of the two types.

**Mechanism of formation of cholesterol stones:** There is supersaturation of bile with cholesterol. Cholesterol is not dispersed and cholesterol is toxic to the gallbladder, promoting hypomotility, which results in nucleation of cholesterol. Hypersecretion of mucus traps cholesterol crystals, forming stones.

**Mechanism of formation of pigment stones:** Less well understood.

**Risk factors for cholesterol gallstones:** Obesity, female, fertile, older than 40 years of age, and Native American or Hispanic ancestry.



**Figure 15-15.** Cholangiocarcinoma and hepatocellular carcinoma in a cirrhotic liver. As sometimes occurs, both cholangiocarcinoma (arrowheads) and hepatocellular carcinoma (arrows) developed in this cirrhotic liver. An antemortem biopsy of the liver was diagnosed as metastatic adenocarcinoma, which is not unexpected since cholangiocarcinoma cannot be reliably diagnosed via histologic or immunohistochemical stains, and many times is a diagnosis of exclusion.



**Figure 15-16.** Focal nodular hyperplasia. The well-circumscribed solitary nodule in this non-cirrhotic liver has a central scar, characteristic of focal nodular hyperplasia.



**Risk factors for pigment stones:** Hemolysis (i.e., elevated levels of unconjugated bilirubin), biliary infection.

#### Complications of gallstones

- **Acute and chronic cholecystitis** (Figure 15-18).
- **Choledocholithiasis** (i.e., stone in the duct): May be asymptomatic or may produce biliary colic, jaundice, cholangitis, or pancreatitis (Figure 15-19).
- **Gallstone ileus** (i.e., stone enters the small intestine and causes an obstruction).
- **Fistula** (abnormal connection between the gallbladder or bile duct and the small intestine).
- **Adenocarcinoma of the gallbladder.**

#### Clinical presentation of cholelithiasis

- **Symptoms:** 50–60% of patients are asymptomatic.
- **Radiograph:** Cholesterol stones are radiolucent; pigment stones are radiopaque.

## CHOLECYSTITIS

**Overview:** Inflammation of the gallbladder, which occurs as one of three types: acute calculous, acute acalculous, and chronic cholecystitis.

### ACUTE CALCULOUS CHOLECYSTITIS (FIGURE 15-18)

**Cause:** Gallstones.

**Pathogenesis:** Irritation and inflammation of the gallbladder in the background of obstruction of bile flow. Disruption of the mucous layer occurs, which exposes epithelium to detergent effects of the bile.

#### Clinical presentation of acute calculous cholecystitis

- **Symptoms:** Acute onset of upper abdominal pain that lasts for several hours, gradually increasing in severity. Nausea and vomiting and low-grade fever are common. Unlike pain of chronic cholecystitis, the pain of acute calculous cholecystitis does not subside spontaneously.
- **Signs: Murphy sign**, indicated by respiratory arrest on palpation of the right upper quadrant. Patients can have fever and mild jaundice.

### ACUTE ACALCULOUS CHOLECYSTITIS

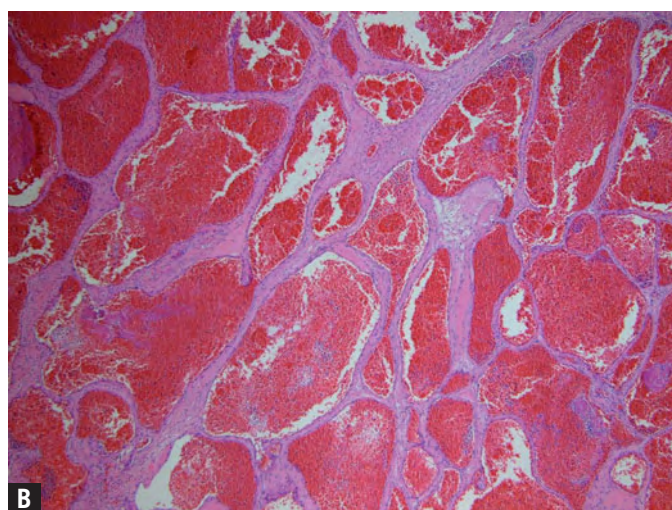
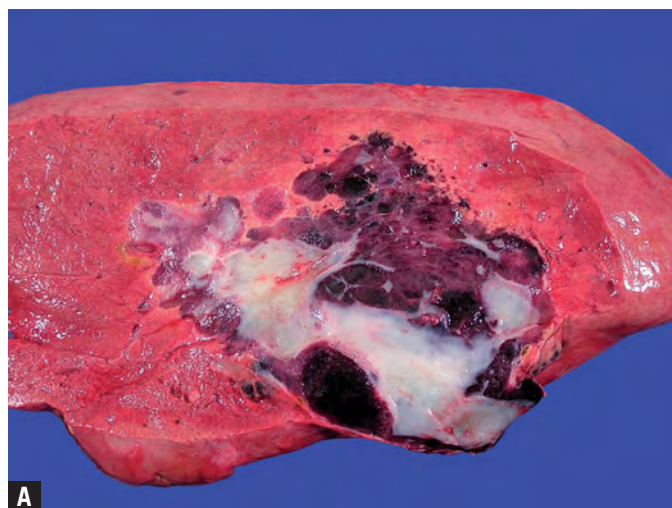
**Causes:** Major surgery, severe trauma, severe burns, sepsis.

**Mechanism of acute acalculous cholecystitis:** Dehydration, gallbladder stasis, and bile sludging in combination with vascular insufficiency produce ischemia of the gallbladder.

## CHRONIC CHOLECYSTITIS

**Mechanism:** Supersaturation of bile predisposes to chronic inflammation and stone formation.

**Important point:** Clinically, the symptoms of chronic cholecystitis are better referred to as **biliary pain**, since there is poor correlation between symptoms and pathologic findings.



**Figure 15-17.** Hemangioma of the liver. **A**, A cross-section of the liver, with a large (10 cm) hemangioma. The white tissue within the tumor mass is scar, associated with degeneration of a long-standing, slow-growing neoplasm. **B**, Large spaces filled with red blood cells, divided by thin fibrous septae. This histology is consistent with a cavernous hemangioma. In adults, most hemangiomas have similar histologic architecture. Hematoxylin and eosin, 40 $\times$ .



**Clinical presentation of chronic cholecystitis:** Steady ache of sudden onset in the right upper quadrant of the abdomen, reaching a plateau over a few minutes and subsiding over 30 minutes to a few hours. Patients may have nausea and vomiting.

#### Gross morphology of cholecystitis

- **Acute cholecystitis:** Thick, edematous wall of the gallbladder, with red discoloration.
- **Chronic cholecystitis:** Thick wall of gallbladder.

#### Microscopic morphology of cholecystitis

- **Acute cholecystitis:** Infiltration of the wall of the gallbladder with neutrophils; necrosis of epithelium.
- **Chronic cholecystitis:** **Rokitansky-Aschoff sinuses** (i.e., down-pouching of epithelium through muscularis).

### ASCENDING ACUTE CHOLANGITIS

**Overview:** Cholangitis is acute inflammation of the bile ducts. Once bacteria are within the duct, they tend to spread upward (ascending) into the intrahepatic bile ducts.

**Common causative organisms:** Include gram-negative rods (e.g., *Escherichia coli*, *Klebsiella*); in the Middle East, the parasites *Clonorchis sinensis* and *Opisthorchis viverrini* are common causative organisms.

#### Causes

- **Most common:** Choledocholithiasis.
- **Other causes:** Tumors; indwelling stents.

#### Complications of ascending acute cholangitis

- Development of suppurative cholangitis and liver abscess.
- Sepsis, shock, and death.

**Clinical presentation of ascending acute cholangitis: Charcot triad,** features of which are abdominal pain, jaundice, and fever. It is more common in elderly patients, and is often associated with hypotension and altered mental status.

### ADENOCARCINOMA OF THE GALLBLADDER

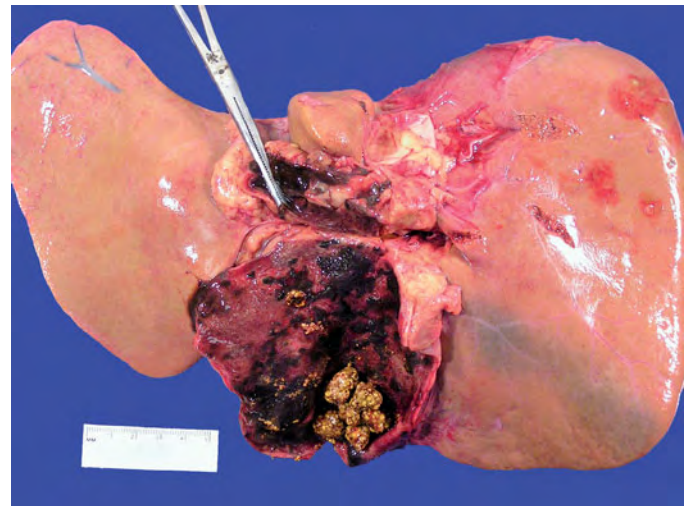
**Epidemiology:** Seventh decade of life.

**Risk factors:** Include gallstones, parasitic disease of the bile tract, and porcelain gallbladder.

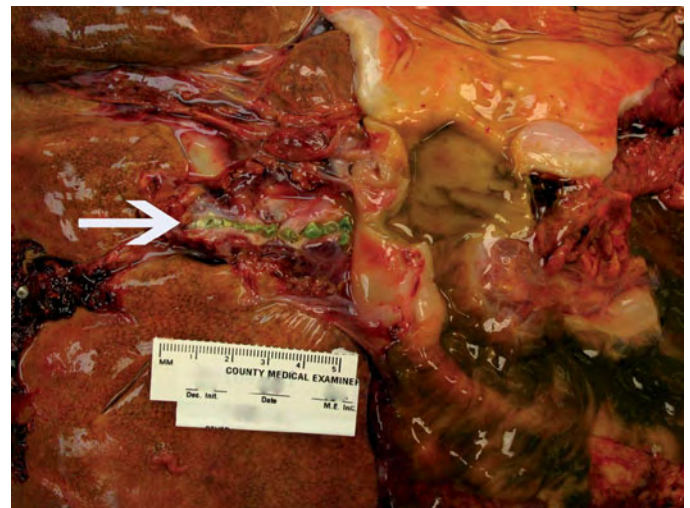
**Prognosis:** Poor; few cases are discovered in time for prompt and curative resection.

#### Important points

- More common than tumors of the bile ducts.
- Most often discovered postoperatively (e.g., after a cholecystectomy). Most tumors have invaded adjacent structures at the time of diagnosis.



**Figure 15-18.** Acute cholecystitis and cholelithiasis. This gallbladder has been opened, revealing a thick edematous wall and an inflamed mucosa (acute cholecystitis). These inflammatory changes are due to the several calculi within the lumen of the gallbladder. Based upon their appearance (yellow), the calculi are most likely composed predominantly of cholesterol.



**Figure 15-19.** Choledocholithiasis. When calculi in the gallbladder are small enough, they can exit the gallbladder and become entrapped in the cystic duct or common bile duct (arrow). Choledocholithiasis can lead to inflammation of the bile ducts, causing ascending cholangitis.

## PATHOLOGY OF THE PANCREAS

**Overview:** Although there are other diseases of the pancreas, the three most important conditions affecting the pancreas are acute and chronic pancreatitis and pancreatic neoplasms (most importantly pancreatic adenocarcinoma and islet cell tumors), which are discussed here. Pancreatic cysts will also be discussed briefly in this section.

### ACUTE PANCREATITIS (FIGURE 15-20 A and B)

#### **Causes**

- *The two most common causes of acute pancreatitis are alcohol use and gallstones.*
- **Other causes:** Hypercalcemia, hypertriglyceridemia, drugs (e.g., thiazide diuretics, estrogen), trauma, steroids, and autoimmune disease.

**Mechanism of acute pancreatitis:** Uncontrolled activation of pancreatic enzymes.

**Complications:** Chronic pancreatitis, pseudocysts.

#### **Clinical presentation of acute pancreatitis**

- **Signs and symptoms:** Acute epigastric abdominal pain, radiating to the back; anorexia and nausea.
- **Laboratory findings:** Elevated amylase and lipase levels (lipase is more sensitive than amylase). Amylase remains elevated for 4–7 days, whereas lipase remains elevated for a longer time period. Hypocalcemia and leukocytosis are common.

**Ranson criteria** are used to predict severity of acute pancreatitis and include two general categories: those at presentation, and those within 48 hours of presentation. The presence of three or more criteria indicates severe pancreatitis.

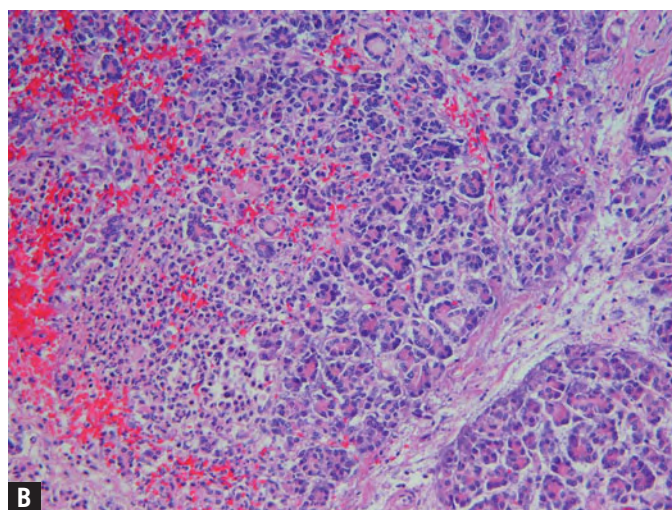
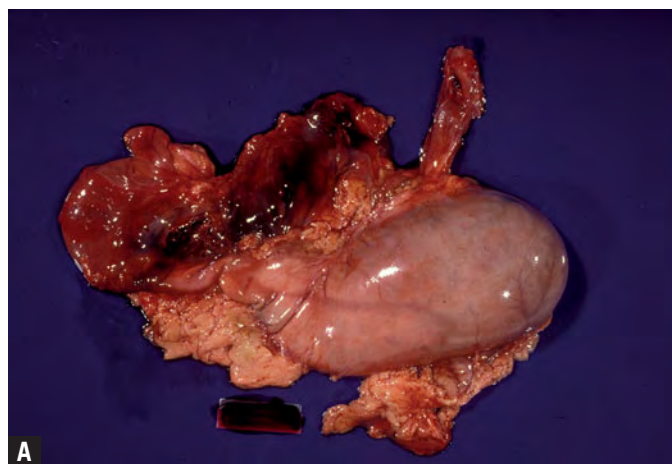
#### ■ **At presentation**

- Age: Older than 55 years.
- Blood glucose level of  $> 200$  mg/dL.
- White cell count of  $> 16,000/\text{mm}^3$ .
- Lactate dehydrogenase of  $> 350$  IU/L.
- Alanine aminotransferase of  $> 250$  IU/L.

#### ■ **Within 48 hours of presentation**

- Hematocrit:  $> 10\%$  decrease.
- Serum calcium  $< 8$  mg/dL.
- Base deficit of  $> 4$  mEq/L.
- BUN of  $> 5$  mg/dL.
- Fluid sequestration of  $> 6$  L.
- Partial pressure of arterial oxygen of  $< 60$  mm Hg.

**Important point:** Acute pancreatitis is a severe systemic disorder; it causes diffuse alveolar damage and disseminated intravascular coagulation (DIC).



**Figure 15-20.** Acute hemorrhagic pancreatitis. In this block of organs (A), the esophagus and stomach are present as well as the pancreas (the pancreas is the hemorrhagic mass above the stomach). Acute pancreatitis is most commonly due to gallstones or alcohol use, and is a potentially life-threatening condition that causes widespread systemic changes, including diffuse alveolar damage and disseminated intravascular coagulation. In (B), note the neutrophilic infiltrate and hemorrhage within the pancreatic parenchyma. Hematoxylin and eosin, 200 $\times$ .



### CHRONIC PANCREATITIS (FIGURE 15-21 A and B)

**Causes:** In many patients, chronic pancreatitis is the result of recurring bouts of acute pancreatitis due to causes such as alcohol abuse and gallstones.

**Complications:** Diabetes mellitus and malabsorption

**Clinical presentation of chronic pancreatitis:** Weight loss, abdominal pain, and symptoms associated with malabsorption, such as diarrhea.

### PANCREATIC CYSTS

■ **True cysts:** True cysts of the pancreas (i.e., those with epithelial lining) are seen in patients with polycystic kidney disease.

■ **Pseudocysts:** No epithelial lining; seen as a result of acute pancreatitis; most commonly in alcoholics.

**Pancreatic neoplasms:** Features of pancreatic adenocarcinoma and islet cell tumors, the two most common pancreatic neoplasms, are discussed below.

### PANCREATIC ADENOCARCINOMA

**Epidemiology:** 60–80 years of age.

**Risk factor:** Smoking.

**Prognosis:** Poor; most patients do not survive more than 5 years after diagnosis.

**Location of tumor:** Most are in the head of the pancreas.

**Clinical presentation of pancreatic adenocarcinoma**

■ **Symptoms:** Abdominal pain radiating to the back; weight loss as a result of malabsorption and anorexia.

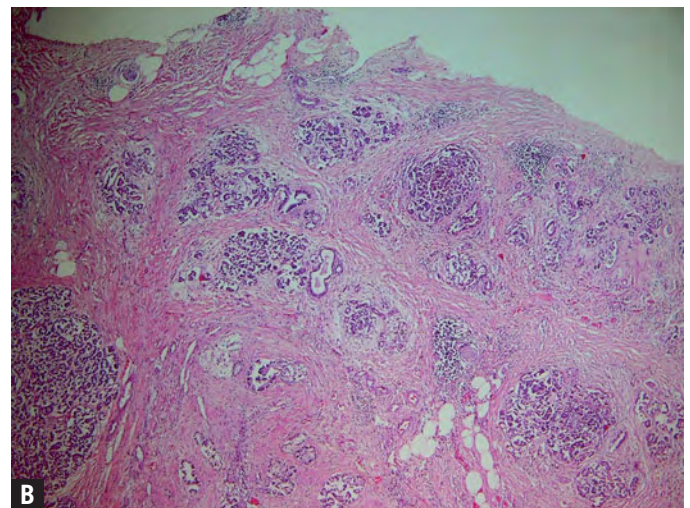
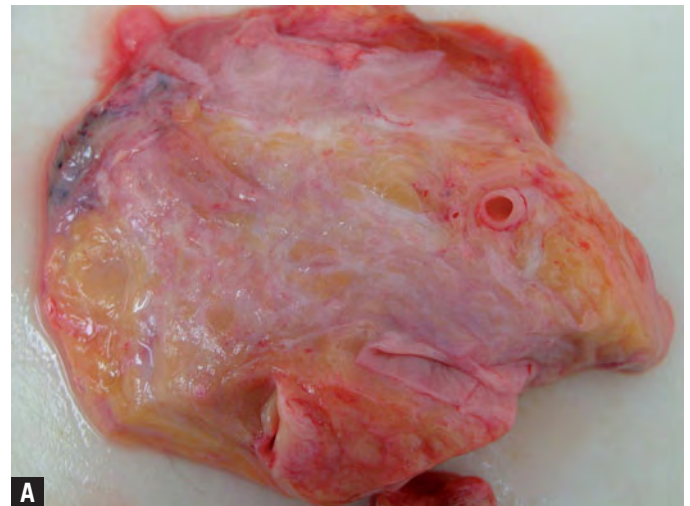
■ **Signs:** Obstructive jaundice with palpable gallbladder (i.e., **Courvoisier sign**). Dilated proximal pancreatic duct on CT and MRI. Elevated CA19-9.

**Important points**

- **Trousseau syndrome:** Migratory thrombophlebitis.
- Pancreatic adenocarcinoma is known for perineural invasion (painful).
- If pancreatic adenocarcinoma occurs in the ampulla, patients can present with jaundice. Because of the early production of symptoms, the tumor can be resected at an early stage (i.e., when it is small), and patients then have a better prognosis. In contrast, a tumor in the tail can grow large before it presents with symptoms, and patients have a poor prognosis.

### ISLET CELL TUMOR

**Important points:** Most islet cell tumors are benign (i.e., do not invade or metastasize), but they can produce insulin or glucagon and have systemic effects. Insulinomas (i.e., a type of islet cell tumor that produces insulin) usually cause hypoglycemia with an elevated C-peptide level. About 5% of cases are associated with MEN 1.



**Figure 15-21.** Chronic pancreatitis. **A**, Note the loss of pancreatic parenchyma and its replacement with fibrosis. Chronic pancreatitis is not an immediately life-threatening condition as is acute pancreatitis; however, it can lead to secondary diabetes mellitus and malabsorption, depending upon its extent. **B**, Note the loss of pancreatic glandular parenchyma and its replacement with fibrosis (the glandular parenchyma should be back to back). The islets are resistant to the changes and, in cases of chronic pancreatitis, only clusters of pancreatic islets may be present among the fibrosis. Hematoxylin and eosin, 40 $\times$ .



*This page intentionally left blank*

A detailed scanning electron micrograph (SEM) of kidney tissue, showing the complex, textured surface of a glomerulus and the surrounding tubular structures. The image is in grayscale, highlighting the intricate three-dimensional architecture of the renal tissue.

## CHAPTER 16

# PATHOLOGY OF THE KIDNEY AND BLADDER

### OVERVIEW

In this chapter, the pathology of the kidney is organized into four anatomic categories: diseases of the glomeruli, tubules, interstitium, and vessels. Diseases that affect the glomeruli often have an immunologic etiology, whereas those that affect the tubules and interstitium usually have an infectious or toxic etiology. Early in the disease process, most disorders predominantly affect one of the anatomic structures listed above. Over time, however, the entire kidney usually becomes diseased. Because of the large physiologic reserve of the kidneys, many diseases do not become clinically apparent until the majority of the organ is affected, making subtle abnormalities in laboratory findings the only early indication of renal disease. Recognition of these patterns of abnormalities, pathologic findings, and clinical presentation is perhaps more important to renal pathology than in any other organ system. This chapter describes acute and chronic renal failure, disorders of volume regulation, glomerular diseases, tubulointerstitial diseases, nephrolithiasis, cystic diseases of the kidney, renal tumors, pathology of the bladder, acid-base disorders, and electrolyte disorders.

### ACUTE RENAL FAILURE

**Overview:** Acute renal failure is rapid onset of **azotemia** (i.e., elevated blood urea nitrogen [BUN] and creatinine [Cr]) combined with oliguria or anuria. Azotemia can occur by itself, in which case a patient has an elevated BUN and creatinine but normal urine output. Therefore, the difference between azotemia and acute renal failure is the amount of urine output (normal with azotemia; decreased or absent with acute renal failure). There are three types of acute renal failure and azotemia: **prerenal**, **intrinsic** (i.e., **renal**), and **postrenal**, which are based upon the location of the source of the azotemia or acute renal failure. To simplify the following discussion, the three forms will be listed as prerenal azotemia, intrinsic azotemia, and postrenal azotemia; however, remember that azotemia and acute renal failure are technically on a spectrum defined by urine output. For example, the listed causes of prerenal azotemia can also lead to acute renal failure.

### PRERENAL AZOTEMIA

**Basic description:** Source of azotemia originates proximal to the kidney.

**Causes:** Low-volume stimulus caused by hypovolemia, heart failure, sepsis, and renal vascular pathology (e.g., atherosclerosis, fibromuscular dysplasia).

**Important point regarding prerenal azotemia:** In prerenal azotemia, the kidney functions normally and responds to a perceived low-volume stimulus by reabsorption of sodium ( $\text{FENa} < 1\%$ ), water, and urea. Because creatinine is filtered and secreted by the tubules, and urea is filtered and reabsorbed, the low-volume stimulus in prerenal azotemia causes a rise in serum BUN out of proportion to the rise in serum creatinine. Therefore, in the absence of other causes of alterations in BUN and creatinine (e.g., gastrointestinal bleed, rhabdomyolysis), the BUN/Cr ratio is usually  $> 20$ .

### INTRINSIC AZOTEMIA

**Basic description:** Source of azotemia originates within the kidney.

**Causes:** Acute tubular necrosis (toxic or ischemic type), glomerular disease, acute interstitial nephritis.

**Important point:** Intrinsic azotemia implies dysfunction of the kidney itself. In the setting of a normal kidney, oliguria would be expected to be accompanied by avid sodium retention. Intrinsic azotemia, however, is characterized by  $\text{FENa} > 1\%$  due to impaired tubular function. The BUN/Cr ratio is  $< 20$  because of normal hemodynamics.

### POSTRENAL AZOTEMIA

**Basic description:** Azotemia due to obstruction of the urinary tract. The source of renal failure originates distal to the kidney.

**Causes:** Urethral, bladder, or prostatic obstruction; kidney stones.

**Important points:** Urinary obstruction may be accompanied by complete anuria, oliguria, or normal urinary output. Tubular dysfunction in the setting of partial obstruction may even cause polyuria. Renal ultrasound is the diagnostic test of choice in postrenal azotemia and can identify hydronephrosis and most stones.

#### Complications of acute renal failure

- **Electrolyte disturbances:** Hyponatremia, hyperkalemia, hyperphosphatemia, and hypocalcemia. Hypocalcemia is a result of the high phosphate level.
- Metabolic acidosis.
- Gastrointestinal hemorrhage, sepsis, and heart failure, which represent many of the causes of death due to acute renal failure.

#### Clinical presentation of acute renal failure (Table 16-1)

- **Signs and symptoms:** Oliguria ( $< 400$  mL of urine per day), lethargy, fatigue, and nausea.

**TABLE 16-1.** Laboratory Diagnosis of Acute Renal Failure

Laboratory Test	Prerenal Acute Renal Failure	Intrinsic Renal Failure
$\text{FENa}$	$< 1\%$	$> 1\%$
BUN/Cr ratio	$> 20:1$	$< 20:1$
Urine sodium	$< 20$ mEq/L	$> 20$ mEq/L
Urine osmolality	$> 500$ mOsm/kg	$< 400$ mOsm/kg
Specific gravity	$> 1.020$	$< 1.010$

$\text{FENa}$ , fractional excretion of sodium; BUN, blood urea nitrogen; Cr, creatinine.



**Laboratory evaluation**

- **Prerenal failure:** BUN/Cr ratio  $> 20:1$ .
- **Intrinsic failure:** BUN/Cr ratio  $< 20:1$ .

**Urine sodium level**

- **In prerenal failure:**  $< 20$  mEq/L.
- **In intrinsic renal failure:**  $> 20$  mEq/L, because the kidney cannot absorb sodium.

**Urine osmolality and specific gravity**

- **In prerenal failure:** Urine osmolality is  $> 500$  mOsm/kg. Urine specific gravity is  $> 1.020$ , because the kidney is absorbing as much water as possible.
- **In intrinsic renal failure:** Urine osmolality is  $< 400$  mOsm/kg, and urine specific gravity is  $< 1.010$ .

**Fractional excretion of sodium** (a very sensitive test)

- **Prerenal failure:**  $< 1\%$ .
- **Intrinsic renal failure:**  $> 1\%$ .

## CHRONIC RENAL FAILURE

**Basic description:** Symptoms of acute renal failure with longer duration. The term **uremia** indicates the presence of clinical symptoms in the background of chronic renal failure.

**Causes:** The most common causes of chronic renal failure are diabetes mellitus, hypertension, and glomerulonephritis.

**Four stages of chronic renal failure** (in order of appearance)

1. **Diminished renal reserve:** Glomerular filtration rate (GFR) = 50%.
2. **Renal insufficiency:** GFR is 20–50% of normal. Signs and symptoms include azotemia, hypertension, anemia, and polyuria. The polyuria is a result of decreased concentrating ability.
3. **Renal failure:** GFR is  $< 20\%$ . Signs and symptoms include edema and metabolic acidosis.
4. **End-stage renal disease:** GFR is  $< 5\%$ .

**Clinical presentation of chronic renal failure**

■ **Signs and symptoms:** Fatigue, nausea and vomiting, wasting, hypertension, edema.

**Laboratory findings**

- **Electrolytes:** Increased phosphate, decreased calcium, increased potassium.
- **BUN and creatinine:** Increased.
- Metabolic acidosis, because of decreased bicarbonate ( $\text{HCO}_3^-$ ).
- Urine specific gravity of  $< 1.010$ .

**Complications of uremia occurring during chronic renal failure**

- **Cardiac:** Pericarditis, congestive heart failure, hypertension.
- **Hematologic:** Normocytic normochromic anemia, platelet dysfunction, increased susceptibility to infection.
- **Gastrointestinal:** Nausea, vomiting, anorexia.

- **Central nervous system (CNS):** Polyneuropathy, encephalopathy.
- **Skeletal:** Renal osteodystrophy, because of decreased production of active vitamin D (vitamin D is normally activated in the kidney), and hyperparathyroidism secondary to phosphate retention and hypocalcemia.

## VOLUME DISORDERS

**Overview:** The two forms of volume disorders, volume depletion and volume excess, will be discussed below, followed by details regarding the laboratory distinction of the two disorders.

### VOLUME DEPLETION

#### Clinical presentation

- **In mild volume depletion:** Orthostatic dizziness; tachycardia.
- **In severe volume depletion:** Hypotension, mental obtundation, cool extremities, severe oliguria.
- **Important point:** Oliguria is the earliest and most sensitive clinical indication of hypovolemia.

#### Causes of volume depletion

- **Gastrointestinal causes of volume depletion:** Bleeding, vomiting, diarrhea.
- **Renal causes of volume depletion**
  - **Due to loss of salt and water:** Diuretics; acute tubular necrosis.
  - **Due to loss of water:** Diabetes insipidus.
- **Skin and respiratory causes of volume depletion:** Sweat; burns.

### CAUSES OF VOLUME EXCESS

- **Primary renal sodium retention** (associated with increased effective circulating volume): Acute renal failure, Cushing syndrome, hyperaldosteronism.
- **Secondary renal sodium retention:** Heart failure, liver disease, nephrotic syndrome. In these edematous states, the excess volume is sequestered outside the arterial system. This causes a persistent low-volume stimulus to which the kidney responds by retaining water, leading to hyponatremia.

#### Laboratory studies to help determine cause of volume disorder

##### 1. Urine osmolality

- **Increased in:** Addison disease, congestive heart failure, shock, hypovolemia, syndrome of inappropriate antidiuretic hormone (SIADH).
- **Decreased in:** Hyperaldosteronism, diabetes insipidus, excess fluid intake, renal tubular necrosis.

##### 2. Serum osmolality

- **Increased in:** Dehydration, diabetes insipidus, increased glucose, hypernatremia, methanol intoxication, ethylene glycol intoxication, uremia.
- **Decreased in:** Excess fluid intake, hyponatremia, SIADH.

## GLOMERULAR DISORDERS

**Overview:** This section will cover terminology, histologic techniques used to evaluate glomeruli, and clinical manifestations and general pathogenesis of glomerular disorders.

### Terms

- **Segmental:** A portion of a glomerulus is involved.
- **Global:** All of a glomerulus is involved.
- **Focal:** Some of the glomeruli are involved.
- **Diffuse:** All or almost all of the glomeruli are involved.

**Techniques used to evaluate glomeruli:** Light microscope, immunofluorescence, electron microscope.

### Light microscopy (stains utilized)

- **Periodic acid–Schiff (PAS)** stain: Highlights basement membrane and mesangium.
- **Trichrome** stain: Highlights fibrosis.
- **Silver** stain: Highlights basement membrane.

### Immunofluorescence (using IgG, IgM, IgA)

- Pattern (linear or granular) and Ig type that is positive are important diagnostic features.
- **Microscopic morphology**
  - **Linear pattern:** Result of reaction of antibody (with immunofluorescent tag) with pathogenic antibody directed against antigen in the glomerular basement membrane (e.g., in Goodpasture syndrome).
  - **Granular pattern:** Result of reaction of antibody (with immunofluorescent tag) with pathogenic antigen–antibody complexes deposited in the glomerular basement membrane (e.g., in systemic lupus erythematosus [SLE]).

**Electron microscopy:** Allows for the detection and determination of the location of immune complex deposits and for evaluation of the basement membrane (e.g., in asymptomatic hematuria).

### Clinical manifestations of glomerular disease

- Acute nephritic syndrome.
- Nephrotic syndrome.
- Rapidly progressive glomerulonephritis (RPGN).
- Chronic renal failure.
- Asymptomatic hematuria.

### General pathogenesis of glomerular injury

- Most glomerular diseases are immunologic in origin. They are the result of either the deposition of immune complexes or the result of antibodies directly binding to antigens in the kidney. The antigens that trigger the antibodies can be exogenous (e.g., in hepatitis B or C) or endogenous (e.g., in DNA in SLE).
- The immune complexes activate complement. C5a acts as a chemoattractant for neutrophils. C5b-9 forms the membrane attack complex, which is believed to activate mesangial and epithelial cells, causing them to release proteases. The production of radical intermediates by the attracted inflammatory



cells and the production of proteases are both thought to play a role in glomerulonephritis.

- The immune complexes can be degraded and renal function recovered if the inciting condition is brief, or can lead to chronic renal failure if the inciting condition is ongoing (e.g., in SLE).

## NEPHROTIC SYNDROME

### Four components of nephrotic syndrome

- Proteinuria ( $> 3.5$  g/day), which can be highly selective (i.e., albumin only) or poorly selective (i.e., albumin and higher weight globulins) (Figure 16-1).
- Hypoalbuminemia ( $< 3$  gm/dL).
- Generalized edema.
- Hyperlipidemia.

### Pathogenesis of nephrotic syndrome

- Damage to glomeruli results in leakage of protein, and much of the protein lost is albumin, resulting in hypoalbuminemia.
- Hypoalbuminemia causes a decreased osmotic pressure that leads to edema. The edema caused by nephrotic syndrome is generalized (i.e., **anasarca**). Edema decreases the amount of fluid in the vascular space and decreases blood pressure, which stimulates the kidney to produce renin. Ultimately, aldosterone retains sodium and water and provides more fluid to contribute to the further development (i.e., worsening) of edema.
- The liver responds to the loss of albumin by producing more apolipoprotein in an attempt to compensate for the low serum osmotic pressure. This compensatory mechanism results in hyperlipidemia.
- Nephrin is a key component of the slit diaphragm found between the podocyte foot processes, which may help control permeability and may play a role in the development of nephrotic syndrome.

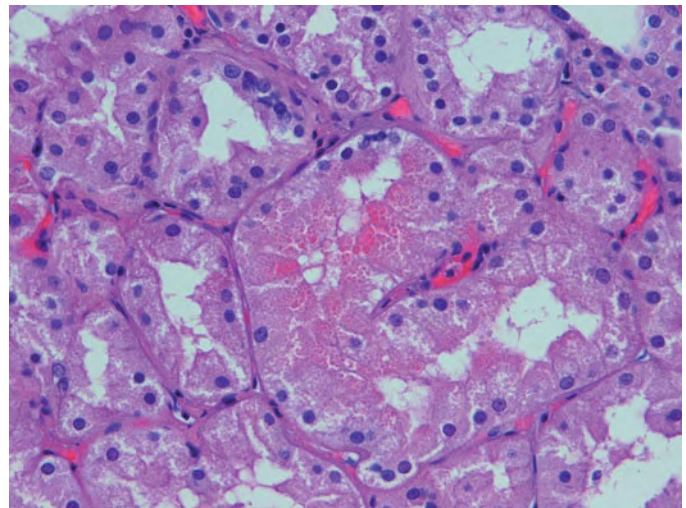
**Complications of nephrotic syndrome:** Infections as a result of loss of Ig; thrombosis secondary to urinary loss of antithrombin III, protein C, and protein S.

### Clinical presentation of nephrotic syndrome

- **Signs and symptoms:** Nausea and vomiting, periorbital and presacral edema, frothy urine.
- **Laboratory evaluation:** Proteinuria, hypoproteinemia, hypoalbuminemia. Waxy casts (lipid droplets) and oval fat bodies in urine. Lipid droplets have a “**maltese cross**” appearance under polarized light.
- **Diagnosis:** Biopsy of the kidney is required for diagnosis of the specific cause of nephrotic syndrome.

### General causes of nephrotic syndrome

- **In adults,** most cases of nephrotic syndrome are secondary to systemic diseases such as diabetes mellitus, SLE, amyloidosis, Goodpasture syndrome, polyarteritis nodosa, and Wegener granulomatosis.



**Figure 16-1.** Hyaline change in renal tubules. The eosinophilic droplets in the central tubule are indicative of proteinuria, one of the features of nephrotic syndrome. Hematoxylin and eosin, 400 $\times$ .

**TABLE 16-2.** Histologic Features of Conditions Causing Nephrotic and Nephritic Syndrome

Syndrome	Condition	Light Microscopy	Immunofluorescence	Electron Microscopy
Nephrotic syndrome	Minimal change disease	Normal	Negative	Effacement of foot processes
	FSGS	Segmental sclerosis of some glomeruli	Entrapped IgM and C3	No immune complexes
	Membranous glomerulonephropathy	“Spike and dome” pattern on silver stain	Granular pattern; IgG positive	Subepithelial immune complex deposits
Nephritic syndrome	Postinfectious glomerulonephritis	“Lumpy-bumpy” pattern on silver stain	Granular pattern; IgG and IgM positive	Predominantly subepithelial immune complex deposits
	RPGN type I	Glomerular crescents	Linear pattern; IgG positive	No immune complexes
	RPGN type II	Glomerular crescents	Granular pattern; IgG positive	Immune complex deposits
	RPGN type III	Glomerular crescents	Negative	No immune complex deposits
	MPGN type I*	“Tram-track” appearance on silver stain	Granular pattern; IgG and C3 positive	Subendothelial immune complex deposits
	MPGN type II	“Tram-track” appearance on silver stain	C3 positive; IgG negative	Long dense band in lamina densa

FSGS, focal segmental glomerulosclerosis; RPGN, rapidly progressive glomerulonephritis; MPGN, membranoproliferative glomerulonephritis.

\* Note: Although membranoproliferative glomerulonephritis is listed under nephritic syndrome, many patients with the condition present with a nephrotic syndrome.

- **In children**, most cases are primary glomerular diseases. The most common cause of nephrotic syndrome in children is minimal change disease (85% of cases).

### SPECIFIC CAUSES OF NEPHROTIC SYNDROME

**Overview:** The four main conditions that cause nephrotic syndrome (minimal change disease, focal segmental glomerulosclerosis, membranous glomerulonephropathy, and diabetic nephropathy) will be discussed below and are listed in [Table 16-2](#).

#### MINIMAL CHANGE DISEASE

##### Histologic evaluation

- **Light microscope:** No abnormalities in the glomeruli. Proximal convoluted tubule cells can be laden with lipid and protein, which is why minimal change disease is also called **lipoid nephrosis**.
- **Immunofluorescence:** No abnormalities.
- **Electron microscopy:** Effacement (formerly described as fusion) of podocyte foot processes (i.e., flattening, retraction, and swelling of foot processes).

**Important points regarding minimal change disease**

- Minimal change disease is the most common cause of nephrotic syndrome in children (usually ages 2–8 years); 2:1 male to female ratio.
- Minimal change disease causes selective proteinuria and is effectively treated with steroids.
- In adults, minimal change disease is associated with Hodgkin disease and other lymphomas, leukemias, and with nonsteroidal anti-inflammatory drug (NSAID) use.

**FOCAL SEGMENTAL GLOMERULOSCLEROSIS (FSGS)****Histologic evaluation**

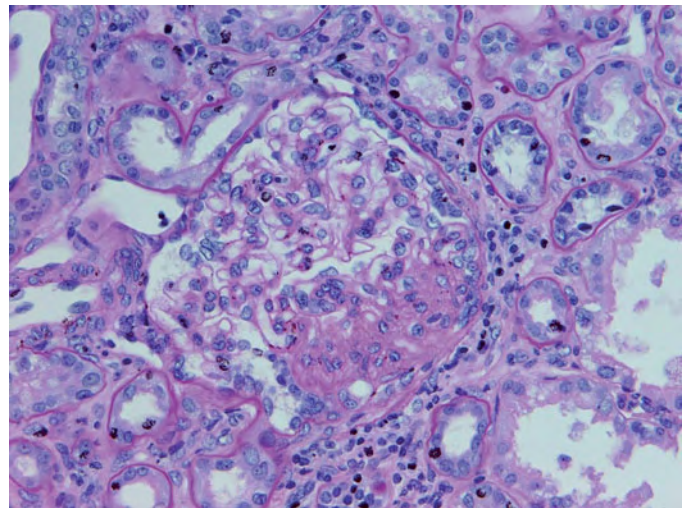
- **Light microscope:** Segmental sclerosis of a few glomeruli (Figure 16-2).
- **Immunofluorescence:** Positive for IgM and C3 (see below).
- **Electron microscopy:** No immune complexes.

**Etiology of histologic appearance of FSGS:** Although FSGS is a primary disorder of the renal glomeruli, the histologic appearance of FSGS may be present in the kidney in association with other conditions (i.e., FSGS is both a specific condition as well as a descriptive pattern of glomerular change).

- Failed compensatory mechanism: Renal ablation glomerulonephropathy is failure of glomeruli when they are overworked and they develop segmental sclerosis.
- Secondary to another glomerular disease (e.g., IgA nephropathy, Alport syndrome).

**Important points regarding FSGS**

- FSGS is the second most common cause of nephrotic syndrome in children (minimal change disease is the most common cause). Overall, FSGS is the most common primary cause of nephrotic syndrome in adults.
- FSGS is not immunologic in origin; the IgM and C3 present are entrapped. The mechanism of FSGS is injury to epithelial cells; serum complement levels are normal.
- FSGS causes nonselective proteinuria.
- **Collapsing variant FSGS:** Collapse and sclerosis of glomeruli similar in appearance to that seen in patients with human immunodeficiency virus (HIV); has a worse prognosis; seen in African Americans. Patients have massive proteinuria and rapidly progressive renal insufficiency.
- Intravenous (IV) heroin use and HIV are significant independent risk factors for the development of FSGS. The risk of FSGS in IV heroin users is 30 times that of the general population.
- *There is no treatment or cure for FSGS.* Patients commonly progress to chronic glomerulonephritis, and 50% of patients develop end-stage renal disease within 10 years.



**Figure 16-2.** Focal segmental glomerulosclerosis. At the 3-o'clock to 6-o'clock position in the glomerulus in the photomicrograph, the glomerular tuft is focally collapsed and sclerotic (segmental). This change was only present in some of the glomeruli in the kidney (focal). Periodic acid–Schiff, 400 $\times$ .



## MEMBRANOUS GLOMERULONEPHROPATHY

### Histologic evaluation

- **Light microscope:** Silver stain highlights thickened basement membrane extending between immune complexes, causing a “**spike and dome pattern**.” The “spikes” of basement membrane between immune complexes thicken and cover immune complexes to produce “domes” (Figure 16-3 A and B).
- **Immunofluorescence:** Granular pattern; positive for IgG.
- **Electron microscopy:** Subepithelial immune complexes.

**Pathogenesis of membranous glomerulonephropathy:** Formation of C5b-9 membrane attack complex causes activation of epithelial and mesangial cells, resulting in liberation of proteases and oxidants.

### Important points

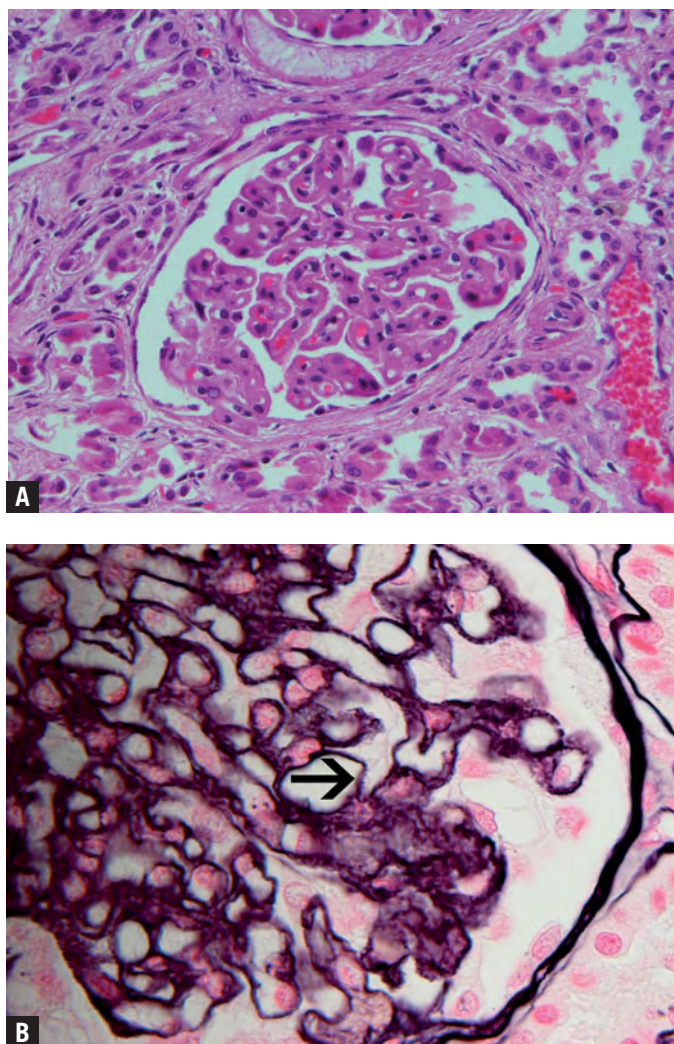
- Membranous glomerulonephropathy causes nonselective proteinuria.
- Membranous glomerulonephropathy is often secondary to other conditions such as syphilis, malaria, hepatitis B and C, carcinoma of the lung and colon, melanoma, lupus, drug therapy (penicillamine, captopril, NSAIDs), and SLE; however, 85% of cases are idiopathic in origin.
- One third of patients undergo remission; one third have proteinuria and stable renal functions; and one third progress to end-stage renal disease within 5–10 years.

## DIABETIC NEPHROPATHY

**Important point:** Diabetic nephropathy is the single most important cause of end-stage renal disease in the United States (in 40% of patients with end-stage renal disease, it is due to diabetes mellitus).

### Clinical presentation of diabetic nephropathy

- Persistent albuminuria and hypertension. Patients have elevated GFR early in the disease, followed by progressive decline in GFR and renal function.
- **Microalbuminuria** predicts development of diabetic nephropathy.



**Figure 16-3.** Membranous glomerulonephropathy. **A**, A hematoxylin and eosin stained section of kidney showing a glomerulus with thickening of the basement membrane of the glomerular capillary tuft, producing a “wire loop” pattern. **B**, A Jones silver stain showing the spikes, which are characteristic of membranous glomerulonephropathy (arrow). **A**, Hematoxylin and eosin, 400 $\times$ . **B**, Jones silver stain, 1000 $\times$ .

Microscopic morphology of diabetic nephropathy

- Most common finding is **diffuse glomerulosclerosis**, which is a diffuse thickening of the basement membrane.
- **Kimmelstiel-Wilson lesion** (i.e., **nodular glomerulosclerosis**) is found in 15–20% of patients with diabetic nephropathy, and consists of acellular nodules within the glomerular basement membrane (Figure 16-4).

NEPHRITIC SYNDROME

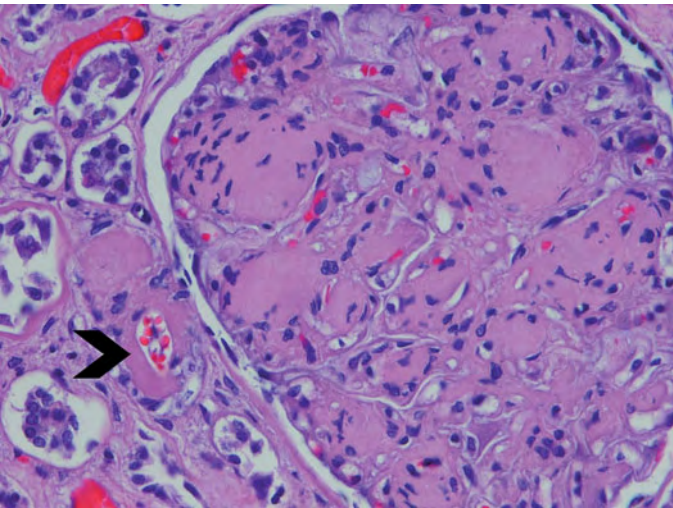
**Overview:** Nephritic syndrome is characterized by acute renal failure (i.e., increased BUN and Cr combined with oliguria) associated with hypertension and hematuria. Edema and proteinuria are present, but are much less severe than in nephrotic syndrome.

**Pathogenesis of nephritic syndrome:** The damage to the glomerulus is much more severe than in nephrotic syndrome. In nephrotic syndrome, the damage allows leakage of protein; in nephritic syndrome, it allows leakage of red blood cells. The immune complex deposition triggers proliferation of glomerular cells (e.g., epithelial, endothelial, and mesangial) and stimulates arrival of neutrophils (Table 16-3).

Clinical presentation of nephritic syndrome

- **Signs and symptoms:** Include edema, oliguria, and hypertension. Hematuria is often described as “smoky brown” or “cola-colored” urine. If patients have postinfectious glomerulonephritis, they will most likely have had symptoms of the precipitating illness (e.g., pharyngitis, skin rash).
- **Laboratory findings:** Hematuria, proteinuria (< 3.0 g/day), and elevated BUN and creatinine; **red cell casts** in urine.
- **Serum complement level**
  - **Low level:** Found in acute postinfectious glomerulonephritis, membranoproliferative glomerulonephritis, SLE, bacterial endocarditis.
  - **Normal level:** Found in IgA nephropathy, idiopathic rapidly progressing glomerulonephritis, and antiglomerular basement membrane antibody disease.

**Specific causes of nephritic syndrome:** Three conditions that cause nephritic syndrome are postinfectious glomerulonephritis, rapidly progressive glomerulonephritis, and membranoproliferative glomerulonephritis, and will be discussed below (see Table 16-2).



**Figure 16-4.** Nodular glomerulosclerosis (Kimmelstiel-Wilson lesion). The acellular eosinophilic nodules in the capillary tuft of the glomerulus are characteristic of diabetes mellitus. The arrowhead indicates acellular eosinophilic thickening of the arteriole wall, consistent with the histologic feature of hyaline arteriosclerosis, which occurs in diabetes mellitus as well as hypertension (albeit, different mechanisms of formation). Hematoxylin and eosin, 400×.

TABLE 16-3. Comparison and Contrast of Nephrotic and Nephritic Syndromes		
Feature	Nephrotic Syndrome	Nephritic Syndrome
Proteinuria	> 3.5 g/day	< 3.0 g/day
Presence of edema	Yes	Yes
Presence of oliguria	No	Yes
Presence of hematuria	No	Yes
Other features	Hypoalbuminemia, hyperlipidemia	Hypertension, red blood cell casts in urine, elevated BUN/Cr

BUN, blood urea nitrogen; Cr, creatinine.



## POSTINFECTIOUS GLOMERULONEPHRITIS

### Histologic evaluation

- **Light microscope:** All or almost all glomeruli have an increased number of cells, including leukocytes and proliferating endothelial and mesangial cells (**proliferative glomerulonephritis**). On silver stain, a “lumpy-bumpy” pattern is seen, caused by staining of basement membrane growing around immune complexes (Figure 16-5).
- **Immunofluorescence:** Granular pattern; positive for IgG, IgM, and complement.
- **Electron microscopy:** Subepithelial immune complex deposits; also visible are subendothelial, intramembranous, and mesangial deposits.

### Causes of postinfectious glomerulonephritis

- Most commonly the disease occurs 1–4 weeks after group A streptococcal pharyngitis (with types 1, 4, 12) or impetigo.
- Other causes: Staphylococcal infections (such as endocarditis), mumps, measles, hepatitis B and C, and chickenpox.

**Epidemiology:** Most patients are 6 to 10 years of age.

### Important points regarding postinfectious glomerulonephritis

- About 90–95% of patients recover completely.
- Postinfectious glomerulonephritis, in the past, has been called **poststreptococcal glomerulonephritis**, as most cases arose following streptococcal infections. Other infections, however, also cause this condition; thus the term postinfectious glomerulonephritis is preferred.
- Some patients progress to rapidly progressive glomerulonephritis, which results in chronic glomerulonephritis.
- Patients have low complement levels due to activation of the system.
- Markers of streptococcal infection are present, including antistreptolysin-O and anti-DNAse B.

## RAPIDLY PROGRESSIVE GLOMERULONEPHRITIS (RPGN) (SEE TABLE 16-2)

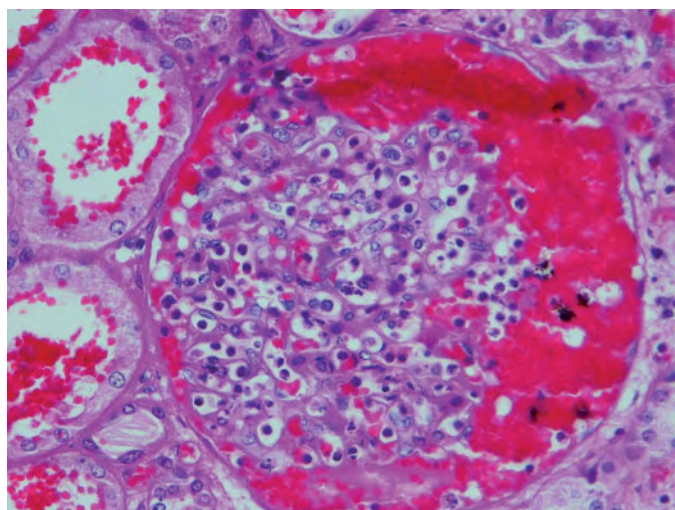
### Important points

- RPGN causes nephritic syndrome; however, RPGN is also considered its own category of renal disease as well.
- Although RPGN can occur as a primary disease, often it occurs secondary to another glomerular disease.
- RPGN is also referred to as **crescentic glomerulonephritis**.

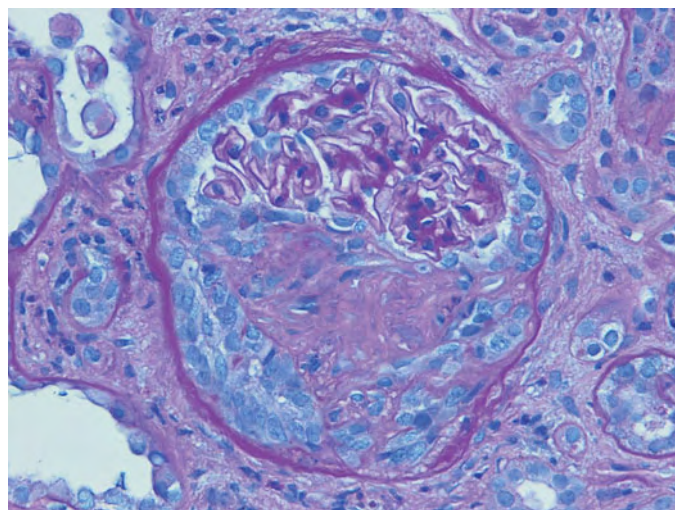
### Histologic evaluation

- **Light microscope:** Crescents of proliferating parietal cells in combination with invading monocytes and fibrin in Bowman space (Figure 16-6).
- **Immunofluorescence:** See types of RPGN.
- **Electron microscopy:** Defect in basement membrane (tear); see also types of RPGN.

**Types of RPGN (I–III):** The three types of RPGN are listed below, including the features and specific causes that distinguish each one from the others.



**Figure 16-5.** Postinfectious glomerulonephritis. All of the glomeruli in this kidney had similar changes (diffuse). The cellularity of the capillary tuft is markedly increased (proliferative). Although this change is most commonly associated with streptococcal pharyngitis, other infections can produce a similar change. Hematoxylin and eosin, 400×.



**Figure 16-6.** Rapidly progressive (crescentic) glomerulonephritis. Note the proliferation of epithelial cells within Bowman space, which is producing a crescent-like structure that is causing collapse of the capillary tuft. Periodic acid–Schiff, 400×.



**Type I RPGN**

- **Distinguishing feature:** Linear pattern of immunofluorescence due to causative IgG binding directly to glomerular basement membrane antigens.
- **Causes:** Goodpasture syndrome; idiopathic.

**Type II RPGN**

- **Distinguishing feature:** Immune complex mediated.
- **Causes:** Postinfectious glomerulonephritis, IgA nephropathy and Henoch-Schönlein purpura, SLE, idiopathic.

**Type III RPGN**

- **Distinguishing feature:** Type III RPGN is referred to as pauci-immune (i.e., no immune complexes). ANCA is positive (e.g., Wegener granulomatosis) in up to 80% of cases.
- **Causes:** Wegener granulomatosis, microscopic polyarteritis, idiopathic.

### MEMBRANOPROLIFERATIVE GLOMERULONEPHRITIS (MPGN)

**Presentation:** About 50% of patients present with nephrotic syndrome, 30% with asymptomatic hematuria, and 20% with acute nephritic syndrome.

**Epidemiology:** Most patients are diagnosed between the ages of 5 and 30 years.

**Important point:** About 50% of patients develop chronic renal failure within 10 years.

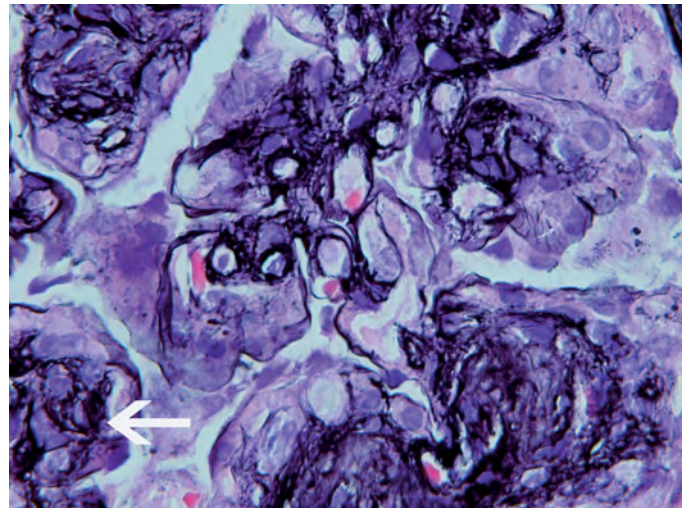
#### Histologic evaluation of membranoproliferative glomerulonephritis (see Table 16-2)

- **Light microscope:** Lobular appearance of glomeruli, thickening of basement membrane, and an increase in the number of cells in the glomerulus. Glomerular basement membranes have “**tram-track**” appearance (like railroad tracks) on silver stain, due to splitting of the basement membrane by extensions of mesangial and inflammatory cell processes. There is a proliferation of glomerular cells combined with leukocyte infiltrate. The proliferation of cells is commonly in a mesangial location, hence the alternative name “**mesangio-capillary glomerulonephritis**” (Figure 16-7).
- **Immunofluorescence:** See types of MPGN.
- **Electron microscopy:** See types of MPGN.

**Types of MPGN (I and II):** There are two types of MPGN based upon the immunofluorescence and electron microscopic findings.

**Type I MPGN**

- **Immunofluorescence:** Granular pattern; positive for C<sub>3</sub> and IgG.
- **Electron microscopy:** Subendothelial immune complex deposits.
- **Important point:** Associated with hepatitis B and C and SLE.



**Figure 16-7.** Membranoproliferative glomerulonephritis. Note the redundancy of the basement membrane (“tram-track” appearance) at the arrow. Jones silver stain, 1000×.

**Type II MPGN**

- **Immunofluorescence:** Positive for C<sub>3</sub> (on either side of dense deposit); no IgG.
- **Electron microscopy:** Long dense band of unknown composition in lamina densa and subendothelial region.
- **Important point:** Associated with C<sub>3</sub> nephritic factor, which stabilizes C<sub>3</sub> convertase; thus, patients have hypocomplementemia.

## CHRONIC GLOMERULONEPHRITIS

**Overview:** Chronic glomerulonephritis is a condition resulting from long-term damage to the glomeruli. In addition, other compartments of the kidney begin to show damage. For example, glomerular failure due to global sclerosis of the glomeruli leads to decreased blood flow to the kidney, and decreased blood flow to the kidney triggers release of renin, which results in hypertension. Hypertension causes hyaline arteriosclerosis, which damages the vessels, resulting in a thinned renal cortex and atrophy of tubules (Figure 16-8).

**Causes of chronic glomerulonephritis**

- **Common causes:** Diabetes mellitus, lupus nephritis, RPGN, FSGS, and membranoproliferative glomerulonephritis.
- **Less common causes:** IgA nephropathy and membranous glomerulonephropathy.
- **Rare causes:** Postinfectious glomerulonephritis.
- **Important point:** In most cases, the original condition that resulted in the chronic damage cannot be identified because the glomeruli are too sclerotic.

## ASYMPTOMATIC HEMATURIA

**Overview:** Asymptomatic hematuria is hematuria without other associated symptoms. For example, nephritic syndrome is associated with hematuria, but hypertension, oliguria, and other symptoms are usually present.

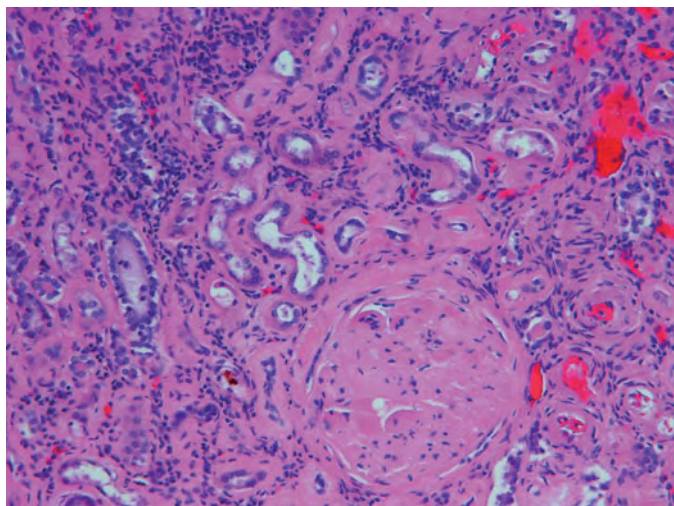
**Important laboratory finding:** Red cell casts.

**General pathogenesis:** Most forms of asymptomatic hematuria caused by glomerular disease are due to abnormalities in the basement membrane; however, the most common glomerular cause of asymptomatic hematuria is IgA nephropathy, which is caused by immune complex deposition.

**Specific causes of asymptomatic hematuria:** The four most common conditions causing asymptomatic hematuria are IgA nephropathy, Henoch-Schönlein purpura, Alport syndrome, and thin basement membrane disease.

## IGA NEPHROPATHY (BERGER DISEASE)

**Epidemiology:** Accounts for 40–50% of patients with asymptomatic hematuria. IgA nephropathy is the most common primary cause of glomerulonephritis. Most patients are between the ages of 15 and 35 years. It has a male to female ratio of 2–3:1, and is more common in whites than African Americans. IgA nephropathy is associated with celiac disease and Henoch-Schönlein purpura.



**Figure 16-8.** Chronic glomerulonephritis. Over time, with many renal diseases, all four components of the renal cortex (i.e., glomeruli, tubules, interstitium, and vessels) are damaged. In this section, there is one globally sclerotic glomerulus and many atrophic tubules. Diabetes mellitus and hypertension are common etiologies of chronic renal failure; however, at the end stage of the disease, histologic examination of the kidney often will not reveal changes to identify the underlying cause. Hematoxylin and eosin, 400 $\times$ .

**Histologic evaluation**

- **Light microscopy:** Variable histologic appearance, including that of focal segmental glomerulosclerosis or crescentic glomerulonephritis.
- **Immunofluorescence:** Granular pattern; positive for IgA and C<sub>3</sub>.
- **Electron microscopy:** IgA immune complexes in the mesangium.

**Pathogenesis:** Defect in production and clearance of IgA through abnormal glycosylation.

**HENOCH-SCHÖNLEIN PURPURA**

**Basic description:** IgA-mediated vasculitis.

**Epidemiology:** Most common in children aged 3–8 years.

**Clinical presentation of Henoch-Schönlein purpura:** Often follows streptococcal or viral infection. Patients have gastrointestinal bleeding, abdominal pain, and arthralgias. The classic rash of Henoch-Schönlein purpura consists of palpable purpura on the legs and buttocks. Up to 50% of patients have renal involvement, usually with hematuria. The renal disease in Henoch-Schönlein purpura is indistinguishable from IgA nephropathy.

**ALPORT SYNDROME****Histologic evaluation**

- **Light microscopy:** Variable (from normal appearance of the glomeruli to that of focal segmental glomerulosclerosis); **interstitial foam cells** (i.e., accumulation of neutral fats and mucopolysaccharides).
- **Immunofluorescence:** Negative.
- **Electron microscopy:** Splitting, thickening, and thinning of basement membrane (i.e., **basket-weave pattern**).

**Pathogenesis:** Abnormal production of type IV collagen; commonly due to mutation in  $\alpha_5$  gene.

**Important points regarding Alport syndrome**

- The condition is hereditary (X-linked, autosomal dominant, and autosomal recessive forms). About 80% of cases are X-linked.
- In addition to renal failure, patients have lens dislocation, cataracts, and nerve deafness.
- The disease is more common and more severe in males.

**Clinical presentation of Alport syndrome:** Deafness and hematuria. Symptoms appear between ages 5 to 20 years, and renal failure occurs between ages 20 to 50 years.

**Thin basement membrane disease:** The disease is diagnosed by electron microscopy. In thin basement membrane disease, the basement membrane is 150–200 nm thick; the normal thickness is 300–400 nm.

**TUBULOINTERSTITIAL DISEASE**

**Overview:** Tubulointerstitial disease encompasses a group of disorders with prominent involvement of the renal tubules and



interstitium. These disorders can be divided into four categories—acute tubulointerstitial disease, acute interstitial nephritis, chronic tubulointerstitial disease, and acute tubular necrosis—each of which will be discussed below. One important concept to remember is that acute interstitial nephritis and pyelonephritis (see infections of the kidney and urinary tract) are subcategories of acute tubulointerstitial disease.

### ACUTE TUBULOINTERSTITIAL DISEASE

**Microscopic morphology:** Edema, neutrophils, and focal necrotizing infiltrates.

**Clinical presentation:** Acute renal failure over a period of days to weeks; hematuria. If due to an allergic drug reaction (e.g., interstitial nephritis), rash, fever, eosinophilia, and elevated IgE may be present.

**Causes of acute tubulointerstitial nephritis:** Drugs, systemic infections, primary renal infections, immune disorders.

- **Drugs:** Penicillins (methicillin), rifampin, sulfonamides, ciprofloxacin. Drugs are responsible for 70% of cases of acute interstitial nephritis.
- **Systemic infections:** Legionnaire disease, streptococcal infections, cytomegalovirus, infectious mononucleosis.
- **Primary renal infections:** Acute bacterial pyelonephritis.
- **Immune disorders:** SLE, Sjögren syndrome.

### ACUTE INTERSTITIAL NEPHRITIS

**Basic description:** Usually refers to noninfectious causes of acute tubulointerstitial nephritis.

**Cause:** Usually drug induced (e.g., synthetic penicillins such as methicillin, rifampin, thiazides, sulfonamides).

**Pathogenesis of acute interstitial nephritis:** Tubules have a high metabolic rate because of active transport systems and are sensitive to injury. Acute interstitial nephritis results from tubular injury combined with a persistent and severe decrease in blood flow.

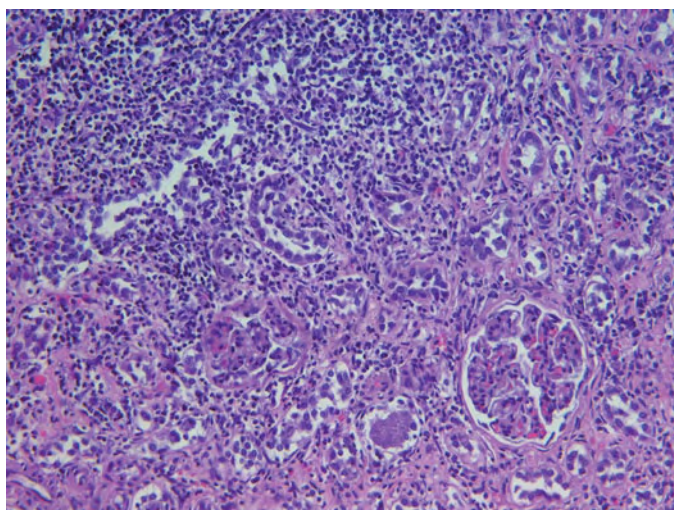
**Microscopic morphology:** Interstitial lymphocytes and macrophages, edema, eosinophils; sometimes giant cells and granulomas (Figure 16-9).

**Clinical presentation of acute interstitial nephritis:** Hematuria, acute renal failure (i.e., azotemia and oliguria), rash, eosinophilia, proteinuria.

### CHRONIC TUBULOINTERSTITIAL DISEASE

**Microscopic morphology:** Cellular infiltrate composed of lymphocytes and macrophages in combination with interstitial fibrosis.

**Clinical presentation of chronic tubulointerstitial disease:** Renal insufficiency, hypertension, anemia, and non-nephrotic range proteinuria occurring over years. Analgesic nephropathy, which was once the most important cause of chronic tubulointerstitial disease, is more common in older women, typically with a history of arthritis or headaches and a long history of chronic heavy analgesic use (e.g., aspirin, phenacetin, acetaminophen).



**Figure 16-9.** Acute interstitial nephritis. Acute interstitial nephritis is often due to various drugs. In the image, note that the interstitial infiltrate (which spares the glomeruli) is predominantly composed of lymphocytes. Hematoxylin and eosin, 200 $\times$ .

### Causes of chronic tubulointerstitial nephritis

- **Urinary tract obstruction** (most important cause).
- **Chronic pyelonephritis** and reflux nephropathy.
- **Drugs:** NSAIDs (analgesic nephropathy), cisplatin, cyclosporine.
- **Vascular disease:** Hypertension, atherosclerosis.
- **Heavy metals:** Lead, cadmium.
- **Malignancies:** Multiple myeloma.

### ACUTE TUBULAR NECROSIS

**Basic description:** Rapid onset of necrosis of tubular epithelium with subsequent acute loss of renal function. Acute tubular necrosis is the most common cause of acute renal failure.

#### Causes of acute tubular necrosis

- **Ischemic category:** Trauma with blood loss; sepsis.
- **Toxic category:** Aminoglycosides, intravenous contrast, mercury, oxalic acid (due to ethylene glycol poisoning), myoglobinuria, hemoglobinuria; hyperuricemia (associated with rapid cellular turnover with certain malignancies).

**Pathogenesis:** Tubular injury and decreased GFR leads to acute tubular necrosis.

#### Stages of acute tubular necrosis

- **Initiating:** The initiating stage is the event that causes the acute tubular necrosis; no change in renal output.
- **Maintenance:** Oliguria; urine flow decreases to < 400 mL/day within 24 hours of initiating event.
- **Recovery:** Increased urine output (up to 3 L); electrolyte disturbances at this time increase the risk of death.

**Microscopic morphology of acute tubular necrosis:** Tubulorhexis; coagulative necrosis of epithelial cells, protein casts (composed of **Tamm-Horsfall protein**), and dilation of proximal convoluted tubules (Figure 16-10 A and B).

**Clinical presentation of acute tubular necrosis:** Acute renal failure with granular or “muddy brown” epithelial casts in urine.

## INFECTIONS OF THE KIDNEY AND URINARY TRACT

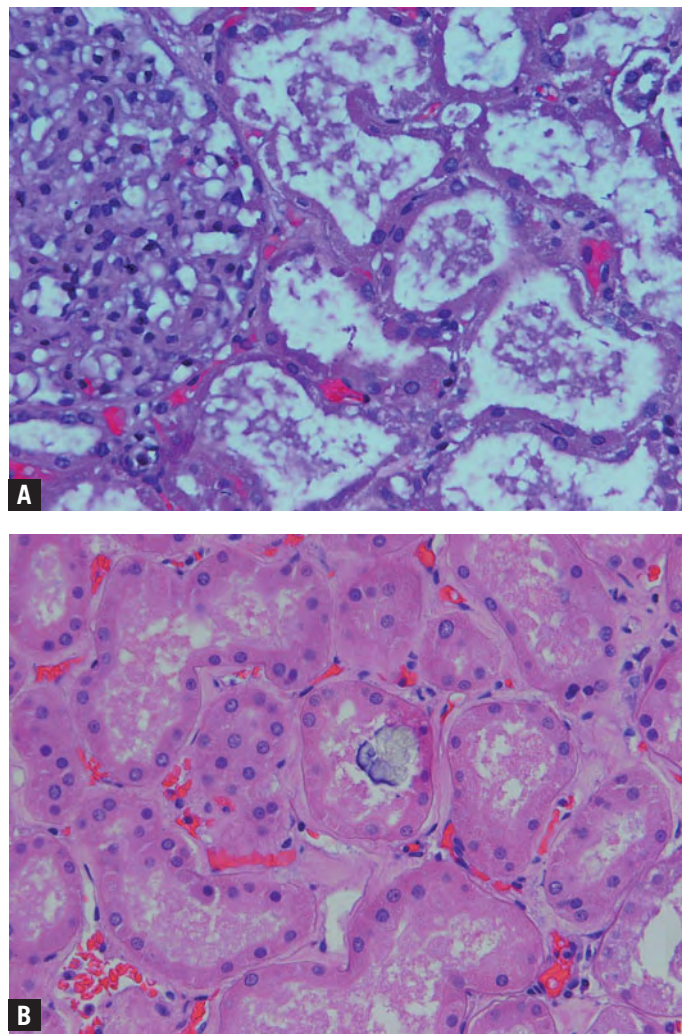
**Overview:** The three most important infections of the kidneys and urinary tract are classified as cystitis and acute and chronic pyelonephritis. Although each is a separate entity, they all are also interrelated. These three infections and xanthogranulomatous pyelonephritis are all discussed in this section.

### CYSTITIS

**Basic description:** Infection of the bladder.

#### Clinical presentation of cystitis

- **Symptoms:** Dysuria, urinary frequency, urgency.
- **Signs:** Suprapubic discomfort.
- **Laboratory testing:** Urine is positive for leukocyte esterase and has elevated pH and elevated nitrates.



**Figure 16-10.** Acute tubular necrosis. **A**, The tubules are dilated and lined with flattened epithelial cells, some of which are necrotic (eosinophilic, with loss of nuclear basophilia). Acute tubular necrosis is due to an ischemic or toxic insult. One toxin that affects the kidney is ethylene glycol. Ethylene glycol is, by itself, harmless to the kidney; however, metabolism of the toxin converts it to oxalic acid, which damages the kidney. **B**, An oxalic acid crystal is in the center of the photomicrograph. Hematoxylin and eosin, **A** and **B**, 400 $\times$ .



**Complications of cystitis:** Acute pyelonephritis.

### ACUTE PYELONEPHRITIS (FIGURE 16-11 A–C)

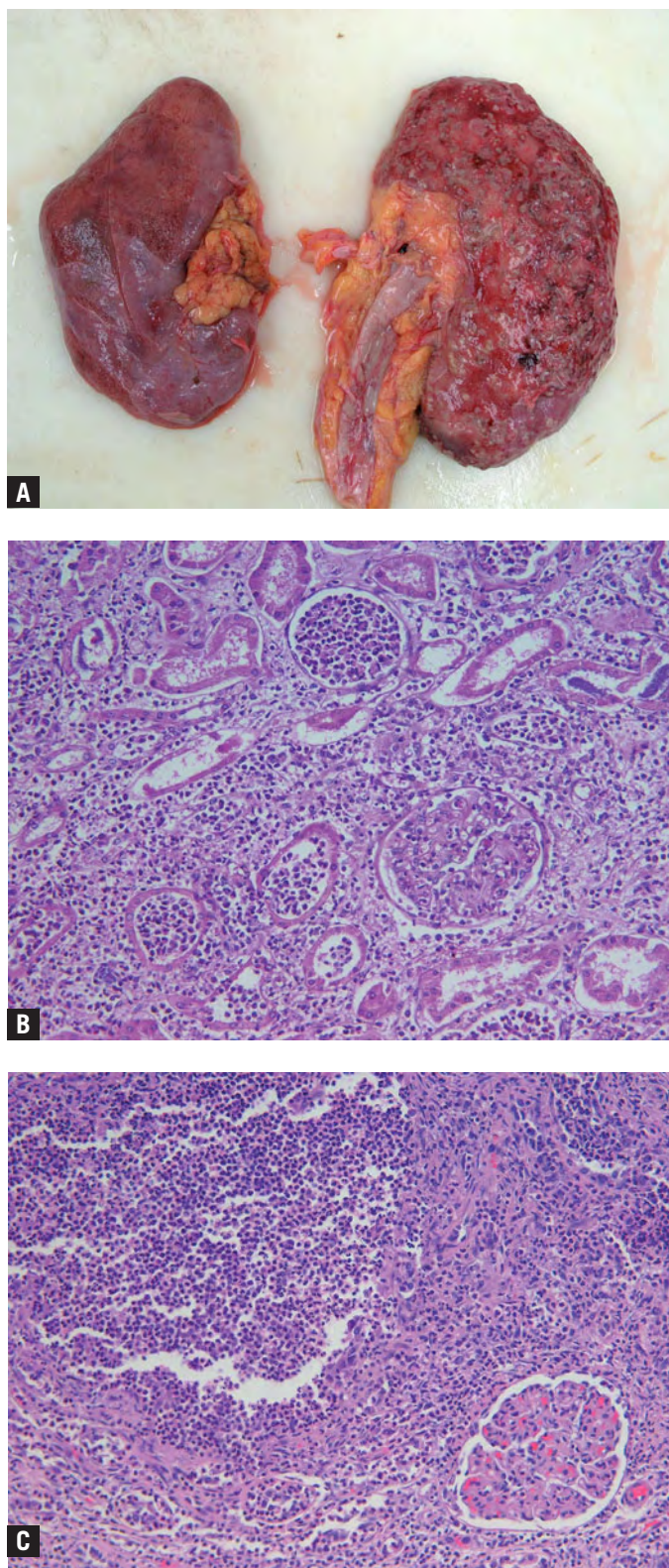
**Basic description:** Inflammation (usually bacterial in origin) of the kidney (primarily tubules and interstitium). The glomeruli are fairly resistant, but eventually can become involved.

#### Pathogenesis of acute pyelonephritis

- **Two sources of infection:** Ascending infections from the bladder (most common), or hematogenous spread from another site of infection.
- **Causative organisms:** *Escherichia coli*, *Proteus*, *Enterobacter*, and *Staphylococcus*. *Staphylococcus* is more common from hematogenous sources.
- **Mechanism of ascending infections:** Bacteria adhere to the mucosa of the lower urinary tract (i.e., colonization of urethra) and enter into the bladder following instrumentation or other trauma (e.g., from sexual intercourse). From the bladder, bacteria ascend to the pelvis of the kidney because of vesicoureteral reflux (i.e., incompetent valves between the ureter and bladder).
- **Risk factors for ascending infections**
  - **Obstruction** (e.g., benign prostatic hyperplasia, uterine prolapse) impairs voiding. Voiding is a mechanism the bladder has for remaining sterile by washing the bacteria out frequently.
  - **Vesicoureteral reflux** (see Figure 16-11 A).
  - **Diabetes mellitus:** Patients have increased risk of infection and can have bladder dysfunction due to nerve damage.
  - **Gender:** Females have shorter urethra.
  - **Other risk factors:** Presence of renal lesion, immunosuppression, and trauma, including sexual intercourse and pregnancy.

**Morphology of acute pyelonephritis:** Abscesses in cortex.

**Clinical presentation of acute pyelonephritis:** Acute onset of fevers, chills, rigors, and back pain with costovertebral angle tenderness. Leukocytosis is almost always present. Hematuria, dysuria, and frank pyuria may occur. White blood cells, white cell casts, and positive leukocyte esterase in urine.



**Figure 16-11.** Acute pyelonephritis. **A**, Both kidneys are from the same patient. The right kidney has a friable cortex, and the ureter is dilated. The left kidney is essentially normal. The fact that only one kidney is affected supports the concept that a urinary tract infection alone is not enough to result in pyelonephritis. This patient most likely had vesicoureteral reflux on the right side, but none on the left. **B**, Note the infiltrate of neutrophils in the interstitium and filling the tubules. **C**, The neutrophilic infiltrate can result in abscess formation (left upper corner), which contributed to the degeneration and subsequent friable nature of the cortex in (**A**). Hematoxylin and eosin, **B** and **C**, 200 $\times$ .



### Complications of acute pyelonephritis

- **Pyonephritis:** Because of obstruction, the renal pelvis fills with neutrophils and bacteria.
- **Emphysematous pyelonephritis:** An unusual but serious complication of pyelonephritis is almost exclusively seen in diabetics; characterized by gas production within the renal parenchyma visible on plain films or CT. Most cases are due to *E coli*.
- **Papillary necrosis**
  - **Basic description:** Necrosis of renal papillae (Figure 16-12).
  - **Pathogenesis of papillary necrosis:** Requires variable amounts of obstruction, ischemia, and infection.
  - **Associations:** All patients with pyelonephritis are at risk for papillary necrosis; increasingly so are diabetics with obstruction, patients with sickle cell disease, and patients abusing analgesics (usually combination analgesics, often with phenacetin).
  - **Complications of papillary necrosis:** Acute renal failure; urinary obstruction due to sloughing of necrotic papillae.

### CHRONIC PYELONEPHRITIS

**Basic description:** Chronic tubulointerstitial change with inflammation and scarring and with involvement of calyces.

**Causes:** Reflux; chronic obstructive pyelonephritis.

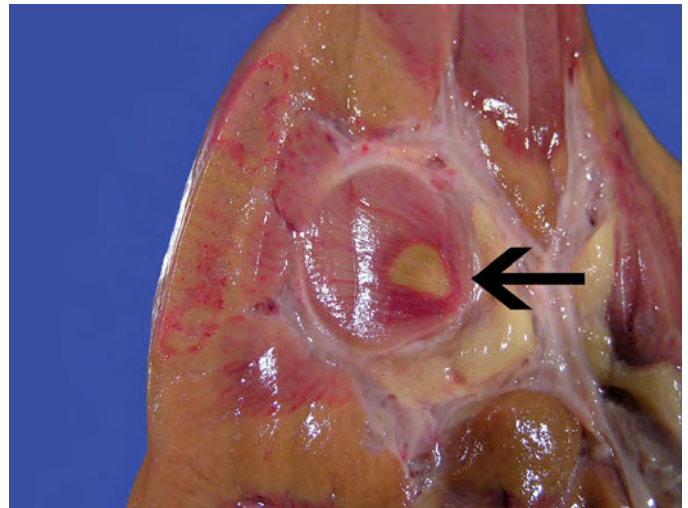
**Morphology of chronic pyelonephritis** (Figure 16-13 A and B)

- **Gross:** U-shaped cortical scars, dilated pelvis and calyces, blunting of renal papillae.
- **Microscopic:** Thyroidization of the tubules.

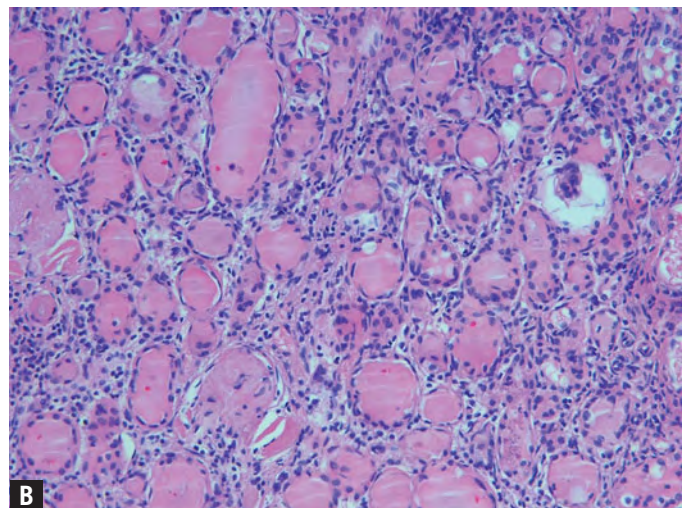
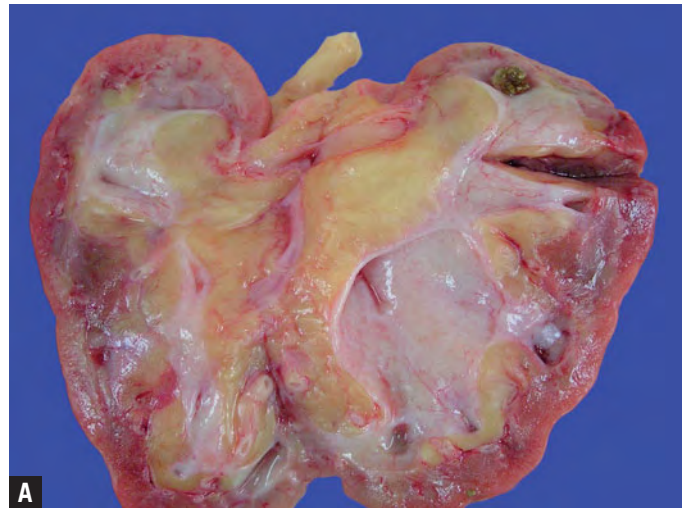
### XANTHOGRANULOMATOUS PYELONEPHRITIS

**Basic description:** Unilateral necrotizing, granulomatous, inflammatory destruction of kidney.

**Associations:** Enlarged kidneys, chronic kidney infection, and renal calculi.



**Figure 16-12.** Papillary necrosis. Note the yellow discoloration with a hemorrhagic rim in the renal papilla at the tip of the arrow. Papillary necrosis can lead to sloughing of the papillae and subsequent obstruction of a ureter.



**Figure 16-13.** Chronic pyelonephritis. In chronic pyelonephritis, the pelvis and calyces will be dilated and the cortex will be thinned (A). The cause of the chronic pyelonephritis in (A) is a renal calculus (top of right side). A characteristic histologic feature of chronic pyelonephritis is “thyroidization” of the tubules (B). Hematoxylin and eosin, 200X.

## NEPHROLITHIASIS

**Overview:** Nephrolithiasis is kidney stones (calculi). Calculi form within the renal pelvis and calyces due to supersaturation of urine. There are four main types of renal calculi: calcium, uric acid, struvite, and cystine (Figure 16-14; Table 16-4).

### CALCIUM OXALATE AND CALCIUM PHOSPHATE STONES (75% of stones)

#### Causes

- Hypercalciuria (50% of cases).
- Hypercalcemia and hypercalciuria together (10% of cases) as a result of parathyroid gland hyperplasia, vitamin D toxicity, and sarcoidosis.
- In 90% of patients, the hypercalciuria is idiopathic.

**Radiographic appearance:** Radiopaque.

### URIC ACID STONES

**Cause:** Hyperuricemia as a result of gout or tumors with rapid cell turnover (e.g., leukemia, lymphoma).

**Radiographic appearance:** Uric acid stones are the only radiolucent stone.

### STRUVITE STONES

**Other names:** Staghorn, magnesium-phosphate-ammonium (i.e., triple stone).

**Appearance:** Look like deer antlers, branching and filling the pelvis and calyces; can cause renal failure.

**Associated bacteria:** *Proteus vulgaris* and *Providencia* (urea-splitting), *Pseudomonas*.

**Pathogenesis of struvite stones:** Ammonium raises urine pH, which precipitates struvite and apatite. Ammonium phosphate traps calcium and magnesium.

**Radiographic appearance:** Radiopaque.

**Complications of struvite stones:** Xanthogranulomatous pyelonephritis (Figure 16-15); failure of involved kidney.

### CYSTINE

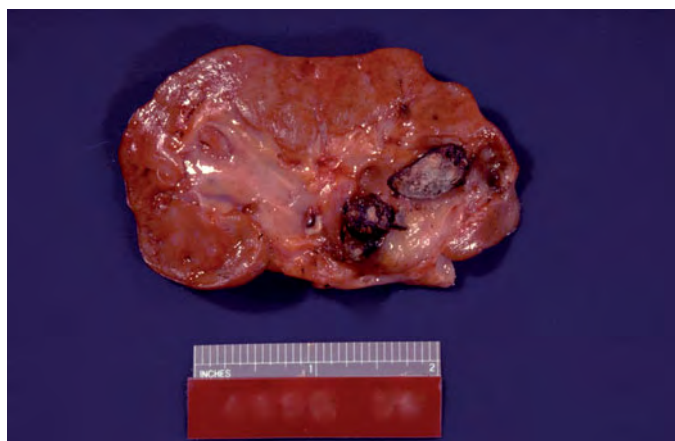
- **Radiographic appearance:** Radiopaque.

#### Clinical presentation of nephrolithiasis

- **Symptoms:** Severe, intermittent flank pain often radiating to the groin; nausea and vomiting; fever; hematuria.
- **Signs:** Costovertebral angle tenderness.
- **Diagnosis:** Intravenous pyelogram; radiographs of abdomen.

## CYSTIC DISEASES OF THE KIDNEY

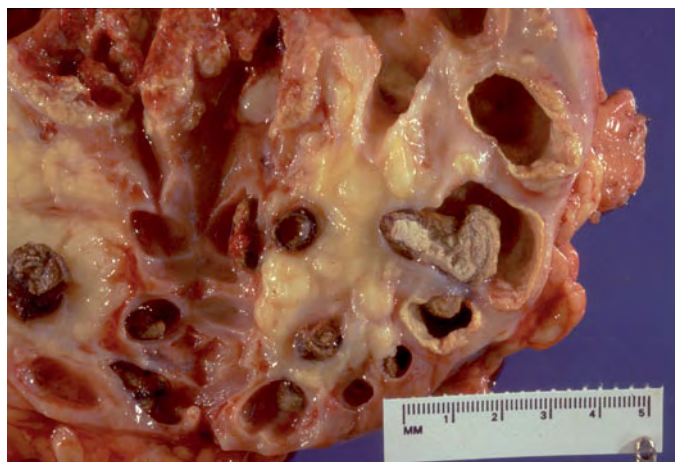**Overview:** Renal cysts are a common incidental finding at autopsy. Most cysts of the kidney are simple cysts, and usually are of little clinical significance. However, cystic renal dysplasia and polycystic kidney disease are important conditions associated with cyst formation.



**Figure 16-14.** Nephrolithiasis. This bisected kidney has a calculus partially filling and distending the pelvis and calyces.

**TABLE 16-4.** Kidney Stones

Composition	Radiographic Appearance	Disease Association(s)
Calcium oxalate and calcium phosphate	Radiopaque	Parathyroid gland hyperplasia, sarcoidosis
Uric acid	Radiolucent	Gout, leukemia, and lymphoma
Struvite (triple stones made of magnesium, phosphate and ammonium)	Radiopaque	Xanthogranulomatous pyelonephritis
Cystine	Radiopaque	



**Figure 16-15.** Xanthogranulomatous pyelonephritis. This bisected kidney has a staghorn calculus (note the dilated remnants of the pelvis and calyceal system with fragments of the stone within them). The renal parenchyma is abnormal; it is homogeneous, pale tan-white in color, and microscopically has sheets of macrophages. These changes are consistent with xanthogranulomatous pyelonephritis, a complication of staghorn calculi.



### SIMPLE CYSTS

**Basic description:** Fluid-filled cyst, usually in the cortex of the kidney.

#### Important points

- Simple cysts are common and benign.
- Patients on chronic dialysis can develop many cysts, and have an increased risk of developing renal cell carcinoma.

### CYSTIC RENAL DYSPLASIA

**Location:** Can be bilateral or unilateral.

**Microscopic morphology:** Undifferentiated mesenchyme surrounding immature collecting ducts; can also have cartilage.

**Pathogenesis:** Abnormality in metanephric differentiation.

### AUTOSOMAL DOMINANT POLYCYSTIC KIDNEY DISEASE (ADPKD)

**Basic description:** Hereditary condition that usually has its clinical onset (i.e., symptoms) during adulthood.

#### Mutations

- Chromosome 16p13.3 involves *PKD1* gene, which encodes polycystin.
- Chromosome 4q21 involves *PKD2* gene, which encodes polycystin 2.

#### Complications of ADPKD

- **Renal failure:** Most common cause of death. ADPKD causes 5–10% of all cases of chronic renal failure. About 50% of patients progress to chronic renal failure by 60 years of age.
- Hypertension.
- Chronic urinary tract infections.

#### Important points regarding ADPKD

- Associated with berry aneurysms, which can be a source of subarachnoid hemorrhage.
- Associated with cysts of liver and pancreas.
- Can see a myxomatous mitral valve in 20% of patients.

**Gross morphology:** Multiple cysts (up to 4 cm in size), which usually distort the normal architecture of the kidney to a point where it is no longer identifiable as a kidney (Figure 16-16).

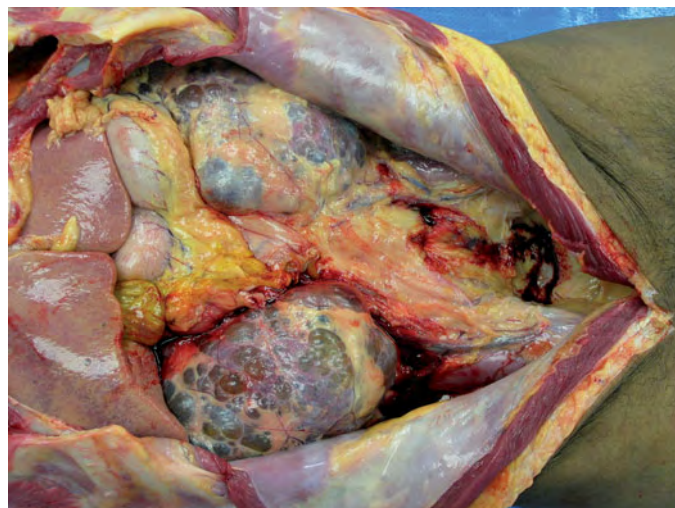
#### Clinical presentation of ADPKD

- **Symptoms:** Abdominal flank pain, back pain, hematuria.
- **Signs:** Abdominal mass, microscopic hematuria, hypertension.

### AUTOSOMAL RECESSIVE POLYCYSTIC KIDNEY DISEASE

**Basic description:** Hereditary condition that usually has its clinical onset (i.e., symptoms) during infancy or childhood.

**Mutation:** 6p21-23 involves *PKHD1* gene, which encodes fibrocystin.



**Figure 16-16.** Adult polycystic kidney disease. Both kidneys are enlarged and multicystic. Adult polycystic kidney disease is responsible for a portion of cases of chronic renal failure. The condition is associated with cerebral berry aneurysms, which may be responsible for the sudden death of the patient.



**Morphology**

- **Gross:** Multiple cysts in cortex and medulla; normal kidney architecture (i.e., the general shape of the kidney) is preserved.
- **Microscopic:** Dilation of collecting tubules.

**RENAL NEOPLASMS**

**Overview:** Although there are many different renal neoplasms, the most common tumor in adults is a renal cell carcinoma, and the most common tumor in children is Wilms tumor.

**RENAL CELL CARCINOMA**

**Epidemiology:** Occurs in sixth and seventh decades of life; predominance of male to female, with a ratio of 2:1.

**Risk factors:** Smoking, cadmium, chronic dialysis.

**Types of renal cell carcinoma:** Although there are several histologic variants of renal cell carcinoma, the most common is the clear cell type, which, along with the chromophobe and papillary types, will be discussed below.

**CLEAR CELL RENAL CELL CARCINOMA**

**Incidence:** About 85% of all renal cell carcinomas.

**Morphology** (Figure 16-17 A and B)

- **Gross:** Yellow (from glycogen) and hemorrhagic.
- **Microscopic:** Clear cells with variably pleomorphic nuclei (graded I–IV, based upon pleomorphism of nuclei); well vascularized.

**Mutations:** Deletion or unbalanced translocations involving 3p. *VHL* gene is on chromosome 3p25 and produces a protein that is a component of ubiquitin-ligase complex, which targets proteins for degradation.

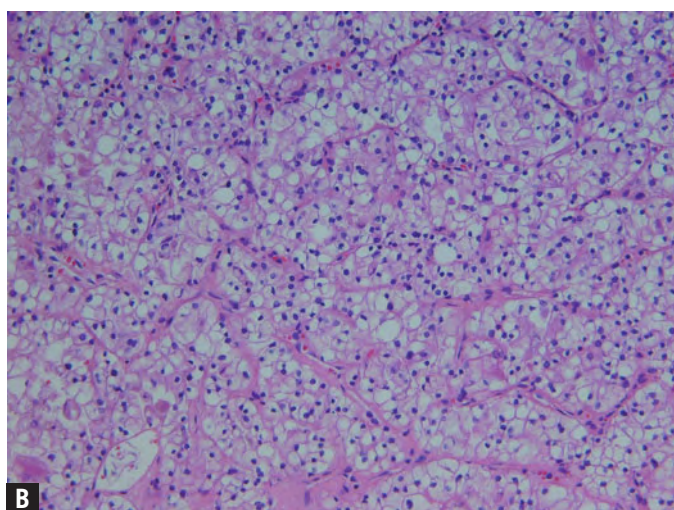
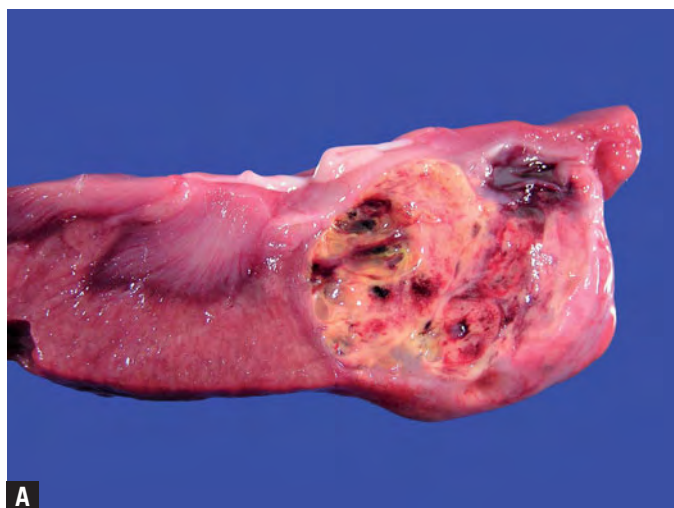
**CHROMOPHOBE RENAL CELL CARCINOMA**

**Incidence:** About 5% of all renal cell carcinomas.

**Morphology**

- **Gross:** Brown mass.
- **Microscopic:** Neoplastic cells with abundant eosinophilic cytoplasm.

**Important point:** Unique among tumors in that they usually have multiple losses of entire chromosomes.



**Figure 16-17.** Renal cell carcinoma, clear cell type. Clear cell renal cell carcinoma has a very characteristic gross appearance, yellow coloration from the glycogen in the tumor cells and hemorrhage due to the prominent vascularity of the tumor (A). Histologically, the neoplasm is composed of clear cells with a background of prominent vascularity (B). Although the tumor cells appear bland (i.e., no pleomorphism, few mitotic figures), renal cell carcinoma is a highly malignant tumor and known for its propensity to metastasize to unusual locations. Hematoxylin and eosin, 200 $\times$ .

## PAPILLARY RENAL CELL CARCINOMA

**Incidence:** About 10% of renal cell carcinomas.

**Microscopic morphology:** Fibrovascular papillae lined with neoplastic cells; foamy macrophages are within the papillae (Figure 16-18).

### Mutations

- *MET* gene on chromosome 7q31.
- *PRCC* gene on chromosome 1.
- Trisomy 7, 16, or 17.

### Important points regarding renal cell carcinoma

- Propensity to invade the renal vein, potentially into the inferior vena cava and even to the heart.
- Produce erythropoietin, resulting in polycythemia.
- Occasionally produce parathormone-like substance and adrenocorticotrophic-like substance.
- Metastases are usually via hematogenous routes; most commonly to the lungs, bone, and liver, and less commonly to the lymph nodes, adrenal glands, and brain. Renal cell carcinoma is also known to metastasize to unusual locations such as the forehead and arm.

### Classic clinical triad of renal cell carcinoma

- Hematuria, flank pain, and palpable mass.
- Only seen in about 10% of patients.

**Paraneoplastic syndromes associated with renal cell carcinoma:** Polycythemia, hypercalcemia, and hypertension.

**Condition associated with development of renal cell carcinoma:** von Hippel-Lindau syndrome (VHL)

- **Mutation:** *VHL* gene on chromosome 3p25; autosomal dominant inheritance.
- **Features of VHL syndrome:** Cerebellar hemangioblastomas; renal cell carcinoma.

## PATHOLOGY OF THE BLADDER AND URETER

**Overview:** This section will discuss urothelial neoplasms in detail and squamous cell carcinoma of the bladder and obstruction of the ureter briefly.

### UROTHELIAL NEOPLASM (TRANSITIONAL CELL CARCINOMA)

**Epidemiology:** Male predominance; 50–80 years of age.

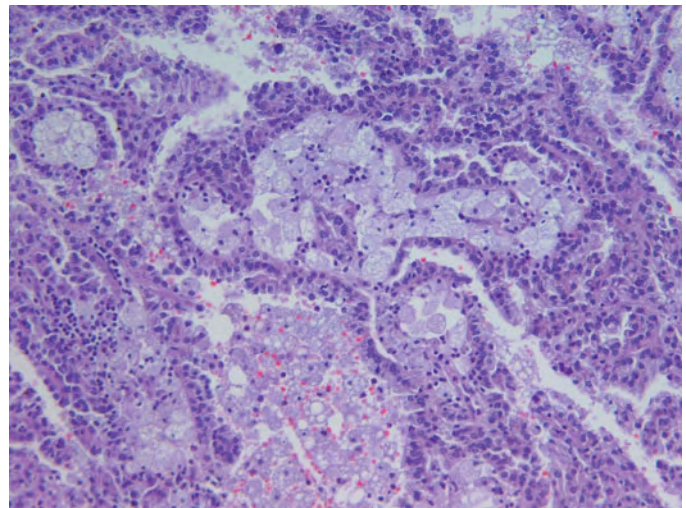
**Risk factors:** Smoking, 2-naphthylamine, long-term analgesic use, chronic cystitis, cyclophosphamide.

### Precursor lesions

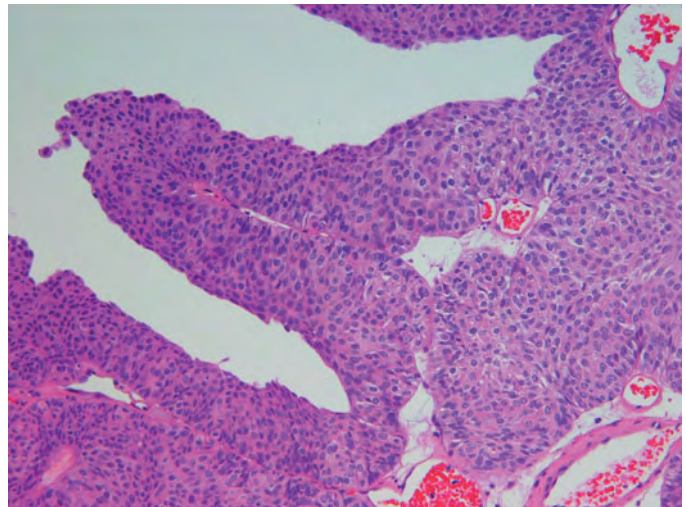
- Papillary urothelial hyperplasia.
- Carcinoma in situ (i.e., cytologically malignant cells in an otherwise flat urothelium).

### Forms of urothelial neoplasms

- Papillary urothelial neoplasia of low malignant potential.
- Low-grade papillary urothelial carcinoma (Figure 16-19).



**Figure 16-18.** Papillary renal cell carcinoma. The histologic architecture of papillary renal cell carcinoma is papillae lined by neoplastic cells, with a core of foamy macrophages. Hematoxylin and eosin, 200×.



**Figure 16-19.** Low-grade papillary urothelial neoplasm. The majority of urothelial neoplasms are low grade and have a papillary architecture. These tumors can easily be debulked, and although they recur, can be debulked again. However, invasion into the wall of the bladder usually requires a cystectomy as part of the treatment. Hematoxylin and eosin, 200×.



- High-grade papillary urothelial carcinoma.
- Invasive urothelial carcinoma (Figure 16-20 A and B).

#### Mutations

- 9p deletion in papillary tumors.
- 17p deletion in invasive urothelial carcinoma.

#### Important points regarding urothelial neoplasms

- Many lesions are papillary and noninvasive; therefore, they can be removed without removing the bladder itself.
- Muscularis propria invasion is a poor prognostic indicator (50% mortality within 5 years).
- Usually cause death by obstruction of the ureter, with resultant pyelonephritis, hydronephrosis, and renal failure.

**Clinical presentation of urothelial neoplasms:** Painless hematuria.

**Causes of squamous cell carcinoma of the bladder:** Schistosomiasis infection; chronic inflammation and irritation.

### OBSTRUCTION OF THE URETER

**Complications:** Hydronephrosis, hydroureter, and sometimes pyelonephritis.

#### Causes of ureter obstruction

- **Intrinsic causes:** Calculi, strictures, tumors, blood clots, neurogenic.
- **Extrinsic causes:** Pregnancy, tumors.

### ACID-BASE DISORDERS

**Overview:** There are four basic types of acid-base disorders: respiratory alkalosis, respiratory acidosis, metabolic alkalosis, and metabolic acidosis. The diagnosis of the basic types of acid-base disorders is relatively straightforward; however, acid-base disorders can also be mixed (i.e., more than one type of disorder is present). The formulas to identify an acid-base disorder are presented below and in Table 16-5. The explanation of the diagnosis of a mixed acid-base disorder is beyond the scope of this book, however.

#### RESPIRATORY ALKALOSIS

**Definition:** pH of  $> 7.45$ ;  $p\text{CO}_2$  of  $< 35$  mm Hg.

#### Causes

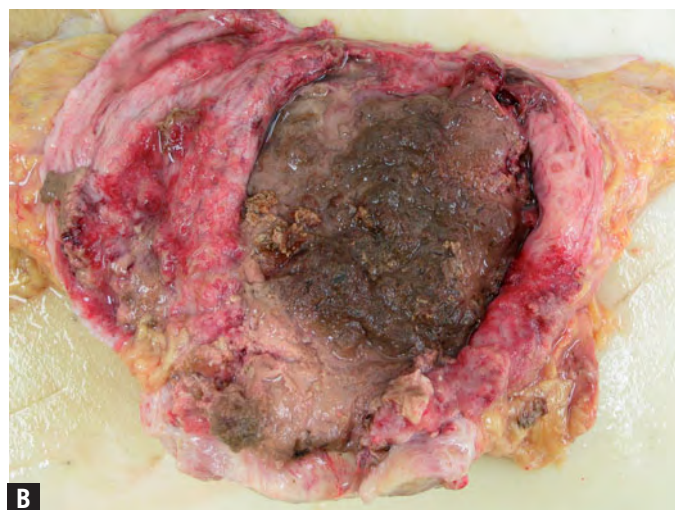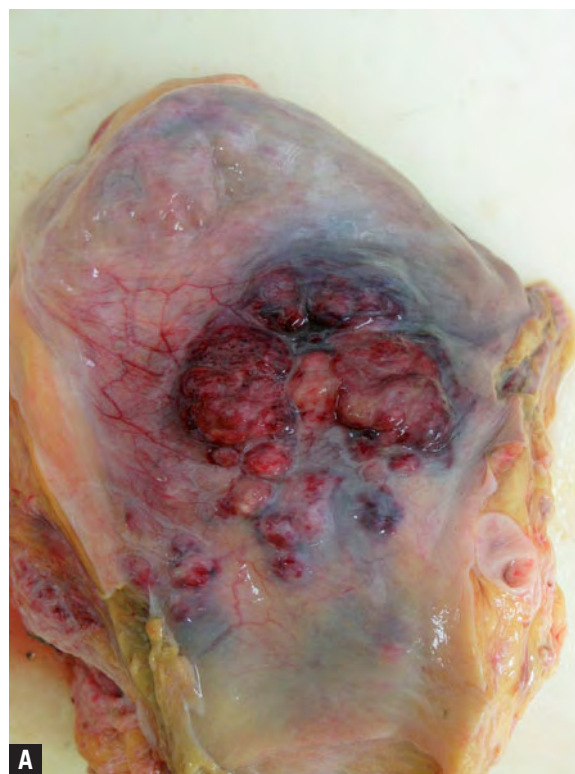- **Acute respiratory alkalosis:** Include hyperventilation (e.g., anxiety); drugs.
- **Chronic respiratory alkalosis:** Include lung carcinoma.

#### RESPIRATORY ACIDOSIS

**Definition:** pH of  $< 7.35$ ;  $p\text{CO}_2$  of  $> 45$  mm Hg.

#### Causes

- **Acute respiratory acidosis:** Include CNS depression, airway obstruction, and thoracic cage injury.
- **Chronic respiratory acidosis:** Include obstructive lung disease.



**Figure 16-20.** Invasive urothelial carcinoma. The posterior surface of the bladder (A) shows tumor nodules from an invasive urothelial carcinoma, which has perforated the wall. In (B), the bladder has been opened, revealing the flat, friable, tan-brown neoplasm lining the inner surface.

**TABLE 16-5.** Basic Laboratory Testing for Acid-base Disorders

Disorder	pH	$p\text{CO}_2$	$\text{HCO}_3^-$
Respiratory alkalosis	$> 7.45$	$< 35$ mmHg	
Respiratory acidosis	$< 7.35$	$> 45$ mmHg	
Metabolic alkalosis	$> 7.45$		$> 23$ mEq/L
Metabolic acidosis	$< 7.35$		$< 18$ mEq/L



## METABOLIC ALKALOSIS

**Definition:** pH of  $> 7.45$ ; bicarbonate ( $\text{HCO}_3^-$ ) of  $> 23$  mEq/L.

### Causes

- **If urinary chloride is decreased:** Include vomiting, nasogastric suction, and diuretics.
- **If urinary chloride is normal:** Include excess mineralocorticoids.

**Important point:** Metabolic alkalosis carries a much graver prognosis than metabolic acidosis. Nearly 50% of patients with a pH  $> 7.55$  die.

## METABOLIC ACIDOSIS

**Definition:** pH of  $< 7.35$ ; bicarbonate of  $< 18$  mEq/L.

**Definition of anion gap:** Sodium minus (chloride plus bicarbonate).

- If  $> 15$  mEq/L, the patient has a probable metabolic acidosis.
- If  $> 25$  mEq/L, the patient has a definitive metabolic acidosis.

### Causes of metabolic acidosis

- **If anion gap is increased:** Include ketoacidosis, lactic acidosis, uremia, methanol, and ethylene glycol.
- **If anion gap is normal:** Include diarrhea and renal bicarbonate loss.

## DETERMINATION OF MIXED ACID-BASE DISORDER

**Important formulas:** In a simple acid-base disorder, these are the expected values for compensatory changes made. If the changes seen in the patient are not within these parameters, the disorder is most likely mixed.

### In respiratory acidosis

#### ■ If acute

- 1 mEq/L  $\text{HCO}_3^-$  per 10 mm Hg  $\text{CO}_2$
- 0.8 mEq  $[\text{H}^+]$  per 1 mm Hg  $\text{pCO}_2$

- **If chronic:** 3.5 mEq/L  $\text{HCO}_3^-$  per 10 mm Hg  $\text{CO}_2$

### In respiratory alkalosis

#### ■ If acute

- 2 mEq/L  $\text{HCO}_3^-$  per 10 mm Hg  $\text{CO}_2$
- 0.8 mEq  $[\text{H}^+]$  per 1 mm Hg  $\text{pCO}_2$

- **If chronic:** 5 mEq/L  $\text{HCO}_3^-$  per 10 mm Hg  $\text{CO}_2$

### In metabolic acidosis

- $\text{pCO}_2 = 1.5 (\text{HCO}_3^-) + 8 \pm 2$  or
- Change in  $\text{pCO}_2 = 1.2 (\text{change HCO}_3^-) \pm 2$

### In metabolic alkalosis

- $\text{pCO}_2 = 0.6 (\text{change in HCO}_3^-) \text{ or}$
- $\text{pCO}_2 = 0.9 (\text{HCO}_3^-) + 9$

## SODIUM AND POTASSIUM ELECTROLYTE DISORDERS

### HYPERNATREMIA

#### Causes

- Water loss, as occurs in profuse sweating, fever, burns, hyperventilation, osmotic diarrhea, and diabetes insipidus.
- Sodium retention.

#### Clinical presentation of hypernatremia

- **Symptoms:** Lethargy, weakness, agitation, seizures, and coma. Rapid correction of hypernatremia results in cerebral edema.
- **Laboratory testing**
  - If urine osmolality is  $> 400$  mOsm/kg, it suggests osmotic diarrhea, burns, or profuse sweating. This urine osmolality is consistent with loss of water, with attempted renal saving of water.
  - If urine osmolality is  $< 250$  mOsm/kg, it suggests diabetes insipidus. To aid in diagnosis, give the patient vasopressin. Patients with central diabetes insipidus will respond; those with nephrogenic diabetes insipidus will not respond.

### HYPERKALEMIA

#### Causes

- Decreased excretion. Renal failure is the most common cause of hyperkalemia.
- Increased intake of potassium.
- Increased movement of potassium from cells to extracellular space (e.g., in acidosis, insulin deficiency, cell lysis, drug use).

**Clinical presentation:** Peaked T waves on electrocardiogram and short QT interval progressing to wide QRS, which can lead to ventricular fibrillation.

### HYPONATREMIA

#### Causes

- Sodium loss.
- Free water retention
  - Conditions causing hypervolemia (e.g., congestive heart failure, ascites).
  - Increased levels of antidiuretic hormone (e.g., SIADH, adrenal insufficiency).

#### Clinical presentation of hyponatremia

- **Symptoms:** Lethargy, encephalopathy, seizures, and coma. Rapid correction of hyponatremia causes central pontine myelinolysis.
- **Laboratory (urine sodium)**
  - If  $< 25$  mEq/L, the body is conserving sodium.
  - If  $> 40$  mEq/L, the body is *not* conserving sodium, which suggests SIADH, diuretics, or renal failure.

## HYPOKALEMIA

### Causes

- Diuretics and gastrointestinal conditions such as diarrhea or vomiting are the most common causes.
- Decreased intake.
- Increased loss, as occurs in sweating, dialysis, diarrhea, and vomiting; in vomiting, hypokalemia is due to volume depletion and metabolic alkalosis.
- Increased entry into cells (e.g., in alkalosis, insulin use, hypothermia).
- Other causes of hypokalemia: increased levels of mineralocorticoids or renin.

### Clinical presentation of hypokalemia

- **Symptoms:** Muscle weakness, cardiac dysrhythmias, glucose intolerance.
- **Signs:** Flattened T wave, prominent U wave. Hypokalemia has a synergistic effect on digitalis toxicity.
- **Laboratory findings (urine potassium)**
  - If  $< 25$  mEq/day, suggests extrarenal loss.
  - If  $> 30$  mEq/day, suggests renal wasting (e.g., due to increased mineralocorticoids, tubular defect).





# CHAPTER 17

## PATHOLOGY OF THE MALE AND FEMALE REPRODUCTIVE TRACT AND BREAST

### OVERVIEW

Testicular and ovarian pathology focuses predominantly on neoplasms, although not all clinically important pathologic processes of these organs are neoplastic. The majority of testicular tumors are derived from germ cells, and the majority of ovarian tumors are derived from surface epithelial cells. Many germ cell tumors in the testes and in the ovaries share common features. One important pathologic process in both the penis and in the cervix is squamous cell carcinoma, caused by the human papillomavirus (HPV). In the prostate, there are basically three pathologic processes that are of most importance: acute prostatitis, benign prostatic hyperplasia, and prostatic adenocarcinoma. The breast hosts a multitude of histologic abnormalities, from fibrocystic disease to invasive ductal adenocarcinoma. With many of the benign lesions, their importance lies in their associated risk of later development of invasive carcinoma.

This chapter will discuss testicular tumors, squamous cell carcinoma of the penis, prostatic pathology (including benign prostatic hyperplasia and prostatic adenocarcinoma), tumors of the vagina, cervical intraepithelial neoplasia (CIN) as a precursor of squamous cell carcinoma of the cervix, amenorrhea, pelvic inflammatory disease, uterine pathology (including endometrial hyperplasia and endometrioid adenocarcinoma), ovarian pathology (including neoplasms), various disorders of pregnancy, and breast pathology (including non-neoplastic and neoplastic diseases).

### TESTICULAR NEOPLASMS

**Overview:** All masses of the testes are considered malignant until proven otherwise. Approximately 95% of testicular tumors are derived from germ cells ([Figure 17-1](#)). Seminomas tend to remain localized in the testis for a longer period, are radiosensitive, and metastasize to lymph nodes, whereas nonseminomatous

neoplasms metastasize sooner, are radioresistant, and tend to metastasize via hematogenous routes. The classic presentation of testicular cancer is a painless testicular mass.

#### Sites of metastases from testicular neoplasms

- **Lymph nodes:** Para-aortic, mediastinal, and supraclavicular lymph nodes.
- **Hematogenous dissemination:** Lungs, liver, brain, bone.

#### Two categories of testicular neoplasms

- Germ cell (most common type of testicular neoplasm).
- Non-germ cell (including sex cord-stromal tumors and Leydig cell tumors).

#### Risk factors for development of testicular neoplasms

- **Cryptorchidism** (i.e., undescended testicle).
- Syndromes with testicular dysgenesis (e.g., Klinefelter syndrome).
- Family history and history of a tumor in the contralateral testis.

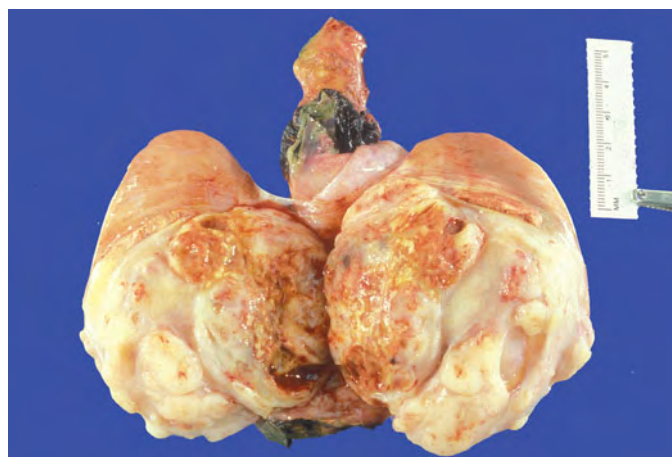
#### World Health Organization (WHO) classification of testicular neoplasms

- Tumors with one histologic pattern.
- Tumors with more than one histologic pattern (also referred to as mixed germ cell tumor), which account for 60% of testicular tumors.

**Mutations:** Isochromosome (12p) is found in virtually all germ cell tumors. It encodes the *DAD-R* gene, which produces a protein that prevents apoptosis.

### TYPES OF GERM CELL TUMORS AND THEIR PRECURSORS

**Overview:** Intratubular germ cell neoplasia and five common types of germ cell tumors (seminoma, embryonal carcinoma, yolk sac tumor, choriocarcinoma, and teratoma) are discussed below. Remember, although the germ cell tumors are being discussed under testicular tumors, they also occur in the ovary. For clinical purposes, the important distinction is seminoma versus non-seminomatous germ cell tumor, because seminomas are radiosensitive and the other germ cell tumors are radioresistant (Table 17-1).



**Figure 17-1.** Mixed germ cell tumor of testis. This testicle has been bisected (the spermatic cord is at the 12-o'clock position), revealing an expansive mass in the parenchyma. The mass has a variegated appearance, consistent with a mixed germ cell tumor.

**TABLE 17-1.** Comparison of Germ Cell Neoplasms

Neoplasm	Radiosensitive?	Protein Secreted	Age Range
Seminoma	Yes	hCG (15% of tumors)	15–35 years
Embryonal carcinoma	No	hCG and AFP	20–30 years
Yolk sac tumor	No	AFP	If pure, 3 years
Choriocarcinoma	No	hCG	20–30 years
Teratoma	No	None	18 years

hCG, human chorionic gonadotropin; AFP,  $\alpha$ -fetoprotein.



### INTRATUBULAR GERM CELL NEOPLASIA

**Basic description:** Preneoplastic proliferation of germ cells within seminiferous tubules.

**Important points:** Approximately 50% of cases progress to a germ cell tumor within 5 years. The main risk factor for intratubular germ cell neoplasia is cryptorchidism.

### SEMINOMA

**Epidemiology:** Most arise between 15 and 35 years of age.

#### Important points

- Seminomas are radiosensitive.
- A dysgerminoma is the ovarian correlate of the seminoma (i.e., the tumors have the same features but different names).

#### Morphology of seminoma

- **Gross:** Homogenous tan mass.
- **Microscopic:** Large mononuclear cells with clear cytoplasm and fibrous septae with lymphocytes (Figure 17-2). Approximately 10–15% of seminomas can have giant cells (syncytiotrophoblasts), in which case human chorionic gonadotropin (hCG) can be detected in the blood.

**Clinical presentation of seminoma:** Painless testicular mass. Approximately 15% have metastasized to local lymph nodes at the time of diagnosis. Prognosis is excellent, with cure rates close to 100% for stage I and stage II disease.

### EMBRYONAL CARCINOMA

**Epidemiology:** Many occur between 20 and 30 years of age.

#### Important points

- Approximately 90% of patients have elevated  $\beta$ -hCG or  $\alpha$ -fetoprotein (AFP).
- An embryonal carcinoma is only pure in 2–3% of cases. In most cases, an embryonal carcinoma occurs as part of a mixed tumor.

#### Morphology of embryonal carcinoma

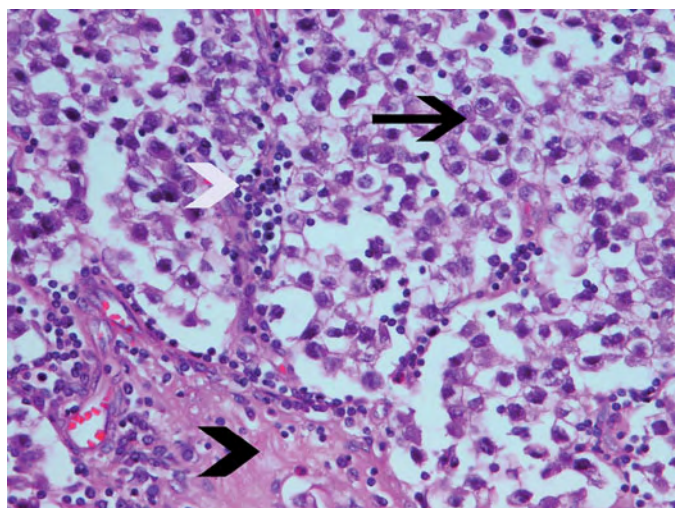
- **Gross:** Hemorrhagic and necrotic mass.
- **Microscopic:** Alveolar or tubular architecture; pleomorphic, primitive looking “ugly” cells with abundant mitotic figures.

### YOLK SAC TUMOR (FIGURE 17-3)

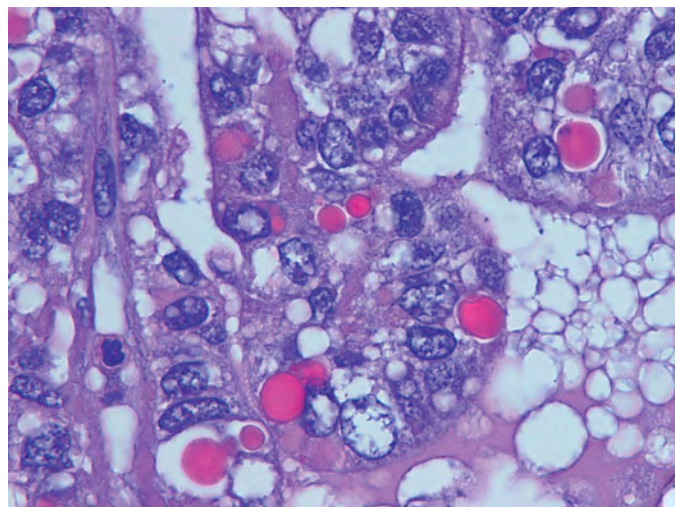
**Epidemiology:** Only occurs as a pure tumor in young males (at about 3 years of age). In adults, yolk sac tumors are part of mixed germ cell tumors.

**Important point:** Positive for AFP (see Figure 17-3).

**Microscopic morphology of yolk sac tumor:** May have a variety of histologic patterns. One characteristic feature is **Schiller-Duval bodies**, which resemble endodermal sinuses. Schiller-Duval bodies have a capillary at the core and are surrounded by a visceral and a parietal layer (i.e., resemble primitive glomerulus).



**Figure 17-2.** Seminoma. The three characteristic microscopic features of seminomas are large mononuclear cells (arrow), fibrous septae (black arrowhead), and lymphocytes (white arrowhead). Seminomas have a characteristic gross appearance (i.e., homogenous and tan). Hematoxylin and eosin, 400 $\times$ .



**Figure 17-3.** Yolk sac tumor. The eosinophilic globules are composed of  $\alpha$ -fetoprotein (AFP). The production of AFP is characteristic of yolk sac tumors. Hematoxylin and eosin, 400 $\times$ .



## CHORIOCARCINOMA

**Epidemiology:** Many occur between 20 and 30 years of age.

### Important points

- Choriocarcinoma produces  $\beta$ -hCG.
- Rarely a pure tumor; almost always occurs as part of a mixed tumor.
- Unlike most other tumors, metastases in choriocarcinomas are primarily hematogenous.
- The tumor is responsive to chemotherapy, and prognosis is usually good.

**Morphology of choriocarcinoma** (Figure 17-4 A and B)

- **Gross:** Hemorrhagic mass. Small tumors often have extensive metastases at the time of presentation.
- **Microscopic:** Syncytiotrophoblasts (multinucleated cells) and cytotrophoblasts.

## TERATOMA

**Basic description:** Tumor derived from all three germ cell layers.

**Epidemiology:** Many occur at about 18 years of age.

**Types of teratoma:** Mature, immature, and teratomas with malignant transformation.

### Important points

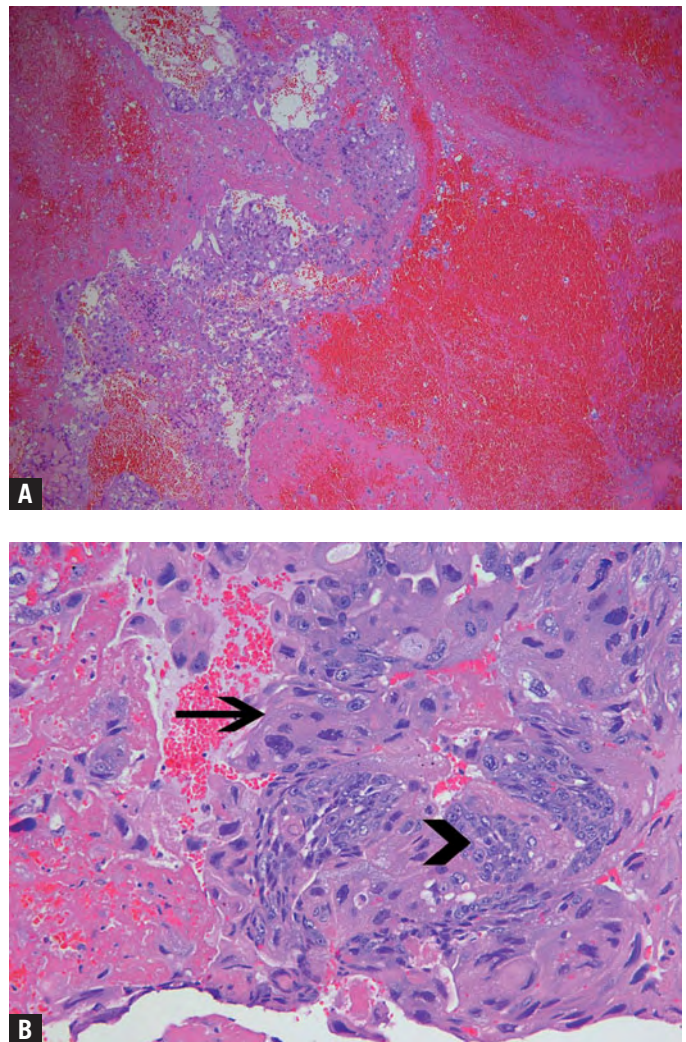
- Pure teratomas occur in males before puberty and can be benign (if mature).
- In adults, teratomas are almost always part of a mixed germ cell tumor; therefore, even mature teratomas should be considered malignant. In adult males, it is assumed there is another component to the tumor in addition to just the mature teratoma, even if it is not seen on the histologic slide. Immature teratomas are always considered malignant.

### Microscopic morphology of teratoma

- **Mature teratoma:** Fully differentiated tissue from all three germ lines that is haphazardly arranged.
- **Immature teratoma:** Areas of tumor have appearance of fetal or embryonic tissue.
- **Malignant transformation of teratoma:** Development of tumor (e.g., squamous cell carcinoma or adenocarcinoma) from benign component of mature teratoma.

**Clinical presentation of teratoma:** Teratomas can present as a testicular mass, as a pure teratoma, or as part of a mixed tumor; extragonadal (outside of testis) teratomas are not uncommon. Classic extragonadal presentations include the congenital sacrococcygeal teratoma, which is more common in females, and the anterior mediastinal mass.

**Types of non-germ cell tumors:** Although the most frequent type of tumor occurring in the testis is a germ cell tumor, several types of non-germ cell tumors occur in the testis as well. Of these types, the two types that will be discussed here are lymphoma and spermatocytic seminoma.



**Figure 17-4.** Choriocarcinoma. **A**, Hemorrhage shown in the right lower corner is characteristic of these tumors. **B**, The two cell types that occur in choriocarcinomas are syncytiotrophoblasts (arrow) and cytotrophoblasts (arrowhead). Hematoxylin and eosin, **A**, 40 $\times$ ; **B**, 400 $\times$ .

## LYMPHOMA

**Epidemiology:** Usually occurs in patients older than 60 years of age.

**Important points:** Usually bilateral, and most have disseminated at the time of diagnosis. Lymphoma is the most common testicular mass in men older than 60 years of age.

## SPERMATOCYTIC SEMINOMA

**Epidemiology:** Usually occurs in patients about 65 years of age.

**Important points:** Does *not* arise from intratubular germ cell neoplasia and rarely if ever metastasizes.

**Microscopic morphology of spermatocytic seminoma:** Composed of three cell types: small, medium, and large.

## NON-NEOPLASTIC TESTICULAR MASSES

- **Hydrocele:** Collection of fluid in tunica vaginalis. Presents as nontender testicular fluid collection, which can be transilluminated.
- **Hematocoele:** Accumulation of blood.
- **Varicocele:** Dilation of veins of pampiniform plexus. Most cases occur on the left side. The classic presentation of a varicocele is testicular pain, which is worse when standing; scrotal enlargement and “bag of worms” texture to palpation. If left untreated, a varicocele may cause infertility.
- **Torsion:** Testis twists on itself, cutting off venous supply but not arterial flow. The result is a hemorrhagic infarct. The clinical presentation is sudden onset of excruciating testicular pain with a tender, swollen, “high riding” testicle. Testicular torsion is a surgical emergency.

## SQUAMOUS CELL CARCINOMA OF THE PENIS

**Overview:** Squamous cell carcinoma of the penis is an uncommon lesion occurring almost entirely in uncircumcised men. Like squamous cell carcinoma of the cervix, squamous cell carcinoma of the penis is associated with HPV infection.

**Epidemiology:** Males between 40 and 70 years of age.

### Risk factors

- Uncircumcised.
- Infection with HPV, including HPV types 16 and 18.

### Precursor lesions to squamous cell carcinoma of the penis

- **Bowen disease:** Carcinoma in situ on the shaft of the penis.
- **Erythroplasia of Queyrat:** Erythematous patch on the glans, which, histologically, is carcinoma in situ.
- **Bowenoid papulosis:** Occurs on the shaft. Most patients do not progress to invasive squamous cell carcinoma.

## PATHOLOGY OF THE PROSTATE

**Overview:** The three main pathologic conditions affecting the prostate are acute prostatitis, benign prostatic hyperplasia, and prostatic adenocarcinoma.

### ACUTE PROSTATITIS (FIGURE 17-5)

**Associated conditions:** Infection of the urinary bladder or urethra, obstruction (e.g., due to prostatic hyperplasia), and human immunodeficiency virus (HIV) infection.

**Causative organisms:** In men older than 35 years of age, *Escherichia coli*, *Enterobacter*, and other urinary tract pathogens are the most common cause of acute prostatitis. In men younger than age 35 years, *Neisseria gonorrhoeae* and *Chlamydia* are the causative agents until proven otherwise.

**Complications of acute prostatitis:** Chronic prostatitis, which can be source of recurring urinary tract infections in older males because antibiotics poorly penetrate the prostate.

#### Clinical presentation of acute prostatitis

- **Symptoms:** Dysuria, urinary frequency, lower back pain.
- **Signs:** Boggy, tender prostate on examination. Leukocytosis, fever, and elevated prostate-specific antigen (PSA) are common.

### BENIGN PROSTATIC HYPERPLASIA

**Basic description:** Hyperplasia of glandular and stromal elements of prostate.

**Epidemiology:** More common with increasing age; usually males older than 50 years of age.

**Location of benign prostatic hyperplasia:** Usually involves the parenchyma around the urethra (i.e., transitional zone) first, and produces urinary obstruction.

**Pathogenesis:** Results from action of androgens. Testosterone is converted to dihydrotestosterone by 5 $\alpha$ -reductase.

#### Complications of benign prostatic hyperplasia

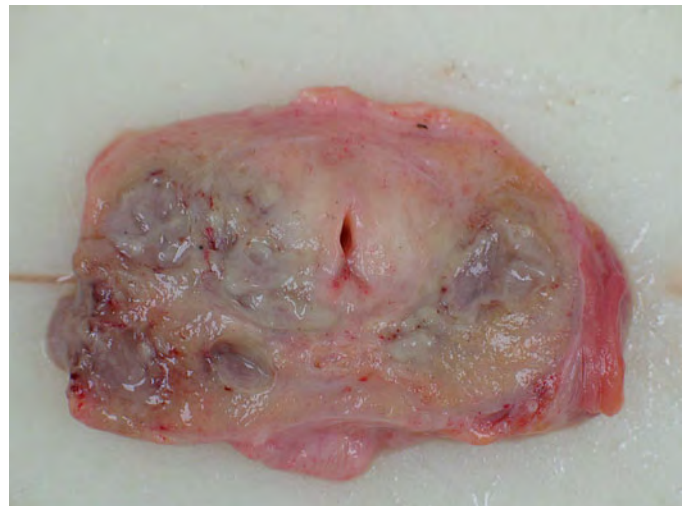- Urinary obstruction, which is subsequently risk for urinary tract infection; postrenal azotemia, hydronephrosis, renal failure, and kidney stones.
- Benign prostatic hyperplasia is *not* considered a premalignant condition.

#### Morphology of benign prostatic hyperplasia

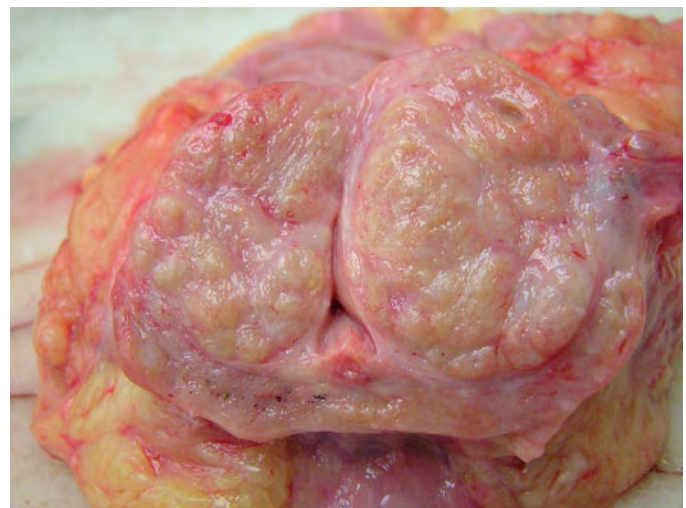
- **Gross:** Well-circumscribed nodules in the center of the gland around the urethra (Figure 17-6).
- **Microscopic:** Nodules of glandular hyperplasia associated with stromal hyperplasia; can have squamous metaplasia surrounding infarcts.

#### Clinical presentation of benign prostatic hyperplasia

- **Symptoms:** Increased frequency of urination, nocturia, difficulty starting and stopping urine flow, and incomplete voiding.
- **Signs:** Enlarged gland on digital rectal examination, with no nodules; gland may be tender upon palpation.



**Figure 17-5.** Acute prostatitis. Note the scattered yellow-green depressed regions, which are abscesses. Prostatitis can serve as the source of bacteria in patients with chronic urinary tract infections.



**Figure 17-6.** Benign prostatic hyperplasia. Note the large nodules of hyperplastic parenchyma compressing the urethra (center). The posterior aspect of the gland is at the 6-o'clock position and is uninvolved. Prostatic adenocarcinoma more commonly arises in this region and can be palpated upon digital rectal examination.



## PROSTATIC ADENOCARCINOMA

**Epidemiology:** Males, age 60 years and older; second leading cause of cancer deaths in men.

**Location:** Peripheral portion of gland and, therefore, palpated by digital rectal examination.

**Important point:** Prostatic adenocarcinoma is known for osteoblastic metastases to lumbar spine, proximal femur, and pelvis, which can cause increased alkaline phosphatase.

**Genetics:** Prostatic adenocarcinoma commonly has hypermethylation of glutathione S-transferase gene promoter (GSTP1), which is found on chromosome 11q13.

**Precursor:** High-grade prostatic intraepithelial neoplasia (PIN).

**Gleason grading system for prostatic adenocarcinoma:** Final grade is two numbers (e.g., 3 + 3) representing the dominant (first number) and subdominant (second number) histologic appearance. The dominant and subdominant histologic appearances are each graded from 1 to 5, depending upon the fusion of tubules and the presence of single cells; the lower the number, the lower the grade of the tumor.

**Morphology of prostatic adenocarcinoma (Figure 17-7 A and B)**

■ **Gross:** Yellow discoloration; usually involves periphery of the gland first.

■ **Microscopic**

- **Low power:** Small glands, back-to-back.
- **High power:** Single cell layer (i.e., no basal cell layer as found in the normal prostate), prominent nucleoli, crystals, blue mucin; known for perineural invasion.

**Clinical presentation of prostatic adenocarcinoma**

■ **Symptoms:** Decreased urinary stream, urinary frequency; back pain from osteoblastic metastases to lumbar spine.

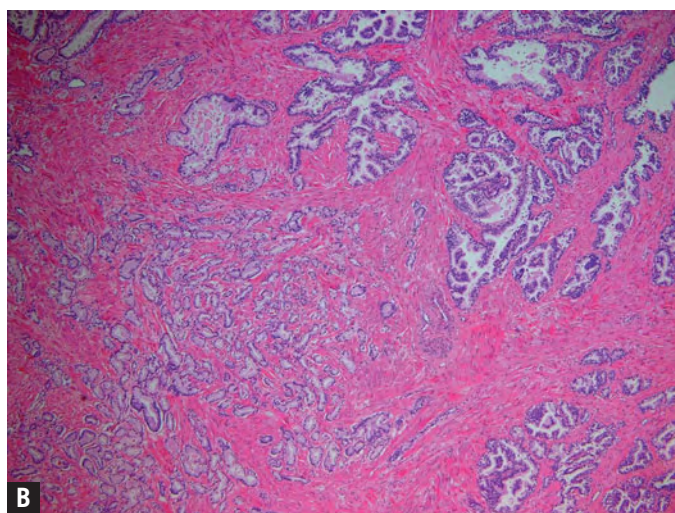
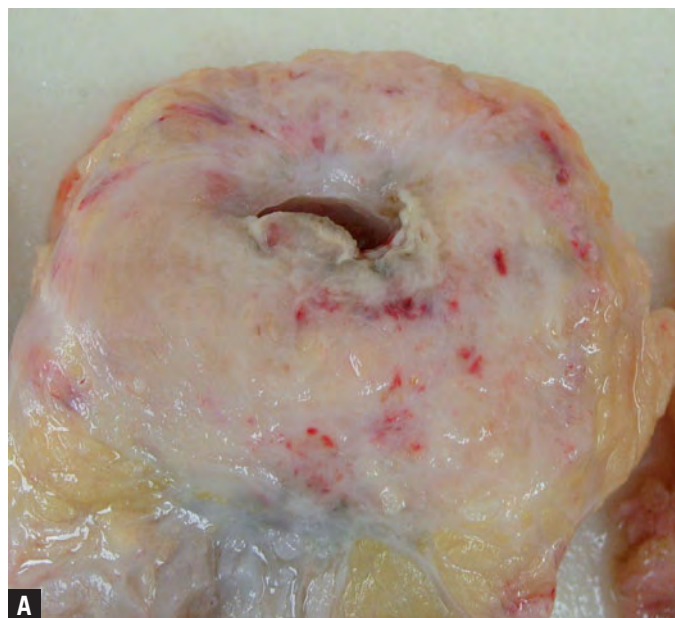
■ **Signs:** Nodules or induration (i.e., hardness) felt upon digital rectal examination.

■ **PSA**

- PSA level of 4–10 ng/mL is gray zone; < 4 ng/mL is rarely cancer; > 10 ng/mL is most likely cancer; and 4–10 ng/mL is of uncertain etiology.
- **Important point regarding PSA testing:** Free PSA level is good for evaluation of patients in the 4–10 ng/mL range; normal free PSA level is < 24% of the total PSA
- **Other causes of elevated PSA:** BPH, prostatitis, prostate massage, cystoscopy, transurethral resection of the prostate (TURP), prostate biopsy.

■ **Other laboratory studies for evaluating PSA**

- **PSA density:** Is calculated as PSA divided by weight of prostate gland (weight of prostate determined by transrectal ultrasound); a PSA density of > 0.15 suggests carcinoma.
- **PSA velocity:** Rate of change in PSA; suspicious for carcinoma if > 0.75 ng/mL/year.



**Figure 17-7.** Prostatic adenocarcinoma. **A**, Note the blurring and obliteration of normal parenchyma from the 5-o'clock to the 9-o'clock position in this prostate. This tumor has arisen in the posterior portion of the gland. **B**, The initial diagnosis of prostatic adenocarcinoma is based upon the low power appearance. The small glands that are back-to-back in the left lower corner are characteristic of prostatic adenocarcinoma; compare these to the larger, more widely separated normal glands in the upper right corner. Hematoxylin and eosin, 40 $\times$ .

- **Diagnosis of prostatic adenocarcinoma:** Made by physical examination plus prostatic biopsy. An elevated PSA can help screen for, diagnose, and monitor prostatic adenocarcinoma.

## TUMORS OF THE VAGINA

**Squamous cell carcinoma:** Associated with HPV (see CIN).

**Clear cell adenocarcinoma:** Occurs in young females whose mothers received diethylstilbestrol (DES) during pregnancy; vaginal adenosis is the precursor lesion.

## CERVICAL INTRAEPITHELIAL NEOPLASIA AND SQUAMOUS INTRAEPITHELIAL LESION

**Overview:** Cervical intraepithelial neoplasia (CIN grades I–III) and squamous intraepithelial lesions (SIL) are dysplastic changes in the cervical epithelium that are a precursor to malignancy (i.e., squamous cell carcinoma of the cervix) and are the result of infection with HPV.

**Basic description of grades of CIN:** CIN grades I–III refer to how high within the epithelium the dysplastic changes are present. In CIN I, the changes are one third of the distance from the basement membrane to the surface of the cervical mucosa. In CIN II, changes are two thirds of the distance, and in CIN III, the dysplastic changes extend from the basement membrane almost all the way to the top of the mucosa. The diagnosis of CIN is based upon biopsy of the cervix.

**Basic description of grades of SIL:** SIL is divided into two grades. Low-grade SIL usually corresponds to CIN I, and high-grade SIL usually corresponds to CIN II and III. SIL is based upon the appearance of cells in Papanicolaou (PAP) smears.

### Risk factors for CIN and SIL

- In virtually all cases, CIN and SIL arise because of infection with HPV.
- The risk factors for CIN and SIL are early age at first intercourse, multiple sexual partners, male partner with multiple sexual partners, multiparity, and smoking. As with most cancers, the risk of cervical cancer increases with increasing age. The risk of cervical cancer is dramatically higher in women with HIV infection.

### Risk for progression to squamous cell carcinoma based upon HPV type

- Low-grade SIL and CIN I lesions are caused by HPV types 6, 11, 42, and 44, and have a low risk for progression to squamous cell carcinoma.
- High-grade SIL and CIN II–III lesions are caused by HPV types 16, 18, 31, 33, 35, 39, 45, and 52, and have a high risk for progression.

**Significance of CIN and SIL:** Low-grade SIL and CIN I lesions are likely to regress; high-grade SIL and CIN II–III lesions are more likely to progress to an invasive squamous cell carcinoma.



### Pathogenesis of CIN and SIL

- Protein E6, produced by HPV, binds to and induces degradation of p53.
- Protein E7, produced by HPV, binds to and inhibits RB.

**Important points:** The development of the PAP smear, which allows for screening of preneoplastic lesions, has greatly reduced the death rate from squamous cell carcinoma of the cervix. Unlike HSV infection, most HPV infections will resolve over time, unless the patient smokes. The advent of the HPV vaccine, which will confer some immunity against two cancer-causing HPV serotypes, is expected to further reduce the incidence of cervical cancer.

**Microscopic morphology of CIN:** Dysplastic changes, including increased nuclear basophilia, mitotic figures, high nuclear/cytoplasmic (N/C) ratio, and disorganized growth are observed at different levels in the mucosa. **Koilocytes** are a viral change associated with CIN I. They have a wrinkled (i.e., “raisinoid”) nucleus surrounded by a clear halo. Koilocytes are found in the upper portion of the mucosa, but this *does not* imply a high-grade (e.g., CIN II–III) lesion (Figure 17-8 A–C).

**Clinical presentation:** CIN and squamous cell carcinoma of the cervix can be asymptomatic. The most common presenting symptom in cervical cancer is abnormal vaginal bleeding or postcoital spotting. The most common cause of death in cervical cancer is uremia from ureteral obstruction.

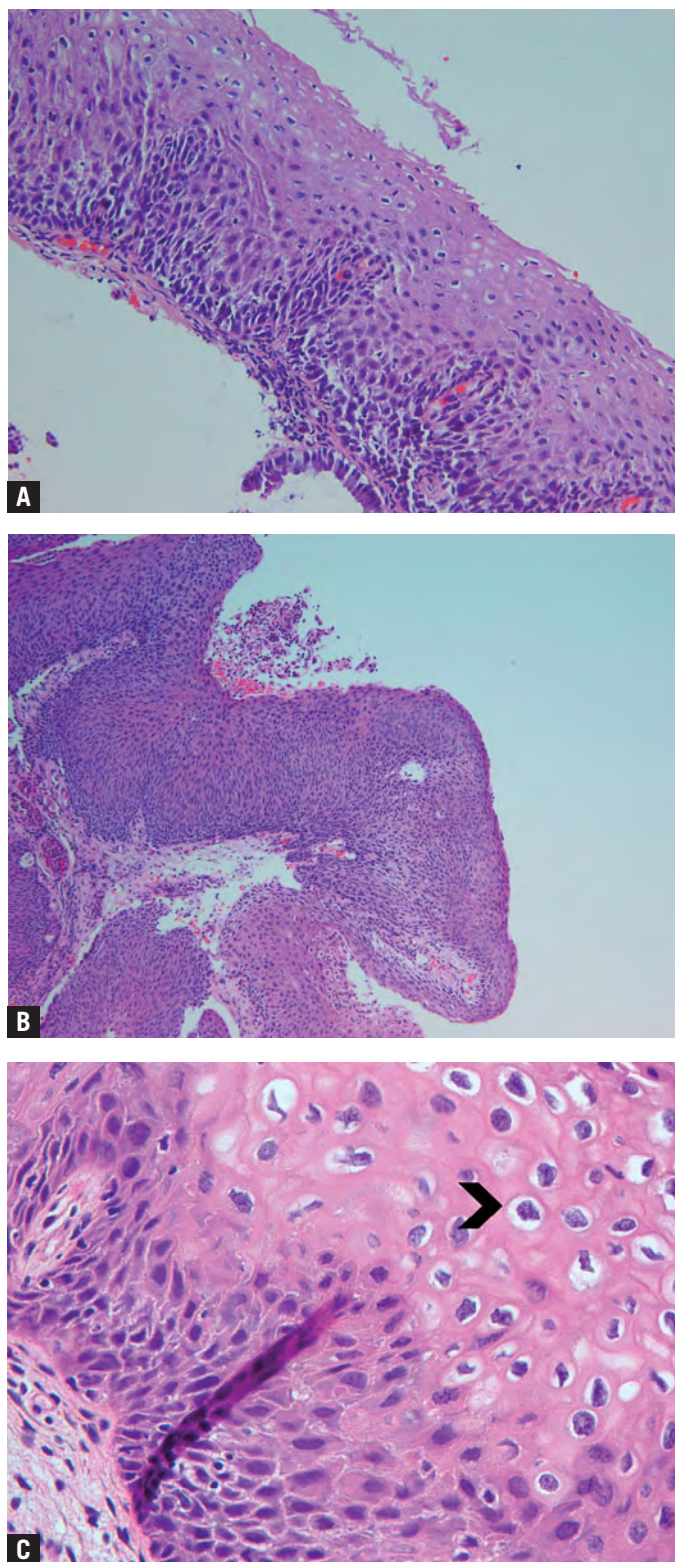
**Diagnosis:** High-grade lesions on PAP smear and any suspicious lesion noted on examination should prompt colposcopic examination and either a biopsy or excisional biopsy. The PAP smear is *NOT* a test used to diagnose cervical cancer. Findings on colposcopic examination include “acetowhite” change (when the cervix is painted with acetic acid), color change, and atypical vascular changes (i.e., corkscrew and hairpin vessels).

## PELVIC INFLAMMATORY DISEASE (PID)

**Basic description:** Inflammation of the pelvic organs (i.e., fallopian tubes and ovaries).

**Causative organisms:** *Chlamydia*, *Neisseria gonorrhoeae*; *Streptococcus* and *Staphylococcus* in the postpartum and postabortion period.

**Complications of PID (Figure 17-9):** Tubo-ovarian adhesions, infertility, ectopic pregnancy, peritonitis, intestinal obstruction, bacteremia, and tubo-ovarian abscess.



**Figure 17-8.** Cervical intraepithelial neoplasia (CIN). **A**, The dysplastic cells (with lack of maturation) only involve the lower third of the mucosa. This appearance is consistent with CIN I, a low-grade lesion. **B**, The dysplastic cells (with lack of maturation) involve almost the entire thickness of the mucosa. This appearance is consistent with CIN III, a high-grade lesion that is likely to progress to invasive squamous cell carcinoma. **C**, The characteristic cell associated with CIN is a koilocyte. Note the wrinkled, or “raisinoid,” appearance of the nucleus, and the perinuclear clearing (arrowhead). In (C), the purple line is an artifact created by folding of the tissue during production of the microscopic section. Hematoxylin and eosin, **A**, 200 $\times$ ; **B**, 100 $\times$ ; **C**, 400 $\times$ .



### Clinical presentation of PID

- **Triad:** Fever, elevated white blood cell count, and purulent cervical discharge.
- **Signs and symptoms:** Abdominal tenderness, cervical motion tenderness (“chandelier sign”), dyspareunia, adnexal tenderness, and pain after menses. Right upper quadrant pain may be seen in gonococcal or chlamydial perihepatitis (i.e., **Fitz-Hugh-Curtis syndrome**). The presence of an adnexal mass should raise suspicion for a tubo-ovarian abscess. Ruptured tubo-ovarian abscess is a life-threatening surgical emergency.

## AMENORRHEA

### Basic description

- **Primary amenorrhea:** No menarche by the age of 16 years.
- **Secondary amenorrhea:** Lack of menstrual period for three cycles or > 6 months after menarche has already occurred.

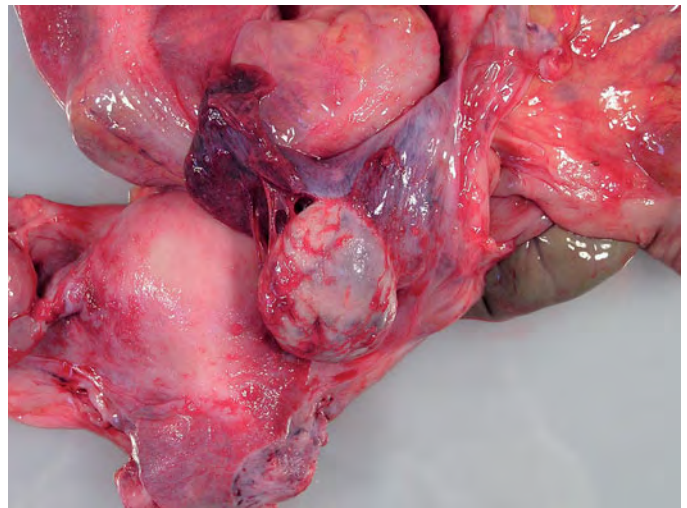
**Physiologic causes of amenorrhea:** Prepuberty, pregnancy, lactation, and menopause.

### Pathologic causes of amenorrhea

- **Anatomical defects:** Include congenital malformations (e.g., bifid uterus) and acquired defects (e.g., **Asherman syndrome**).
- **Premature ovarian failure and chronic anovulation:** Causes include excessive exercise, anorexia, obesity (produces increased levels of estrogen, which are converted to androgens), pituitary tumor, and hyperthyroidism or hypothyroidism.
- **Important point:** Turner syndrome is the most common cause of primary amenorrhea.

**Evaluation of primary amenorrhea:** The first step in evaluation of primary amenorrhea is a urine hCG test to rule out pregnancy, followed by a thorough physical examination. Physical examination of patients who have Turner syndrome will reveal small underdeveloped breasts with widely spaced nipples and a classic Turner phenotype (see Chapter 6). Physical examination of patients who have either androgen insensitivity (46,XY) or müllerian agenesis (46,XX) will reveal normal breast development and an absent uterus. Axillary and pubic hair development is androgen dependent; patients with androgen insensitivity lack pubic and axillary hair.

**Evaluation of secondary amenorrhea:** The most common cause of secondary amenorrhea is pregnancy. Polycystic ovarian disease (PCOD) is also very common. Galactorrhea may indicate pregnancy, hyperprolactinemia, or hypothyroidism, and can be seen as a side effect of antipsychotic medications. Luteinizing hormone (LH) and follicle-stimulating hormone (FSH) levels may be either high, as occurs in primary ovarian disease or menopause, or low, as occurs in pituitary dysfunction (hypogonadotropic hypogonadism.) An LH/FSH ratio > 2:1 suggests polycystic ovarian disease.



**Figure 17-9.** Pelvic inflammatory disease (PID). Note the adhesions between the right ovary and the fallopian tube and the small intestine. PID is a complication of infections caused by *Neisseria gonorrhoeae* and *Chlamydia trachomatis*, and is a risk factor for ectopic pregnancy, infertility, and bowel obstruction.

**Progesterone challenge test:** This test involves administering progestins for a short period (7–10 days). Withdrawal bleeding indicates the presence of an estrogen-primed endometrium and, thus, anovulatory but otherwise normal ovaries. An absence of withdrawal bleeding is followed up with a combined estrogen and progesterone challenge. Lack of withdrawal bleeding with combined challenge indicates an anatomic obstruction to menstruation. Withdrawal bleeding with estrogen supplementation indicates low estrogen levels due to either nonfunctional ovaries or dysfunction of the hypothalamic pituitary axis.

## NON-NEOPLASTIC DISEASES OF THE UTERUS

**Overview:** Although there are many non-neoplastic conditions that can affect the uterus, six of the more common and clinically important conditions are acute endometritis, chronic endometritis, adenomyosis, endometriosis, abnormal uterine bleeding, and endometrial hyperplasia, and all will be discussed in this section. Endometrial hyperplasia is a precursor for endometrial adenocarcinoma, which will be discussed in the subsequent section called tumors of the uterus.

### ACUTE ENDOMETRITIS

**Basic description:** Acute infection of the endometrium caused by polymicrobial infection with vaginal flora.

**Clinical presentation of acute endometritis**

- **Symptoms:** Postpartum fever, foul-smelling vaginal discharge, uterine tenderness.
- **Important point:** Acute endometritis is the most common cause of postpartum fever in patients following caesarean section.
- **Risk factors:** Cesarean delivery, retained products of conception, and PID (in the nonobstetric population).

### CHRONIC ENDOMETRITIS

**Causes:** PID, tuberculosis, retained placental tissue, intrauterine (contraceptive) devices.

**Microscopic morphology:** Plasma cells in endometrium.

### ADENOMYOSIS

**Basic description:** Presence of normal endometrial tissue within the myometrium of the uterus; it may represent down-growth of endometrium into the myometrium (Figure 17-10).

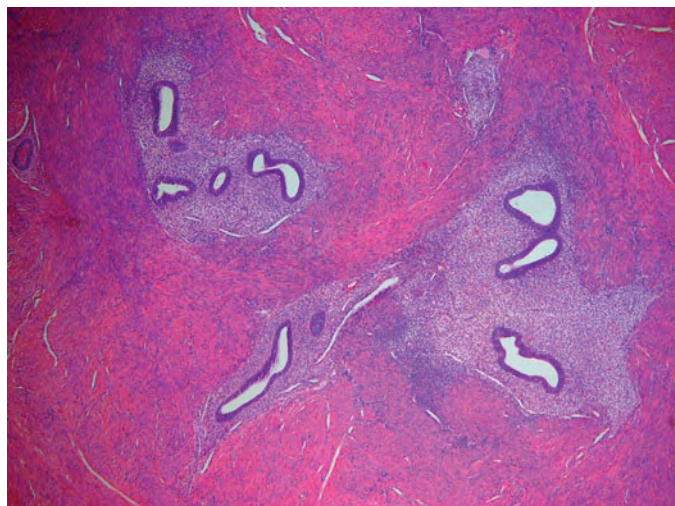
**Clinical presentation of adenomyosis**

- **Symptoms:** Many cases are asymptomatic, but patients may have pelvic pain, dyspareunia, abnormal bleeding, and infertility.
- **Signs:** Enlarged uterus.

### ENDOMETRIOSIS

**Basic description:** Endometrial tissue in an abnormal location outside of the uterus.

**Locations:** Ovaries, pouch of Douglas, uterine ligaments, fallopian tubes; rarely intestine or lungs.



**Figure 17-10.** Adenomyosis. In adenomyosis, endometrial tissue is displaced deep into the myometrium. The presence of both glands and stroma indicates that this is not invasive endometrial adenocarcinoma (which would consist of glands only). Adenomyosis can cause pelvic pain and infertility. Hematoxylin and eosin, 40 $\times$ .

### Three theories of the mechanism for endometriosis

- Regurgitation of endometrial tissue into the peritoneum from the uterine cavity.
- Metaplastic differentiation of coelomic epithelium.
- Vascular or lymphatic dissemination.

**Complications of endometriosis:** Infertility, dysmenorrhea, pelvic pain.

### Morphology of endometriosis

- **Gross:** Cyst filled with thick, brown-red fluid (i.e., **chocolate cyst**).
- **Microscopic:** Two of three of the following features must be present for a diagnosis of endometriosis: endometrial glands, endometrial stroma, or hemosiderin (Figure 17-11).

### Clinical presentation of endometriosis

- **Symptoms:** Pelvic and abdominal pain, dyspareunia, and infertility. Pelvic pain is often chronic, and cyclical variation in the severity of pain and symptoms coinciding with menses (dysmenorrhea) is classic. Pain with defecation, and bowel symptoms are not uncommon. Recurrent perimenstrual hemoptysis from bronchial endometriosis is a rare but “text-book” presentation.
- **Signs:** Examination findings may include enlarged, tender retroflexed uterus, nodularity of the cul-de-sac, and adnexal masses. Visualization of “chocolate cysts” on laparoscopy is diagnostic.

## ABNORMAL UTERINE BLEEDING

**Basic description:** Profuse or prolonged bleeding during menstruation (i.e., menorrhagia) or bleeding between menstrual cycles (i.e., metrorrhagia). The most common cause is anovulation. Abnormal uterine bleeding as a result of anovulation is referred to as dysfunctional uterine bleeding (DUB).

### Mechanisms of abnormal uterine bleeding

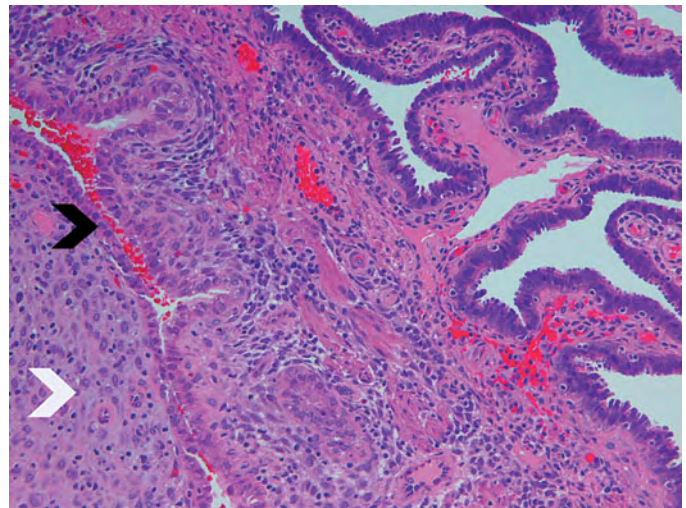
- **Inadequate luteal phase.**
- **Contraceptive-induced bleeding.**
- **Failure of ovulation** (failure of ovulation is the result of excess estrogen relative to progesterone, which can be produced in the situations discussed below).

#### Causes

- Beginning or ending of reproductive life.
- Dysfunction of hypothalamic-pituitary axis.
- Excess estrogen as a result of adrenal disease, pituitary tumors, granulosa cell tumor, polycystic ovarian disease, obesity, or malnutrition

## ENDOMETRIAL HYPERPLASIA

**Cause:** Endometrial hyperplasia (or endometrial intraepithelial neoplasia) results from increased estrogen levels from failure of ovulation, exogenous estrogen, or estrogen-secreting conditions such as polycystic ovaries or granulosa cell tumor.



**Figure 17-11.** Endometriosis involving the fallopian tube. The fimbriae of the fallopian tube are in the right upper corner of the image. The black arrowhead indicates the glands, and the white arrowhead indicates the stroma. The third component of endometriosis (hemosiderin) is not readily apparent in this section. Hematoxylin and eosin, 200×.



**Risk factors:** Any condition that increases lifetime estrogen exposure increases the risk of endometrial hyperplasia. In general, risk factors are the same as for endometrial cancer (see below).

**Complications of endometrial hyperplasia:** Hyperplasia leads to dysplasia, which leads to carcinoma. Endometrial hyperplasia is a premalignant condition.

**Mutation:** Inactivation of *PTEN* (phosphatase and tensin homologue). Without *PTEN*, endometrial cells are more sensitive to estrogen stimulation.

**Gross morphology of endometrial hyperplasia:** Thickening of the endometrium.

**Microscopic morphology of endometrial hyperplasia** (Figure 17-12 A and B)

- **Simple hyperplasia:** Cystic hyperplasia; very uncommonly progresses to carcinoma.
- **Complex hyperplasia:** Crowded, back-to-back glands (> 50% of tissue is glands).
- **Complex hyperplasia with atypia:** Crowded back-to-back glands with nuclear pleomorphism and mitotic figures. It can be difficult to separate complex hyperplasia with atypia from invasive carcinoma.

#### Clinical presentation of endometrial hyperplasia

- **Symptoms:** Vaginal bleeding, especially in a postmenopausal woman.
- **Signs:** Widened endometrial stripe on transvaginal ultrasound and endometrial or atypical glandular cells on PAP smear. Endometrial biopsy is diagnostic.

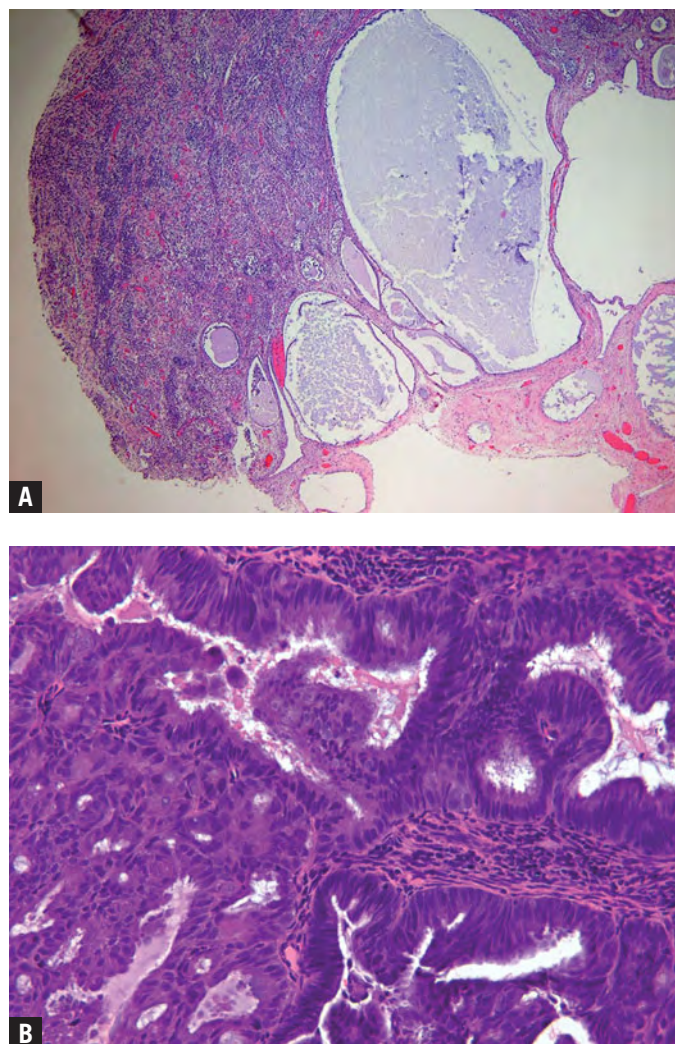
## TUMORS OF THE UTERUS

**Overview:** Although there are many different tumors of the uterus, the most common endometrial carcinoma is endometrial adenocarcinoma. Leiomyomas are the most common tumor overall of the uterus. Their malignant counterpart, the leiomyosarcoma, is not common, however. In addition to these three neoplasms, endometrial stromal sarcomas and combination tumors will be discussed briefly in this section.

### ENDOMETRIAL ADENOCARCINOMA (FIGURE 17-13 A and B)

**Epidemiology:** Many occur about age 55 years or older.

**Risk factors:** The most important general risk factor is increased estrogen levels, which can be caused by early menarche and late menopause, nulliparity, and polycystic ovarian disease (PCOD); exogenous estrogen via estrogen-only contraception and hormone replacement therapy (HRT); and obesity. Obesity causes increased estrogen levels through peripheral conversion of androstenedione to estrone via aromatase in adipose tissue. Other risk factors for endometrial adenocarcinoma include diabetes mellitus and hypertension.



**Figure 17-12.** Endometrial hyperplasia. **A**, Simple hyperplasia, cystic glands in the endometrium. **B**, Complex hyperplasia with atypia (back-to-back glands, with dysplastic features such as pleomorphism, hypercellularity, and nuclear hyperchromasia). Hematoxylin and eosin, **A**, 40 $\times$ ; **B**, 400 $\times$ .

**Precursor lesion for endometrial adenocarcinoma:** Endometrial hyperplasia.

**Mutations:** Approximately 35% of cases of endometrial adenocarcinoma have a mutation of *PTEN*. *PTEN* is located at 10q23, and is a tumor suppressor gene whose function is to cause arrest of the cell cycle at G<sub>1</sub>, enabling apoptosis. Endometrial adenocarcinoma can also have a mutation of  $\beta$ -catenin.

#### Important points regarding endometrial adenocarcinoma

- Higher-grade variants of endometrial adenocarcinoma such as clear cell adenocarcinoma and papillary serous adenocarcinoma are less commonly related to increased estrogen and hyperplasia. They have a poorer prognosis, and are associated with microsatellite instability or mutation of *p53*.
- Endometrial adenocarcinoma metastasizes to lungs, liver, and bone.

#### Clinical presentation of endometrial adenocarcinoma

- **Symptoms:** Vaginal bleeding.
- **Important points**
  - Vaginal bleeding in a postmenopausal woman is endometrial hyperplasia or cancer until proven otherwise, and *always* necessitates biopsy. Because of this sentinel symptom, endometrial cancer is usually diagnosed at an early stage.
  - Granulosa cell tumors secrete estrogen, and thus are an uncommon cause of endometrial hyperplasia and endometrial adenocarcinoma.

### LEIOMYOMA (UTERINE FIBROIDS)

**Basic description:** Benign tumor of smooth muscle.

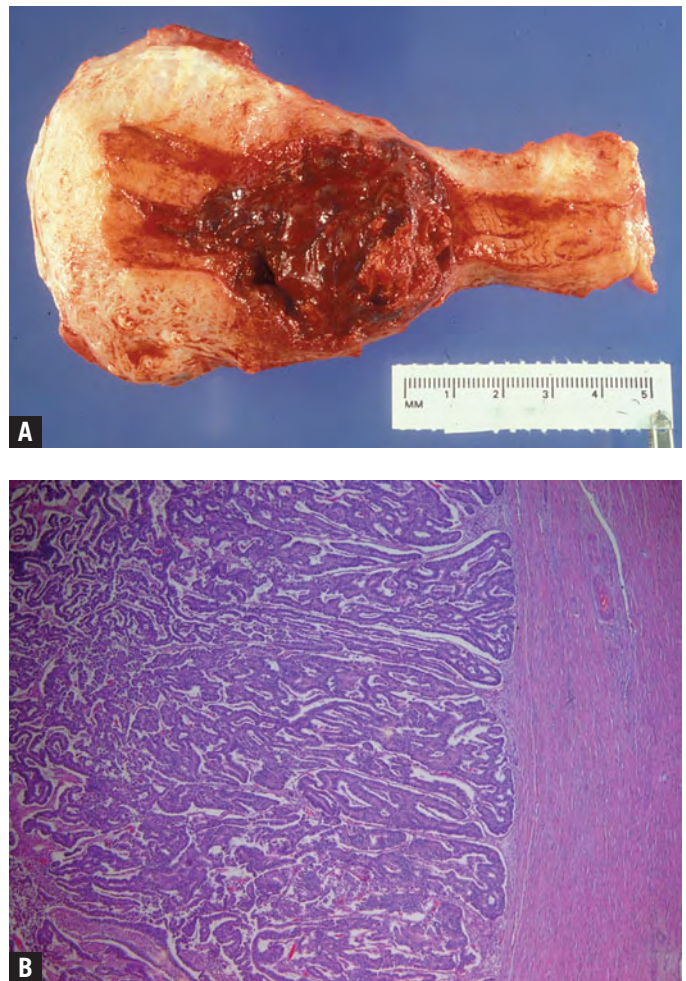
**Epidemiology:** Very common during reproductive years; found in up to 75% of women of reproductive age. More common in African Americans.

**Locations:** Leiomyomas can occur in subserosal, intramural, or subendometrial locations. Leiomyomas are usually multiple in number.

**Mutations:** t(12;14) and del 7.

#### Complications of leiomyomas

- Menorrhagia with severe anemia.
- Infertility, abortion, and premature labor.
- Compression of the bladder or ureter, causing hydronephrosis or hydroureter.
- Development of leiomyosarcoma is extremely rare.



**Figure 17-13.** Endometrial adenocarcinoma. **A**, Bulging forth from the endometrial surface is a large, red-tan polypoid mass. Endometrial adenocarcinoma can be detected early in its course because of vaginal bleeding. **B**, This low-power view illustrates an invasive endometrial adenocarcinoma. Note the complexity of the glands (compare to Figure 17-12 **B**). One of the only histologic differences between complex hyperplasia with atypia and endometrial adenocarcinoma is the presence of invasion. Hematoxylin and eosin, 40 $\times$ .



### Morphology of leiomyomas

- **Gross:** Firm, tan, well-circumscribed mass (Figure 17-14).
- **Microscopic:** Interlocking fascicles of smooth muscle cells.

**Clinical presentation of leiomyoma:** Abnormal uterine bleeding (menorrhagia), anemia, enlarged irregular uterus, recurrent abortions, infertility.

### Important points

- Leiomyomas are estrogen sensitive and increase in size with pregnancy and decrease in size with menopause.
- The most important risk factor for malignant degeneration to leiomyosarcoma is prior pelvic irradiation.

## LEIOMYOSARCOMA

**Basic description:** Malignant tumor of smooth muscle.

**Epidemiology:** Females between ages 40 and 60 years.

**Clinical presentation:** Rapidly enlarging pelvic mass. May present in a woman with a history of leiomyomas. Metastases to lungs, bone, and brain.

## OTHER NEOPLASMS

**Endometrial stromal sarcoma:** Malignant tumor of endometrial stroma; represent < 5% of endometrial tumors.

### Combination tumors

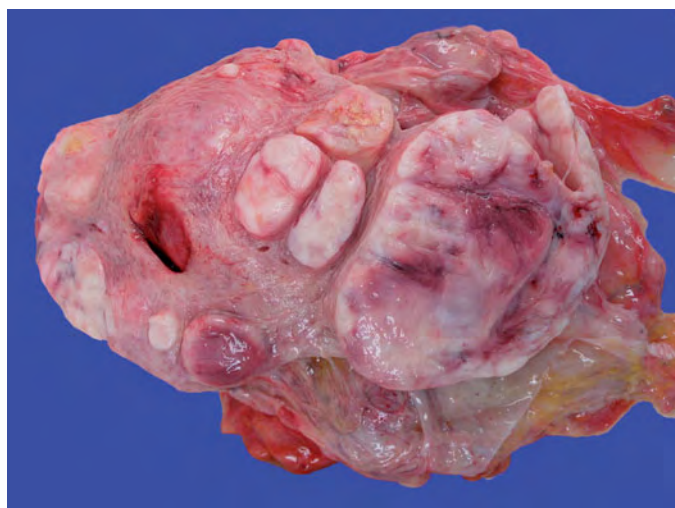- **Endometrial carcinoma with stromal differentiation** (called **carcinosarcoma** or **malignant mixed müllerian tumor**).
- **Adenosarcoma:** Stromal tumor associated with benign glands.

## NON-NEOPLASTIC OVARIAN DISEASE

**Overview:** One of the most important conditions involving the ovaries is tumors, which will be discussed in the next section. Many ovaries have non-neoplastic conditions, most commonly cysts of various types, which are usually incidental findings during surgery and of little or no clinical importance. However, polycystic ovarian disease (formerly known as **Stein-Leventhal syndrome**) is a condition associated with multicystic ovaries and is discussed below.

### Polycystic ovarian disease (PCOD)

- **Mechanism:** Multiple cysts in the ovary result in excessive production of estrogen and androgens, which are converted to estrone. Estrone then inhibits FSH.
- **Complications:** Increased risk for endometrial hyperplasia and cancer, diabetes mellitus, and metabolic syndrome. Infertility responds well to metformin, although the mechanism is poorly understood.
- **Clinical presentation of PCOD:** Include obesity, hirsutism and acne, and infertility. Patients have insulin resistance and may have signs of diabetes mellitus, including **acanthosis nigricans**. The LH/FSH ratio is > 2:1.



**Figure 17-14.** Leiomyomas. This uterus has been bisected (the lumen is present on the left side), revealing multiple well-circumscribed, tan-white masses (leiomyomas) that bulge from the cut surface. Often, more than one leiomyoma is present. These tumors can cause pelvic pain, infertility (preventing expansion of the uterus during pregnancy), and vaginal bleeding (if they project into the endometrial cavity).



## OVARIAN TUMORS

**Overview:** There are four general categories of ovarian tumors: surface epithelial (70% of tumors); germ cell (20% of tumors); sex cord–stromal (5% of tumors); and metastases from neoplasms of the uterus, fallopian tubes, breast, gastrointestinal system (e.g., colon, stomach), and contralateral ovary, which represent 5% of ovarian tumors. Because surface epithelial tumors represent the most common form of ovarian tumor, the majority of the discussion here will cover them. The forms of germ cell tumors have been discussed previously under testicular tumors; therefore, only the important differences between ovarian and testicular germ cell tumors will be discussed below.

### SURFACE EPITHELIAL TUMORS

**Overview:** There are five categories of surface epithelial tumors: serous, mucinous, Brenner, endometrioid, and clear cell (clear cell tumors will not be discussed below). Each category can be divided into benign, borderline (i.e., low malignant potential), or malignant types (e.g., there are benign, borderline, and malignant forms of serous surface epithelial tumors) (Table 17-2). Approximately 80% of surface epithelial tumors are benign. Borderline (i.e., low malignant potential) tumors exhibit features of anaplasia with no or little invasion of stroma. In many cases, peritoneal “metastases” do not invade.

#### Epidemiology

- Benign ovarian tumors: Females between the ages of 20 and 45 years.
- Malignant ovarian tumors: Females between the ages of 40 and 65 years.

**Tumor markers:** CA-125 is elevated in patients with ovarian epithelial tumors. About 90% of ovarian cancers are derived from surface epithelium, making CA-125 the most important tumor marker for ovarian cancer.

### SEROUS TUMORS

**Incidence:** Most common type (30% of all ovarian tumors); 60% are benign, 15% are borderline, and 25% are malignant.

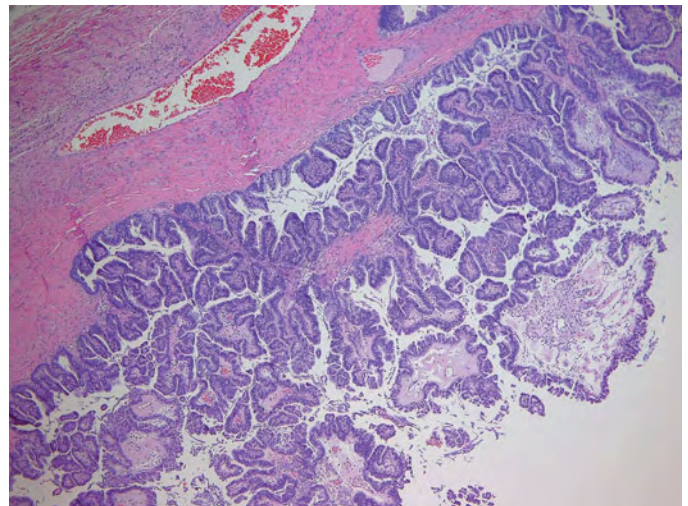
**Important points (serous vs mucinous tumors):** Serous tumors are more likely to be unilocular, malignant, and bilateral.

**Microscopic morphology of serous tumors (Figures 17-15 and 17-16 A and B)**

- Lined by fallopian tube-like epithelium; can have **Psam-moma bodies**.
- Increased solid areas, papillary projections, and friable tissue within the tumor increase the chance that a malignant component is present.

**TABLE 17-2.** General Types of Surface Epithelial Tumors

Tumor Type	Variants
Serous	Benign Borderline Malignant
Mucinous	Benign Borderline Malignant
Brenner tumor	Benign Borderline Malignant
Endometrioid carcinoma	Benign Borderline Malignant
Clear cell carcinoma	Benign Borderline Malignant



**Figure 17-15.** Borderline serous surface epithelial tumor. The neoplastic cells are forming papillae; however, there is no evidence of tissue invasion. Hematoxylin and eosin, 100×.

### MUCINOUS TUMORS

**Incidence:** Represent 25% of all ovarian tumors; 80% are benign and 10% are malignant.

**Important points (mucinous vs serous tumors)**

- Mucinous tumors are more likely to be multilocular, benign, and unilateral.
- **Pseudomyxoma peritonei:** An associated condition where patients have mucinous ascites, adhesions, and cystic peritoneal implants. Pseudomyxoma peritonei can cause intestinal obstruction and death.

**Microscopic morphology of mucinous tumors:** Lined by glandular-like epithelium (Figure 17-17).

### BRENNER TUMOR

**Important point:** Brenner tumors are almost always benign.

**Microscopic morphology:** Fibrous stroma plus clusters of transitional cell-like epithelium (Figure 17-18).

### ENDOMETRIOID TUMOR

**Incidence:** Represent 20% of all ovarian carcinomas.

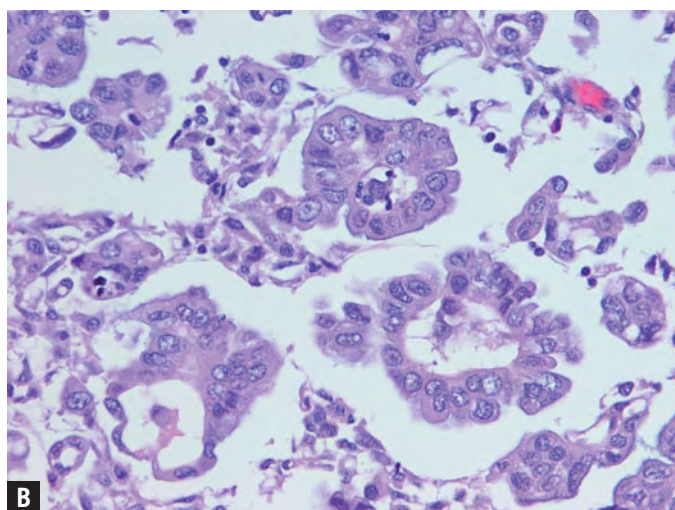
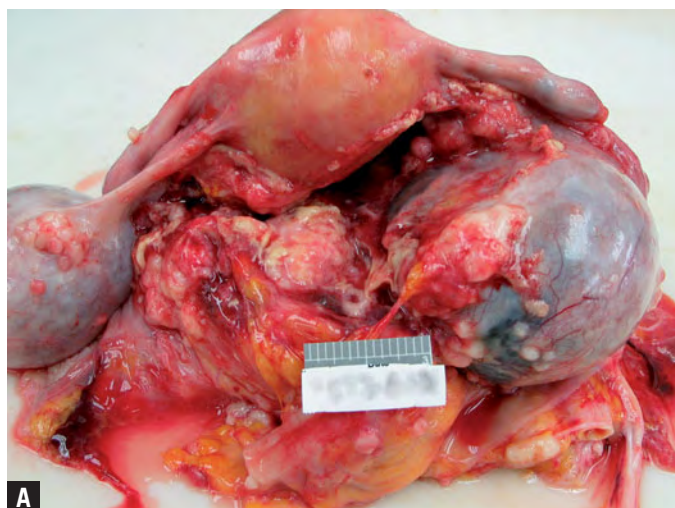
**Microscopic morphology:** Appearance is similar to endometrial adenocarcinoma.

**Other forms of ovarian tumors:** Although surface epithelial tumors represent the most common types of ovarian neoplasms, germ cell tumors and sex cord–stromal tumors can also develop in the ovary. Germ cell tumors (e.g. embryonal carcinoma, choriocarcinoma, and yolk sac tumors) have been previously discussed with testicular neoplasms. Testicular and ovarian germ cell tumors share many characteristics; however, key differences (i.e., mature cystic teratomas and dysgerminomas) will be discussed below. Also included in this section is a brief discussion of sex cord–stromal tumors and ovarian metastases.

### MATURE CYSTIC TERATOMA

**Important points**

- In adult females, mature teratomas occur as the sole component of a tumor, as opposed to in the testes, where mature teratomas occur in association with other germ cell tumors.
- It is possible for one of the mature components to undergo malignant degeneration (e.g., a squamous cell carcinoma developing from the squamous cells).
- **Monodermal teratomas:** Tumors derived from one of the three layers; one form is called **struma ovarii** and is a monodermal teratoma composed entirely of thyroid epithelium. This functional thyroid tissue can lead to hyperthyroidism via ectopic secretion of thyroid hormone.
- Extragonadal presentation (e.g., sacrococcygeal teratoma and anterior mediastinal mass is not unusual).



**Figure 17-16.** Malignant serous surface epithelial tumor. **A**, This patient had bilateral benign ovarian cysts and a papillary serous cystadenocarcinoma. The white-tan nodules posterior to the uterus and studding the surface of the right ovarian cyst represent the tumor. **B**, Microscopically, the neoplastic cells are pleomorphic and hyperchromatic and form small papillae. Papillary serous cystadenocarcinoma is a high-grade malignant neoplasm. Hematoxylin and eosin, 400 $\times$ .



### Morphology of mature cystic teratoma

- **Gross:** Cyst containing hair, sebaceous material, and teeth (Figure 17-19).
- **Microscopic:** Usually contain a large component of epidermis and dermal appendages; however, the tumor can also contain tissue from the gastrointestinal system, liver, peripheral nervous system, and brain, among other organs.

### DYSGERMINOMA

**Epidemiology:** About 75% occur during the second and third decades of life.

**Important points:** A dysgerminoma is the female counterpart of the male seminoma. All dysgerminomas are malignant.

### FIBROTHERCOMA

**Incidence:** A form of sex cord–stromal tumor. Fibrothecomas represent 4% of ovarian tumors.

**Important points:** Fibrothecomas are benign. Most are inactive, but some produce estrogen and some are associated with **Meigs syndrome** (i.e., ascites and hydrothorax).

### GRANULOSA CELL TUMOR

#### Important points

- Most are benign; however, between 5 and 25% are malignant. Malignancy cannot absolutely be predicted by the histology, and requires the presence of invasion and/or metastases to confirm the diagnosis.
- The tumors can produce estrogen, thus leading to endometrial hyperplasia and cancer.

**Microscopic morphology of granulosa cell tumor:** Have **Call-Exner bodies** (appear similar to ovarian follicle), and produce inhibin, which can be identified in serum and by immunohistochemistry.

### KRUKENBERG TUMOR

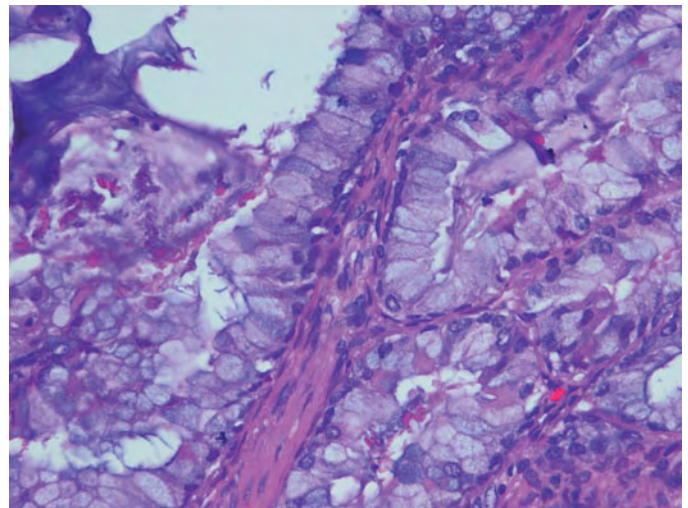
**Basic description:** Bilateral metastatic ovarian tumor composed of signet ring cells, usually gastrointestinal in origin (e.g., gastric carcinoma).

## PLACENTAL AND PREGNANCY-RELATED PATHOLOGY

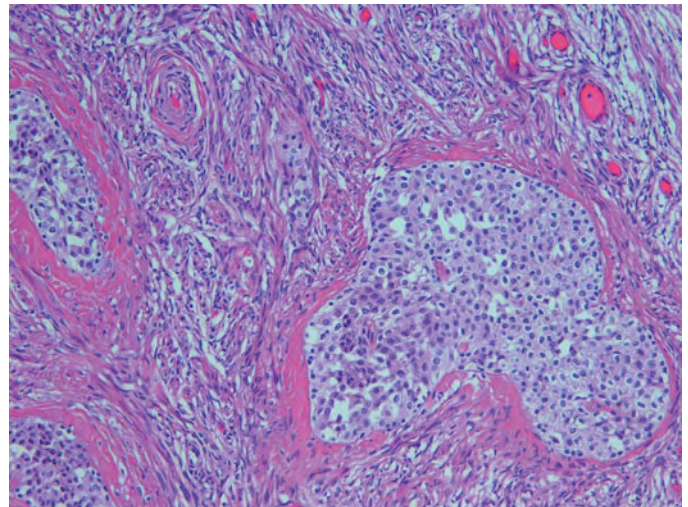
**Overview:** The major conditions associated with pregnancy, including abortion, infections (chorioamnionitis), gestational trophoblastic disease, placental abruption, abnormal placental implantation (ectopic pregnancy, placenta previa and placenta accreta), and toxemia of pregnancy, are discussed in this section.

### ABORTION

**Basic description:** Pregnancy that fails before 20 weeks' gestation. The death of a fetus after this time (i.e., 20 weeks' gestational age) is referred to as a **stillbirth**.



**Figure 17-17.** Mucinous surface epithelial tumor. The neoplastic cells produce mucin, as can be seen in the image. Similar to serous tumors, mucinous surface epithelial tumors occur in benign, borderline, and malignant forms. Hematoxylin and eosin, 400X.



**Figure 17-18.** Brenner tumor. This neoplasm has a characteristic histologic appearance of nests of transitional epithelium-like cells admixed with a fibrous stroma. Most Brenner tumors are benign. Hematoxylin and eosin, 200X.



### Types of abortion

- **Threatened abortion:** Patients have uterine bleeding, and the cervical os is closed. About 50% of threatened abortions will eventually result in miscarriage.
- **Inevitable abortion:** Patients have uterine bleeding, and the cervical os is open.
- **Incomplete abortion:** Fetus is not passed.
- **Complete abortion:** All tissue is passed. Cervical os is closed.

**Complications of abortion:** Hemorrhage with resultant hypovolemic shock, sepsis, and psychological distress.

**Important point:** Chromosomal abnormalities are the most common identifiable cause of spontaneous abortion.

### Clinical presentation of abortion

- **Symptoms:** Vaginal bleeding, cramping abdominal pain.
- **Signs:** Open or closed cervical os, depending upon the form of abortion. Passage of clots or tissue.
- **Laboratory evaluation:** Failure of serial serum hCG to double in 48 hours and serum progesterone  $< 5$  ng/mL are indicative of a nonviable pregnancy.

## CHORIOAMNIONITIS

**Basic description:** Infection of the fetal membranes.

### Mechanism

- Ascending infection from the uterus, often associated with premature rupture of membranes. Most common causative organisms include group B *Streptococcus* and *Escherichia coli*.
- Hematogenous (less common).

**Risk factors for chorioamnionitis:** Premature and prolonged rupture of membranes, multiple vaginal examinations during labor, and colonization of vagina and perineum with group B *Streptococcus*.

**Complications:** Premature labor, endometritis, fetal and newborn sepsis, and stillbirth.

**Clinical presentation of chorioamnionitis:** Fever, maternal and fetal tachycardia, leukocytosis, uterine tenderness, and foul-smelling vaginal discharge.

## GESTATIONAL TROPHOBLASTIC DISEASE (HYDATIDIFORM MOLE)

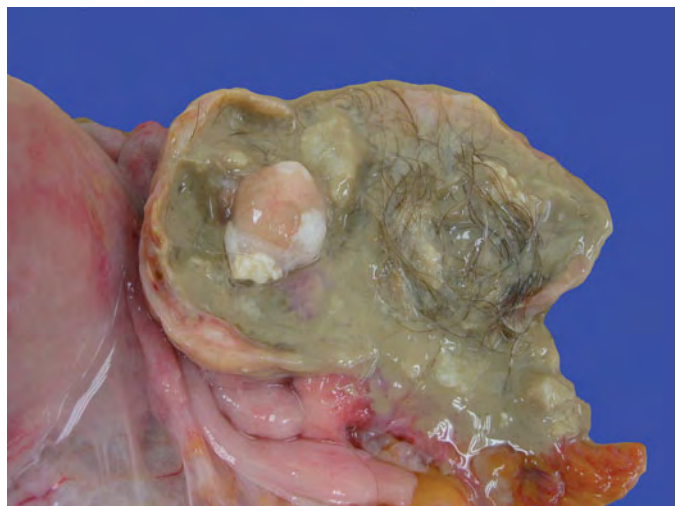**Incidence:** Occurs in 1 in 1500 pregnancies.

**Three main types of hydatidiform moles:** Complete, partial, and invasive (Table 17-3). Uterine choriocarcinoma is directly related to gestational trophoblastic disease, and will be discussed below as a fourth entry.

### 1. Complete hydatidiform mole

**Mechanism of development:** Approximately 90% of cases are due to an empty egg fertilized by one sperm (with subsequent duplication of DNA); 10% of cases are due to an empty egg fertilized by two sperm.

**Karyotype:** Most are 46,XX.



**Figure 17-19.** Mature cystic teratoma. A frequently occurring benign ovarian tumor; the gross appearance of a mature cystic teratoma is characteristic, with a cyst containing hair, sebaceous fluid (the thick green liquid), and occasionally teeth. The components of a mature cystic teratoma can, rarely, undergo malignant change (resulting in a squamous cell carcinoma or adenocarcinoma).

**TABLE 17-3.** Comparison and Contrast of Complete and Partial Moles

Feature	Complete Mole	Partial Mole
Mechanism of formation	Empty egg fertilized by one or two sperm	Normal egg fertilized by two sperm
Karyotype	46, XX	69, XXY
Risk for choriocarcinoma	2%	Rare
Presence of fetal parts	No	Yes
Morphology	All villi are hydropic and have trophoblastic proliferation	Some villi are hydropic and have trophoblastic proliferation

**Risk of choriocarcinoma:** 2%

**Important point:** Approximately 20% of women will have recurrence in subsequent pregnancies.

#### Morphology of complete hydatidiform mole

- **Gross:** Markedly hydropic villi, which resemble cluster of grapes. No fetal parts.
- **Microscopic:** All villi are edematous and have prominent trophoblast proliferation (Figure 17-20).

#### 2. Partial hydatidiform mole

**Mechanism of development:** Normal egg fertilized by two sperm.

**Karyotype:** Triploid (69,XXY).

**Risk of choriocarcinoma:** Patients rarely develop choriocarcinoma.

#### Morphology of partial hydatidiform mole

- **Gross:** Difficult to distinguish from spontaneous abortion; some hydropic villi; fetal parts are present.
- **Microscopic:** Some edematous villi; some trophoblast proliferation.

#### 3. Invasive mole

**Basic description:** Molar pregnancy that penetrates the uterine wall.

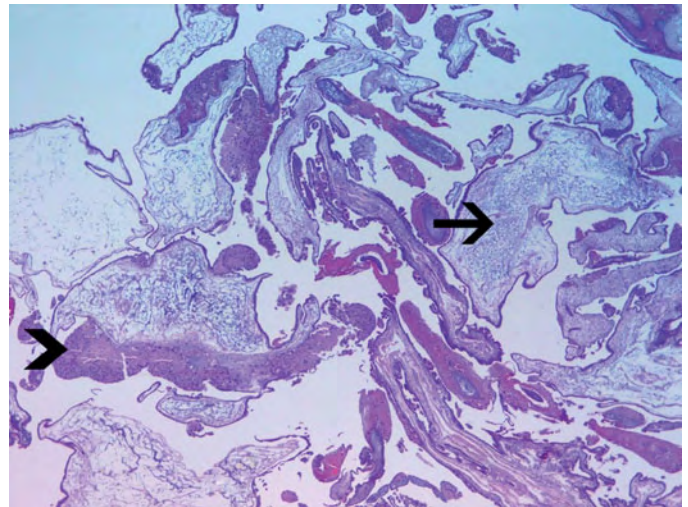
#### Important points

- Locally destructive.
- May embolize.
- Approximately 10% of complete moles become an invasive mole.

#### 4. Uterine choriocarcinoma

##### Precursor conditions to choriocarcinoma

- Approximately 50% arise in molar pregnancies; 25% from previous abortion and 25% from normal pregnancies.
- Complicate about 1 in 100,000 normal pregnancies.



**Figure 17-20.** Complete hydatidiform mole. The characteristic gross appearance of this condition is described as “grape-like clusters.” The grape-like clusters are produced by edematous villi (arrow). In a complete mole, all villi are edematous and have prominent trophoblastic proliferation (arrowhead). Hematoxylin and eosin, 40×.

**Important points**

- Metastases: Lungs (50%), vagina (30%), then brain, liver, and kidney.
- Produce  $\beta$ -hCG.
- Responds to methotrexate.

**Clinical presentation of gestational trophoblastic disease**

- **Signs and symptoms:** The clinical hallmarks of trophoblastic disease are uterine enlargement and elevated hCG in excess of what is expected for gestational age. Hyperemesis and bleeding are common, and new onset of hypertension in the first trimester should raise suspicion of molar pregnancy.
- **Radiologic finding:** The classic sonographic finding is the “snowstorm pattern.”
- **Important point:** The two main risk factors for molar pregnancy are extreme maternal age (either very young or old) and prior molar pregnancy.

**PLACENTAL ABRUPTION**

**Basic description:** Premature separation of the placenta from the uterus due to hemorrhage between the placenta and uterine wall.

**Incidence:** Occur in 1 in 150 pregnancies; usually during the third trimester.

**Complications of placental abruption:** Hemorrhage between the uterus and the placenta results in decreased oxygen and nutrients delivered to the fetus, with 20% chance of fetal mortality. The mother can develop hypovolemic shock. Maternal coagulopathy and disseminated intravascular coagulation (DIC) are common.

**Risk factors:** Increasing age, multiparity, hypertension, trauma, cocaine use.

**Clinical presentation of placental abruption**

- **Symptoms:** Painful vaginal bleeding, uterine tenderness, back pain.
- **Diagnosis:** Because blood has a similar echotexture to placenta, ultrasound cannot be used to rule out placental abruption; thus diagnosis is clinical and confirmed at delivery.

**ECTOPIC PREGNANCY**

**Basic description:** Pregnancy occurring when the fetus implants in a location other than the uterine cavity.

**Location:** Fallopian tubes (90% of cases), ovaries, and abdominal cavity.

**Risk factors for ectopic pregnancy**

- Scarring of the fallopian tube due to PID.
- Tumors, endometriosis.
- Intrauterine devices (IUD).
- Adhesions (e.g., from previous surgery).

**Complications of ectopic pregnancy:** Hemorrhage from rupture of pregnancy.



### Clinical presentation of ectopic pregnancy

- Triad (seen in 15% of patients): Unilateral abdominal or adnexal pain, abnormal vaginal bleeding, and adnexal mass.
- With rupture, patients have severe abdominal pain, peritoneal signs, tachycardia, and shock.

### PLACENTA PREVIA

**Basic description:** Abnormal insertion of placenta, in which placenta partially or completely covers the cervical os (Figure 17-21).

**Incidence:** 1 in 200 pregnancies.

**Complications of placenta previa:** Hemorrhage.

**Risk factors:** Previous caesarean section; multiple gestation pregnancies.

### Clinical presentation of placenta previa

- **Symptoms:** Painless vaginal bleeding; postcoital spotting at > 30 weeks' gestation.
- **Diagnosis:** Ultrasound is diagnostic and should be performed prior to vaginal examination in any third trimester bleed to avoid tearing the placenta and causing hemorrhage.

### PLACENTA ACCRETA

**Basic description:** Placental villi in direct contact with myometrium, due to partial or complete loss of decidua (Figure 17-21).

**Risk factors:** Low lying placenta or placenta previa; prior cesarean section.

**Complications of placenta accreta:** Postpartum bleeding as a result of failure of placental separation; perforation of uterus.

### TOXEMIA OF PREGNANCY

**Basic description:** Hypertension, proteinuria, and edema occurring during pregnancy. This constellation of symptoms is referred to as **preeclampsia**. If the patient develops seizures, the condition is referred to as **eclampsia**.

**Incidence:** About 7% of pregnancies.

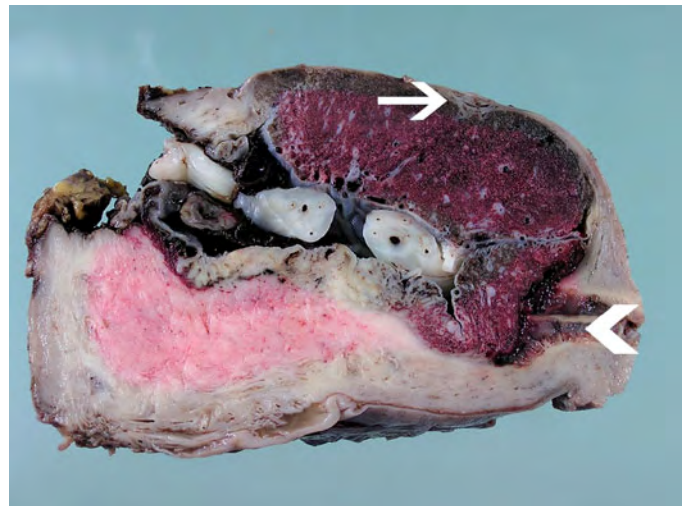
**Epidemiology:** Occurs from 20 weeks' gestation to 6 weeks' postpartum; primigravidas are more commonly affected than multigravidas.

**Pathogenesis of toxemia of pregnancy:** Possibly the result of abnormal placentation leading to ischemia. A shallow implantation results in incomplete conversion of decidual vessels to vessels adequate for pregnancy. The incomplete conversion of decidual vessels may be due to a defect in trophoblasts.

**Risk factors for toxemia of pregnancy:** Hypertension, diabetes mellitus, and chronic renal disease.

### Morphology of toxemia of pregnancy

- Placental infarcts.
- Retroplacental hemorrhage.
- **Specific microscopic finding: Atherosclerosis**, which is fibrinoid necrosis and lipid deposition in walls of vessels.



**Figure 17-21.** Placenta accreta and placenta previa. This cross section of a uterus, with the placenta still within the uterine cavity, reveals placental previa (at the *arrowhead*, note the placenta completely covers the cervical os) and placenta accreta (at the *arrow*, note the placenta has invaded the wall of the uterus, extending almost to the serosal surface; compare to the opposite uterine wall).

**TABLE 17-4.** Risk for Future Development of Breast Carcinoma Associated with Certain Conditions

Condition	No or Minimal Risk	Slight Risk	Moderate Risk	Great Risk
Fibrocystic disease with no proliferative activity	X			
Ductal hyperplasia, fibroadenoma, sclerosing adenosis		X		
Atypical ductal hyperplasia			X	
Carcinoma in situ				X

**Clinical presentation of toxemia of pregnancy**

■ **Symptoms:** Headache, visual disturbances, weight gain, and nausea and vomiting.

■ **Signs:** Hypertension, oliguria; right upper quadrant tenderness resulting from subcapsular liver hemorrhage.

**Associated condition: HELLP syndrome** (features are *hemolysis*, *elevated liver function tests*, *low platelets*).

**NON-NEOPLASTIC DISEASES OF THE BREAST**

**Overview:** The three most clinically important categories of breast disease are non-neoplastic diseases, carcinoma in situ, and breast neoplasms (Table 17-4). Because of their importance, both carcinoma in situ of the breast and breast neoplasms will be discussed separately, following this section covering non-neoplastic lesions of the breast. After a brief discussion of acute mastitis, fibrocystic change, sclerosing adenosis, fibroadenoma, phyllodes tumor, and intraductal papilloma and their risk for future development of carcinoma will be discussed.

**ACUTE MASTITIS**

**Basic description:** Bacterial infection of the breast occurring during lactation.

**Causative organism:** Most commonly *Staphylococcus aureus*.

**Mechanism:** Bacteria enter the breast through cracks in the nipple.

**Clinical presentation of acute mastitis:** Erythematous and painful breast.

**FIBROCYSTIC CHANGE**

**Epidemiology:** Females older than 35 years of age.

**Two forms of fibrocystic change: nonproliferative and proliferative**

■ **Nonproliferative form:** No epithelial hyperplasia in ducts; no increased risk for development of breast cancer.

- **Proliferative form:** Some ducts have epithelial hyperplasia. If the amount of hyperplasia is moderate to severe, patients have increased risk for future development of breast cancer. Risk is 1.5–2.0 times higher than the normal population. However, if proliferation is atypical (i.e., atypical ductal or atypical lobular), the risk is 4.0–5.0 times higher than that of the normal population.

#### Morphology of fibrocystic change

- **Gross:** Lumpy, bumpy, breast parenchyma.
- **Microscopic**
  - Cysts and fibrosis (Figure 17-22).
  - **Proliferative version:** Epithelial hyperplasia within ducts. Ducts with epithelial hyperplasia have irregular, slit-like lumens and overlapping cells.

**Clinical presentation of fibrocystic change:** Pain that may be exacerbated by menstruation and chocolate or caffeine consumption; lumpy, irregular breast texture, and tenderness to palpation. May occasionally be associated with nipple discharge. Classic “blue domed cysts” are seen at surgery.

### SCLEROSING ADENOSIS

**Importance:** Slightly increased risk of breast cancer.

**Microscopic morphology:** Sclerosing (i.e., fibrosis) and duct proliferation (i.e., adenosis).

### FIBROADENOMA

**Epidemiology:** Females younger than 25 years of age.

**Prognosis:** Fibroadenomas are almost always benign; carcinoma rarely occurs within a fibroadenoma.

#### Important points regarding fibroadenoma

- Although a fibroadenoma is not itself a risk factor for carcinoma, women who have a fibroadenoma have shown their potential for producing a proliferative lesion and, therefore, in general, have an increased risk of later development of cancer.
- A fibroadenoma can be “shelled out” at surgery (i.e., removed without a rim of breast tissue).

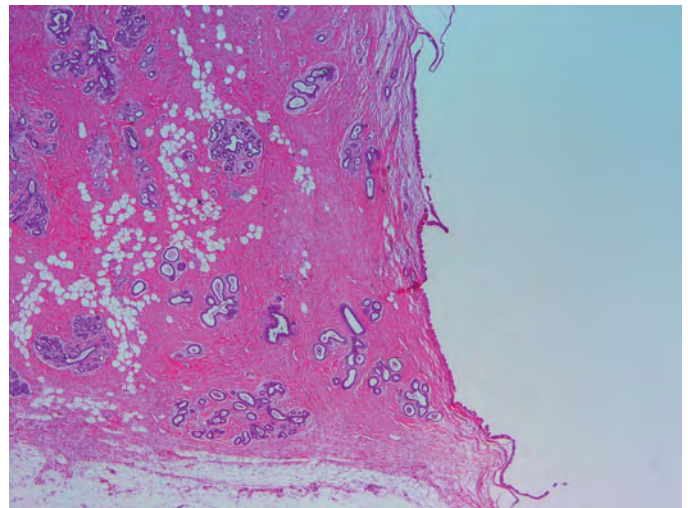
#### Morphology of fibroadenoma

- **Gross:** Well-circumscribed, firm, tan nodule; often multiple and bilateral.
- **Microscopic:** Proliferation of stroma and glands with glandular proliferation greater in amount than stromal proliferation (Figure 17-23).

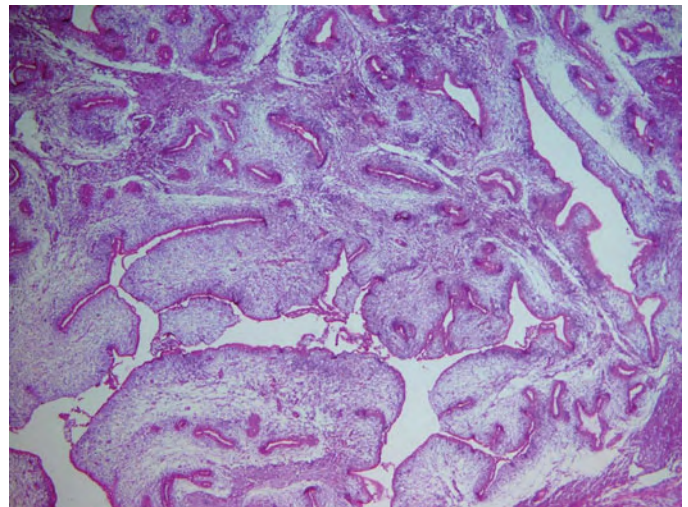
**Clinical presentation of fibroadenoma:** Painless, firm, mobile, “rubbery” nodule. Biopsy is required to rule out malignancy.

### PHYLLODES TUMOR

**Basic description:** Similar to a fibroadenoma, a phyllodes tumor is a stromal and glandular proliferation but with the stromal proliferation predominating, producing a leafy architecture.



**Figure 17-22.** Fibrocystic disease. The large clear space at the right side of the image is a cyst (note the apocrine metaplasia lining), and fibrosis is apparent between the lobules of breast parenchyma. Fibrocystic disease is a risk factor for breast carcinoma only if it has a proliferative component. Hematoxylin and eosin, 40 $\times$ .



**Figure 17-23.** Fibroadenoma. Note the glandular and stromal proliferation. Hematoxylin and eosin, 40 $\times$ .



**Three forms of phyllodes tumor:** Benign, borderline, and malignant, depending upon the degree of stromal overgrowth and presence of anaplasia.

**Important point:** Phyllodes tumor requires wide local excision or it can recur.

#### Morphology of phyllodes tumor

- **Gross:** Fairly well-circumscribed nodule, if benign; most are benign.
- **Microscopic:** Leaf-like proliferation of glands with prominent stromal proliferation.

### INTRADUCTAL PAPILLOMA

**Basic description:** Benign nodule occurs in the ducts and has a papillary architecture (Figure 17-24).

#### Important points

- Produce bloody nipple discharge as a result of sloughing of necrotic tissue.
- Can produce nonbloody discharge as a result of intermittent obstruction of duct.
- Can occasionally be malignant.

## CARCINOMA IN SITU OF THE BREAST

**Overview:** Carcinoma in situ is a premalignant lesion that places the patient at a high risk for future development of invasive carcinoma. There are two types of carcinoma in situ, **ductal** and **lobular**.

### DUCTAL CARCINOMA IN SITU (DCIS)

#### Important points

- Patients with DCIS have a greatly increased risk for development of invasive ductal carcinoma.
- DCIS is not detected as density on mammogram.
- Can be associated with calcification (clustered, or linear and branching), which can be detected on mammogram.

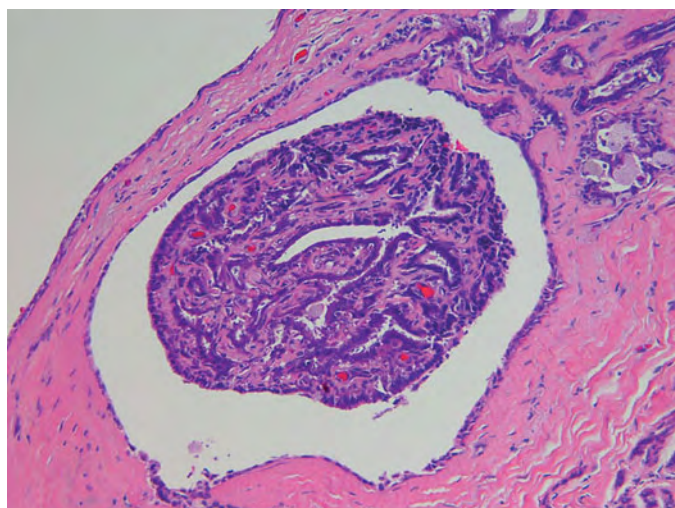
**Risk of breast carcinoma:** 8.0–10.0 times the normal population; the higher the grade of the DCIS, the greater the risk.

#### Microscopic morphology of DCIS (Figure 17-25 A and B)

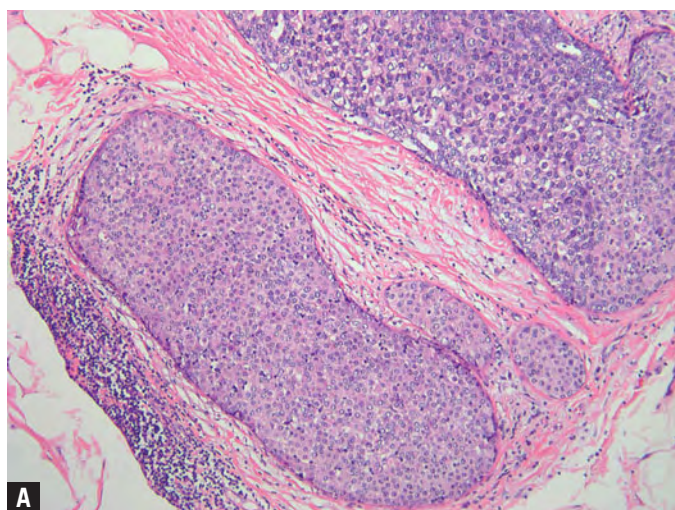
- Proliferation of cells within the duct. The collections of cells produce punched-out lumens (as opposed to slit-like lumens in hyperplasia), and cells “obey” each other’s borders (as opposed to hyperplasia, where they overlap).
- **High-grade DCIS:** Comedo (has central necrosis).
- **Other architectural types:** Cribriform, solid, micropapillary.

**Associated condition:** Paget disease of the nipple

- **Gross morphology:** Erythematous eruption with scaling crust.



**Figure 17-24.** Intraductal papilloma. Although most intraductal papillomas are benign, the lesion can cause bloody nipple discharge, which is a concerning symptom for patients. Hematoxylin and eosin, 200 $\times$ .



**Figure 17-25.** Ductal carcinoma in situ (DCIS). **A**, The ducts are expanded by a proliferation of cells that “obey” each other’s boundaries (i.e., do not overlap). This image illustrates low-grade DCIS. (Continued)

- **Microscopic morphology:** Neoplastic cells in the epidermis (Figure 17-26).
- **Important point:** Paget disease of the nipple is always associated with underlying DCIS, which extends to the epidermis through the lactiferous ducts.

### LOBULAR CARCINOMA IN SITU (LCIS)

#### Important points

- Patients with LCIS have a greatly increased risk for development of invasive breast carcinoma (either lobular or ductal type). The cancer does not necessarily occur at the site of the LCIS—it can occur at a different location or even in the opposite breast. Therefore, *LCIS is a marker of future risk of developing invasive carcinoma*. The ipsilateral breast is thought to be at the highest risk, and in 33% of cases, the resultant carcinoma is invasive lobular.
- The finding of LCIS is always incidental. It is not associated with calcifications and does not produce fibrosis (hence no mass).
- Like lobular carcinoma, LCIS is associated with a lack of e-cadherin.

**Treatment:** Varies from close clinical follow-up to the possibility of bilateral mastectomy; 25–35% of patients with LCIS progress to invasive carcinoma.

**Microscopic morphology of LCIS:** Monotonous proliferation of small cells with oval to round nuclei, which expand the lobule.

## BREAST CARCINOMA

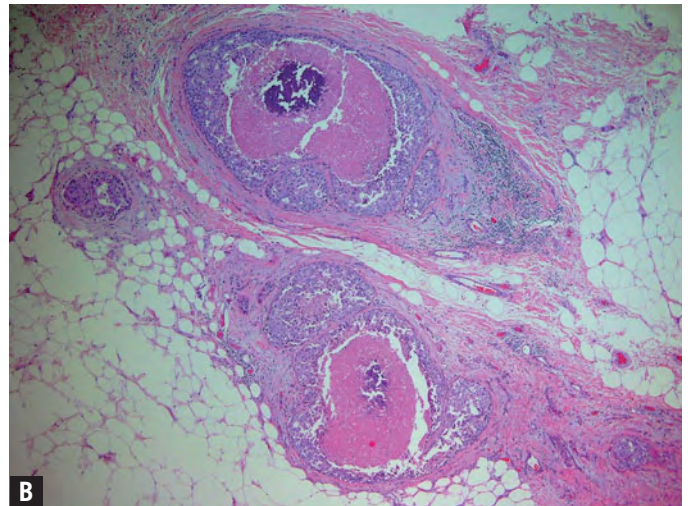
**Epidemiology:** Uncommon in females younger than 30 years of age; rises in incidence as age increases toward menopause. About 1% of cases of breast carcinoma are diagnosed in men.

#### Risk factors for breast carcinoma

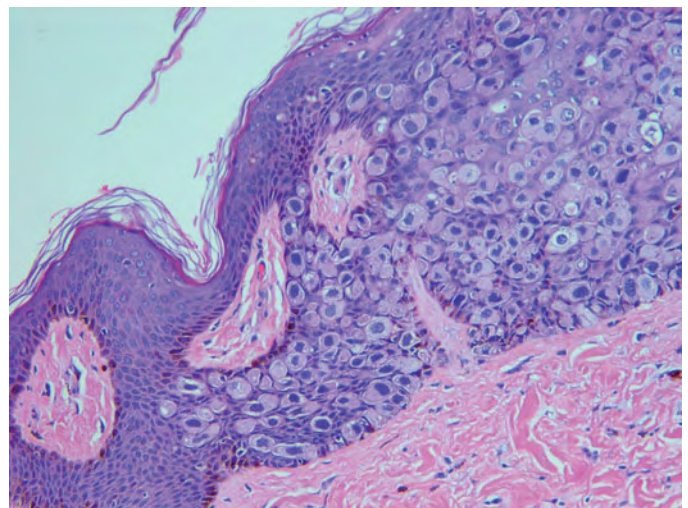
- Age: Rare in females younger than 25 years of age; 70% of breast carcinomas occur in females older than 50 years of age.
- Family history.
- Increased exposure to estrogen (e.g., by early menarche, late menopause, nulliparous or first pregnancy late in life, or exogenous intake) predisposes females to the development of carcinoma. Metabolites of estrogen can cause mutations or generate DNA-damaging free radicals, or estrogen itself can drive proliferation of premalignant lesions and carcinomas.
- Inherited mutations (responsible for < 10% of tumors): *BRCA1* (17q21.3) or *BRCA2* (13q12-13), both of which have gene products that play a role in DNA repair. Inheritance of either mutation results in 60–80% risk of carcinoma.

#### Major prognostic factors for breast carcinoma

- Invasive versus in situ: Excision of in situ lesion results in cure; one half of patients with invasive carcinoma have metastases at diagnosis.



**Figure 17-25.** (Continued) **B**, The ducts are expanded by a proliferation of cells; however, there is central necrosis. Comedo necrosis indicates high-grade DCIS. Hematoxylin and eosin, **A**, 100×; **B**, 40×.



**Figure 17-26.** Paget disease of the nipple. Note the neoplastic cells within the epidermis (right upper corner), with pleomorphic, hyperchromatic nuclei and abundant eosinophilic cytoplasm. Paget disease of the nipple indicates the presence of an underlying ductal carcinoma in situ. Hematoxylin and eosin, 200X.



- Distant metastases or lymph node metastases are poor prognostic indicators.

#### ■ Size of breast tumor

- A node-negative patient with a < 1-cm tumor has a 90% survival rate.
- With a > 2-cm tumor: over one half of patients will have lymph node metastases.

- Invasion of skin or muscle predict a poorer prognosis.

#### ■ Inflammatory carcinoma

- **Basic description:** Inflammatory carcinoma is not a specific type of breast carcinoma, but instead is a term applied to a specific gross appearance of the breast due to certain microscopic findings.
- **Gross morphology:** Swollen, erythematous breast with thickening of skin and dimpling around hair follicles (referred to as **peau d'orange**).
- **Microscopic morphology:** Infiltration of subepidermal lymphatic ducts with neoplastic cells.
- **Important point:** Has a 3-year survival rate of 3–10%.

#### Minor prognostic factors for breast carcinoma

- Histologic type: Medullary, tubular, and colloid carcinomas have a better prognosis.
- Histologic grade: A combination of nuclear grade, tubule formation, and mitotic rate.
- ER and PR positivity: ER- and PR-positive tumors have a better prognosis.
- *Her-2-Neu* positivity: *Her-2-Neu* positivity is a poor prognostic indicator.
- Lymphovascular invasion.
- Proliferative rate: A high proliferative rate has a poorer prognosis.
- DNA content.

**Good prognosis:** Size < 2.0 cm, ER and PR positivity, *Her-2-Neu* negativity, and negative lymph nodes.

**Poor prognosis:** Size > 2.0 cm or > 5.0 cm, ER and PR negativity, *Her-2-Neu* positivity, aneuploidy, and high proliferative rate.

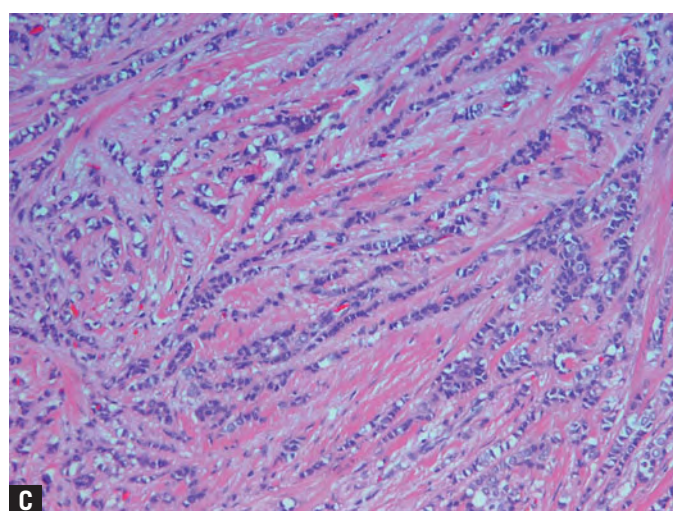
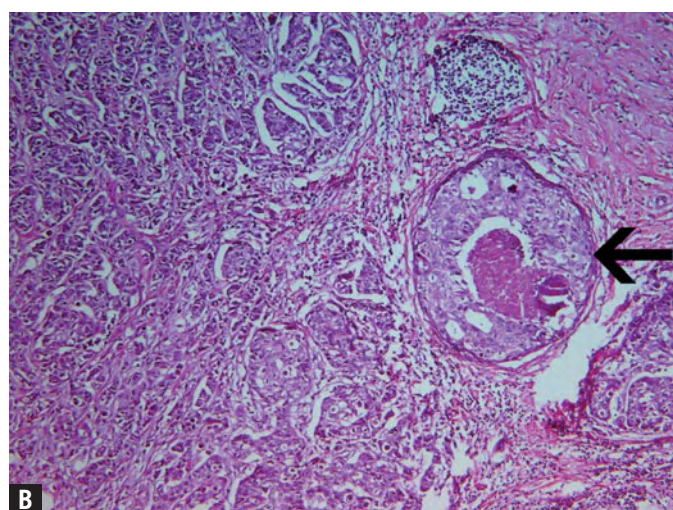
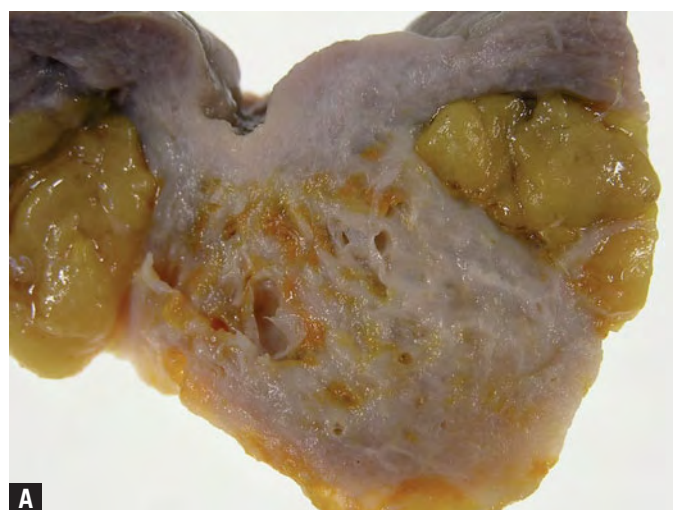*Her-2-Neu* is a proto-oncogene expressed in > 30% of breast cancers; it is an epidermal growth factor receptor.

#### Types of breast carcinoma (Figure 17-27 A)

1. **Invasive ductal carcinoma** (Figure 17-27 B)
2. **Invasive lobular carcinoma** (Figure 17-27 C)
3. **Additional types:** Colloid, medullary, and tubular. These three types are associated with a better prognosis than invasive lobular or invasive ductal carcinomas.

#### Microscopic morphology of invasive carcinoma of the breast

- **Invasive ductal:** Ranges from neoplastic glands to sheets of neoplastic cells.



**Figure 17-27.** Invasive breast carcinoma. **A**, In this cross section of the breast, the ill-defined white-tan mass in the adipose tissue is invasive breast carcinoma. Note the retraction of the overlying skin. **B**, The left side of the image is invasive ductal carcinoma of the breast. The arrow indicates associated high-grade, comedo DCIS. **C**, This image of lobular carcinoma illustrates the characteristic single-file nature of the neoplastic cells. Hematoxylin and eosin, **B** and **C**, 200 $\times$ .



- **Invasive lobular:** Neoplastic cells occur in single-file (see Figure 17-27 C); can surround non-neoplastic glands (referred to as **targetoid lesion**).
- **Medullary:** Well-circumscribed border; sheets of anaplastic cells associated with lymphocytic infiltrate.
- **Colloid:** Produce abundant mucin.
- **Tubular:** Well-formed tubules.

**Mutations found in breast carcinoma:** Deletion 16q22.1—cell adhesion molecules such as e-cadherin and  $\beta$ -catenin.

**Location of breast carcinoma metastases:** To peritoneum, retroperitoneum, leptomeninges, gastrointestinal system, and ovaries.



# CHAPTER 18

## ENDOCRINE PATHOLOGY

### OVERVIEW

In general, most endocrine pathology involves either the overproduction or the underproduction of a hormone. Overproduction of a given hormone may be caused by hyperplasia of the organ that produces the hormone, by a neoplastic process, or by some combination of the two processes. Underproduction of a given hormone, in contrast, may be caused by either destruction of the gland that produces the hormone or by conditions that deprive an endocrine organ of its normal trophic influence.

A working knowledge of the pathways that regulate normal hormone levels helps to interpret the laboratory values in patients being worked up for suspected endocrine disorders. For example, thyroid-releasing hormone (TRH) released by the hypothalamus stimulates thyroid-stimulating hormone (TSH) production by the pituitary gland, which in turn stimulates triiodothyronine ( $T_3$ ) and thyroxine ( $T_4$ ) production by the thyroid gland.  $T_3$  and  $T_4$  then cause feedback inhibition of pituitary release of TSH. If the patient has a TSH-secreting pituitary adenoma,  $T_4$  and  $T_3$  levels as well as the TSH will be high; normally, high  $T_3$  and  $T_4$  levels should cause a low TSH level. Also, remember primary diseases are diseases that originate within the gland in question (e.g., primary hyperthyroidism is due to a defect in the thyroid gland), and secondary diseases represent change in one organ as a result of disease in another organ (e.g., secondary hyperthyroidism may be due to a TSH-secreting pituitary adenoma).

This chapter will discuss diseases of the pituitary gland (hyperpituitarism, hypopituitarism, mass effect as related to pituitary gland lesions, and posterior pituitary gland pathology), diseases of the thyroid gland (goiter, hyperthyroidism, hypothyroidism, thyroiditis, and thyroid neoplasms), diseases of the parathyroid glands (hyperparathyroidism and hypoparathyroidism), diabetes mellitus, diseases of the adrenal glands (hyperadrenalism, hypoadrenalism, hyperaldosteronism, and adrenal neoplasms), and multiple endocrine neoplasia (MEN).

### HYPERPITUITARISM

**Overview:** Overproduction of pituitary gland hormones, usually referring to those derived from the anterior pituitary gland. Causes of hyperpituitarism include adenomas, hyperplasia, and carcinoma.

## PITUITARY ADENOMAS (FIGURE 18-1)

**Epidemiology:** Most pituitary adenomas occur during the fourth to sixth decades of life. Adenomas are the most common cause of hyperpituitarism.

### Hormone production

- About 30% of pituitary adenomas produce prolactin. The second most common hormone produced by adenomas is growth hormone (GH), followed by adrenocorticotropin hormone (ACTH). Thyroid-stimulating hormone (TSH) is rarely produced by adenomas. Adenomas that secrete combinations of different hormones are referred to as **plurihormonal adenomas**. Adenomas producing both prolactin and GH are the most common type of such mixed tumors.
- **Null cell adenomas** are tumors that do not produce a significant amount of hormone, and are the second most common type of adenoma overall.

### Important point regarding pituitary adenomas

- **Stalk effect:** Secretion of all of the anterior pituitary hormones, except prolactin, is stimulated by delivery of releasing hormones, including TRH, gonadotropin-releasing hormone (GnRH), and corticotropin-releasing hormone (CRH), from the hypothalamus via the hypophyseal portal system. Secretion of prolactin, however, is tonically inhibited by the delivery of dopamine via the same portal system. A mass pressing on the stalk will prevent dopamine from reaching the pituitary gland, thus causing increased levels of prolactin without actually producing prolactin. In general, however, the level of prolactin in the “stalk effect” does not equal that produced by a prolactin-secreting adenoma. This stalk effect will, simultaneously, cause inhibition of secretion of the other anterior pituitary hormones.

## SPECIFIC ADENOMAS

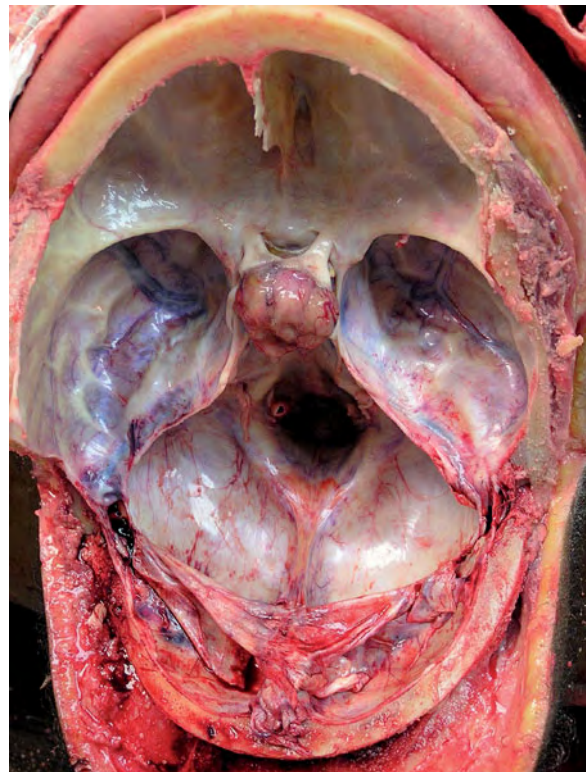
**Overview:** The characteristic features of prolactinomas, GH-producing adenomas, ACTH-producing adenomas, and null cell adenomas will be discussed below.

### 1. Prolactinoma

**Clinical presentation:** Prolactinomas are diagnosed earlier in females (between 20 and 40 years of age) than in males, because patients present with symptoms of galactorrhea, infertility, and amenorrhea. In males, prolactinomas cause decreased libido and impotence.

**Diagnosis:** Basal prolactin level of  $> 200$  ng/mL; brain MRI.

**Important point regarding prolactinoma:** The differential diagnosis of hyperprolactinemia includes pharmacologic and physiologic causes in addition to pituitary lesions. For example, in primary hypothyroidism, both TSH and TRH are elevated. In addition to stimulating release of TSH, TRH causes release of prolactin; thus primary hypothyroidism is a cause of hyperprolactinemia and galactorrhea. Antipsychotic medications that block dopamine are also a common cause of hyperprolactinemia. Other causes include pregnancy.



**Figure 18-1.** Pituitary adenoma. This large pituitary adenoma was an incidental finding at autopsy. As would be suggested by the size of the tumor, this pituitary adenoma did not secrete any hormones (i.e., a null adenoma).



## 2. GH-secreting adenomas

**Mutation:** Often (40%) have a mutation in the *GNAS1* gene on chromosome 20q13, which results in abnormal activation of G protein through inhibition of guanosine triphosphate (GTPase) activity and resultant production of cyclic adenosine monophosphate (cAMP).

### Clinical presentation of GH-secreting adenoma

- In children, **gigantism** (if the adenoma is present before the closure of the epiphyseal plates).
- In adults, **acromegaly** (if the adenoma develops after closure of the epiphyseal plates). Acromegaly is characterized by growth in skin, soft tissue, thyroid gland, heart, liver, and bones of face, hands, and feet. The most classic feature is **acral enlargement**, or widening of the hands and feet and coarsening of facial features. Patients with acromegaly have persistently elevated levels of GH, which stimulates insulin-like growth factor-1 (IGF-1), causing abnormal glucose tolerance and diabetes mellitus. Patients also have muscle weakness, hypertension, arthritis, osteoporosis, and congestive heart failure.

**Diagnosis:** Failure to suppress GH level with an oral load of glucose; IGF-1 levels are elevated.

## 3. ACTH-secreting adenoma

**Diagnosis:** Elevated levels of plasma ACTH and plasma cortisol. Suppression of cortisol and ACTH secretion with high-dose dexamethasone challenge, but no response to low-dose dexamethasone.

**Clinical presentation of ACTH-secreting adenoma:** Produce Cushing disease.

**Important point:** If a patient with an undiagnosed pituitary ACTH-secreting adenoma undergoes adrenalectomy, the pituitary adenoma has aggressive growth due to loss of feedback inhibition. This condition is called **Nelson syndrome**.

- 4. **Null cell adenomas:** Present because of mass effect (see below).

### Morphology of pituitary adenoma

- **Gross:** Hormone-producing adenomas can be small (< 1.0 cm). Null cell adenomas are usually much larger at presentation because a larger size is required to produce mass effect. Mass effects produce the symptoms that allow for the tumor to present in a patient.
- **Microscopic:** Monomorphous proliferation of cells; usually, immunostains are used to identify specific cell types. Adenomas have no reticulin, in contrast to the normal anterior pituitary gland.
- **Clinical presentation of pituitary adenoma:** A macroadenoma can have symptoms due to mass effect, including headache, visual abnormalities (e.g., **bitemporal hemianopsia**), and hypopituitarism due to compression and atrophy of the normal portion of the gland. Patients can also have compression of the oculomotor nerve (CN III), trochlear nerve (CN IV), and the abducens nerve (CN VI), with resultant abnormalities of eye movement.

## HYPOPITUITARISM

**Overview:** Underproduction of pituitary gland hormones. Hypopituitarism is noted clinically if there is a loss of 75% or more of the gland.

### Causes of hypopituitarism

- **Null cell pituitary adenoma:** Mechanism is the growth of a nonsecreting tumor that causes destruction of the adjacent normal gland.
- **Ischemic injury:** For example, in **Sheehan syndrome**, pregnancy causes enlargement of the pituitary gland due to an increase in the number and size of prolactin-secreting cells. The blood supply of the anterior pituitary is derived from the low-pressure hypothalamic-hypophyseal portal venous system and does not increase despite the increase in the overall size of the anterior pituitary, rendering the anterior pituitary vulnerable to ischemic injury. When blood flow to the anterior pituitary is compromised, as in the case of hypotension associated with obstetrical hemorrhage, necrosis of the gland may occur.
- **Pituitary apoplexy**
  - **Basic description:** Hemorrhage into the pituitary gland, usually into an adenoma.
  - **Clinical presentation:** Rapid onset headache and diplopia.
  - **Complications of pituitary apoplexy:** Hypopituitarism and diabetes insipidus; potentially cardiovascular collapse and death.
- **Empty sella syndrome:** Condition due to an incompetent diaphragm sella that allows herniation of arachnoid into the sella turcica. The herniated arachnoid presses on the pituitary gland, which causes atrophy of the pituitary gland.

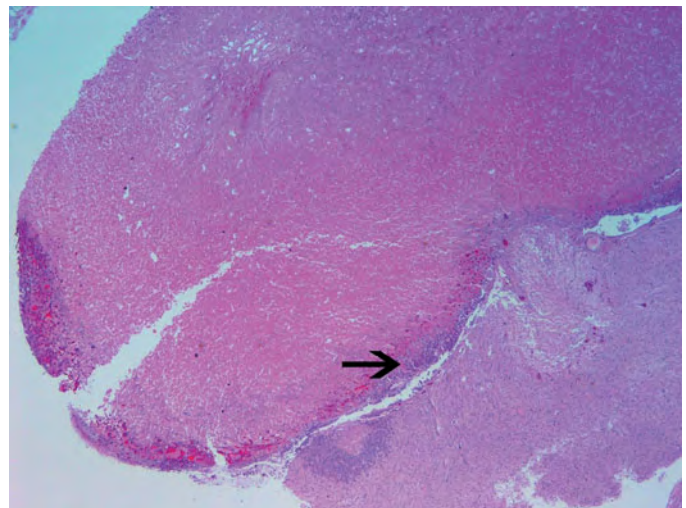
**Others causes of hypopituitarism:** Surgery, radiation, inflammatory reactions, disseminated intravascular coagulation (DIC), and sickle cell anemia. Necrosis of the anterior pituitary may also occur in the setting of increased intracranial pressure due to compression of the low pressure portal veins supplying the anterior pituitary (Figure 18-2).

### Clinical presentation of hypopituitarism

- **GH deficiency**
  - **In infants:** Growth retardation, short stature, and fasting hypoglycemia.
  - **In adults:** Abdominal obesity and reduced strength and exercise capacity.
- **TSH deficiency:** Hypothyroidism (see below).
- **ACTH deficiency:** Hypoadrenalism (see below).
- **ADH deficiency:** Diabetes insipidus (see below).

## MASS EFFECT

**Overview:** Mass effect, in general, refers to the effects of a tumor based upon its mass and the involvement of adjacent structures. The pituitary gland is such a small organ surrounded by numerous vital and important structures that mass effects caused by lesions in the pituitary gland are of vital importance



**Figure 18-2.** Infarct of pituitary gland. This pituitary gland is almost entirely infarcted. Only a thin rim of viable cells remains (*arrow*). Pituitary infarcts occur during pregnancy (Sheehan syndrome), and can occur as a result of cerebral edema. Hematoxylin and eosin, 40 $\times$ .

in diagnosis. Mass effects are most common with null adenomas and other space-occupying lesions of the pituitary gland and surrounding region.

#### Types of mass effect

- Visual field abnormalities: Pressure on the optic chiasm due to a mass lesion produces bitemporal hemianopsia.
- Elevated intracranial pressure, which causes headache and nausea and vomiting.
- Obstructive hydrocephalus: Due to blockage of ventricular system.
- Cranial nerve palsies: Due to impingement upon adjacent cranial nerves.
- Diabetes insipidus: Due to destruction of posterior pituitary gland.
- Hypothalamic disturbances: Disorders of thirst, appetite, temperature regulation, behavior, and consciousness.

#### Causes of mass effect

- Pituitary adenomas: Most often null cell adenomas are the type of adenoma that can grow to a size large enough to cause mass effect.
- Metastatic carcinoma.

#### ■ Craniopharyngioma

- **Epidemiology:** Two age ranges; one at 5–15 years of age and another at the sixth decade or older. Craniopharyngiomas are the most common cause of hypothalamic disturbances in children.
- **Two types: Adamantinomatous** (commonly calcify) and **papillary** (rarely calcify).
- **Important points regarding craniopharyngioma**
  - Derived from Rathke pouch.
  - Most are suprasellar.
  - Prognosis is dependent upon completeness of surgical excision.

## PATHOLOGY OF THE POSTERIOR PITUITARY GLAND

**Overview:** The two syndromes most commonly associated with the posterior pituitary gland are syndrome of inappropriate antidiuretic hormone and diabetes insipidus, which are described below.

### SYNDROME OF INAPPROPRIATE ANTIDIURETIC HORMONE (SIADH)

**Basic description:** Syndrome caused by hyperfunctioning of the posterior pituitary gland resulting in increased levels of antidiuretic hormone (ADH). Increased levels of ADH result in water retention and hyponatremia.

#### Causes of SIADH

- Ectopic ADH (commonly secreted by small cell lung carcinoma).
- Non-neoplastic diseases of the lung (e.g., tuberculosis, pneumonia).



- Central nervous system disorders (e.g., meningitis, abscess, head trauma).
- Injury to the hypothalamus or posterior pituitary gland.

**Mechanism:** Increased retention of water by increased ADH leads to hyponatremia.

#### Clinical presentation of SIADH

- **Symptoms:** Headache, anorexia, vomiting, confusion (when sodium level is 115–120 mEq/L), and stupor; coma and seizures (when sodium level is < 110 mEq/L). SIADH can cause delirium and dementia.
- **Laboratory findings:** Hyponatremia, decreased serum osmolality, inappropriately concentrated urine (> 100 mOsm/kg), and low blood urea nitrogen (BUN).

### DIABETES INSIPIDUS

**Basic description:** Syndrome caused by hypofunctioning of the posterior pituitary gland resulting in decreased levels of ADH.

#### Types of diabetes insipidus

- **Central diabetes insipidus:** Due to decreased production of ADH.
- **Nephrogenic insipidus:** Due to decreased renal responsiveness to ADH.

#### Causes of diabetes insipidus

- **Central diabetes insipidus:** Head trauma, neoplasms, Langerhans cell histiocytosis, infectious processes, surgical procedures, autoimmune diseases.
- **Nephrogenic diabetes insipidus:** Chronic renal disease; sickle cell anemia.

#### Clinical presentation of diabetes insipidus

- **Symptoms:** Polyuria and polydipsia.
- **Laboratory testing:** Dilute urine (specific gravity < 1.005); urine osmolality is < 200 mOsm/kg, and serum osmolality is increased. Administration of ADH will correct central diabetes insipidus, but not nephrogenic diabetes insipidus.
- **Must differentiate from primary polydipsia** (compulsive thirst). In diabetes insipidus, urine osmolality is less than plasma osmolality. In primary polydipsia, both are dilute. The definitive test is water deprivation, which causes decreased urine output and an increase in urine osmolality in primary polydipsia and high urine output and dilute urine (decreased specific gravity) in diabetes insipidus.

### GOITER

**Overview:** Enlargement of the thyroid gland, which can cause hyperthyroidism, hypothyroidism, or euthyroidism. The two types of goiter are endemic (occur in areas of iodine deficiency) and sporadic.

#### Types of goiter

- **Endemic goiter** (i.e., goiters in more than 10% of population): The diet in the area is deficient in iodine. The thyroid gland enlarges so the individual can make the best use of limited

iodine in the body. Patients may be euthyroid as a result, even though the gland is large.

- **Sporadic goiter:** Female predominance; young adults. Sporadic goiter is due to goitrogens such as brussel sprouts, cauliflower, and cabbage, which inhibit the formation of  $T_3$  and  $T_4$ .

**Pathogenesis of goiter:** Low levels of thyroid hormones cause an increased level of TSH, which stimulates the thyroid gland, causing hyperplasia and hypertrophy of follicular cells. Alternating cycles of growth and degeneration lead to nodule formation.

**Gross morphology of goiter:** Enlarged thyroid gland with discrete nodules with a “glassy” texture, caused by the presence of abundant colloid (Figure 18-3).

## HYPERTHYROIDISM

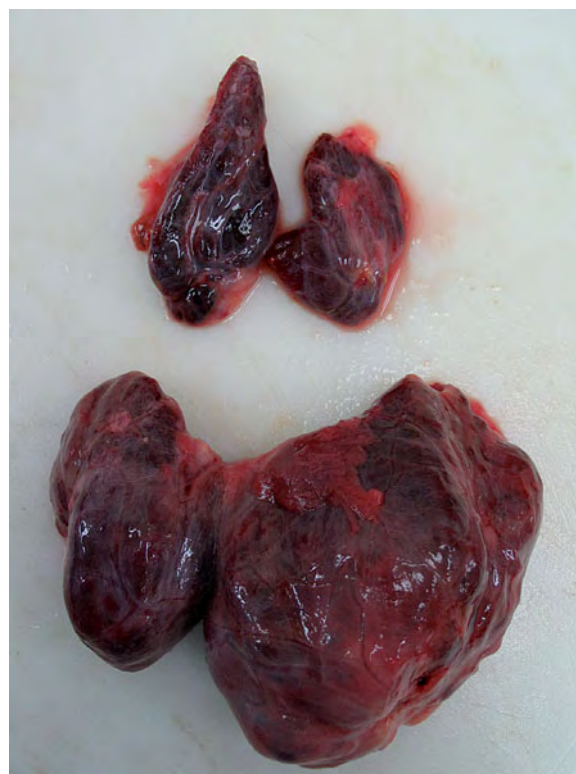**Overview:** Hyperthyroidism increases the basal metabolic rate and increases the organ’s sensitivity to catecholamines. Apathetic hyperthyroidism is most commonly seen in elderly patients, and is characterized by flat affect, weight loss, weakness, and emotional lability.

**Signs and symptoms of hyperthyroidism** (Table 18-1)

- Heat intolerance, sweating, and warm, flushed skin.
- Weight loss associated with increased appetite.
- Palpitations, tachycardia, tremor, anxiety, hyperactivity.
- Diarrhea.
- Fine hair.
- **Important point:** Tachycardia, tremor, and sweating are due to increased sensitivity to catecholamines

**Laboratory findings of primary hyperthyroidism:** Decreased level of TSH and elevated  $T_4$ ; occasionally, patients will have only an elevated  $T_3$ .

**Causes of primary hyperthyroidism:** The two more common causes of primary hyperthyroidism, Graves disease and toxic goiter, will be discussed below. A list of other causes of primary hyperthyroidism will follow that discussion.



**Figure 18-3.** Goiter versus normal thyroid. The thyroid gland at the top of the image is of normal size, and the thyroid gland at the bottom of the image represents a goiter.

**TABLE 18-1.** Comparison and Contrast of Hyperthyroidism and Hypothyroidism

Feature	Hyperthyroidism	Hypothyroidism
Temperature insensitivity	Heat intolerant	Cold intolerant
Weight	Lose weight, but have increased appetite	Gain weight, despite decreased appetite
Activity	Anxious, hyperactive	Depression, sluggish
Gastrointestinal function	Diarrhea	Constipation
Quality of hair	Fine	Coarse

## GRAVES DISEASE

**Pathogenesis:** Due to anti-TSH receptor antibody that stimulates the receptor, resulting in the production of  $T_3$  and  $T_4$ .

**Epidemiology:** Occurs between 20 and 40 years of age; predominance of female to male, with a ratio of 7:1.

**HLA associations:** *HLA-B8* and *HLA-DR3*.

### Morphology of Graves disease

- **Gross:** Thyroid gland itself is diffusely enlarged but not nodular.
- **Microscopic:** Hyperplastic follicles with papillae (Figure 18-4). The papillae do not have fibrovascular cores. “Scalloping” of colloid at the periphery of the follicles.

### Clinical presentation of Graves disease

- **Signs and symptoms of hyperthyroidism.**
- **Exophthalmos:** Protrusion of eye due to retro-orbital soft tissue infiltrated with lymphocytes, edema, and increased amount of glycosaminoglycans. May progress even after hyperthyroidism is under control.
- **Pretibial myxedema:** Scaling and thickening of dermis by deposition of glycosaminoglycans and lymphocytes. No pitting occurs.
- **Important point:** Exophthalmos and pretibial myxedema are specific to Graves disease and are not found in other causes of hyperthyroidism.

**Toxic (diffuse or multinodular) goiter:** A goiter that usually has one or more nodules that produce  $T_3$  and  $T_4$ . However, most goiters are not hyperfunctioning.

**Rare causes of primary hyperthyroidism:** Thyroid adenoma, postpartum thyroiditis, amiodarone toxicity, and iodinated contrast media.

**Causes of secondary hyperthyroidism:** **Struma ovarii** (i.e., ovarian teratoma composed of thyroid tissue) and **hydatidiform mole** (i.e., proliferation of trophoblasts that cause excessive production of chorionic gonadotropin, which has intrinsic TSH-like activity).

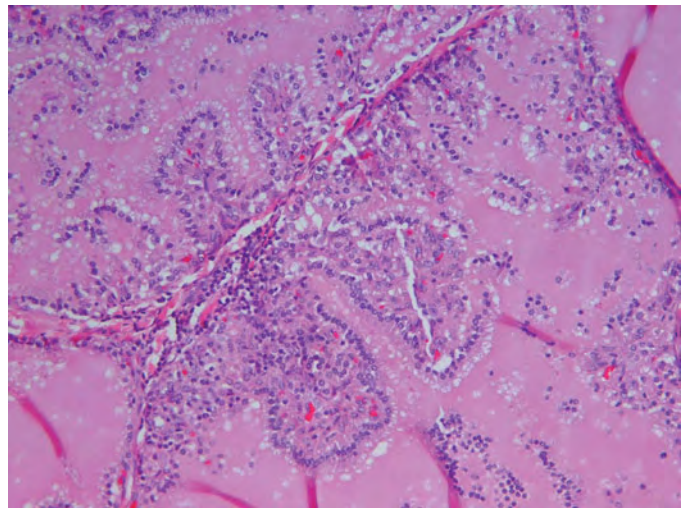
## COMPLICATIONS OF HYPERTHYROIDISM: THYROID STORM

**Basic description:** Abrupt onset of severe hyperthyroidism.

**Cause of thyroid storm:** Most commonly associated with Graves disease in patients with secondarily increased levels of catecholamines due to surgery and acute infection.

**Complications of thyroid storm:** Can cause cardiac dysrhythmias and sudden death.

**Clinical presentation of thyroid storm:** Fever, flushing, and sweating. Patients can have agitation, marked weakness, and mental status changes. Hyperthermia out of proportion to other findings is characteristic of thyroid storm. Patients can also have tachycardia, atrial fibrillation, and delirium.



**Figure 18-4.** Graves disease. The hyperplastic thyroid follicular epithelial cells can form papillae, as is evident in this photomicrograph. Hematoxylin and eosin, 200 $\times$ .



## HYPOTHYROIDISM

**Overview:** Hypothyroidism causes a decreased metabolic rate.

**Signs and symptoms of hypothyroidism** (see Table 18-1)

- Weight gain.
- Cold intolerance and cool skin.
- Thinning hair and loss of lateral portion of eyebrows (known as the “**Queen Anne sign**”).
- Elevated diastolic blood pressure, bradycardia, congestive heart failure.
- Delayed relaxation of deep tendon reflexes (**Woltman sign**), carpal tunnel syndrome.
- Apathy, facial edema, depression.
- Menorrhagia, galactorrhea.
- Constipation.

**Types of hypothyroidism: cretinism and myxedema**

### CRETINISM

**Basic description:** Hypothyroidism occurring during infancy or childhood. Because cretinism is an important preventable cause of mental retardation, most newborns are routinely screened for evidence of hypothyroidism.

#### Features

- Severe mental retardation due to impaired development of the brain.
- Skeletal abnormalities (e.g., short stature).
- Coarse facial features and protruding tongue.

#### Causes of cretinism

- Iodine deficiency.
- Maternal hypothyroidism (if it occurs early in pregnancy, before development of the fetal thyroid gland).
- Inborn metabolic errors in the fetus that interfere with the normal synthesis of thyroid hormones (rare).

### MYXEDEMA

**Basic description:** Hypothyroidism occurring in older children and adults.

**Features:** Signs and symptoms of hypothyroidism.

#### Causes of myxedema

- **Primary hypothyroidism:** Hashimoto thyroiditis, iodine deficiency, and idiopathic.
- **Secondary hypothyroidism:** Failure of the pituitary gland.

#### Complication: myxedema coma

- **Basic description:** Severe complication of hypothyroidism occurring mostly in older patients; characterized by altered mental status with or without coma.
- **Features of myxedema coma:** More common in female patients; rarely occurs in patients younger than 60 years of age. Classic signs are altered mentation, hypothermia, hypotension, and myxedematous physical examination (i.e., presence of signs and symptoms of hypothyroidism).

■ **Causes of myxedema coma:** A precipitating factor is usually present, which may include urinary tract infection or sepsis, trauma, or a side effect of medication.

**Laboratory findings in primary hypothyroidism:** Increased TSH and decreased  $T_4$  and  $T_3$ .

**Laboratory findings in secondary hypothyroidism:** Often decreased TSH and decreased  $T_4$  and  $T_3$ .

**Specific cause of primary hypothyroidism:** Hashimoto thyroiditis

**Pathogenesis:** Inflammatory autoimmune destruction of the thyroid gland.

**Epidemiology:** Hashimoto thyroiditis occurs commonly between 45 and 65 years of age; female to male ratio is 10:1 to 20:1. Hashimoto thyroiditis is associated with both Down and Turner syndromes, and is the most common cause of hypothyroidism and goiter in the United States.

**Morphology of Hashimoto thyroiditis (Figure 18-5 A and B)**

■ **Gross:** Pale, vaguely nodular thyroid gland.

■ **Microscopic:** Lymphocytic infiltrate, usually with follicle formation and plasma cells, and oncocyctic change in follicular epithelium.

**Clinical presentation of Hashimoto thyroiditis:** Insidious onset of hypothyroidism due to gradual loss of thyroid function. Early in the course of the disease, transient hyperthyroidism may be seen because of severe inflammatory destruction of the gland, releasing thyroid hormones into the blood. Symptoms of hypothyroidism may be present, but neck pain should suggest another etiology. Other autoimmune disorders may be present.

**Diagnosis of Hashimoto thyroiditis:** High TSH; anti-thyroid peroxidase and anti-thyroglobulin antibodies are present in 90% of cases.

## THYROIDITIS

**Overview:** Thyroiditis is inflammation of the thyroid gland. Hashimoto thyroiditis is a common form of thyroiditis. However, because Hashimoto thyroiditis is one of the most common causes of hypothyroidism, the disease was discussed earlier. Less common causes of thyroiditis are acute suppurative thyroiditis and subacute thyroiditis, which are discussed in this section.

### ACUTE SUPPURATIVE THYROIDITIS

**Important point:** Rare complication of septicemia.

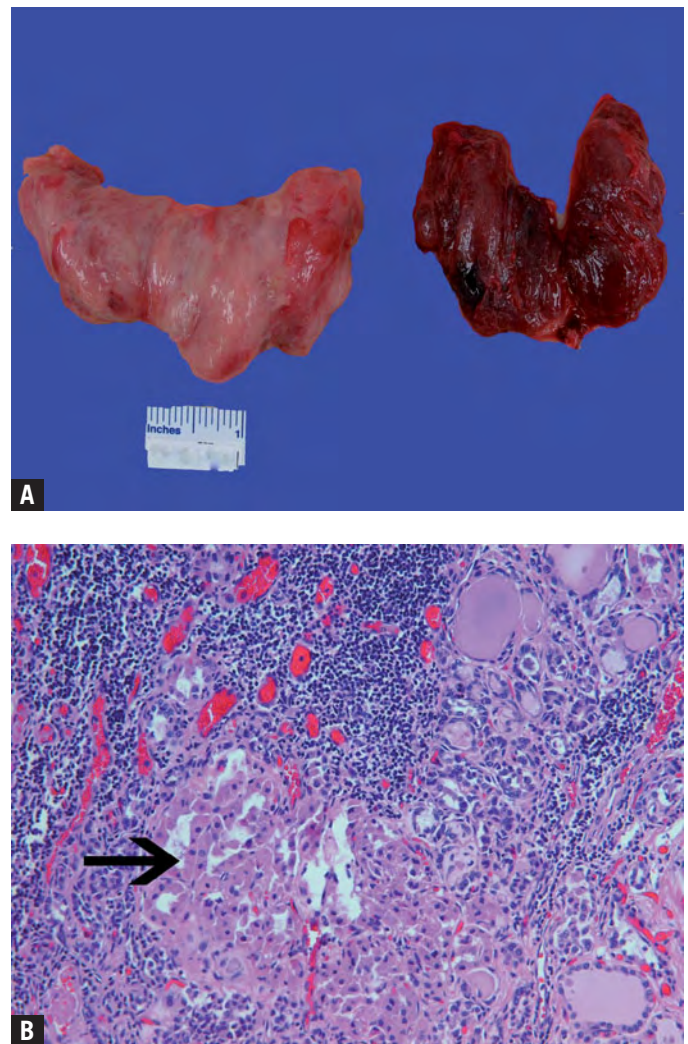
**Clinical presentation:** High fever, redness of skin overlying the thyroid gland, and thyroid gland tenderness.

### SUBACUTE (DE QUERVAIN OR GRANULOMATOUS) THYROIDITIS

**Epidemiology:** Occurs between 30 and 50 years of age; female to male ratio is 3:1 to 5:1.

**Pathogenesis of subacute thyroiditis:** Often follows a viral infection. Associated with *HLA-B35*.

**Microscopic morphology:** Lymphocytes and multinucleated giant cells.



**Figure 18-5.** Hashimoto thyroiditis. **A**, The normal thyroid gland on the right side of the image is dark red-brown, whereas the thyroid gland on the left side of the image is pale tan. The microscopic features of Hashimoto thyroiditis (lymphocyte infiltrate and fibrosis in later stage cases) contribute to the gross appearance. **B**, The characteristic histologic features of Hashimoto thyroiditis are a lymphocytic infiltrate and oncocyctic change of the follicular epithelium (arrow). Hematoxylin and eosin, 200 $\times$ .

### Clinical presentation of subacute thyroiditis

- **Symptoms:** Neck pain; fever.
- **Signs:** Most characteristic is a markedly tender thyroid gland upon palpation. Early hyperthyroidism is followed by a hypothyroid phase. Most patients resume normal thyroid function within 8 weeks.

## NEOPLASMS OF THE THYROID GLAND

**Overview:** When evaluating nodules of the thyroid gland, some features are suggestive of malignancy, including a solitary nodule, young age of patient, male gender, and cold nodules (i.e., no radioactive iodine uptake). Some symptoms are suggestive of malignancy, including pain, rapid rate of growth, and change in voice.

The most important risk factor for thyroid neoplasms is a history of radiation of the head and neck, especially if radiation occurred during the first two decades of life. The diagnosis of a thyroid nodule is done with fine-needle aspiration (FNA) or surgical excision. Nuclear thyroid scans are rarely utilized today in the work-up of a patient with a solitary thyroid nodule, and are never appropriate for the initial workup of lesions strongly suspicious for malignancy. Five common types of thyroid neoplasms are papillary carcinoma, follicular adenoma, follicular carcinoma, medullary carcinoma, and anaplastic carcinoma.

### PAPILLARY THYROID CARCINOMA

**Epidemiology:** Any age, but usually between 20 and 40 years of age. More than 80% of thyroid neoplasms are diagnosed as papillary thyroid carcinoma.

**Mutations:** *RET* proto-oncogene (10q11); *BRAF*, *RAS*.

**Risk factors:** Ionizing radiation.

#### Important points

- Papillary thyroid carcinoma has a good prognosis, even with lymph node metastases. At presentation, cervical lymph node metastases are common.
- The tumor is often multifocal.
- Poor prognosis is associated with size > 2.5 cm, patient older than age 45 years, and tall cell variant.

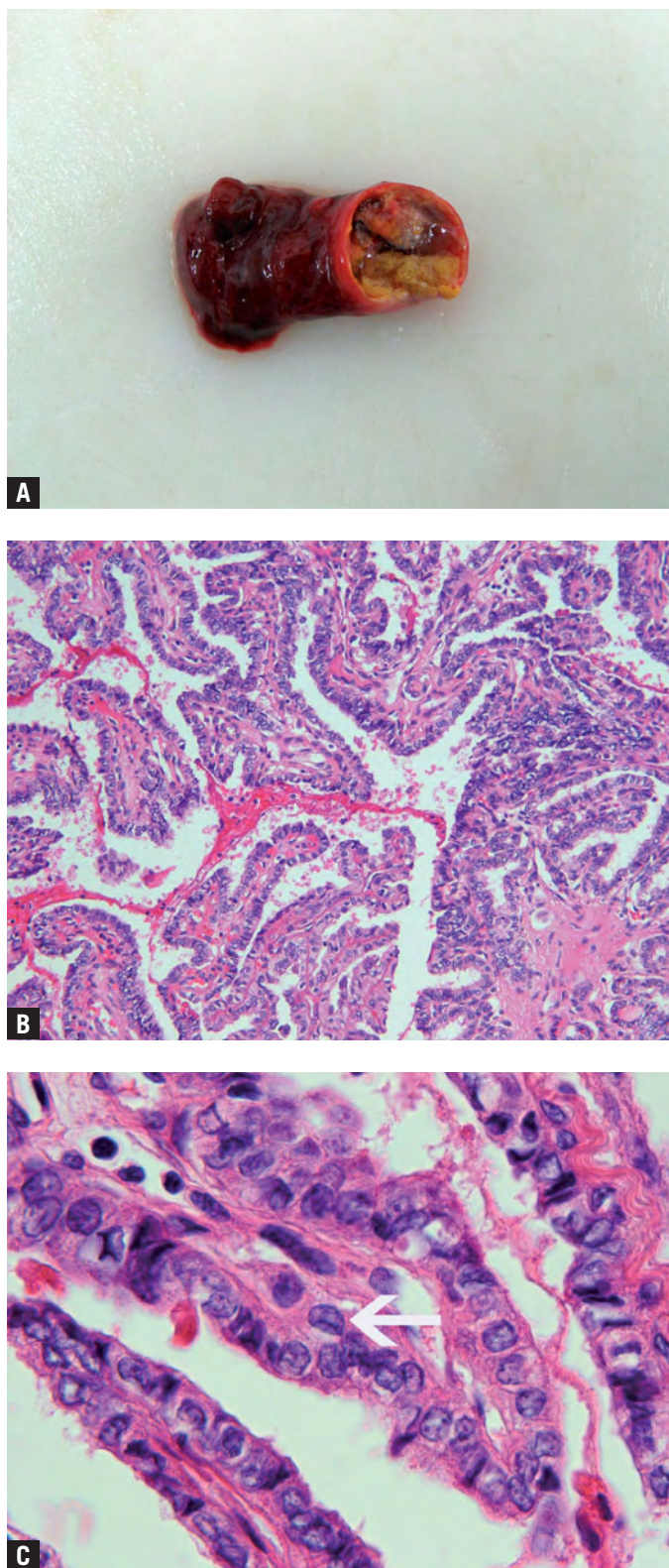
#### Morphology of papillary thyroid carcinoma (Figure 18-6 A–D)

- **Gross:** Variable; sometimes encapsulated.
- **Microscopic:** “Orphan Annie” eye nuclei (i.e., clear nuclei), overlapping nuclei, nuclear grooves, pseudo-inclusions, **psammoma bodies**, and papillary architecture. Nuclear features are the most important criteria for diagnosis of the tumor, as some variants of papillary thyroid carcinoma may have a follicular growth pattern.

### FOLlicULAR ADENOMA AND CARCINOMA

**Epidemiology:** Older patients.

**Incidence:** Adenomas occur frequently; follicular carcinomas account for >10% of malignant thyroid neoplasms.



**Figure 18-6.** Papillary thyroid carcinoma. **A**, Some papillary thyroid carcinomas are encapsulated. **B**, Although there are some histologic variants, most cases of papillary thyroid carcinoma have a low-power papillary architecture. **C**, The nuclear features of papillary thyroid carcinoma are critical to its correct diagnosis—overlapping, clear (“Orphan Annie’s eyes”) nuclei with grooves (arrow) and occasional pseudoinclusions (not seen in the image).



### Mutations

- **Adenoma:** TSH receptor gene *GNAS1*. Mutation in TSH receptor or  $\alpha$ -subunit of  $G_s$  leads to the activation of cAMP pathway.
- **Carcinoma:** *PAX8-PPAR1* (on t(2;3),(q13;p25)); one half of tumors have a mutation of *RAS*.

### Important points regarding follicular adenoma and follicular carcinoma

- Nuclear features are important in distinguishing follicular carcinoma from papillary thyroid carcinoma. As noted above, papillary thyroid carcinoma can have a follicular growth pattern.
- Capsular invasion or blood vessel invasion distinguishes a follicular carcinoma from a follicular adenoma.
- Follicular adenomas and carcinoma usually are not multifocal.

**Prognosis:** Excision is curative for adenomas, and they do not invade or metastasize. If a follicular carcinoma is minimally invasive, the prognosis is good. Adenomas are rarely a precursor of malignancy.

### Morphology of follicular adenoma and follicular carcinoma

- **Gross:** Variable.
- **Microscopic** (Figure 18-7): Identification of capsular or blood vessel invasion is most important to differentiate between adenoma and carcinoma. Follicular carcinoma has capsular or blood vessel invasion, while adenomas do not. Blood vessel invasion must be in the blood vessels outside the neoplasm. Adenomas usually have thin capsules, whereas carcinomas have thick capsules.

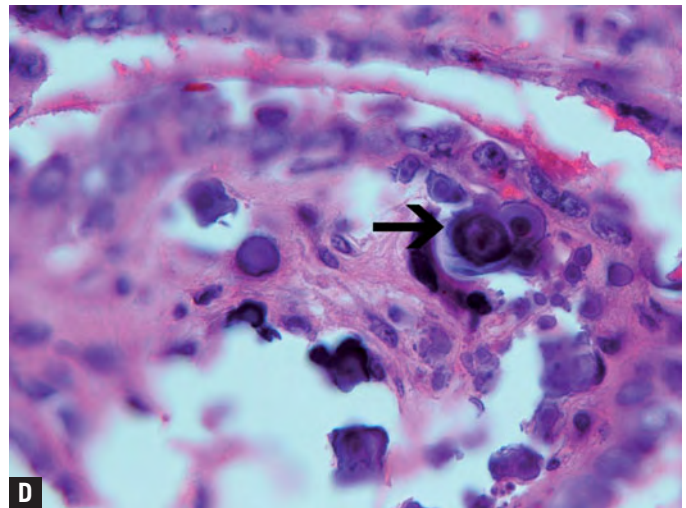
## MEDULLARY THYROID CARCINOMA

**Epidemiology:** Sporadic medullary thyroid carcinoma occurs in older patients (> 50 years); younger adults with multiple endocrine neoplasia (MEN) can develop medullary thyroid carcinoma. Medullary thyroid carcinoma represents approximately 5% of thyroid gland tumors, and 80% are sporadic.

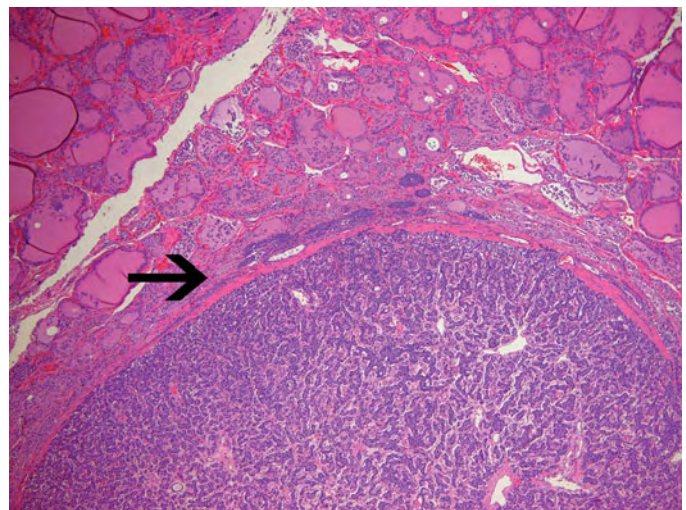
**Mutation:** *RET* (in both MEN and non-MEN familial carcinomas).

### Important points

- Medullary thyroid carcinoma is associated with C-cell hyperplasia.
- Medullary thyroid carcinoma can produce hormones, most commonly calcitonin, but also carcinoembryonic antigen (CEA), serotonin, and vasoactive intestinal peptide (VIP).
- Familial tumors are commonly multifocal and/or bilateral, and are associated with C-cell hyperplasia in the surrounding gland.



**Figure 18-6.** (Continued) **D**, Papillary thyroid carcinomas are one of several tumors associated with psammoma bodies (arrow). Hematoxylin and eosin, **A**, 200 $\times$ ; **B** and **C**, 400 $\times$ .



**Figure 18-7.** Follicular adenoma. The bottom half of the image has a follicular adenoma, with a rim of normal thyroid gland seen in the remainder of the photomicrograph. The follicular adenoma has a thin capsule (arrow), and no invasion of the capsule or adjacent blood vessels was present. Hematoxylin and eosin, 40 $\times$ .

### Morphology of medullary thyroid carcinoma

- **Gross:** Variable.
- **Microscopic:** Variable, including trabecular and occasionally follicular architectural patterns; produce amyloid (Figure 18-8). Both the neoplastic cells and the extracellular amyloid stain strongly for calcitonin.

### ANAPLASTIC CARCINOMA

**Epidemiology:** Older patients (> 50 years of age).

**Important point:** Rapidly growing, highly malignant neoplasm with extremely poor prognosis. The tumor usually causes death within 1 year.

**Microscopic morphology of anaplastic carcinoma:** Variable cell types, including giant cells, spindle cells, and/or small cells (Figure 18-9).

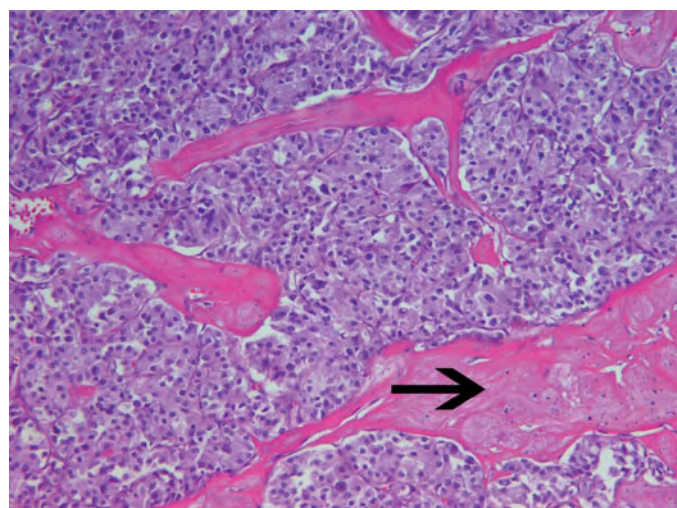
**Clinical presentation:** Pain, dysphagia, hoarseness.

## HYPERPARATHYROIDISM

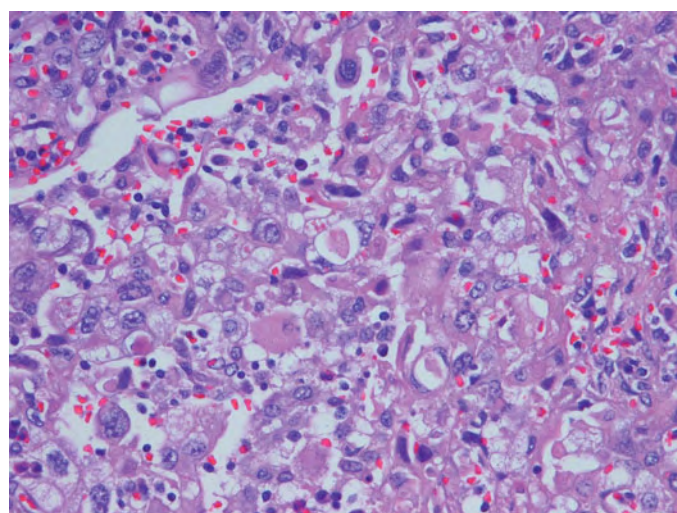
**Overview:** In primary hyperparathyroidism, an elevated level of parathyroid hormone results in hypercalcemia. The most common cause of asymptomatic hypercalcemia is hyperparathyroidism. The most common cause of symptomatic hypercalcemia is metastatic tumor to the bones. RANK ligand (RANKL) is produced by tumor cells and stimulates osteoclasts. Hyperparathyroidism has three important forms: primary, secondary, and tertiary (Table 18-2).

### Signs and symptoms of hyperparathyroidism (due to hypercalcemia)

- Fractures due to weakened bones.
- Kidney stones.
- Psychiatric symptoms; abdominal pain.
- Seizures.
- Constipation, muscular weakness, and hypotonia: High calcium levels hyperpolarize the neuromuscular membranes; therefore, muscle is refractory to stimulus, resulting in weakness and constipation.
- Electrocardiogram has short QT interval.



**Figure 18-8.** Medullary thyroid carcinoma. Amyloid (arrow) is often associated with these tumors. Medullary thyroid carcinoma can be sporadic, but also has familial forms, as well as being a component of multiple endocrine neoplasia, type 2 (MEN 2). Hematoxylin and eosin, 200 $\times$ .



**Figure 18-9.** Anaplastic thyroid carcinoma. Note the nuclear pleomorphism and giant cells. Hematoxylin and eosin, 400 $\times$ .

**TABLE 18-2.** Forms of Hyperparathyroidism

Feature	Primary Hyperparathyroidism	Secondary Hyperparathyroidism	Tertiary Hyperparathyroidism
Causes	Adenoma, hyperplasia	Renal failure, vitamin D deficiency	Autonomous transformation of secondary hyperparathyroidism
PTH level	Increased	Increased	Increased
Calcium level	Increased	Decreased	Normal or increased

PTH, parathyroid hormone.



## PRIMARY HYPERPARATHYROIDISM

### Causes

- Parathyroid adenoma (70–80% of cases) (Figure 18-10).
- Hyperplasia.
- Carcinoma (rare: < 1% of cases).

**Mutations:** *PRAD1*; *MEN1* (in sporadic tumors as well).

**Important point:** Adenomas are confined to a single gland. If more than one gland is enlarged, the condition is hyperplasia.

### Complications of hyperparathyroidism

- **Osteitis fibrosa cystica:** Thinned cortex; hemorrhage and cysts in bone, with changes most prominent in the phalanges and skull.
- **Brown tumors:** Intraosseous accumulations of osteoclasts and giant cells; brown color is imparted by areas of old hemorrhage.
- Nephrolithiasis.

**Laboratory findings of primary hyperparathyroidism:** Elevated PTH; hypercalcemia.

## SECONDARY HYPERPARATHYROIDISM

### Causes

- Renal failure: Decreased phosphate excretion elevates phosphate levels, which depress calcium activity. Also, renal failure causes reduced synthesis of active vitamin D.
- Vitamin D deficiency.

**Laboratory findings:** Elevated PTH, hypocalcemia, and hyperphosphatemia.

## TERTIARY HYPERPARATHYROIDISM

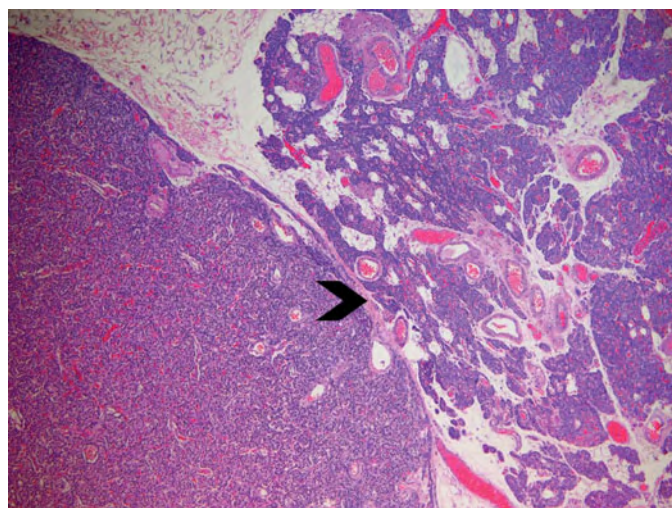
**Overview:** Tertiary hyperparathyroidism is secondary hyperparathyroidism that becomes autonomous (i.e., the parathyroid gland no longer requires the stimulus of renal failure to undergo hyperplasia.)

## HYPOPARATHYROIDISM

**Overview:** The most common cause of hypoparathyroidism is iatrogenic (e.g., removal of parathyroid glands during thyroidectomy). Other causes include congenital absence (in DiGeorge syndrome) and autoimmune hypoparathyroidism. Hypoparathyroidism causes hypocalcemia.

**Symptoms of hypocalcemia:** Reduction in potential difference at neuromuscular membranes causes increased neuromuscular irritability (i.e., tingling and tetany).

**Signs of hypocalcemia:** **Trousseau sign** (a contraction of forearm muscles when the blood pressure cuff is placed around the arm and inflated to above systolic pressure), and **Chvostek sign** (twitching of facial muscles when the facial nerve is tapped). Patients also have cardiac arrhythmias.



**Figure 18-10.** Parathyroid adenoma. The arrow indicates the border between normal parathyroid gland (right half of image) and the parathyroid adenoma (left half of image). Note the lack of adipose tissue within the adenoma. Hematoxylin and eosin, 40×.



## DIABETES MELLITUS

**Overview:** With diabetes mellitus, patients cannot control the level of glucose in their blood. There are two types of diabetes mellitus, type 1 and type 2 (Table 18-3). In type 1 diabetes mellitus, the lack of control of glucose is due to absence of insulin production, and in type 2 diabetes mellitus, it is due to tissue insulin resistance. Although type 1 and type 2 diabetes mellitus each have characteristic features, there is some overlap between the two conditions. Chronically elevated levels of glucose in the blood cause many complications and will be described at the end of this section.

### TYPE 1 DIABETES MELLITUS

**Epidemiology:** Approximately 10% of cases; usually occurs in younger patients, but can occur at any age.

**Pathogenesis:**  $\beta$ -cell destruction, which is a possible autoimmune process with T lymphocytes reactive against islet cells. Some cases of type 1 diabetes mellitus may be caused by a viral infection.

**Associations:** HLA-DR3 and HLA-DR4.

**Clinical presentation of type 1 diabetes mellitus:** Polyuria, polydipsia, and polyphagia.

- Polyuria is due to hyperglycemia causing increased glucose in the urine, which results in osmotic polyuria.
- Polydipsia (i.e., increased consumption of water) results from hyperosmolarity and water loss due to polyuria. These processes stimulate thirst.
- Polyphagia is due to a catabolic state induced by the lack of glucose in cells, resulting in the breakdown of fats and protein. The patient has a large amount of glucose in the blood, but the glucose does not enter the cells.
- Approximately 25% of patients with type 1 diabetes mellitus initially present in diabetic ketoacidosis.

### DIABETIC KETOACIDOSIS (DKA)

#### Diagnosis

- Hyperglycemia ( $> 250$  mg/dL).
- Ketosis.
- Metabolic acidosis with anion gap.

**TABLE 18-3.** Comparison and Contrast of Type 1 Diabetes Mellitus and Type 2 Diabetes Mellitus

Feature	Type 1 Diabetes Mellitus	Type 2 Diabetes Mellitus
Age	Usually $< 10$ – $20$ years	Usually older ( $> 40$ years)
Genetic association	Weak	Strong
Associated acute complication	Diabetic ketoacidosis	Hyperosmolar nonketotic coma
Associated with obesity	No	Yes
Presenting symptoms	Polyuria, polydipsia, polyphagia	Weakness, weight loss, and infections

**Precipitating factors:** Infection, new-onset diabetes mellitus, stress, and insulin deficiency (insulin noncompliance).

**Pathogenesis of DKA:** DKA is characterized by a combination of insulin deficiency and relative glucagon excess. Physiologic stress such as infection contributes to the development of DKA by increasing catecholamine release, which in turn increases the physiologic insulin requirement. Decreased peripheral glucose uptake and utilization caused by insulin deficiency, coupled with excess glucagon, results in hyperglycemia. Insulin-sensitive lipase is activated, resulting in hepatic mobilization of free fatty acids and conversion to ketone bodies for insulin-independent use. The  $\beta$ -hydroxybutyrate produced by ketosis, combined with lactic acidosis, produces an anion gap acidosis. Osmotic diuresis from hyperglycemia causes severe volume depletion and often leads to electrolyte disturbances. Insulin deficiency, and to a lesser extent acidosis, causes a shift of potassium from the intracellular compartment to the serum. Thus, serum potassium is usually normal or elevated despite heavy urinary losses and depletion of total body potassium stores. Rapid insulin infusion can result in profound hypokalemia.

#### Clinical presentation of DKA

- **Symptoms:** Nausea, vomiting, thirst, abdominal pain, weakness, and fatigue.
- **Signs:** Tachycardia; poor skin turgor and warm and dry skin (due to dehydration). Patients also have ketones on breath and altered mental status.
- **Laboratory findings:** Hyperglycemia, anion gap metabolic acidosis, and serum ketones.
- **Important point:** Patients feel sick, so they present earlier than patients with hyperosmolar nonketotic coma (see below).

### TYPE 2 DIABETES MELLITUS

**Epidemiology:** Type 2 diabetes mellitus represents 80–90% of cases of diabetes mellitus. It usually occurs in older patients (> 40 years) and obese individuals, but can occur in children as young as 6 years of age. Risk factors for its development include sedentary lifestyle, poor nutrition, and overweight and obesity.

**Pathogenesis of type 2 diabetes mellitus:** Genetic factors play a more important role in type 2 diabetes mellitus than in type 1 diabetes mellitus (e.g., 50–90% concordance rate for type 2 diabetes mellitus among identical twins). Type 2 diabetes mellitus is due to inadequate secretion of insulin and peripheral resistance to insulin.

**Clinical presentation:** Weakness, weight loss, and susceptibility to infections.

**Important point:** It is commonly taught that type 1 diabetics develop DKA and type 2 diabetics develop hyperosmolar nonketotic coma. In practice, DKA is very common in both type 1 and type 2 diabetics, whereas hyperosmotic coma is unusual.

#### Hyperosmolar nonketotic coma

- Marked hyperglycemia; no metabolic acidosis or ketonemia.
- More dehydration than DKA.
- Low free fatty acid levels; no ketone bodies; serum hyperosmolality (> 325 mOsm/L).

### Diagnostic criteria for diabetes mellitus

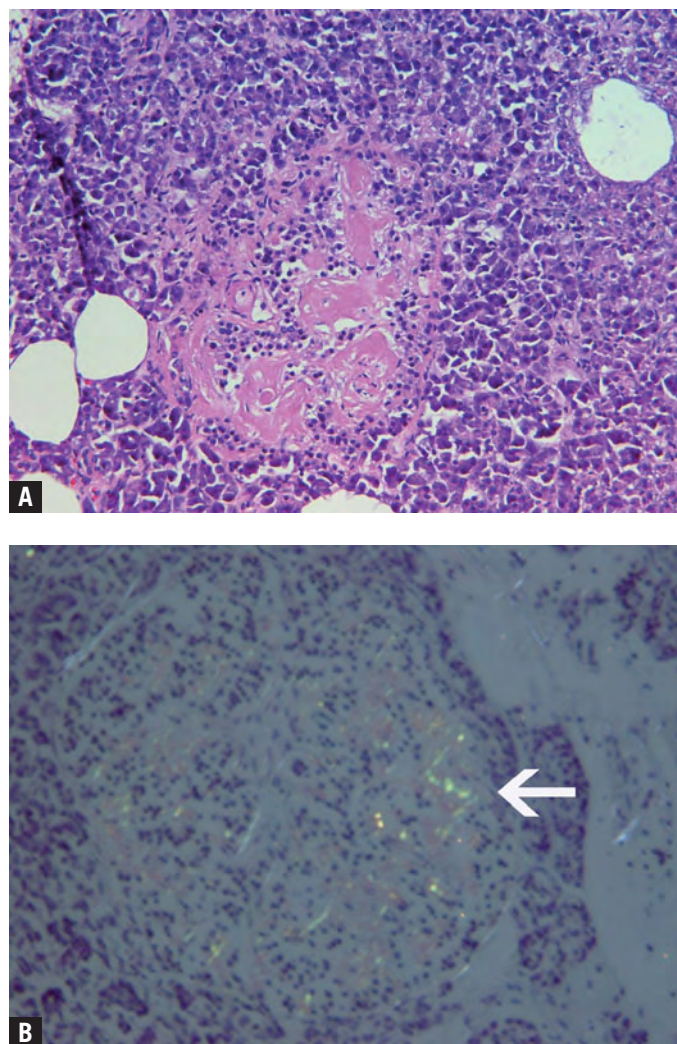
- A single random glucose level  $> 200$  mg/dL in the presence of appropriate symptoms is sufficient for determining the diagnosis of diabetes mellitus.
- Two random glucose tolerance tests with a level  $> 200$  mg/dL in the absence of symptoms.
- Two 2-hour (75 g glucose) glucose tolerance tests with a level  $> 200$  mg/dL.
- A fasting glucose level  $> 126$  mg/dL.
- **Important point:** Hemoglobin A<sub>1</sub>C is a determination of the amount of glycosylated hemoglobin and is used for monitoring the disease process; it is not used for diagnostic purposes.

### Pathogenesis of diabetic complications

- Activation of polyol pathway with accumulation of sorbitol.
- Production of advanced glycosylation end products (and from nonenzymatic glycosylation of proteins).
- Increased oxidative damage.
- Platelet dysfunction associated with increased aggregation.

### Complications of diabetes mellitus

- **Important point:** Diabetes mellitus is the number one cause of end-stage renal disease, blindness, and nontraumatic lower extremity amputations.
- **Pancreas:** Reduction in number and size of islets (type 1 diabetes mellitus); amyloid deposition (type 2 diabetes mellitus) (Figure 18-11 A and B).
- **Vessels:** Diabetes mellitus is a contributor to atherosclerosis in large vessels (i.e., macrovascular damage). In small vessels, diabetes mellitus produces hyaline arteriosclerosis (microvascular damage), which has a similar appearance to that seen in hypertension. There is a different mechanism, however. In hypertension, hyaline arteriosclerosis results from damage of the endothelium by elevated blood pressure, leading to leakage of plasma proteins into the vessel wall with accumulation. In diabetes mellitus, hyaline arteriosclerosis is the result of accumulation of advanced glycosylation end products. Macrovascular damage (atherosclerosis) leads to infarcts (e.g., heart, brain). Diabetics can also develop hypertension due to hyperglycemia-induced endothelial dysfunction.
- **Kidney:** Microalbuminuria (30–300 mg/24 hours), which is associated with 10 to 20 times the increased risk of progression to diabetic nephropathy. Diabetic nephropathy includes diffuse glomerulosclerosis and nodular glomerulosclerosis (**Kimmelstiel-Wilson lesion**); diabetics are also at risk for pyelonephritis with risk of development of papillary necrosis.
- **Eye:** Nonproliferative and proliferative retinopathy; cataracts.
  - Nonproliferative retinopathy is due to increased capillary permeability, dilation of venules, and presence of microaneurysms.
  - Proliferative retinopathy is due to retinal ischemia and hypoxia-induced neovascularization. The new vessels are fragile, and hemorrhage can cause sudden loss of vision.



**Figure 18-11.** Diabetes mellitus, amyloidosis of the islets and ulcer. **A** and **B**, Amyloidosis of the islets. **A**, The single islet in the center of the image contains a prominent amount of acellular eosinophilic material. **B**, Apple-green birefringence under polarization (arrow) on Congo red stain confirms that the material in the islet is amyloid.



- **Peripheral nervous system:** Peripheral neuropathies (sensory loss more than motor loss); decreased sensation causes diabetics to be more prone to injury.
- **Skin and soft tissue of extremities:** Diabetics often develop ulcers and gangrene of the legs, requiring amputation. Decreased sensation causes diabetics to be prone to injury. These patients are unable to feel the damage occurring, and associated damage to vessels leads to poor perfusion that impairs healing (see [Figure 18-11C](#)).
- **Pregnancy:** Large-for-gestational age infants are often born to diabetic mothers.

## HYPERADRENALISM (CUSHING SYNDROME)

**Overview:** Cushing syndrome is due to a hyperfunctioning adrenal gland, which is producing an excess amount of cortisol. Cushing syndrome produces characteristic signs and symptoms and resultant body habitus.

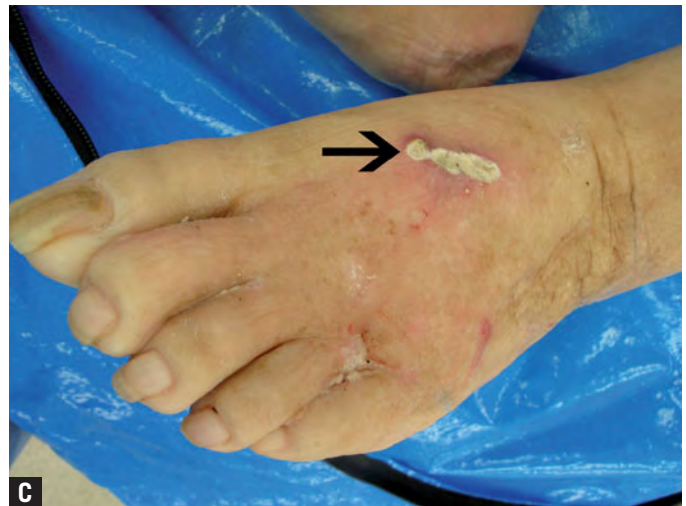### Symptoms and signs

- Hypertension, weight gain, fatigability, weakness.
- Truncal obesity, with wasting of arms and legs; moon facies and accumulation of fat in the posterior neck; cutaneous striae, hirsutism, and acne.
- Proximal muscle weakness with atrophy of type 2 fast-twitch myofibers.
- Inhibition of uptake of glucose by cells leads to hyperglycemia, glucosuria, and polydipsia.
- Resorption of bone, causing osteoporosis.
- Thinning of skin on the top of hands (very characteristic sign of Cushing syndrome in young adults).

**Causes of Cushing syndrome:** Cushing syndrome can result from both exogenous and endogenous causes. Administration of exogenous corticosteroids is the most common overall cause of this syndrome. Endogenous causes of Cushing syndrome can be ACTH-dependent or ACTH-independent.

### ACTH-dependent causes of Cushing syndrome

- ACTH-secreting pituitary adenoma (also called **Cushing disease**) is responsible for 70–80% of cases of endogenous Cushing syndrome.
- Ectopic ACTH secretion by small cell lung carcinoma. These patients usually present with symptoms related to lung disease rather than adrenal disease.
- Ectopic secretion by carcinoid tumor. These patients usually present with symptoms of adrenal disease.
- Other tumors producing ACTH include pancreatic, thyroid, and adrenal tumors.



**Figure 18-11.** (Continued) **C**, Due to loss of sensation secondary to peripheral neuropathy and poor circulation due to vascular damage, diabetics are prone to develop nonhealing ulcers (*arrow*) of the extremities. **A**, Hematoxylin and eosin, 400 $\times$ ; **B**, Congo red, 400 $\times$ .

### ACTH-independent causes of Cushing syndrome

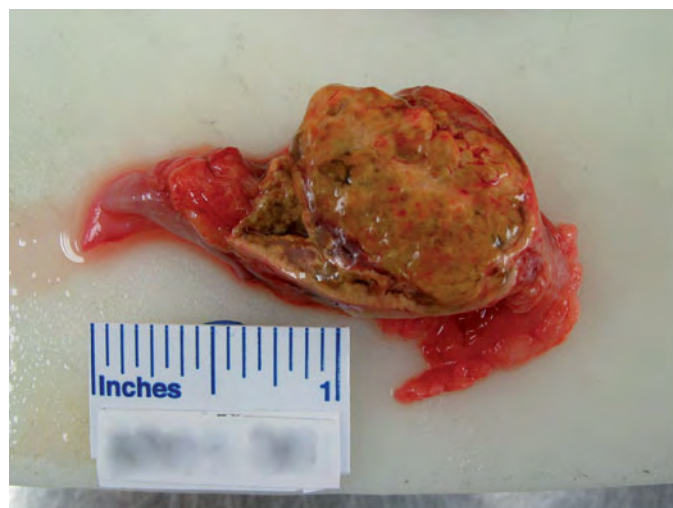
- Adrenal gland adenoma or hyperplasia (Figures 18-12 and 18-13).
- Adenomas are more common than hyperplasia as an ACTH-independent cause of Cushing syndrome.
- Hyperplasia of the adrenal glands in patients with Cushing syndrome is usually secondary due to the stimulus provided by increased ACTH production, and is not the primary cause of the increased cortisol.

### Morphology of Cushing syndrome

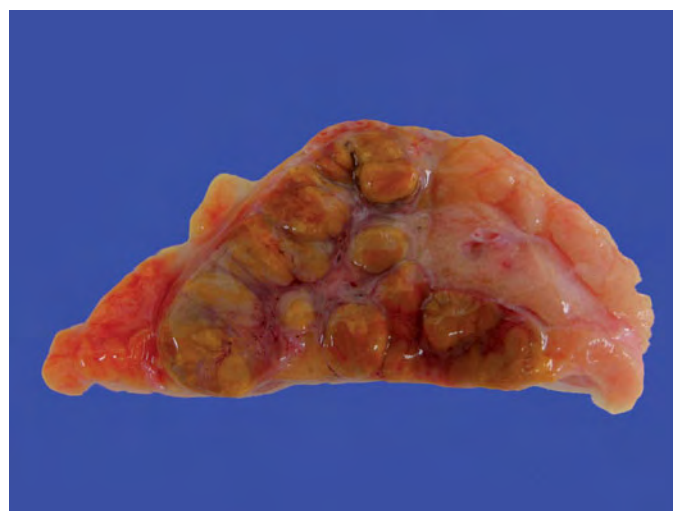
- **Gross and microscopic:** Depends upon the source of ACTH or cortisol.
- With increased cortisol levels, **Crooke hyaline change** occurs in the anterior pituitary gland. Crooke hyaline change is eosinophilic condensation within cytoplasm of ACTH-secreting pituitary basophils.

### Diagnosis of Cushing syndrome (Table 18-4)

- Increased 24-hour urine free cortisol level, which is almost 100% sensitive and specific. Patients also have loss of diurnal pattern of cortisol secretion. The normal diurnal pattern is cortisol levels, which are highest in the morning and lowest at midnight.
- If the patient has elevated cortisol and is given low-dose dexamethasone, and if the cause of elevated cortisol is not Cushing syndrome, the dexamethasone will inhibit ACTH and produce a lower level of cortisol. If dexamethasone does not lower the ACTH level, the patient should be given high-dose dexamethasone. High-dose dexamethasone will inhibit an ACTH-secreting pituitary adenoma, but will not affect adrenal gland hyperplasia or an adenoma-secreting cortisol (since adrenal gland hyperplasia or an adenoma do not require the input of ACTH). High-dose dexamethasone will not inhibit ectopic production of ACTH (e.g., by small cell carcinoma of the lung).



**Figure 18-12.** Adrenal adenoma. Adrenal adenomas may be non-functioning, or they may secrete aldosterone (producing Conn syndrome) or cortisol (producing Cushing syndrome).



**Figure 18-13.** Adrenal hyperplasia. Note the nodularity of the adrenal cortex. Adrenal hyperplasia may be the primary cause of Cushing syndrome (adrenocorticotrophic hormone [ACTH]-independent), but adrenal hyperplasia is more commonly a secondary finding, due to an ACTH-secreting pituitary adenoma (ACTH-dependent Cushing syndrome).

**TABLE 18-4.** Cortisol Level Suppression by Dexamethasone Testing

Condition Causing Hyperadrenalism	Suppression with Low-dose Dexamethasone	Suppression with High-dose Dexamethasone
ACTH-secreting pituitary adenoma	No	Yes
Adrenal gland hyperplasia	No	No
Functional adrenal adenoma	No	No
Ectopic ACTH-production	No	No

ACTH, adrenocorticotrophic hormone.

## HYPOADRENALISM

**Overview:** Hypoadrenalism is due to an adrenal gland that produces an insufficient amount of cortisol. Primary hypoadrenalism occurs in two major forms: acute and chronic. Secondary hypoadrenalism, and its relation to cortisol therapy, is discussed below, following acute and chronic primary adrenocortical insufficiency.

### Causes of acute primary adrenocortical insufficiency

- Rapid withdrawal of exogenous steroids in patients on chronic corticosteroid therapy: Exogenous steroids feed back on the pituitary gland to reduce the level of ACTH. Thus, the adrenal glands have no stimulus for growth and, therefore, undergo atrophy during treatment with steroids. Steroids must be withdrawn slowly to allow regeneration of glucocorticoid-producing cells in the zona fasciculata of the adrenal cortex (Figure 18-14 A and B).
- Acute exacerbation of chronic adrenal insufficiency.
- Anticoagulant therapy, postoperative patients with DIC, and pregnancy.
- **Waterhouse-Friderichsen syndrome:** Overwhelming sepsis due to *Neisseria meningitidis* and *Pseudomonas* associated with hemorrhagic necrosis of the adrenal glands (Figure 18-15).

### Clinical presentation of acute adrenocortical insufficiency

- **Symptoms:** Severe abdominal pain, nausea and vomiting, and somnolence.
- **Signs:** Hypotension.

### Causes of chronic adrenocortical insufficiency

## ADDISON DISEASE

**Overview:** Addison disease, an autoimmune disorder, is the most common cause of chronic primary adrenal insufficiency in developed nations.

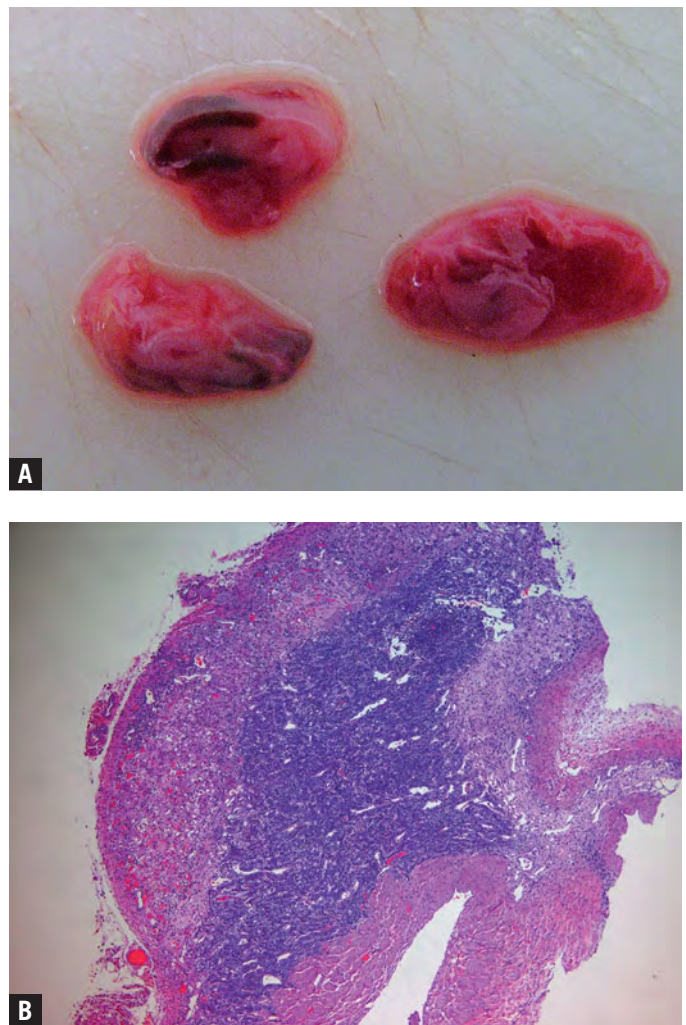
**Important point:** Patients have increased pigmentation of pressure points and buccal mucosa due to increased levels of melanocyte-stimulating hormone. Melanocyte-stimulating hormone is produced along with ACTH in the form of pro-opiomelanocortin, which is cleaved to its respective segments. Note that patients with adrenal insufficiency due to pituitary disorders (secondary adrenal insufficiency) do not have hyperpigmentation, since these conditions are characterized by low ACTH levels.

**Pathogenesis of Addison disease:** Autoantibody to 21-hydroxylase and 17-hydroxylase.

**Other causes of chronic adrenal insufficiency:** Metastatic tumor (Figure 18-16), infections (e.g., tuberculosis, *Histoplasma*, *Coccidioides immitis*), amyloidosis, and hemochromatosis.

### Clinical presentation of chronic adrenocortical insufficiency

- **Symptoms:** Weakness, gastrointestinal disturbances, weight loss, salt craving.
- **Signs:** Hyponatremia, hyperkalemia, hypoglycemia, hypotension, decreased aldosterone.



**Figure 18-14.** Adrenal atrophy due to corticosteroid therapy. **A**, The adrenal gland is markedly atrophic, with little if any normal cortex identified grossly. **B**, Microscopically, the medulla (central basophilic cells) is much more prominent than the cortex. Slow withdrawal of steroids is mandatory to allow the regrowth of the cortex. Hematoxylin and eosin, 40 $\times$ .



## SECONDARY HYPOADRENALISM

**Basic description:** Condition due to pituitary gland destruction (see hypopituitarism) or due to suppression of adrenal gland (due to exogenous steroids).

### Important points

- Hyperpigmentation does not occur in secondary hypoadrenalism, since ACTH levels (and, thus, MSH production) are decreased.
- Mineralocorticoid levels are normal, so hyperkalemia and salt craving do not occur. Hyponatremia can still occur because of increased ADH, which occurs in response to volume depletion.

### Clinical presentation of secondary hypoadrenalism

- **Symptoms:** Weakness, weight loss, anorexia, and nausea and vomiting.
- **Laboratory finding:** Patients do *not* have decreased levels of aldosterone.

### Distinguishing primary hypoadrenalism from secondary hypoadrenalism

- In primary hypoadrenalism, ACTH is increased. In secondary hypoadrenalism, ACTH is decreased. Aldosterone levels are normal or decreased in primary hypoadrenalism and normal in secondary hypoadrenalism.
- **ACTH stimulation test:** Give ACTH and measure plasma cortisol level; in secondary hypoadrenalism, the cortisol level should increase.

## CONGENITAL ADRENAL HYPERPLASIA

**Basic description:** Condition due to a deficiency of an enzyme in the pathway of cortisol synthesis. Lack of cortisol stimulates production of ACTH, which stimulates adrenal glands, causing hyperplasia.

**Types:** Five types; most common type is due to 21-hydroxylase deficiency (95% of cases).

**Pathogenesis:** Failure of 21-hydroxylation of 17-hydroxyprogesterone and progesterone to 11-deoxycortisol and 11-deoxycortisone results in deficient cortisol and aldosterone production. ACTH secretion is increased, resulting in increased production of androstenedione and dehydroepiandrosterone (DHEA).

### Forms of congenital adrenal hyperplasia: classic and late onset

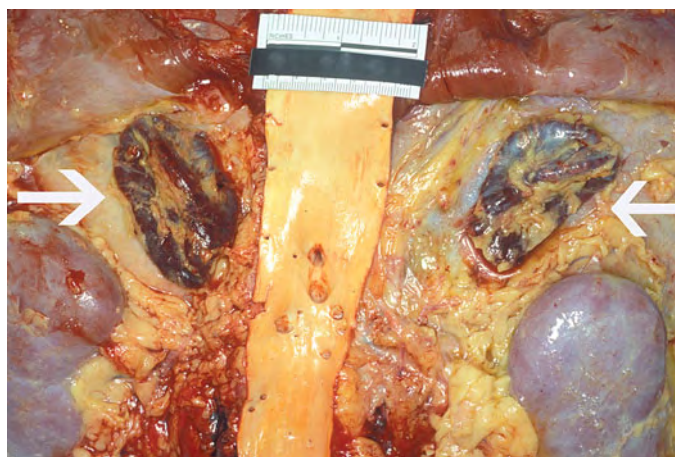
#### 1. Classic congenital adrenal hyperplasia

**Epidemiology:** Diagnosed at birth. Two thirds of patients are salt wasting.

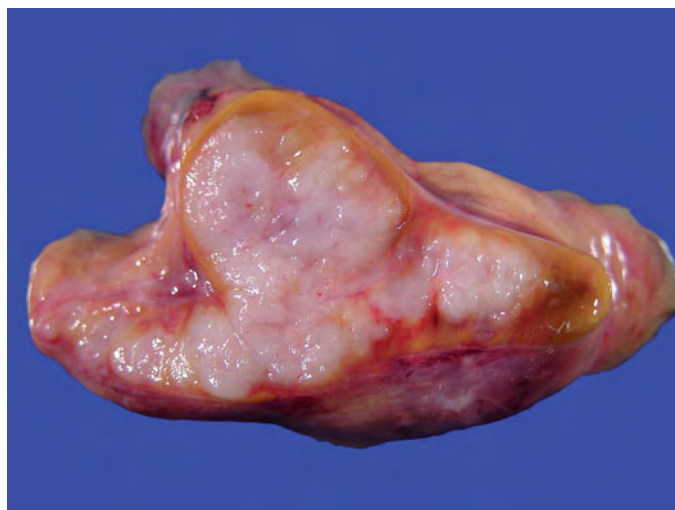
#### 2. Late onset congenital adrenal hyperplasia

**Epidemiology:** Diagnosed at or after puberty.

**Clinical presentation:** Virilization (e.g., hirsutism, acne), amenorrhea, or oligomenorrhea.



**Figure 18-15.** Waterhouse-Friderichsen syndrome. The adrenal glands are in situ. The aorta has been opened, and the perirenal adipose tissue removed from the kidneys. Both adrenal glands are hemorrhagic (arrows). Waterhouse-Friderichsen syndrome is a cause of acute adrenal insufficiency due to overwhelming sepsis caused by *Neisseria meningitidis*, *Pseudomonas*, and other organisms. Courtesy of Dr. Gary Dale, Forensic Science Division, Montana State Department of Justice, Missoula, MT.



**Figure 18-16.** Metastatic squamous cell carcinoma of the adrenal gland. The normal architecture of this adrenal gland is nearly obliterated by this focus of metastatic squamous cell carcinoma in a patient with squamous cell carcinoma of the lung. This condition would lead to chronic adrenocortical insufficiency.

## HYPERALDOSTERONISM

### PRIMARY HYPERALDOSTERONISM (CONN SYNDROME)

#### Causes

- Neoplasm (usually adrenal adenoma).
- Adrenocortical hyperplasia.

**Laboratory findings:** Hypernatremia and hypokalemia. The two most common causes of hypokalemia are primary hyperaldosteronism and diuretic therapy. Patients with primary hyperaldosteronism also have increased aldosterone and decreased renin levels.

### SECONDARY HYPERALDOSTERONISM

**Causes:** Decreased renal perfusion (e.g., due to renal artery stenosis or atherosclerosis), hypovolemia and edema, and pregnancy.

**Laboratory findings:** Increased aldosterone and increased renin.

## ADRENAL NEOPLASMS

**Overview:** Adrenal adenomas, Conn syndrome, adrenocortical carcinoma, and pheochromocytomas represent the majority of adrenal neoplasms.

#### Adrenal adenoma

- **Important point:** Most adrenal adenomas are nonfunctioning, and if plasma ACTH is detected, a primary adrenal adenoma as a source for Cushing syndrome is unlikely. A functioning adrenal adenoma would produce cortisol, which will feed back on the pituitary gland and inhibit ACTH production.
- **Morphology:** Yellow nodule in adrenal cortex.

#### Conn syndrome

- **Basic description:** Adenoma of the glomerulosa cells that produces aldosterone, which results in secondary hypertension. Conn syndrome can also be due to hyperplasia of the adrenal glands, but is most commonly associated with an adrenal adenoma.
- **Laboratory findings:** Include hypokalemia and low plasma renin level.

**Adrenocortical carcinoma:** Size (weight) is important in differentiating an adrenocortical carcinoma from an adenoma. A tumor weighing > 100 grams is more likely to be a carcinoma than an adenoma.

#### Pheochromocytoma

- **Basic description:** A tumor of the adrenal medulla that secretes epinephrine and norepinephrine, causing episodic hypertension.
- **Associated conditions** (i.e., conditions that often manifest with a pheochromocytoma): MEN 2A and 2B, von-Hippel Lindau syndrome, von Recklinghausen disease of bone, and Sturge-Weber syndrome.

### ■ Important points regarding pheochromocytoma

- 10% are familial.
- 10% are extra-adrenal (e.g., in the carotid body or sympathetic chain).
- 10% are bilateral.
- 10% are malignant (require metastases to determine malignancy).
- 10% occur during childhood.

### ■ Morphology of pheochromocytoma (Figure 18-17 A and B)

- **Gross:** Yellow-tan; can be hemorrhagic.
- **Microscopic:** Bland, monomorphous cells in nests (referred to as **Zellballen pattern**); nuclei have salt and pepper chromatin.

### ■ Clinical presentation of pheochromocytoma

- **Signs and symptoms:** Precipitous tachycardia, palpitations, pounding headache, sweating, and weight loss. Symptoms can be precipitated by stress (e.g., surgery, acute infections) and hypertension (episodic in classic cases, but in other cases may be more sustained).

### ■ Laboratory diagnosis of pheochromocytoma

- **Plasma:** Free metanephrine level  $> 0.61$  nmol/L and normetanephrine level  $> 0.31$  nmol/L. A 24-hour metanephrine test is almost 100% sensitive.
- **Urine:** Free catecholamines; vanillylmandelic acid (VMA).
- **Important point:** Plasma testing is performed first; urine testing if needed.

## MULTIPLE ENDOCRINE NEOPLASIA (MEN) 1

**Name:** Wermer syndrome.

**Mutation:** *MEN1* gene at 11q13 (protein is menin, a tumor suppressor gene).

### Organs affected

- **Parathyroid gland:** Hyperplasia or adenoma.
- **Pancreas:** Endocrine tumors, which are usually aggressive and multifocal and may secrete gastrin or insulin.
- **Pituitary gland:** Prolactinoma, most common form of pituitary adenoma in MEN 1.

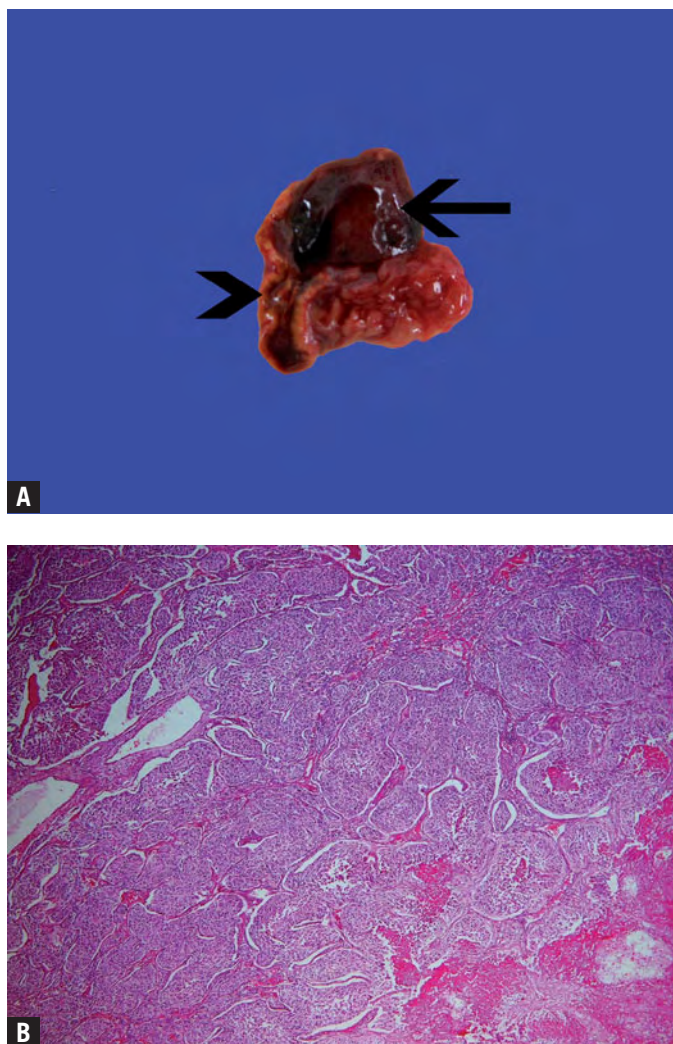
## MEN 2A

**Name:** Sipple syndrome.

**Mutation:** *RET* proto-oncogene (10q11.2); mutation causes activation of receptor producing “gain of function.”

### Organs affected

- **Thyroid gland:** Medullary thyroid carcinoma.
- **Adrenal medulla:** Pheochromocytoma.
- **Parathyroid gland:** Hyperplasia.



**Figure 18-17.** Pheochromocytoma. **A**, The mass in the adrenal medulla (arrow) is a pheochromocytoma. The arrowhead indicates the adrenal cortex. **B**, Histologically, pheochromocytomas appear as bland monomorphic cells in nests (the “zellballen” pattern). Hematoxylin and eosin, 40 $\times$ .



## MEN 2B

**Mutation:** *RET* proto-oncogene; different mutation than in MEN 2a.

### Organs affected

- **Thyroid gland:** Medullary thyroid carcinoma.
- **Adrenal medulla:** Pheochromocytoma.

### Difference from MEN 2a

- MEN 2b does *not* develop parathyroid gland hyperplasia.
- MEN 2b has ganglioneuromas and marfanoid habitus.



# CHAPTER 19

## PATHOLOGY OF THE BONES AND JOINTS

### OVERVIEW

Diseases of the bone include non-neoplastic disorders such as genetic defects (e.g., achondroplasia), osteoporosis, infections of the bone (i.e., osteomyelitis), and Paget disease. The age of the patient and the location of the tumor are very important considerations in the diagnosis of bone tumors. For example, most chondrosarcomas occur in older adults and almost never occur in the bones of the hands, whereas most Ewing sarcomas occur in the diaphysis of long bones of children.

Diseases of the joints include inflammatory and noninflammatory arthritides. The two major types of arthritis are osteoarthritis and rheumatoid arthritis. Wear and tear is one of the major etiologic agents for the development of osteoarthritis, whereas rheumatoid arthritis is considered to be an autoimmune condition. An important molecular topic regarding bone pathology is the receptor for nuclear factor- $\kappa\beta$  (RANK), which is expressed on macrophages, monocytes, and preosteoclasts. The binding of RANK ligand (RANKL) to RANK stimulates osteoclastogenesis. RANKL is produced by osteoblasts and marrow stromal cells. Osteoprotegerin binds to RANK and blocks the binding of RANKL; therefore, it is inhibitory.

This chapter will discuss non-neoplastic bone diseases (including those caused by genetic defects, osteoporosis, osteonecrosis, osteomyelitis, Paget disease, renal osteodystrophy, and fractures), bone neoplasms, and joint disorders, primarily osteoarthritis, rheumatoid arthritis, and gout.

### INHERITED DEFECTS IN BONE STRUCTURE

**Overview:** There are many inherited conditions that result in abnormalities of bone structure. Three of the more common types, achondroplasia, osteogenesis imperfecta, and osteopetrosis, will be discussed below.

#### ACHONDROPLASIA

**Inheritance pattern:** Autosomal dominant; 80% of new cases are the result of spontaneous mutations.

**Mutation:** Gene for FGF receptor 3 (*FGFR3*) on the p arm of chromosome 4.

**Effect of mutation:** FGF receptor 3 (*FGFR3*) is an inhibitor of cartilage proliferation. The mutation places the receptor in a constant state of activation.

#### Manifestations of achondroplasia

■ **Gross:** Disproportionate dwarfism with normal trunk length and short extremities, varus and valgus deformities of legs, short fingers and toes, and large head with prominent forehead.

■ **Microscopic:** Narrow and disorganized zones of proliferation and hypertrophy.

**Important points:** Achondroplasia accounts for 70% of cases of dwarfism. Less commonly, dwarfism may be due to pituitary dysfunction or secondary to a mutation in the growth hormone receptor (**Laron dwarfism**).

### OSTEOGENESIS IMPERFECTA

**Overview:** There are several different types of osteogenesis imperfecta, each one caused by one of several different mutations. Some of the mutations have an autosomal dominant inheritance pattern. Only type I and type II osteogenesis imperfecta, two of the more common forms of the disease, will be discussed in detail here.

**Mutations:** Gene for  $\alpha 1$  and  $\alpha 2$  chains of type I collagen.

**Effect of mutation:** Varies, depending upon mutation. The results vary from phenotypically normal collagen produced in decreased amounts to absence of collagen production.

#### Two types of osteogenesis imperfecta

##### 1. Type I osteogenesis imperfecta

**Mutation:** Decreased synthesis of pro- $\alpha 1(1)$  collagen chain, which is compatible with normal life span or abnormal pro- $\alpha 1(1)$  or pro- $\alpha 2(1)$  collagen chains, which produce the complications discussed below.

**Manifestations:** Increased number of fractures; blue sclerae because of thin layer of collagen, causing choroid to be visible; hearing loss; and defective dentition. Patients can have a normal life span.

**Microscopic morphology:** Osteoporosis (i.e., decreased bone mass; bones have thin trabeculae).

##### 2. Type II osteogenesis imperfecta

**Mutation:** Can involve gene for pro- $\alpha 1(1)$  collagen chain in autosomal recessive form of the disease or produce an unstable triple helix in autosomal dominant form of the disease.

**Manifestations:** Death in utero or early perinatal period. Patients have multiple fractures.

### OSTEOPETROSIS

**Effect of mutation:** Decreased resorption of bone by osteoclasts results in increased amount of bone, but the bone is structurally weak.



### Types of osteopetrosis

#### 1. Infantile malignant osteopetrosis

- **Inheritance pattern:** Autosomal recessive.
- **Manifestations:** Fractures, hydrocephaly, anemia, and infections due to decreased hematopoiesis, and hepatosplenomegaly due to extramedullary hematopoiesis.

#### 2. and 3. Autosomal dominant type I and type II

- **Manifestations of both type I and type II autosomal dominant osteopetrosis:** Fractures, anemia, and mild cranial nerve defects due to impingement.

#### 4. Carbonic anhydrase II deficiency

- **Effect of mutation:** Inability to excrete hydrogen ions.

### Morphology of osteopetrosis

■ **Gross:** No medullary canal; bulbous ends of long bones (i.e., **Erlenmeyer flask deformity**).

■ **Microscopic:** Woven bone, with obliteration of marrow cavity.

**Treatment of osteopetrosis:** Bone marrow transplantation, since osteoclasts are derived from monocyte precursors.

## OSTEOPOROSIS

**Overview:** Osteoporosis is due to a decrease in bone mass with a subsequent increase in the risk for fractures. Osteoporosis can be localized to one or a few bones (because of disuse) or generalized (involving a majority of the skeletal system). Osteoporosis can be a primary disorder, or it may be secondary to many other disorders.

**Epidemiology:** Incidence of osteoporosis increases with increasing age.

**Forms of primary osteoporosis:** Most common forms are type I (postmenopausal osteoporosis) and type II (senile osteoporosis).

### Causes of secondary osteoporosis

- **Endocrine causes:** Increased levels of parathyroid hormone (PTH) due to an adenoma, or hyperplasia of the parathyroid glands; diabetes mellitus; Addison disease.
- **Gastrointestinal cause:** Malnutrition.
- **Drug causes:** Steroids, heparin.

### Risk factors for primary osteoporosis

- Increasing age and family history.
- Smoking and alcoholism.
- Decreased estrogen; early or surgical menopause.
- Low body mass index, low calcium diet, and lack of weight-bearing exercise.

**Pathogenesis of primary osteoporosis**

- Decreased ability of cells to make bone, which occurs with senility of the bone.
- Decreased physical activity.
- Decreased estrogen, which results in increased level of interleukin-1 (IL-1) and IL-6. IL-1 and IL-6 increase the level of RANK and RANKL and decrease the level of osteoprotegerin.

**Microscopic morphology:** Thin cortex and thin trabeculae.

**Clinical presentation of osteoporosis:** Vertebral compression fractures with acute back pain and kyphosis; hip fracture. Most compression fractures are asymptomatic.

**Diagnosis of osteoporosis:** Bone density measurements (DEXA scan).

## OSTEONECROSIS

**Causes of osteonecrosis (avascular necrosis):** Fractures and trauma, corticosteroids, sickle cell anemia and other hematologic diseases, and idiopathic.

**Morphology of osteonecrosis**

- **Gross:** If subchondral in location, the area of tissue death is wedge shaped.
- **Microscopic:** Empty lacunae.

**Clinical presentation of osteonecrosis:** Most commonly affects the epiphysis of the femur. Osteonecrosis of the jaw has been associated recently with bisphosphonate use. Patients present with pain and, as the lesion evolves, joint collapse may occur.

## OSTEOMYELITIS

**Overview:** Osteomyelitis is infection of the bone. Two of the major forms of osteomyelitis are pyogenic and tuberculous.

### PYGENIC OSTEOMYELITIS

**Causative organisms:** *Staphylococcus aureus* causes 80–90% of cases. *S aureus* has a receptor for collagen, which contributes to its pathogenicity. Other organisms that cause osteomyelitis include:

- *Escherichia coli* and *Pseudomonas* in intravenous drug users and patients with urinary tract infections.
- *Haemophilus influenzae* and Group B *Streptococcus* in neonates.
- *Salmonella* in patients with sickle cell disease.

**Routes of infection:** Hematogenous, direct extension from infection in adjacent site, or traumatic implantation.

**Bones affected by osteomyelitis:** Long bones, vertebral bodies.

### Location of infection within the bone

- **Neonates:** Metaphysis or epiphysis.
- **Child:** Metaphysis.
- **Adults:** Epiphysis.

**Gross morphology of pyogenic osteomyelitis:** The infection can lift the periosteum, which impairs blood flow and can lead to ischemia of the bone. In children, periosteal lifting can lead to abscess formation. The dead bone fragment is called a **sequestrum**. New bone growth around the sequestrum is called the **involucrum**. A **Brodie abscess** is a residual abscess surrounded by rim of new bone growth.

### Clinical presentation of pyogenic osteomyelitis

- **Signs and symptoms:** Malaise, fever, chills, pain, warmth, swelling, erythema; range of motion may be limited by pain.
- **Laboratory findings:** Leukocytosis with or without a left shift; elevated erythrocyte sedimentation rate. Reactive thrombocytosis may be seen; platelet count can be extremely high.
- **Radiographic findings:** Destruction of bone; can have radiolucent or radiodense areas in chronic osteomyelitis.
- **Diagnosis:** Blood cultures are positive in 50% of acute cases. An aspirate with culture is more sensitive and should be performed if possible. Plain radiographs are the first test in the evaluation of suspected osteomyelitis and may reveal soft tissue swelling, periosteal elevation, and subperiosteal resorption and erosion. MRI is the test of choice for evaluating suspected osteomyelitis in diabetic patients. In nondiabetic patients with normal radiographs, a bone scan is indicated to rule out osteomyelitis.

### Complications of pyogenic osteomyelitis

- Ruptured periosteum, leading to soft tissue abscess and fistula formation (e.g., draining sinuses to the skin) (Figure 19-1 A and B).
- Pathologic fractures.
- Squamous cell carcinoma in the fistulous tract; sarcomas.
- Suppurative arthritis, which is more common in children and less common in adults.
- Approximately 5–25% of cases of acute osteomyelitis progress to chronic osteomyelitis.

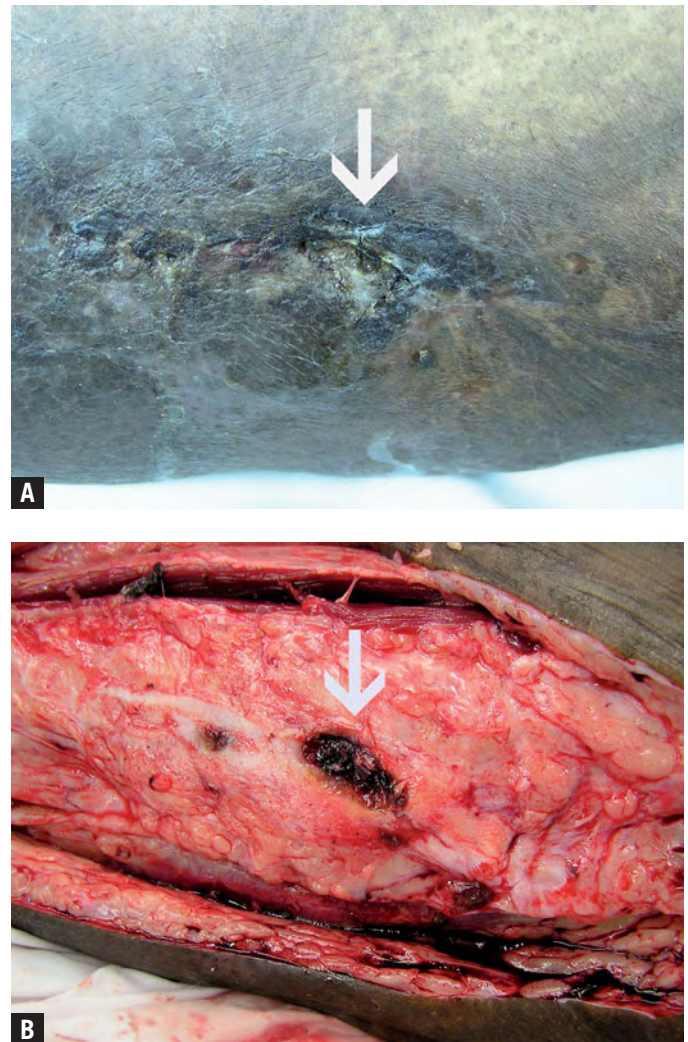
## TUBERCULOUS OSTEOMYELITIS

**Routes of infection:** Usually hematogenous.

**Bones affected:** Most commonly the spine (i.e., **Pott disease**), followed by knee and hip.

## PAGET DISEASE (OSTEITIS DEFORMANS)

**Overview:** Paget disease is a non-neoplastic disorder of bone characterized by disorganized growth of bony trabeculae, resulting in a thick, but fragile bone.



**Figure 19-1.** Osteomyelitis with draining fistula. **A**, The surface of the skin exhibits a draining fistula (arrow). The fistula developed due to underlying osteomyelitis. **B**, The arrow indicates the defect in the involucrum, through which the fistula connects with the overlying skin.



**Three phases of Paget disease:** Osteoclastic activity with hypervascularity; then mixed osteoclastic and osteoblastic stage; and finally, the osteosclerotic stage. The resultant bone is thick, but structurally weak.

**Epidemiology:** Prevalence in whites more than African Americans or Asians. Occurs in 1–10% of whites and commonly affects middle-aged adults.

**Cause of Paget disease:** Unknown, but may be viral. May be caused by paramyxovirus, which induces IL-6, which in turn stimulates osteoclasts.

**Bones affected:** Axillary skeleton (e.g., skull, ribs, vertebrae, pelvic bones) and proximal femur. The disease may be monostotic (15% of cases) or polyostotic (85% of cases).

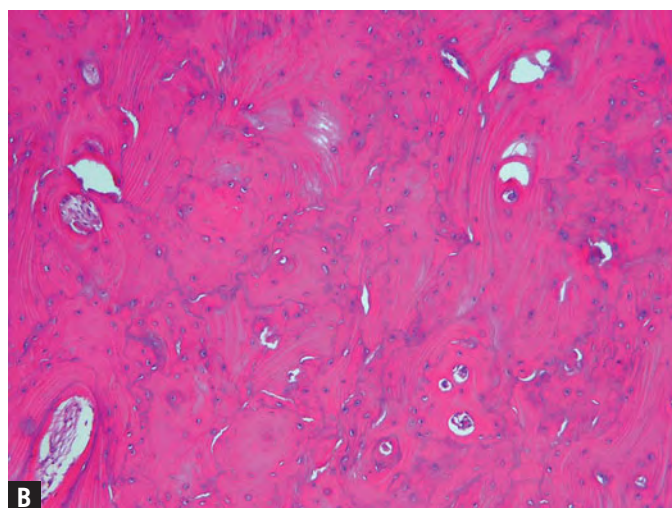
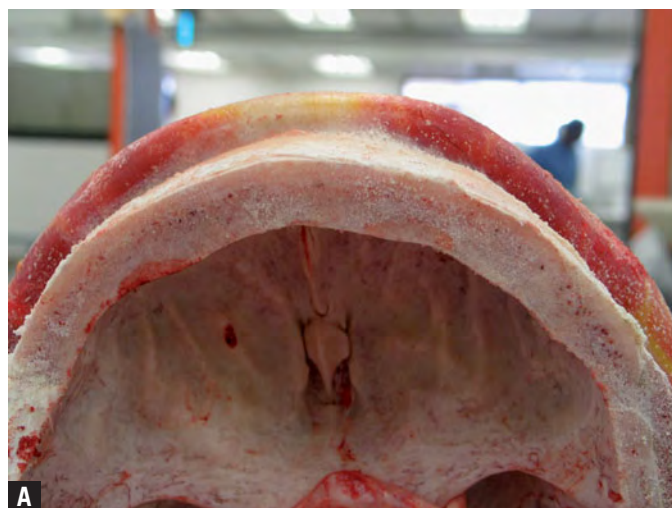
#### Clinical presentation and complications of Paget disease

- Most cases are diagnosed incidentally by radiography.
- The classic presentation is a patient who complains that his hat size is enlarging. Increased thickness of the skull can cause headaches.
- Pain caused by microfractures and bony overgrowth impinging the nerves. Patient may also have symptoms caused by impingement of the cranial nerves.
- Pathologic fractures, especially **chalkstick-type fractures**.
- High-output cardiac failure in initial hypervascular stage. The hypervascularity warms the skin and increases blood flow, functioning as an arteriovenous malformation.
- Sarcoma (1%), usually osteosarcoma or chondrosarcoma. Patients can also develop giant cell tumors.

#### Morphology of Paget disease (Figure 19-2 A and B)

- **Gross:** Thick bone.
- **Radiographic finding:** Thick, coarse cortex.
- **Microscopic:** Mosaic pattern of lamellar bone.

**Laboratory findings:** Elevated serum alkaline phosphatase and urinary excretion of hydroxyproline.



**Figure 19-2.** Paget disease of bone. **A**, The skull is markedly thick, and is a typical location for Paget disease. **B**, The bony trabeculae are thick and meshed together, creating the characteristic mosaic pattern of Paget disease and obliterating the marrow space. Hematoxylin and eosin, 200 $\times$ .

## RENAL OSTEODYSTROPHY

**Basic description:** Bony changes caused by renal disease.

**Pathogenesis:** Phosphate retention in renal failure leads to hypocalcemia and hyperparathyroidism. The inability of the failing kidneys to convert 25-OH-vitamin D to the active form, 1,25-OH-vitamin D, causes further stimulation of PTH secretion.

**Clinical presentation of renal osteodystrophy:** The presentation of renal osteodystrophy is essentially the same presentation as hyperparathyroidism (see Chapter 18). Bone pain and arthralgias are common and may be severe. Pathologic fractures are not uncommon. Spontaneous tendon rupture, which is classic for hyperparathyroidism, is less commonly seen in renal osteodystrophy. The characteristic radiographic finding is subperiosteal bone resorption, most easily demonstrated in the bones of the hands.

**Radiographic findings of renal osteodystrophy:** Two radiographic findings are classic for renal osteodystrophy and hyperparathyroidism: subperiosteal bone resorption (most easily demonstrated in the bones of the hands) and “rugger jersey spine,” in which the upper and lower portions of the vertebral body have a higher bone density than the middle portion.

## FRACTURES

### Types of fractures

- Complete (extends through bone causing total separation at the site of the fracture), or incomplete.
- Closed (i.e., intact overlying skin), or compound (i.e., lacerated overlying skin, exposing bone).
- Comminuted (i.e., bone broken into many smaller fragments at the site of fracture).
- Displaced fracture: Edges of bone at fracture site are no longer aligned.
- Pathologic fracture: Fracture occurring at the site of another form of pathology (e.g., at the site of a tumor metastasis) (Figure 19-3).
- Spiral fracture: Caused when torque is directed along the axis of the shaft of a bone. In children, spiral fractures are often an indication of physical abuse.

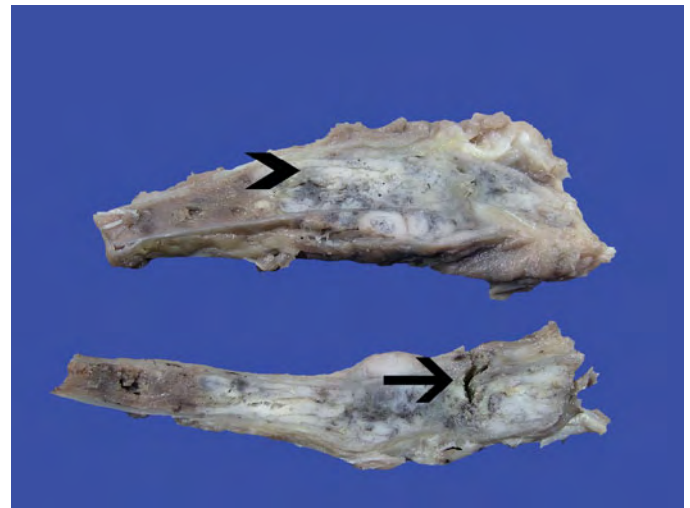
### Stages of repair

1. Formation of hematoma, which seals off fracture site and provides framework for repair.
2. Inflammatory cells release platelet-derived growth factor (PDGF), fibroblast growth factor (FGF), and other mediators, and activate osteoprogenitor cells.
3. Together, the hematoma and inflammatory cells (and the effects of their mediators) form a soft tissue callus.
4. Deposition of woven bone.

**Important point regarding fractures:** If the fracture is not immobilized, the callus can undergo cystic degeneration and a pseudoarthrosis is formed.

## BONE TUMORS

**Overview:** The most common tumor arising within bone is multiple myeloma (see Chapter 12). The most common tumor of bone is a metastasis. With bone tumors, age and location are very important factors in the diagnosis (Table 19-1). Of primary bone tumors, > 40% are hematopoietic (most commonly multiple myeloma), > 20% chondrogenic, > 20% osteogenic, and 10% are of unknown origin. Not including multiple myeloma and metastases, the three most common malignant tumors of bone are osteosarcoma, chondrosarcoma, and Ewing sarcoma. Benign bone tumors are 100-fold more common than malignant tumors.



**Figure 19-3.** Pathologic fracture due to metastatic small cell carcinoma. This cross-section of a rib shows a metastasis (*arrowhead*) and the associated fracture of the rib (*arrow*). A pathologic fracture is a fracture due to another underlying disease of the bone. Metastatic and primary tumors are not the only cause of pathologic fractures.

**TABLE 19-1.** Bone Neoplasms

Neoplasm	Age Range	Location	Important Point
Osteoid osteoma	10–30 years	Appendicular skeleton	Pain relieved with aspirin; < 2 cm in size
Osteoblastoma	10–30 years	Spine	Pain <i>not</i> relieved with aspirin; > 2 cm in size
Osteochondroma	Usually present in late adolescence and early adulthood	Metaphysis of tubular bones	Inactivation of <i>EXT</i> gene
Chondroma	20–50 years	Metaphysis of tubular bones	Associated with Ollier and Maffucci syndromes
Primary osteosarcoma	10–20 years	Metaphysis of distal femur, proximal tibia and humerus	65% have loss of heterozygosity or mutations of <i>RB</i> gene
Secondary osteosarcoma	> 40 years	Metaphysis of femur, humerus; pelvis	Arise due to Paget disease, osteomyelitis and other conditions
Chondrosarcoma	40–60 years	Shoulder, spine, pelvis, ribs	Can arise from osteochondroma
Giant cell tumor of bone	20–40 years	Epiphysis and metaphysis of long bones	Only 5% metastasize; neoplasm is locally aggressive
Ewing sarcoma and PNET	10–20 years	Diaphysis of femur, tibia; pelvis	t(11;22)

*RB*, retinoblastoma gene; PNET, primitive neuroectodermal tumor.

### Clinical presentation of bone tumors

- **Symptoms:** Pain, mass lesion, and pathologic fracture.
- **Prognosis:** The most important feature regarding prognosis is the histologic grade of the tumor. Younger patients are more likely to have benign tumors, and older patients are more likely to have malignant tumors.

## OSTEOMA

**Epidemiology:** Middle adulthood.

**Location:** If subperiosteal in location, skull and facial bones are often involved.

**Microscopic morphology:** Woven and lamellar bone. The differential diagnosis is reactive bone (e.g., around a fracture).

**Important point:** Multiple osteomas are a common extra-intestinal manifestation in the **Gardner syndrome** variant of familial adenomatous polyposis (FAP).

## OSTEOID OSTEOMA AND OSTEOLASTOMA

**Size:** Osteoid osteoma is < 2 cm and osteoblastoma is > 2 cm.

**Epidemiology:** Second and third decades of life.



**Location:** Osteoid osteoma particularly affects the appendicular skeleton (50% of osteoid osteomas are in the femur or tibia). Osteoblastoma particularly affects the spine.

#### Morphology of osteoid osteoma and osteoblastoma

- **Gross:** Osteoid osteoma has a central tumor nidus, surrounded by reactive bone.
- **Microscopic:** Both tumors have randomly interconnected trabeculae rimmed by osteoblasts.

**Clinical presentation:** Osteoid osteomas produce pain due to excess prostaglandin E2 synthesis, and the pain is therefore responsive to aspirin. Osteoblastomas produce a dull pain, which is unresponsive to aspirin.

### OSTEOSARCOMA

**Epidemiology:** If the osteosarcoma is primary, 10–20 years of age; if the osteosarcoma is secondary, which arises as a result of another disease process (e.g., Paget disease), patients tend to be older than 40 years of age. Osteosarcomas are more common in males than females, with a 2:1 ratio.

**Location:** If primary, metaphysis of the distal femur, proximal tibia, and humerus. If secondary, metaphysis of the femur, humerus, and pelvis.

**Mutations:** Loss of heterozygosity and point mutations in the *RB* gene (65% of tumors); mutations also in *p53*, *CDK4*, and *p16* genes.

**Predisposing factors for osteosarcoma:** Paget disease, bone infarcts, chronic osteomyelitis, radiation, and familial retinoblastoma.

#### Classification of osteosarcoma (based upon five categories)

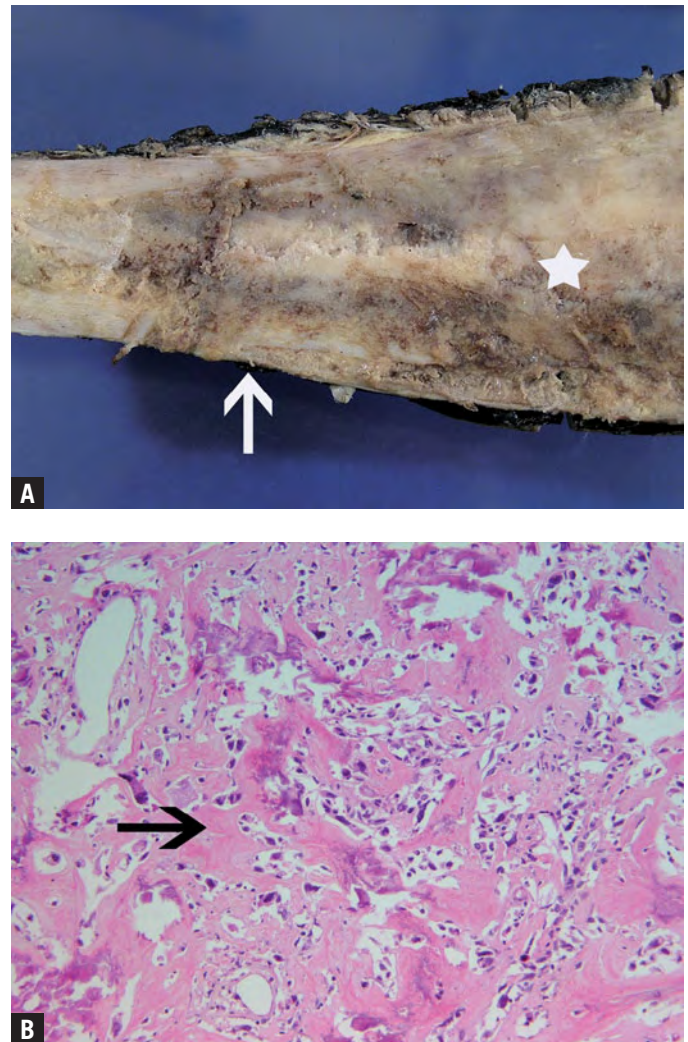
1. **Location in bone:** Intramedullary, intracortical, or surface.
2. Degree of differentiation.
3. **Multicentricity:** Synchronous or metachronous.
4. Primary or secondary tumor.
5. **Histology:** Osteoblastic, chondroblastic, fibroblastic, telangiectatic, small cell, and large cell.

**Most common type of osteosarcoma:** Primary, solitary, intramedullary, poorly differentiated, and osteoblastic osteosarcoma.

**Metastases of osteosarcoma:** Metastases to the lungs are classic; other sites include bone and brain.

#### Morphology of osteosarcoma (Figure 19-4 A and B)

- **Gross:** Gray-white mass, which has hemorrhage and necrosis.
- **Radiographic findings:** The classic radiographic sign of osteosarcoma is the **Codman triangle**, created when a rapidly growing tumor lifts the periosteum away from the bone. “Sunburst” or “hair on end” may be seen, and is caused by stretching of Sharpey fibers.
- **Microscopic:** Osteoblastic lesions with “lacy” osteoid (unmineralized bone) deposition.



**Figure 19-4.** Osteosarcoma. **A**, The expansive mass arising within this bone (*star*) is an osteosarcoma. The tumor has penetrated through the cortex of the bone, lifting the periosteum (*arrow*). **B**, Osteosarcomas may be osteoblastic, chondroblastic, or fibroblastic. However, all produce osteoid (*arrow*), which is present in a “lacy” distribution. Note the pleomorphism of the neoplastic cells. Hematoxylin and eosin, 200 $\times$ .

### OSTEOCHONDROMA (EXOSTOSIS)

**Epidemiology:** All ages are affected, but the tumor usually presents in late adolescence and in early adulthood. Prevalence of males to females is 5:1.

**Location:** Metaphysis near the growth plate of tubular bones; can be solitary or multiple.

**Mutation:** Inactivation of both *EXT* genes in sporadic and hereditary tumors.

#### Important points regarding osteochondroma

- Osteochondroma may be a malformation and not a neoplasm.
- Rarely result in development of sarcoma (< 1%).

**Morphology of osteochondroma:** Bony protuberance that communicates with bone marrow and has a cartilage cap (Figure 19-5).

### CHONDROMA

**Epidemiology:** 20–50 years of age.

**Location:** Metaphysis of tubular bones (e.g., hands and feet).

**Pathogenesis:** Represent rests of growth plate cartilage that later enlarge.

#### Related conditions

- **Ollier syndrome:** Multiple enchondromas.
- **Maffucci syndrome:** Multiple enchondromas and hemangiomas.

#### Morphology of chondroma

- **Microscopic:** Nodules of cartilage.
- **Radiographic finding:** Well-circumscribed, oval lucency surrounded by a thin rim of radiodense bone.
- **Important point:** Chondromas are called **enchondromas** if they are subperiosteal in location.

**Clinical presentation of chondroma:** Pain; pathologic fracture.

### CHONDROSARCOMA

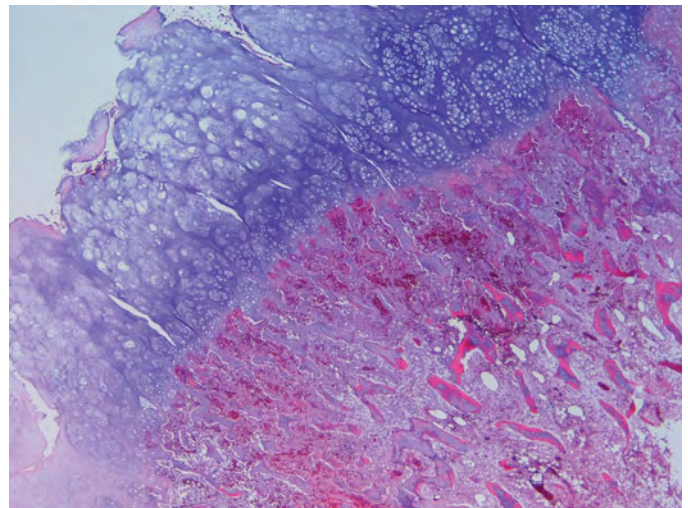
**Epidemiology:** 40–60 years of age; predominance of males to females is 2:1.

**Types of chondrosarcomas:** Conventional, clear cell, dedifferentiated, and mesenchymal.

**Location:** Shoulder (e.g., scapula and humerus), spine, pelvis, proximal femur, and ribs. Clear cell variant of chondrosarcoma occurs in the epiphysis of tubular long bones.

#### Classification of chondrosarcoma (based upon two categories)

1. **Location:** Intramedullary or juxtacortical.
2. **Histology**
  - **Conventional chondrosarcoma** (grades I to III): Varying from grade I (which has increased cellularity and sparse binucleate cells) to grade III (which has much increased cellularity and extreme pleomorphism).



**Figure 19-5.** Osteochondroma. A bony protuberance (right lower half of image) capped with cartilage (left upper half of image), an osteochondroma is a benign mass, possibly of developmental origin. The cartilage cap may undergo malignant degeneration, developing into a chondrosarcoma. Hematoxylin and eosin, 40×.



- **Clear cell chondrosarcoma:** Clear cytoplasm, giant cells.
- **Dedifferentiated chondrosarcoma:** Conventional low-grade chondrosarcoma plus component of high-grade sarcoma (e.g., malignant fibrous histiocytoma, fibrosarcoma, or osteosarcoma).
- **Mesenchymal chondrosarcoma:** Well-differentiated hyaline cartilage plus small round cells.

#### Morphology of conventional chondrosarcoma

- **Gross:** Arise in medullary cavity and erode bone.
- **Microscopic:** Cartilage; multinucleated chondrocytes (Figure 19-6 A and B).

### FIBROUS CORTICAL DEFECT

**Epidemiology:** Older than 2 years of age.

**Locations:** Metaphysis of distal femur or proximal tibia.

#### Morphology of fibrous cortical defect

- **Radiographic finding:** Well-defined radiolucency with a rim of sclerosis.
- **Microscopic:** Fibroblasts and histiocytes.

**Important point:** If size is > 5–6 cm, referred to as **nonossifying fibroma**.

### FIBROUS DYSPLASIA

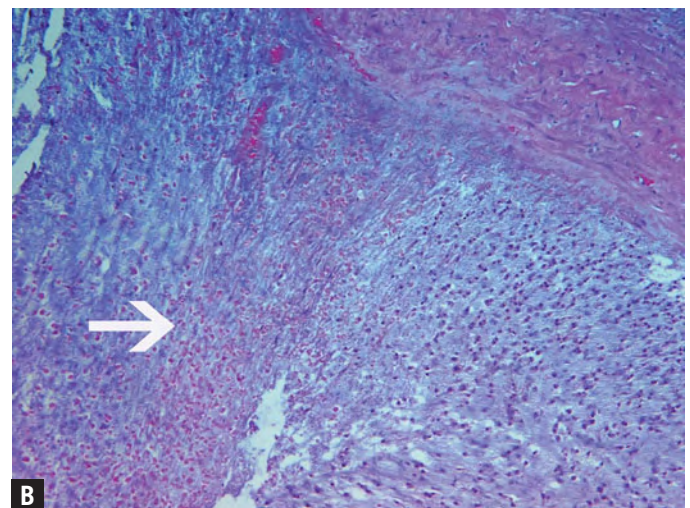
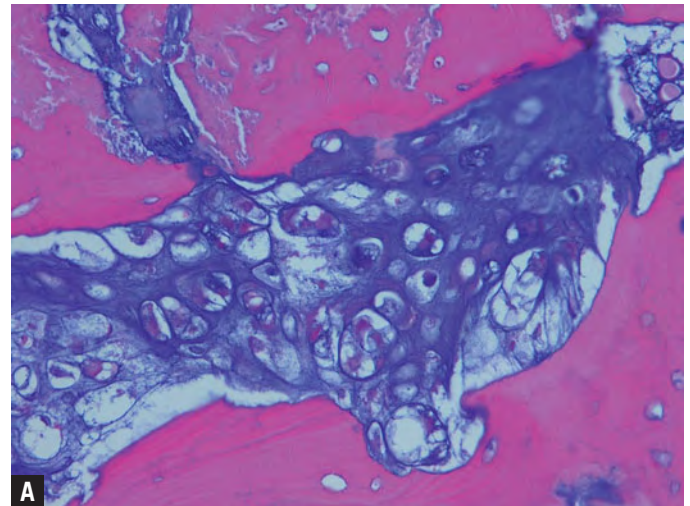
**Overview:** Fibrous dysplasia is not a neoplastic process, but instead is a development disorder that produces mass lesions within the skeletal system.

#### Types of fibrous dysplasia

1. **Monostotic (70% of cases); location:** Ribs, femur, and tibia.
2. **Polyostotic (27% of cases)**
  - **Epidemiology:** Occur in adolescents.
  - **Location:** Femur, skull, and tibia.
3. **Polyostotic with café au lait spots (McCune-Albright syndrome).**
  - **Mutation:** Gene for G protein, leading to activation and excessive production of cyclic adenosine monophosphate (cAMP).
  - **Other features:** Endocrine dysfunction (e.g., precocious puberty, hyperthyroidism).

#### Morphology of fibrous dysplasia

- **Gross:** Fibrous dysplasia is a tan-white, well-circumscribed, expansive lesion, which has an intramedullary location.
- **Microscopic:** Curvilinear trabeculae of woven bone surrounded by a fibroblastic proliferation.



**Figure 19-6.** Chondrosarcoma. **A**, This chondrosarcoma is well differentiated. Note some of the chondrocyte lacunae have more than one nucleus, which is a feature of malignancy. **B**, This well-differentiated chondrosarcoma has outgrown its blood supply and become focally necrotic (arrow). Hematoxylin and eosin, **A**, 400 $\times$ ; **B**, 200 $\times$ .



### GIANT CELL TUMOR OF THE BONE

**Epidemiology:** 20–40 years of age; prevalent in females. Most occur after closure of the epiphyseal plate.

**Location:** In adults, epiphysis or metaphysis of long bones (e.g., distal femur, proximal tibia, proximal humerus, and distal radius); metaphysis in adolescents.

**Important point:** Histologically benign, but can recur. Only about 5% metastasize, usually to the lung, and can be locally aggressive.

#### Morphology of giant cell tumor

- **Gross:** Red-brown mass; may have cystic degeneration.
- **Microscopic:** Composed of giant cells and mononuclear cells. The mononuclear cells are neoplastic, and the giant cells are reactive (Figure 19-7).

**Clinical presentation of giant cell tumor:** Arthritis; pathologic fractures.

### EWING SARCOMA AND PRIMITIVE NEUROECTODERMAL TUMOR (PNET)

**Basic description:** Ewing sarcomas are undifferentiated; PNETs have some neural differentiation. Ewing sarcomas and PNETs should be viewed as the same tumor.

**Epidemiology:** 10–20 years old.

**Location:** Diaphysis and metaphysis of femur, tibia, and pelvis.

**Important point:** Approximately 95% of Ewing sarcomas have translocation t(11;22) or t(21;22), which results in fusion of *EWS* (Ewing sarcoma gene) to *FLI* (chr 11) or *ERG* (chr 21). *FLI* and *ERG* are transcription factors.

#### Morphology of Ewing sarcoma

- **Gross:** Tan-white mass with hemorrhage and/or necrosis.
- **Radiographic findings:** Lytic tumor with permeative margins and extension into the surrounding soft tissue. Codman triangle may be present; however, the classic radiographic lesion of Ewing sarcoma is the “onion skin” periosteal reaction.
- **Microscopic (Figure 19-8):** Small round cell tumor; positive for CD 99; forms **Homer-Wright rosettes** (circle of neoplastic cells around a central fibrillary core).

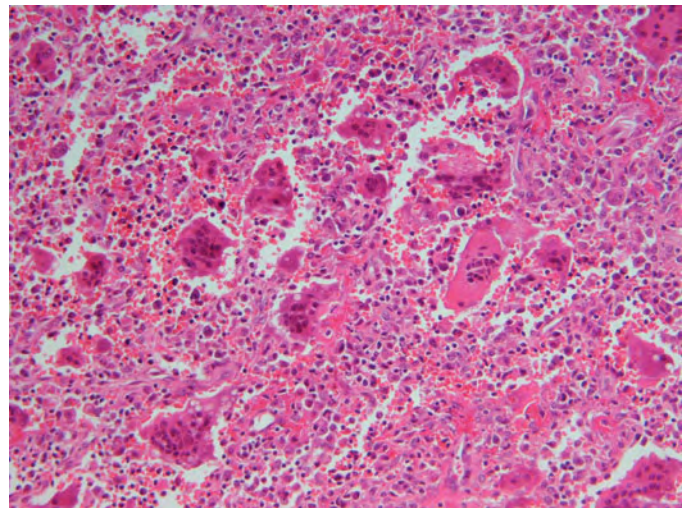
**Clinical presentation of Ewing sarcoma and PNET:** Pain, tenderness, warmth, swelling, and fever. The tumor can masquerade as an infection.

### METASTASES TO THE BONE

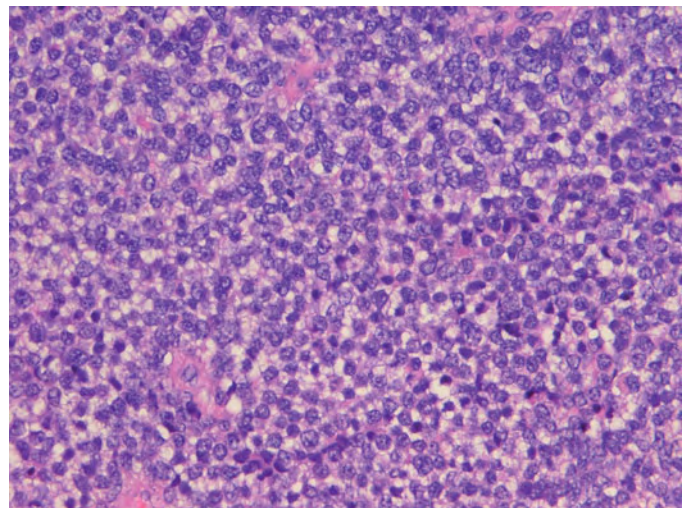
**Important point:** Overall, metastases are the most common tumor of bones.

#### Source of metastases

- **Adults:** Approximately 75% of metastases to the bone are derived from prostate, breast, kidney, and lung carcinomas.
- **Children:** Neuroblastoma, Wilms tumor, osteosarcoma, and Ewing sarcoma.



**Figure 19-7.** Giant cell tumor of bone. The photomicrograph depicts the two components of a giant cell tumor of bone, multinucleated giant cells, and mononuclear cells. The multinucleated giant cells are felt to be reactive in nature, and the mononuclear cells represent the neoplastic component of the tumor. Hematoxylin and eosin, 200×.



**Figure 19-8.** Ewing sarcoma. Ewing sarcoma is one of the “small round cell tumors” of childhood, as is evident by its histologic appearance. Immunohistochemical stains specific for CD99 help confirm its diagnosis. Hematoxylin and eosin, 200×.

**TABLE 19-2.** General Classification of Arthritis

Group	Descriptive Name of Group	Laboratory Findings	Common Cause
I	Noninflammatory arthritis	50–2000 WBC/mm <sup>3</sup> ; < 30% neutrophils	Osteoarthritis
II	Mildly inflammatory arthritis	0–9000 WBC/mm <sup>3</sup> ; < 20% neutrophils	Systemic lupus erythematosus
III	Severely inflammatory arthritis	100–160,000 WBC/mm <sup>3</sup> ; 70% neutrophils	Gout
IV	Purulent arthritis	150–250,000 WBC/mm <sup>3</sup> ; 90% neutrophils	Bacterial infections

WBC, white blood cells.

#### Important points regarding metastases to the bone

- Kidney and thyroid neoplasms are known for producing a solitary metastasis.
- Metastases to hand and foot bones are uncommon and, if present, the source is usually a lung, colon, or renal neoplasm.

## ARTHRITIS

**Overview:** In general, arthritis is inflammation of the joint. Analysis of synovial fluid can help determine the cause of the arthritis. Arthritis is divided into four groups, based upon the number of white blood cells in the fluid and the percentage that are neutrophils (Table 19-2). This section will discuss only reactive arthritis. Two of the major forms of reactive arthritis are osteoarthritis and rheumatoid arthritis, each of which will be discussed in separate sections. The final section of this chapter will cover other joint diseases.

## OSTEOARTHRITIS

**Overview:** Osteoarthritis, also referred to as **degenerative joint disease**, occurs as a result of degeneration of the articular cartilage, with a gradual onset of symptoms after 40 years of age.

**Pathogenesis of primary osteoarthritis:** Normal articular cartilage undergoes turnover; however, in osteoarthritis, this turnover does not occur. Osteoarthritis is due to wear and tear and other factors, including genetic factors. Osteoarthritis can also be secondary, as a result of trauma and other causes.

**Joints involved:** Weight bearing, including hips and knees; lower lumbar and cervical vertebrae; and proximal and distal interphalangeal joints.

### Morphology of osteoarthritis (Figure 19-9 A and B)

#### Gross

- **Eburnation:** Term for thickened and polished subchondral bone.
- **Subchondral cysts:** Synovial fluid leaks through defects in cartilage and into underlying bone.
- **Osteophytes:** Include bony excrescences at the distal interphalangeal joint (**Heberden nodes**) and the proximal interphalangeal joint (**Bouchard nodes**).
- **Joint mice:** Loose fragments of cartilage and/or bone in the joint cavity.

■ **Radiographic findings:** Joint space narrowing, subchondral sclerosis and cysts, and osteophyte formation.

■ **Microscopic:** Fibrillation of the cartilage (i.e., splitting of cartilage).

**Clinical presentation of osteoarthritis:** Aching pain, decreased mobility, mild and brief (< 30 minutes) morning stiffness; pain with movement and remission of pain with rest, joint crepitus, and “theater sign” (pain and knee joint locking when arising from a prolonged seated position). With progressive disease, pain occurs at night and with rest. Patients can have symptoms due to compression of nerves.

## RHEUMATOID ARTHRITIS

**Overview:** Rheumatoid arthritis is an autoimmune disorder with an unknown antigen–antibody combination. Patients with HLA-DRB1\*0401 and \*0404 alleles have increased incidence of disease. Rheumatoid arthritis occurs in 1% of the population. Most patients are 40–70 years of age. It is more common in females than males, with a ratio of 3:1.

**Joints affected:** Metacarpophalangeal and proximal interphalangeal joints, and feet, wrist, ankle, elbows, and knees.

### Morphology of rheumatoid arthritis

■ **Gross:** Edematous and thick synovium (**pannus**); surface is rough, with projections.

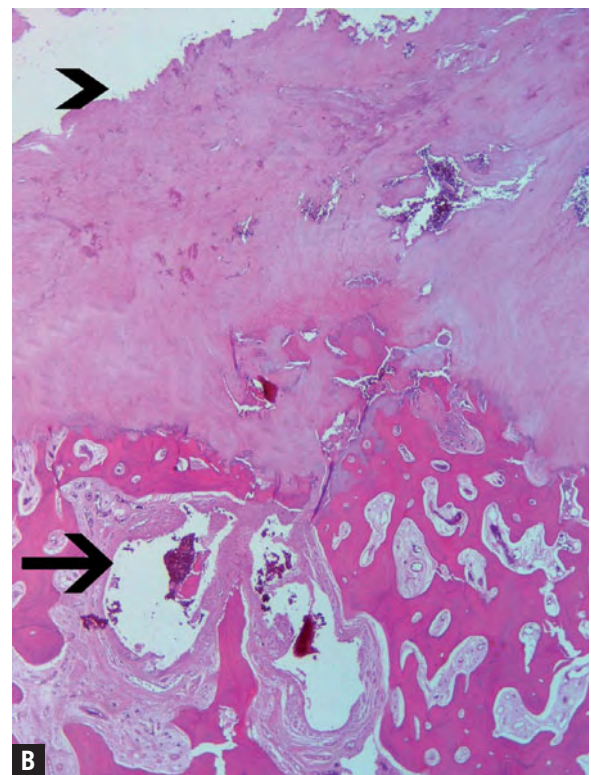
■ **Radiographic finding:** Osteopenia; bony erosion with narrowing of joint space.

■ **Microscopic:** Increased number of B cells and T cells, vesicles, fibrin, and neutrophils form the pannus. Rheumatoid nodule consists of central fibrinoid necrosis rimmed with histiocytes and lymphocytes; located in areas subject to pressure and can be in viscera.

### Clinical presentation of rheumatoid arthritis

■ **Symptoms:** Morning stiffness for > 1 hour, three or more affected joints, and arthritis of the hands with symmetric involvement of joints. Systemic signs such as weight loss, fatigue, and fever may be present.

■ **Signs:** Warm tender joints; radial deviation of wrist and ulnar deviation of phalanges; “**swan neck**” deformity, **Dupuytren contracture**, **boutonnière deformity**; and stiffness after inactivity.



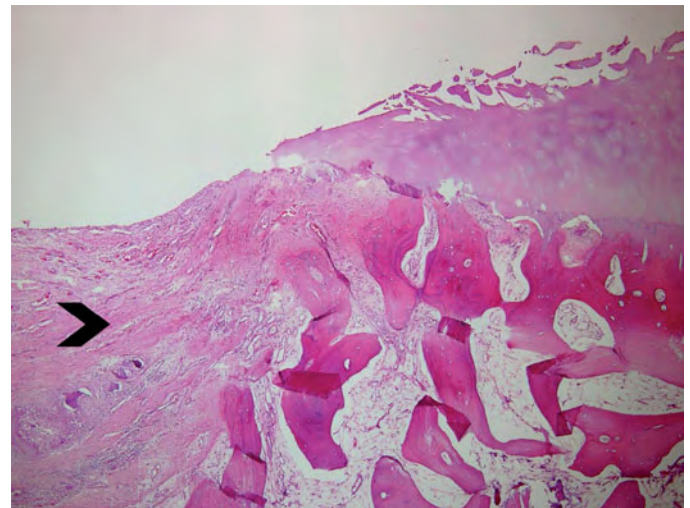
**Figure 19-9.** Osteoarthritis. **A**, Although osteoarthritis (i.e., degenerative joint disease) is not associated with ankylosis of the joint as is rheumatoid arthritis, it is possible for osteophytes to cross a joint and fuse (*arrow*), producing immobility of the joint. **B**, The histologic features of osteoarthritis include fibrillation and loss of basophilia of the cartilage (*arrowhead*) and subchondral cysts (*arrow*). Hematoxylin and eosin, 40×.



■ **Laboratory findings:** Rheumatoid factor (IgM versus Fc portion of IgG) is positive in 70–80% of patients.

**Complications of rheumatoid arthritis:** The pannus erodes cartilage and may bridge bones, causing ankylosis (Figure 19-10). Extra-articular manifestations are not unusual. The triad of rheumatoid arthritis, leukopenia, and splenomegaly is referred to as **Felty syndrome**. Pulmonary involvement may cause pleural effusions, interstitial fibrosis, or nodular disease (**Caplan syndrome**). Anemia of chronic disease is common.

**Differentiation of osteoarthritis versus rheumatoid arthritis (Table 19-3):** Osteoarthritis is degeneration of articular cartilage, and is often associated with wear and tear; therefore, symptoms will improve with rest. However, in rheumatoid arthritis, the disease is caused by the formation of a pannus, which causes fusion of the joint. Rest allows the fusion to progress and causes the joint to become stiffer; thus, conversely, use will keep the joint more mobile and decrease stiffness.



**Figure 19-10.** Rheumatoid arthritis. The inflammation associated with rheumatoid arthritis can lead to fibrosis (*arrowhead*) and fusion of the joint (ankylosis). Hematoxylin and eosin, 40 $\times$ .

## OTHER DISEASES OF THE JOINTS

### ANKYLOSING SPONDYLITIS

**Basic description:** *HLA-B27*-associated seronegative spondyloarthropathy related to **Reiter syndrome** and psoriatic arthritis, and characterized by inflammation of axial joints (e.g., spine and sacroiliac joints).

**Epidemiology:** Second and third decades of life; prevalence in males more than females, with ratio of 3:1.

**Important point:** Approximately 90% of patients have *HLA-B27*.

**Clinical presentation of ankylosing spondylitis:** Gradual onset of back pain, loss of mobility, and tenderness on palpation of the sacroiliac joints. Sacroiliitis with “pseudo-widening” and eventual fusion of sacroiliac joints, and prominent involvement of spine with squaring and fusion of the vertebrae (“bamboo spine”). Erythrocyte sedimentation rate is elevated.

### GOUT

**Basic description:** Arthritis due to deposition of uric acid crystals.

**TABLE 19-3.** Comparison and Contrast of Osteoarthritis and Rheumatoid Arthritis

Feature	Osteoarthritis	Rheumatoid arthritis
Joints affected	Weight-bearing (hips, knees); PIP, DIP	MCP, PIP, feet, wrists, ankles, elbow, knees
Morning stiffness	< 30 minutes	> 1 hour
Symptoms	Pain occurs with movement and is better after rest	Stiffness and pain are worst after inactivity
Physical examination	Heberden and Bouchard nodes	Rheumatoid nodules; radial deviation of wrist and ulnar deviation of phalanges

PIP, proximal interphalangeal; DIP, distal interphalangeal; MCP, metacarpophalangeal.

### Types of gout

■ **Primary gout:** About 85–90% of total number of cases of gout. Results from an unknown enzyme deficiency that causes either increased production of uric acid or normal production of uric acid with decreased excretion. Most patients with primary gout have normal production with decreased excretion of uric acid.

■ **Secondary gout (causes)**

- Increased nucleic acid turnover (e.g., in leukemia).
- Chronic renal disease.

**Risk factors for gout:** Increasing age, alcohol use, obesity, thiazide diuretics (thiazide diuretics completely inhibit secretion of uric acid).

### Pathogenesis of gout

- Urate crystals are precipitated in the synovium; trauma leads to their release into the synovial fluid. The uric acid crystals are chemotactic for neutrophils, and they activate complement.
- Uric acid levels must be elevated for 20–30 years to cause gout.

### Forms of gout

- **Acute arthritis:** Occurs as a result of the neutrophilic infiltrate associated with uric acid crystals in the joint.
- **Chronic tophaceous arthritis:** Urates coat the surface of synovium and deposit within synovium, which causes hyperplasia of synovium.
- **Tophi:** Term for aggregates of urates rimmed with macrophages, lymphocytes, and giant cells (Figure 19-11). Tophi form in tendons and ligaments.
- **Gout nephropathy**
  - Formation of uric acid stones, which can precipitate pyelonephritis.
  - Deposition of uric acid crystals in interstitium.

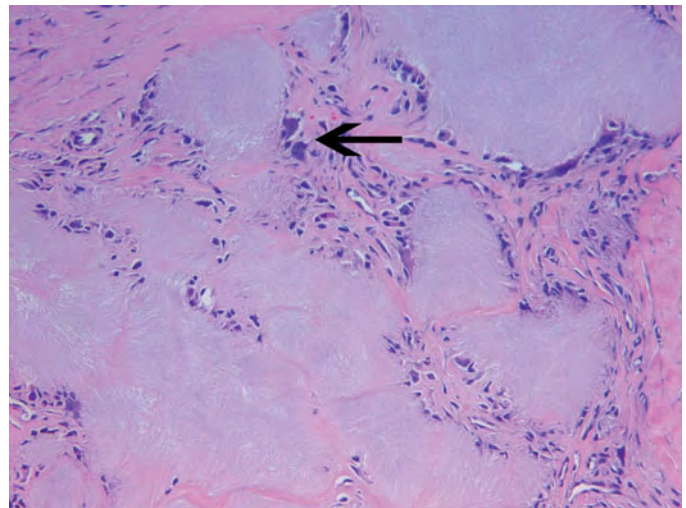
**Microscopic morphology:** Uric acid crystals are needle shaped and have strong negative birefringence when polarized.

### Clinical presentation of gout

- **Important point:** About 50% of the time, the first attack of gout occurs in the first metatarsophalangeal joint. The next joints involved are those in the instep, ankle, and heel.
- **Stages of gout in order of occurrence**
  - Asymptomatic hyperuricemia
  - Acute gouty arthritis
  - Asymptomatic period between acute attacks; then chronic tophaceous gout.
- **Diagnosis of gout:** Joint aspiration with identification of needle-shaped, **negatively birefringent** crystals in synovial fluid.

### Conditions associated with gout

- **Lesch-Nyhan syndrome:** Characterized by hyperuricemia, gout, mental retardation, and self-mutilation; caused by hypoxanthine guanine ribosyl-transferase deficiency (HGPRT).



**Figure 19-11.** Gouty tophus. Deposition of the uric acid crystals within the synovium elicits a giant cell reaction (arrow). Hematoxylin and eosin, 400×.

- **Saturnine gout:** Caused by lead poisoning, and is characterized by gout, renal failure, and microcytic anemia. It is classically associated with homemade whisky (“moonshine”) made from stills containing lead or old car radiators.

### **CALCIUM PYROPHOSPHATE CRYSTAL DEPOSITION (PSEUDOGOUT)**

**Epidemiology:** Older than 50 years of age; occurs in patients with degenerative joint disease.

**Microscopic morphology:** Rhomboid **positively birefringent** crystals examined under polarized light.

#### **Clinical presentation of pseudogout**

- Mimics osteoarthritis.
- Affects large joints, such as the knee.



*This page intentionally left blank*

# CHAPTER 20

## DERMATOPATHOLOGY

### OVERVIEW

Diseases of the skin vary from inflammatory disorders to highly malignant neoplasms. This chapter will discuss disorders of pigmentation, melanocytic proliferations (both benign and malignant), other pigmented lesions, non-melanocytic preneoplastic and neoplastic disorders, inherited skin neoplasia syndromes, acute and chronic inflammatory dermatoses, bullous diseases, other inflammatory skin diseases (including erythema nodosum), infectious disorders, and cutaneous manifestations of systemic disorders.

### DISORDERS OF PIGMENTATION

**Overview:** The three common disorders of pigmentation discussed below are vitiligo, freckles, and lentigo. These disorders represent predominantly cosmetic problems, but rarely may be mistaken for a premalignant lesion.

#### VITILIGO

##### Morphology

- **Gross:** Macules or patches of skin with loss of pigment.
- **Areas affected:** Hands, wrists, and perioral and anogenital regions.

**Pathogenesis of vitiligo:** Partial or complete loss of melanocytes, possibly of autoimmune etiology.

##### Important points

- Vitiligo versus albinism: **Albinism** is lack of melanin pigment due to genetic deficiency of tyrosinase.
- **Vitiligo** is associated with other autoimmune diseases, and is often seen in patients with Hashimoto thyroiditis, type 1 diabetes mellitus, or Addison disease.

#### FRECKLES

**Basic description:** Hyperpigmented lesions occurring as a result of an increased amount of melanin pigment.

**Important point:** A freckle darkens with sunlight.

## LENTIGO

**Basic description:** Hyperpigmented lesions occurring as a result of an increased number of melanocytes along the basement membrane.

**Important point:** A lentigo does not darken with sunlight.

## MELANOCYTIC PROLIFERATIONS

**Overview:** Melanocytic proliferations vary from the benign melanocytic nevus to the highly aggressive malignant melanoma.

### MELANOCYTIC NEVUS

**Basic description:** Benign proliferation of nevus cells, which are derived from melanocytes.

#### Types of melanocytic nevus

- **Junctional nevus:** Proliferation of nevus cells confined to the basal portion of the epidermis.
- **Compound nevus:** Proliferation of nevus cells at the basal portion of the epidermis and upper dermis.
- **Intradermal nevus:** Proliferation of nevus cells confined to the dermis (Figure 20-1).

**Microscopic morphology of melanocytic nevus:** Nests of uniform round cells with inconspicuous nucleoli and few if any mitotic figures. As cells get deeper into the dermis, they acquire more of a neural appearance as a result of maturation of the cells.

### DYSPLASTIC NEVUS

**Basic description:** Proliferation of dysplastic nevus cells; dysplastic nevi are precursors of malignant melanoma.

#### Morphology of dysplastic nevus

- **Gross:** Variable pigmentation; > 5 mm in size; irregular borders.
- **Microscopic:** Fusion and coalescence of nests of nevus cells in epidermis. Also, single nevus cells are present in basal portion of epidermis. The nevus cells have cytologic atypia.

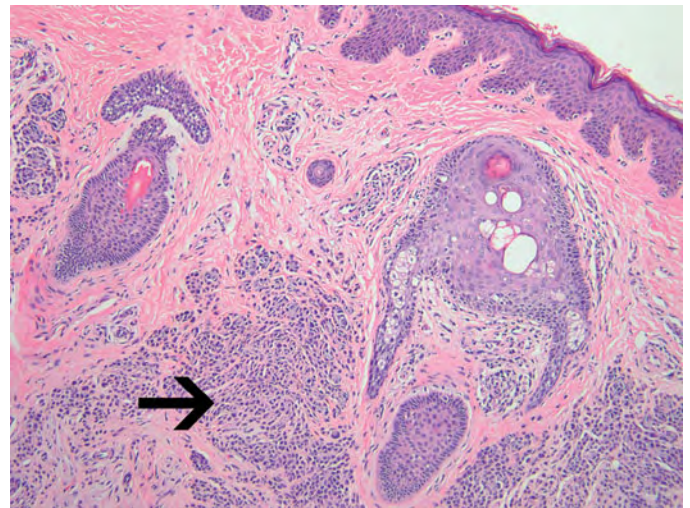
### MALIGNANT MELANOMA

**Basic description:** Malignant tumor of melanocytes.

#### Four types of malignant melanoma

- **Superficial spreading melanoma:** Has a radial growth pattern for a significant period of time.
- **Lentigo maligna melanoma:** Patients are older adults.
- **Nodular melanoma:** Has a vertical growth pattern early in its development.
- **Acral lentiginous melanoma:** Affects most commonly the nail bed, the sole of the foot, or the palms in African Americans.

**Pathogenesis:** Melanomas are caused by ultraviolet radiation that damages the DNA of melanocytes. Mutations in *CDKN2A*,



**Figure 20-1.** Intradermal nevus. Note the proliferation of nevus cells within the dermis only, surrounding the skin appendages. As the nevus cells penetrate deeper into the dermis, they acquire a more “neural” appearance (arrow). Hematoxylin and eosin, 100×.



which alter transcription and cell cycle control, are thought to play a prominent role in melanoma formation.

### Growth patterns of melanoma

- **Radial:** Grows horizontally; not associated with metastases.
- **Vertical:** Grows downward into the dermis; is associated with metastases.

**Risk factors for melanoma:** Sun exposure, especially in fair skinned individuals. Although melanomas do not often arise from nevi, a history of atypical nevi, giant nevi (> 20 cm), or a large number of nevi are risk factors for melanoma.

### Morphology of melanoma (Figure 20-2 A–C)

- **Gross:** > 10 mm in size, variable pigmentation (can be hypopigmented), irregular borders.
- **Microscopic:** Large cells with prominent nucleoli forming poorly defined nests; single cells are present. Neoplastic cells may or may not produce melanin.
- **Important point:** For staging of a melanoma, depth of penetration into the dermis is crucial. The greater the depth of penetration, the more likelihood of metastases.

### Clinical presentation of malignant melanoma

- **Warning signs of melanoma:** Increasing size of nevus; itching and/or pain; change in size, shape, or color of nevus; growth of new nevus; irregular borders.
- **Favorable prognostic factors:** Depth of invasion (**Breslow depth**) of < 1.7 mm; absence of mitotic figures.

**Important point:** S-100 and HMB-45 are commonly used tumor markers for melanoma.

## OTHER PIGMENTED LESIONS

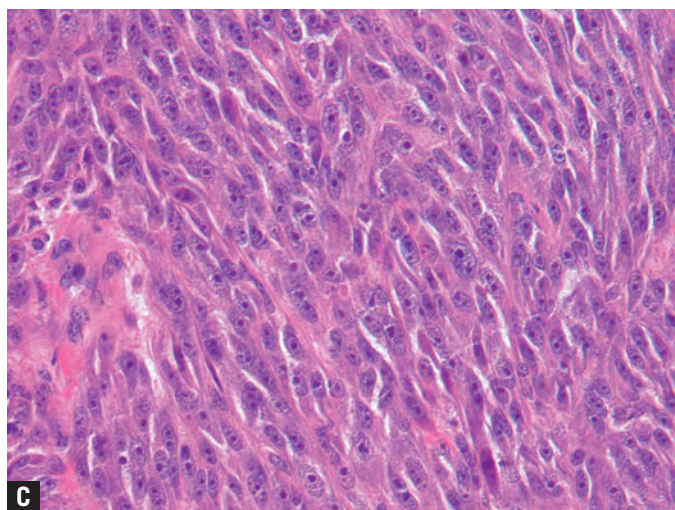
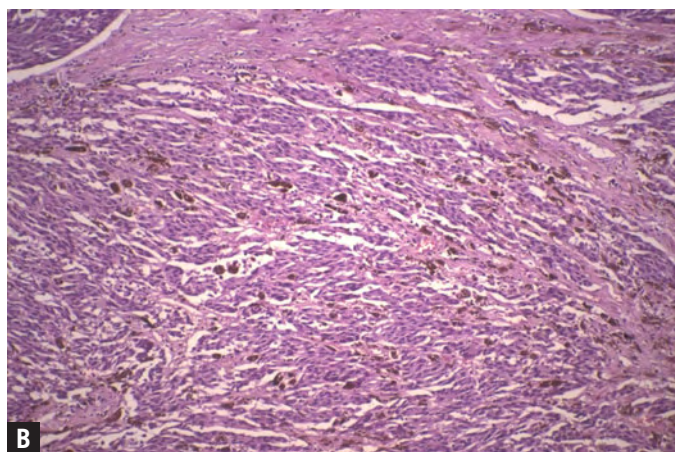
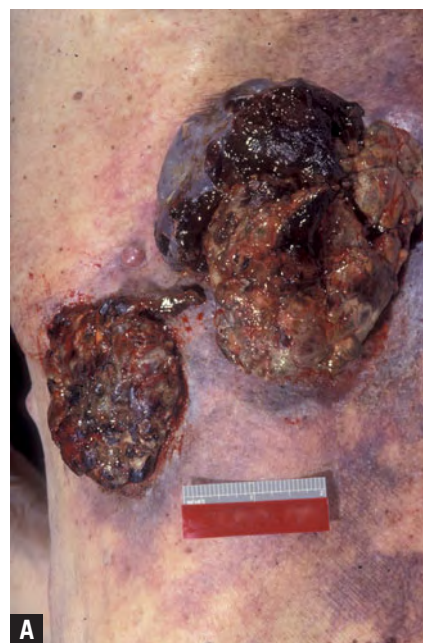### SEBORRHEIC KERATOSIS

#### Morphology (Figure 20-3 A and B)

- **Gross:** Tan to dark brown papule or nodule with a “stuck-on” appearance.
- **Microscopic:** Sheets of basal-like cells, hyperkeratosis, and keratin-filled cysts.

**Epidemiology:** Middle-aged and older adults.

**Sign of Leser-Trélat:** Sudden onset of multiple seborrheic keratoses, which is a cutaneous manifestation of internal malignancy (associated with adenocarcinoma of the gastrointestinal tract).



**Figure 20-2.** Malignant melanoma. **A**, This patient had two large, untreated and undiagnosed nodular malignant melanomas on her back. Malignant melanoma often produces pigment, which can be seen grossly as well as microscopically (**B**). However, not all malignant melanomas produce pigment, and this tumor must always be considered in the diagnosis of malignancies with large pleomorphic cells and prominent nucleoli (**C**). Hematoxylin and eosin, **B**, 200 $\times$ ; **C**, 400 $\times$ .

### ACANTHOSIS NIGRICANS

#### Morphology (Figure 20-4)

- **Gross and microscopic:** Hyperplastic (i.e., acanthosis) and hyperpigmented papules.
- **Areas affected:** Flexor regions, including the posterior neck, axilla, and groin.

#### Types of acanthosis nigricans

- **Benign:** Commonly associated with insulin resistance and obesity.
- **Malignant:** Can be a cutaneous manifestation of internal malignancy (associated with gastrointestinal adenocarcinoma).

### NON-MELANOCYTIC PRENEOPLASTIC AND NEOPLASTIC LESIONS

#### ACTINIC KERATOSIS

##### Morphology

- **Gross:** Rough, sandpaper-like lesion, which may have a keratin horn.
- **Microscopic:** Dysplasia of keratinocytes in basal portion of epidermis; can have parakeratosis.

**Risk factor:** Actinic keratoses are caused by exposure to ultraviolet light and exposure to sun.

**Important point:** Actinic keratosis is a precancerous lesion that has the potential to develop into squamous cell carcinoma.

**Mutations:** Commonly of *p53* gene.

#### CUTANEOUS SQUAMOUS CELL CARCINOMA

**Risk factors:** Sun exposure; older patients. Other risk factors include chronic ulcers, osteomyelitis, and burns (**Marjolin ulcer**).

**Incidence:** Second most common type of skin cancer (80–100,000 cases per year).

**Important point:** Cutaneous squamous cell carcinoma rarely metastasizes (only 5% of cases metastasize). Multiple squamous cell carcinomas may arise at the sites of arsenic exposure.

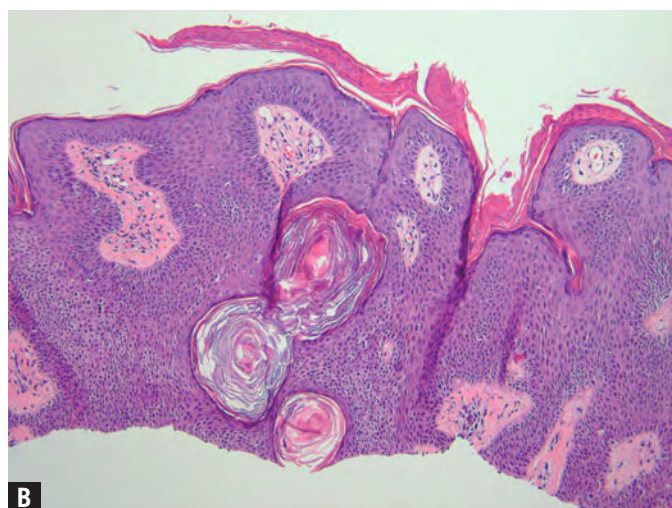
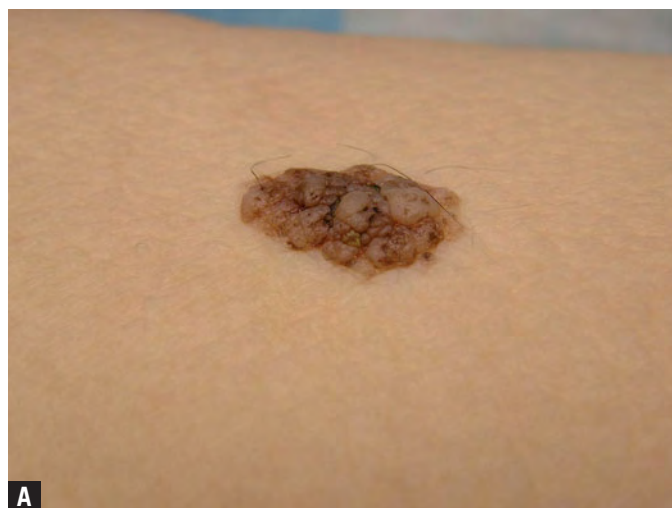#### Precursors of cutaneous squamous cell carcinoma

- Actinic keratosis
- Squamous cell carcinoma in situ: Full-thickness dysplasia of the epidermis. The only histologic difference between squamous cell carcinoma and squamous cell carcinoma in situ is that carcinoma in situ lacks features of invasion.

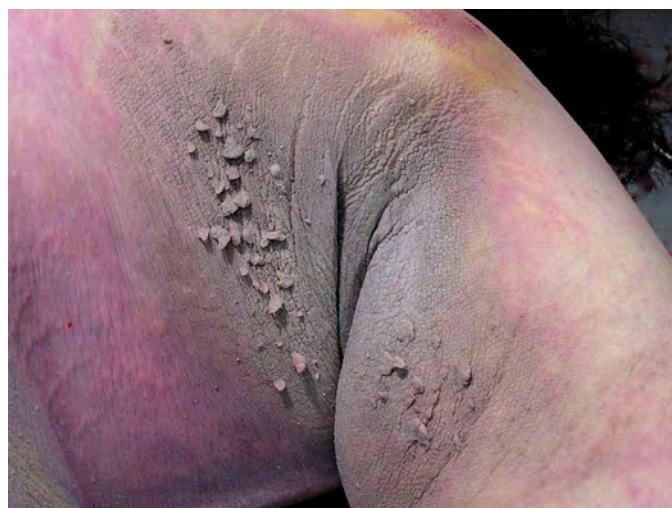**Mutations:** Loss of heterozygosity of chromosomes 3, 9, 17; *p53* mutations.

#### Morphology of cutaneous squamous cell carcinoma

- **Location:** Most commonly head, hands, and face.
- **Gross:** Painless nodule with possible evidence of keratin formation; may ulcerate.



**Figure 20-3.** Seborrheic keratosis. **A**, Seborrheic keratosis has a nodular, “stuck-on” gross appearance. **B**, Microscopically, the tumor is composed of basaloid cells associated with hyperkeratosis and keratin-filled cysts. Hematoxylin and eosin, 40×.



**Figure 20-4.** Acanthosis nigricans. The hyperplastic papules in the axilla of this patient are acanthosis nigricans. Acanthosis nigricans is found in obese persons, patients with diabetic mellitus, and in patients with a gastrointestinal neoplasm.



- **Microscopic:** Invasive squamous-appearing cells in dermis. Keratin pearls and intercellular bridges are evidence of squamous differentiation.

### BASAL CELL CARCINOMA

**Risk factors:** Sun exposure; older persons.

**Important points:** Locally invasive, but rarely metastasize. Most commonly develop on sun-exposed areas (e.g., nose, lip).

**Mutations:** *PTCH*, *p53*.

**Morphology of basal cell carcinoma:** Figure 20-5 A–C

- **Gross:** Pearly papule with dilated subepidermal blood vessels; can ulcerate; formerly called “rodent ulcers.”
- **Microscopic:** Nests of neoplastic cells resembling basal cells of the epidermis. The nests have peripheral palisading and separation clefts and are embedded in mucoid matrix.

## INHERITED SKIN NEOPLASIA SYNDROMES

### BASAL CELL NEVUS SYNDROME

**Inheritance pattern:** Autosomal dominant.

**Manifestations of basal cell nevus syndrome:** Disfiguring disorder characterized by multiple basal cell carcinomas before 20 years of age; associated with dental and maxillofacial abnormalities (e.g., cleft palate, keratocysts of the jaw). Pitting of the palms and soles is a classic finding.

**Mutation:** *PTCH* (“patched”) gene on chromosome 9q22.3. The protein product of the *PTCH* gene is the receptor for the protein produced by the sonic hedgehog gene. The mutation leads to uninhibited activation of *SMO* (“smoothened”).

### DYSPLASTIC NEVUS SYNDROME (FAMILIAL MELANOMA SYNDROME)

**Mutation:** *p16INK4a* on 9p21, which leads to unrestricted phosphorylation of RB and subsequent release of E2F.

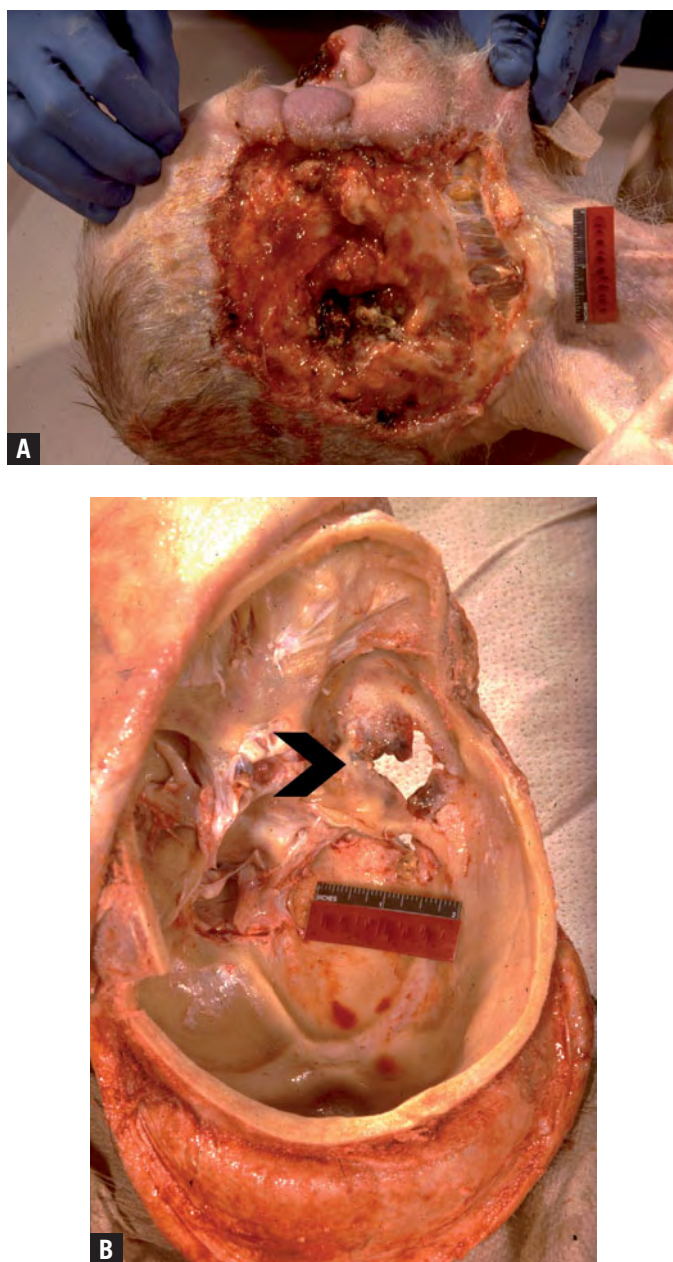
**Other mutations:** *CDK4*, *BRAF* (part of RAS/RAF/MAP kinase pathway).

**Inheritance:** Autosomal dominant with high penetrance.

**Clinical presentation:** Fair-skinned, fair-complexioned patient with multiple irregular nevi with variegated color. High risk for malignant melanoma and increased risk for pancreatic cancer.

## ACUTE INFLAMMATORY DERMATOSES

**Overview:** The acute inflammatory dermatoses are a group of inflammatory skin disorders with a general time course lasting days to weeks. Microscopically, the conditions have neutrophils, edema, and epidermal, vascular, or subcutaneous injury. The number of acute inflammatory dermatoses is large; however, only three common forms, urticaria, acute eczematous dermatitis, and erythema multiforme, are discussed here.



**Figure 20-5.** Basal cell carcinoma. Basal cell carcinoma is a slow-growing malignant neoplasm, which invades locally but almost never metastasizes. Often, patients will present for treatment many years after they first identified the neoplasm, some with incurable locally aggressive tumors. **A** and **B**, This patient has a large basal cell carcinoma on the right side of the head, which has invaded into and perforated the skull (arrowhead).



### URTICARIA (HIVES)

**Pathogenesis:** Mast cell degranulation with resultant increased vascular permeability.

**Epidemiology:** Occurs most commonly in patients 20–40 years of age.

#### Types of urticaria

- **IgE dependent:** A type I hypersensitivity reaction associated with pollens, drugs, and insect venom.
- **IgE independent:** Some substances (e.g., opiates, some antibiotics) can directly cause degranulation of mast cells.

#### Morphology of urticaria

- **Gross:** Pruritic, erythematous, edematous plaques (“wheals”).
- **Microscopic:** Perivascular edema.

### ACUTE ECZEMATOUS DERMATITIS

**Basic description:** A group of skin disorders characterized in the acute period by red oozing and crusting papules and vesicles, and in the chronic stage by raised plaques.

**Types:** Allergic contact dermatitis, atopic dermatitis, drug-related eczematous dermatitis, photoeczematous dermatitis, and primary irritant dermatitis.

**Pathogenesis of acute eczematous dermatitis:** Antigen taken up by the dendritic Langerhans cell is presented to the T cell. Upon reexposure to the antigen, the memory T cells release cytokines.

#### Morphology of acute eczematous dermatitis

- **Gross:** Red, papulovesicular rash with oozing and crusting lesions.
- **Microscopic**
  - **Early stages:** Edema progressing to spongiosis.
  - **Later stages:** Parakeratosis and hyperkeratosis.

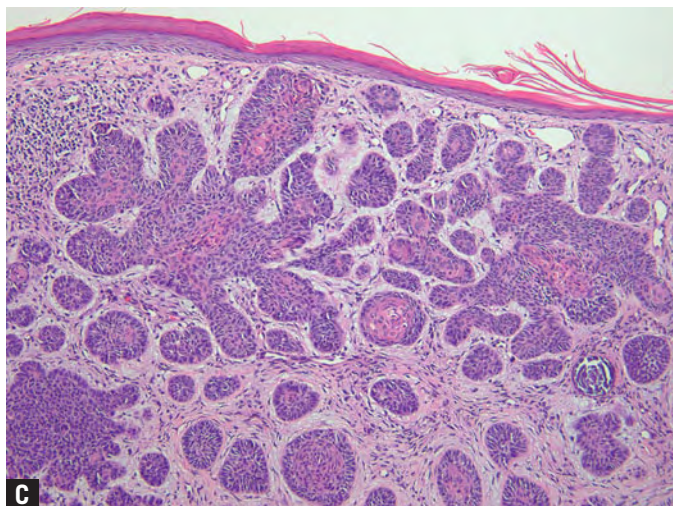
### ERYTHEMA MULTIFORME (FIGURE 20-6)

**Pathogenesis:** Due to hypersensitivity to infections (e.g., herpes simplex virus [HSV], mycoplasma) and to drugs (e.g., sulfonamides, penicillin, salicylates); also seen in patients with carcinomas and collagen vascular diseases. Approximately 90% of cases of erythema multiforme are associated with HSV infection.

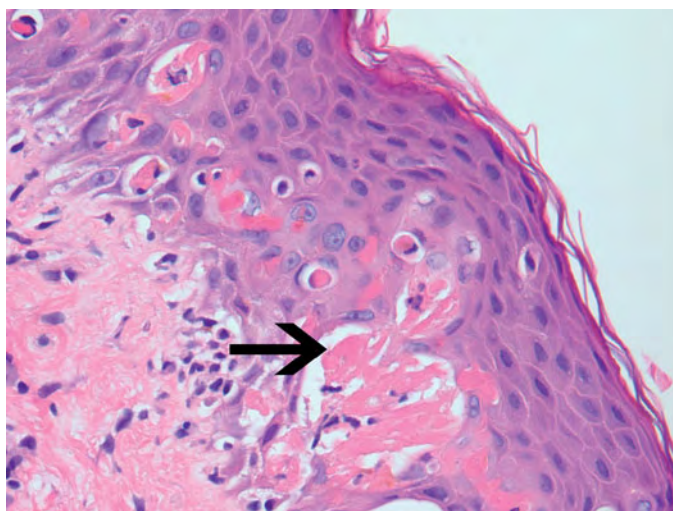
**Gross morphology of erythema multiforme:** Macules, papules, vesicles, and bullae; hence the term multiforme. The characteristic **target lesion** is a red macule or papule with a central pale center. The extremities are usually involved symmetrically.

#### Variants of erythema multiforme: Stevens-Johnson syndrome and toxic epidermal necrolysis

1. **Stevens-Johnson syndrome (i.e., erythema multiforme major):** An extensive form seen in children. Patients are febrile, and changes involve the lips and oral mucosa. Patients often develop a secondary infection leading to sepsis.



**Figure 20-5.** (Continued) **C**, Basal cell carcinoma is composed of nests of neoplastic cells, which resemble basal cells of the epidermis. The nests have peripheral palisading. Images **A** and **B** are provided courtesy of Dr. Sheila Spotswood, Dallas County Medical Examiner's Office, Dallas, TX. **C**, Hematoxylin and eosin, 100 $\times$ .



**Figure 20-6.** Erythema multiforme. There is a sparse infiltrate of lymphocytes at the dermal-epidermal junction. The arrow indicates a subepidermal vesicle. Hematoxylin and eosin, 400 $\times$ .

## 2. Toxic epidermal necrolysis

- **Basic description:** Diffuse sloughing and necrosis of cutaneous and mucosal epithelium.
- **Microscopic morphology:** Diffuse epidermal necrosis, leading to blister formation; also perivascular lymphocytes and dermal edema (Figure 20-7 A and B).

## CHRONIC INFLAMMATORY DERMATOSES

**Overview:** The chronic inflammatory dermatoses are a group of inflammatory skin disorders with a general time course lasting months to years. Microscopically, the conditions have epidermal changes (e.g., atrophy or hyperplasia) and dermal fibrosis. Although there are many conditions that fall under this category of skin disorders, only a few of the common forms (psoriasis and seborrheic dermatitis) will be discussed below.

### PSORIASIS

**Incidence:** 1–2% of the population in the United States is affected.

**Important points:** Two thirds of patients with psoriasis have HLA-Cw\*0602. Psoriasis rarely is pustular. The two forms of pustular psoriasis are benign and generalized.

- **Benign pustular psoriasis:** Involves the hands and feet.
- **Generalized pustular psoriasis:** Life threatening due to secondary infections and electrolyte abnormalities.

**Morphology of psoriasis (Figure 20-8 A and B)**

- **Gross:** Red plaque covered with silvery-white scales. Removal of the scale causes petechial bleeding (**Auspitz sign**). Brown discoloration (“oil spots”) and pitting of nails is classic.
- **Areas affected:** Elbows, knees, scalp, and lumbosacral region; may involve the nails.
- **Microscopic:** Acanthosis; elongated dermal papillae with thinning of overlying epidermis and parakeratosis; neutrophils clustered in parakeratosis (i.e., **Munro microabscesses**).

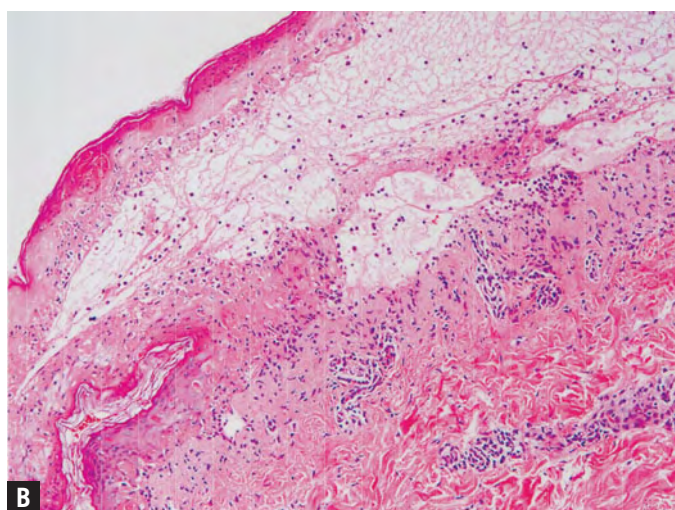
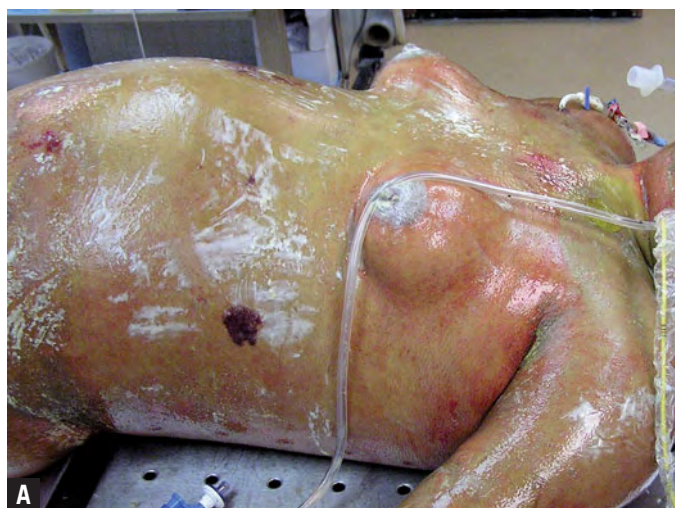**Associated condition:** **Psoriatic arthritis** is one of the seronegative spondyloarthropathies related to Reiter disease and ankylosing spondylitis. It occurs in 5% of patients with psoriasis. Patients are positive for *HLA-B27*. Psoriatic arthritis is characterized by psoriasis, arthritis, and spondylosis.

### SEBORRHEIC DERMATITIS

**Pathogenesis:** Unknown; some cases may be due to *Malassezia furfur*.

**Morphology of seborrheic dermatitis**

- **Gross:** Moist or “greasy” macules and papules on an erythematous base; has scaling and crusting.
- **Areas affected:** Areas with sebaceous glands such as the scalp, face, anterior chest, and intertriginous areas.



**Figure 20-7.** Toxic epidermal necrolysis. **A**, This patient had toxic epidermal necrolysis and underwent diffuse sloughing of the epidermis. The creamy white material represents therapeutic intervention. The loss of an extensive amount of epidermis predisposes the patient to electrolyte imbalances and infection. **B**, There is necrosis of the epidermis, with subepidermal blister formation. Hematoxylin and eosin, 100 $\times$ .



### Microscopic

- **Early stages:** Spongiosis.
- **Later stages:** Acanthosis.
- Can have parakeratosis, neutrophils, and serum near the hair follicles; lymphocytes and neutrophils are in a perivascular distribution.

**Important points:** Dandruff in adults and cradle cap in infants are forms of seborrheic dermatitis.

## BLISTERING (BULLOUS) DISEASES

**Overview:** The general microscopic morphology of the blistering skin diseases is acantholysis. This microscopic change results in bullae formation; the bullae involve the oral mucosa and skin. The three major blistering skin diseases are pemphigus, bullous pemphigoid, and dermatitis herpetiformis (Table 20-1).

### PEMPHIGUS

**Forms of pemphigus:** There are four forms of pemphigus: vulgaris, vegetans, foliaceus, and erythematosus.

#### 1. Pemphigus vulgaris

**Incidence:** About 80% of cases.

**Areas affected:** Lesions classically begin on the oral mucosa and later involve skin of the scalp, face, chest, axillae, and groin.

**Pathogenesis:** IgG to desmoglein 3 (an intercellular cement substance) produces a net-like pattern on immunofluorescence.

#### Morphology of pemphigus vulgaris

**Gross:** Flaccid bullae, which readily rupture leaving superficial erosions. **Nikolsky sign** is positive.

**Microscopic:** Suprabasal bullae with intercellular deposits of IgG and C3.

#### 2. Pemphigus vegetans

**Areas affected:** Groin, axillae, and flexural areas.

**Gross morphology:** Wart-like plaques.

#### 3. Pemphigus foliaceus

**Areas affected:** Scalp, face, and chest.

**Epidemiology:** Seen in South America.

#### Morphology

**Gross:** Superficial bullae.

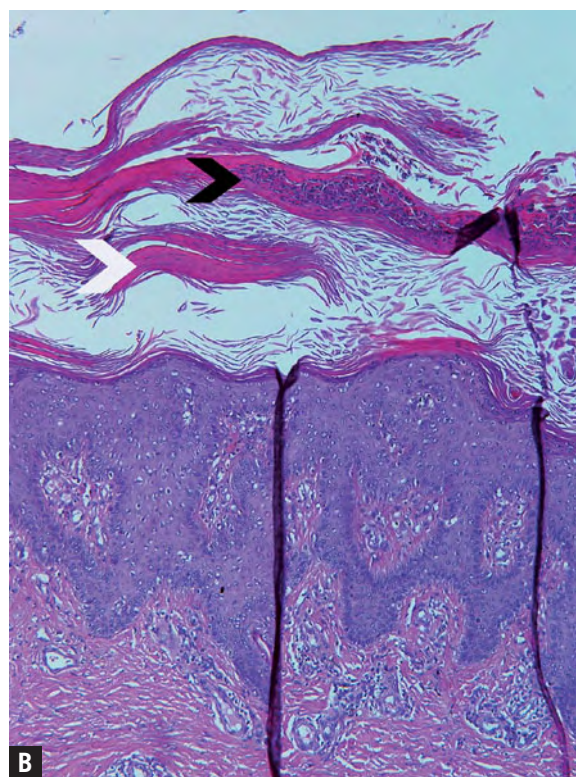
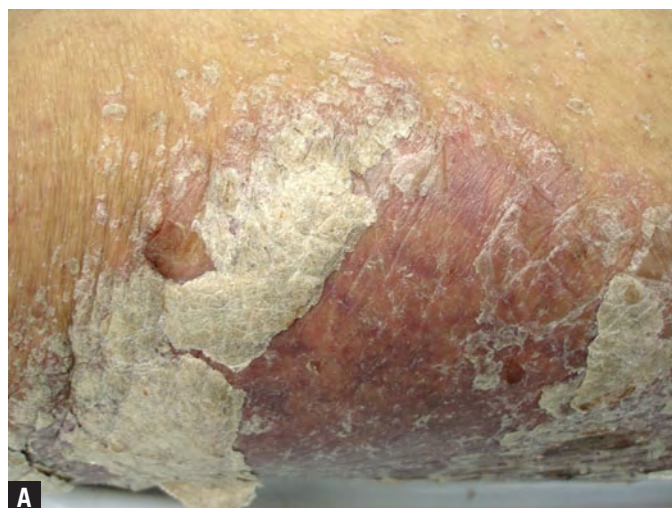**Microscopic:** Subcorneal bullae.

#### 4. Pemphigus erythematosus: Affects the malar area of the face.

### BULLOUS PEMPFIGOID

**Epidemiology:** Older patients.

**Pathogenesis:** Antibody against hemidesmosomes; produces linear pattern at the basement membrane on immunofluorescence.



**Figure 20-8.** Psoriasis. **A**, Note the red plaque covered with white scales. Commonly, the flexural regions (e.g., elbows, knees, lumbosacral region) are involved. **B**, Microscopically, there is acanthosis (thickening of the epidermis), parakeratosis (white arrowhead), Munro microabscesses (black arrowhead), and elongation of the dermal papillae. Hematoxylin and eosin, 100 $\times$ .



**TABLE 20-1.** Blistering Diseases of the Skin

Feature	Pemphigus Vulgaris	Bullous Pemphigoid	Dermatitis Herpetiformis
Areas involved	Oral mucosa (prominent), scalp, face and chest	Extremities, axillae and groin; oral mucosain 10–15%	Extensor surfaces; buttocks
Antibody target	Desmoglein 3	Hemidesmosomes	Gliadin and reticulin
Pattern on immunofluorescence	Net-like pattern	Linear pattern at basement membrane	IgA positive clusters at tips of dermal papillae
Nikolsky sign	Positive	Negative	

### Morphology of bullous pemphigoid

- **Gross:** Tense, up to 2.0-cm bullae. The bullae do not rupture as easily as those of pemphigus; thus the **Nikolsky sign** is negative.
- **Areas affected:** Inner thighs, flexor surface of forearms, axillae, and groin; can involve oral mucosa (10–15% of patients), but not as often as in pemphigus.
- **Microscopic:** Subepidermal nonacantholytic bullae; basal cell vacuolation; can have perivascular neutrophils, lymphocytes, and eosinophils.

### DERMATITIS HERPETIFORMIS

**Epidemiology:** Affects males more frequently than females; third and fourth decades of life.

**Pathogenesis:** Antibodies versus gliadin (is associated with celiac disease) and reticulin.

**Important point:** Responds to gliadin-free diet.

### Morphology of dermatitis herpetiformis

- **Gross:** Extremely pruritic plaques and vesicles.
- **Areas affected:** Bilateral and symmetrical; affects extensor surfaces and buttocks.
- **Microscopic:** In the early stages, clusters of neutrophils and fibrin at the tips of dermal papillae; by immunofluorescence, these clusters at the tips of dermal papillae stain positive for IgA; subepidermal blisters are formed.

### OTHER INFLAMMATORY SKIN DISEASES

**Overview:** As stated above, this chapter covers only a few of the inflammatory skin disorders. Two additional disorders that do not fall under the categories of acute or chronic inflammatory dermatoses or under blistering diseases are granuloma annulare and erythema nodosum, which are discussed briefly in this section.

### GRANULOMA ANNULARE

**Epidemiology:** Most cases are diagnosed in patients younger than age 30 years; more common in females.

**Morphology:** May be localized or disseminated, and most often affects the dorsal surfaces of feet and hands and extensor surfaces of legs and arms. Lesion begins as an annular ring of small, firm, flesh-colored or red papules. The ring expands outward with time, with involution and resolution of central involvement.

**Causes of granuloma annulare:** Associated with a variety of conditions, including tuberculosis, trauma, human immunodeficiency virus (HIV) and HSV infections, and insect bites.

### ERYTHEMA NODOSUM

**Basic description:** An acute form of panniculitis.

#### Morphology of erythema nodosum

- **Gross:** Poorly defined, tender, erythematous plaques. They are often felt but not seen. Over a few weeks, the plaques flatten and become bruise-like.
- **Microscopic**
  - **Early stages:** Edema, fibrin, and neutrophils in connective tissue septae.
  - **Later stages:** Lymphocytes, macrophages, and multinucleated giant cells in connective tissue septae.

**Important point:** Erythema nodosum arises in association with  $\beta$ -hemolytic streptococcal upper respiratory tract infections, tuberculosis, sulfonamide therapy, oral contraceptive use, and inflammatory bowel disease. Erythema nodosum is the most common cutaneous lesion associated with sarcoidosis.

### INFECTIOUS DISORDERS OF THE SKIN

**Overview:** There are many infectious disorders of the skin; however, only verrucae vulgaris and impetigo will be discussed here.

### VERRUCAE VULGARIS

**Epidemiology:** Occurs in children and adolescents.

**Pathogenesis:** Infection with the human papillomavirus.

**Microscopic morphology:** Epidermal hyperplasia with koilocytic changes.

### IMPETIGO

**Pathogenesis:** Infection with group A *Streptococcus* or *Staphylococcus aureus*; due to toxin that cleaves desmoglein 1.

#### Morphology of impetigo

- **Gross:** Erythematous macules forming pustules; associated with honey-colored crust.
- **Areas commonly affected:** Face and hands.
- **Microscopic:** Neutrophils in stratum corneum; can form pustules.

## CUTANEOUS MANIFESTATIONS OF SYSTEMIC DISEASE

**Overview:** Some systemic diseases produce lesions of the skin. Four disorders specifically associated with an underlying systemic disease are necrobiosis lipoidica, pyoderma gangrenosum, ecthyma gangrenosum, and porphyria cutanea tarda. All are discussed in this section.

### NECROBIOSIS LIPOIDICA

**Basic description:** Uncommon disorder associated with diabetes mellitus.

#### Morphology

- **Gross:** Oval-shaped, yellow-brown plaques on the anterior surfaces of the lower legs.
- **Microscopic:** Histiocytomas, PAS-positive areas of necrobiosis.

### PYODERMA GANGRENOSUM

**Basic description:** Seen in 5% of patients with ulcerative colitis.

**Morphology:** Progressive ulceration with well-defined margins. Classically, have purple base with surrounding red border.

**Clinical presentation:** Initially presents similar to cellulitis with erythema and pain. Patients do not respond to antibiotic therapy and are treated with steroid drugs.

### ECTHYMA GANGRENOSUM

**Basic description:** Cutaneous manifestation of sepsis, classically due to *Pseudomonas*.

**Morphology:** Pustules with central hemorrhagic bullae that develop into necrotic ulcers.

### PORPHYRIA CUTANEA TARDA

**Basic description:** Chronic blistering disease caused by deficiency of uroporphyrinogen decarboxylase. Most cases are acquired in association with liver disease due to alcohol use, viral hepatitis, or exposure to estrogen. Familial forms are less common.

**Morphology:** Blistering and erosions on sun-exposed areas, including the hands and face.



*This page intentionally left blank*



# CHAPTER 21

## PRACTICE EXAMINATION

### DIRECTIONS

Each numbered item or incomplete statement is followed by options. Select the best answer to each question. Some options may be partially correct, but there is only **ONE BEST** answer.

### PRACTICE EXAMINATION QUESTIONS

1. A 35-year-old marathon runner died in a motor vehicle accident while driving to work. At the time of the autopsy, which of the following features could be identified through gross and microscopic examination of the organs?
  - A. Atrophy of the skeletal muscle
  - B. Pathologic hyperplasia of the heart
  - C. Physiologic hypertrophy of the heart
  - D. Physiologic hyperplasia of the heart
2. A 72-year-old man suddenly developed weakness of his left leg, causing him to fall to the ground while shopping with his wife. An ambulance is called, and he is rushed to the hospital. He spends 4 days in the hospital, but the weakness in his left leg does not resolve. Which of the following is the most likely diagnosis?
  - A. Global hypoxic ischemic encephalopathy
  - B. Transient ischemic attack
  - C. Acute infarct in the distribution of the right middle cerebral artery
  - D. Acute infarct in the distribution of the right anterior cerebral artery

3. A 53-year-old man with a history of hypertension and diabetes mellitus routinely has chest pain after climbing five flights of stairs. When he rests, the chest pain subsides. He has had such chest pain for the past 5 months, and it has not changed in frequency. Which of the following is the most likely cause of his symptoms?
- Atherosclerotic plaque in the left anterior descending coronary artery causing 75% stenosis of the vessel's lumen
  - Atherosclerotic plaque in the left anterior descending coronary artery causing 45% stenosis of the vessel's lumen
  - Atherosclerotic plaque in the left anterior descending coronary artery that causes 75% stenosis and has a large cluster of intact red blood cells within its core
  - Ruptured atherosclerotic plaque in the left anterior descending coronary artery associated with a nearly occlusive thrombus
4. A 30-year-old man with a history of a cerebellar tumor that was resected when he was 20 years of age presents to his physician because of blood in his urine. He is concerned because his father's brother died early in life from complications of a metastatic tumor. He is evaluated with an ultrasound and found to have a mass in the left kidney. The kidney is removed, and the mass is diagnosed as a renal cell carcinoma. This patient most likely has a mutation at which of the following sites?
- 13q14
  - 5q21
  - 3p25
  - 17p13
5. A 29-year-old man falls 15' while rock climbing and strikes his head. After a brief period of unconsciousness, he awakens and states that his head hurts. Within 30 minutes, he is flown by helicopter to the nearest hospital. En route, he becomes unconscious and his right pupil becomes fixed and dilated. Shortly thereafter, he sustains a cardiac arrest, and resuscitative efforts fail. Which of the following best describes the most likely findings at autopsy?
- Fracture of the squamous portion of the right temporal bone
  - Fracture of the occipital bone
  - Torn bridging vein associated with a < 0.2-cm thick subdural hemorrhage
  - Diffuse subarachnoid hemorrhage
6. A 13-year-old white girl is brought to the emergency department by her parents, who relate her symptoms of fever, shortness of breath, and cough to the attending physician. A chest radiograph reveals complete consolidation of the lower lobe of the left lung. Cultures of the lower lobe of the left lung would most likely reveal which organism?
- Streptococcus pneumoniae*
  - Staphylococcus aureus*
  - Klebsiella pneumoniae*
  - Pseudomonas aeruginosa*
7. A 45-year-old homeless man who is hospitalized on a mental illness warrant is having difficulty with speech and walking. On physical examination, he appears confused and has nystagmus, bilateral lateral rectus palsies, and a broad-based ataxic gait. Most of his symptoms resolve over the course of hospitalization, but he has a permanent footdrop. What is the most likely diagnosis?
- Korsakoff psychosis
  - Wernicke encephalopathy
  - Herpes encephalitis
  - Bacterial meningitis
8. A 25-year-old man presents to his physician because of the recent unexpected death of his brother. His brother died suddenly while playing basketball. His autopsy report said the cause of death was an aortic dissection and also mentioned that he had a myxomatous mitral valve. The patient remembers that his brother was diagnosed with a heart murmur, and that he also has a murmur. He is concerned that he may die suddenly, similar to his brother's death. This patient is at most risk for which one of the following conditions?
- Subarachnoid hemorrhage due to a ruptured berry aneurysm
  - Intracerebral hemorrhage centered on the basal ganglia or thalamus
  - Dislocation of the lens of his right or left eye
  - Aortic stenosis due to degenerative calcification of a bicuspid aortic valve
9. A 38-year-old white woman presents to her physician because of complaints of a persistent headache. She also has noted multiple episodes of double vision in the past several months. She has not seen a physician before this point because of her fears that she has a brain tumor. Physical examination reveals weakness of the lateral rectus muscle of the left eye. A CT scan reveals no intracerebral mass; however, the cortex of the skull is focally thickened. Histologic examination of the bone would likely reveal
- neoplastic cells intermixed with lacy osteoid
  - granulomatous inflammation
  - hypercellular cartilage
  - mosaic pattern of the lamellar bone



10. A 31-year-old man presents to his family physician because of a palpable mass in his right testis identified upon self-examination. As a child, his right testis remained undescended until he was 3 years of age. Which of the following tests would be LEAST useful in presurgical assessment of the mass?
- A. Serum human chorionic gonadotropin (hCG)
  - B. Alkaline phosphatase
  - C. Ultrasound
  - D. Serum  $\alpha$ -fetoprotein (AFP)
11. A 51-year-old man who has diabetes mellitus and has a history of smoking two packs of cigarettes a day for 30 years presents to his family physician with complaints of pain in his legs when he walks. He describes the pain as an ache that it is relieved when he stops walking. Physical examination reveals the man to have a blood pressure of 151/93 mm Hg. Laboratory tests show a glucose level of 223 mg/dL and a normal CBC. What is the most likely diagnosis?
- A. Diabetic peripheral neuropathy
  - B. Peripheral vascular disease
  - C. Raynaud phenomenon
  - D. Diabetes-induced dermatomyositis
12. A 1-year-old girl with a history of several infections since birth, including pneumonia and otitis media, is evaluated for a defect in her immune system. The extensive laboratory testing reveals that her white blood cells are incapable of crossing the endothelium into the surrounding tissue. Further testing reveals the abnormality. She is most likely deficient in which of the following cellular mediators?
- A. LFA-1
  - B. ICAM-1
  - C. Sialyl-Lewis-X molecules
  - D. CD31
13. A 50-year-old man is in the hospital for treatment of an infected aortic graft, which was placed 4 years ago for treatment of an abdominal aortic aneurysm. During the night, he develops massive hematemesis. He has no history of gastric ulcers or cirrhosis. During resuscitation efforts, the physician attempts to place an endotracheal tube. At this time, the anesthesiologist sees a large amount of fluid blood exuding from the esophagus. Despite resuscitation and emergent exploratory surgery, the patient experiences heavy blood loss and dies. An autopsy is most likely to reveal which of the following conditions?
- A. Multiple acute gastric ulcers
  - B. Duodenal peptic ulcer
  - C. Aortoduodenal fistula
  - D. Abscess of the stomach wall with erosion into a vessel
14. A 52-year-old man presents to his family physician with complaints of fatigue. His physical examination and laboratory work-up reveal pancytopenia and splenomegaly. Flow cytometric analysis of his blood reveals cells with CD11c and CD103 positivity. The cells are positive for tartrate-resistant acid phosphatase. What is the most likely diagnosis?
- A. B-cell chronic lymphocytic leukemia
  - B. Hairy cell leukemia
  - C. Chronic myelogenous leukemia
  - D. T-cell chronic lymphocytic leukemia
15. A 15-year-old boy who is mentally retarded is noted by his family physician to have a long face and a large mandible. Physical examination reveals large testicles. Neither his father nor his grandfathers had mental retardation. Chromosomal analysis reveals more than 250 trinucleotide repeats on the X chromosome. What is the most likely composition of the trinucleotide repeats?
- A. CGG
  - B. CTG
  - C. CAG
  - D. CCG
16. A 3-day-old infant develops bilious vomiting, abdominal distention, and intestinal obstruction. Plain films of the abdomen reveal dilated air filled loops of small intestine without air fluid levels and the appearance of "soap bubbles" in the bowel. The colon is small on contrast enema, and there is obstruction of the terminal ileum. Which of the following is the most likely underlying cause of this disorder?
- A. Defect of cAMP-activated ion channel
  - B. Absence of ganglion cells in the large bowel
  - C. Benign hypertrophy of the pylorus
  - D.  $\beta$ -Glucosidase deficiency

17. A 9-year-old boy has puffy eyes and swollen extremities. He is brought by his parents to the hospital, where a urinalysis reveals proteinuria (4+) and no blood. Subsequent testing reveals a 24-hour urine with 10.5 grams of protein. What is the next best step in the treatment of this patient?
- A. Admit the child for close monitoring
  - B. Perform a kidney biopsy to diagnose his condition
  - C. Perform a kidney biopsy to confirm the diagnosis is minimal change disease
  - D. Treat the child with steroid therapy
18. A 17-year-old girl who is pregnant says that she usually smokes about 15 cigarettes a day. Despite being advised to abstain from smoking during her pregnancy, she has not been able to stop. During her third trimester, she suddenly develops abdominal pain and vaginal bleeding. Her boyfriend brings her to the emergency department, where she rapidly deteriorates into shock. An emergent cesarean section is performed. What is the most likely diagnosis?
- A. Placental abruption
  - B. Placenta previa
  - C. Premature rupture of the fetal membranes
  - D. An undiagnosed ectopic pregnancy
19. A 65-year-old woman who lives by herself on a very limited budget is brought to the emergency department by a neighbor. He states that he found her wandering outside unable to find her house, which was only two blocks away. He walked her there and upon entering the house he noticed a terrible smell, which turned out to be several large spots of liquid brown fecal material on the furniture in various states of drying. He also noticed there was very little food in the house. Upon examination, the emergency department physician notes several areas of inflammatory dermatitis. What is the most likely diagnosis?
- A. Deficiency of vitamin B<sub>1</sub>
  - B. Deficiency of vitamin B<sub>2</sub>
  - C. Deficiency of vitamin B<sub>3</sub>
  - D. Deficiency of vitamin B<sub>6</sub>
20. A 50-year-old man presents to the hospital after a brief episode of chest wall pain. An ECG and cardiac enzyme tests reveal no abnormalities. A routine chest radiograph reveals only a single 2-cm coin lesion in the right lower lobe of the lung with a "popcorn" pattern of calcifications. The man is scheduled for surgery, and the lesion is removed. The pathology report describes the mass as a disorganized nodule of cartilage, with no cellular features of malignancy. What is the general term for this lesion?
- A. Choristoma
  - B. Hamartoma
  - C. Adenoma
  - D. Sarcoma
21. A 55-year-old man presents to his family physician because of complaints of headaches and difficulty concentrating. He has also noticed an intermittent, slightly pink discoloration of his urine. A CBC reveals hemoglobin of 21.0 g/dL and normal white blood cell and platelet counts. Which of the following tests is most likely to detect the source of his symptoms?
- A. Bone marrow biopsy
  - B. CT scan of the head
  - C. Chest radiograph
  - D. CT scan of the abdomen and pelvis
22. A 37-year-old woman presents to her family physician with complaints of increased shortness of breath. She is tachypneic but is not cyanotic. Additional physical examination reveals a yellow discoloration of the conjunctivae. A chest radiograph shows bilateral hyperlucency of the lower lung fields, an elevated right hemidiaphragm, and an infiltrate in the right lower lobe. Despite appropriate medical treatment, she dies and an autopsy is performed. Upon examination of the lungs, which pathologic condition will most likely be identified?
- A. Centriacinar emphysema
  - B. Panacinar emphysema
  - C. Asthma
  - D. Bronchiectasis
23. A 24-year-old woman, who is in her 31<sup>st</sup> week of pregnancy, runs a red light and is struck on the side of her car. She sustains trauma to the abdomen, including premature separation of the placenta from the uterus. Because of her proximity to a hospital, she is able to undergo an emergent cesarean section. The infant has an initial Apgar score of 4, but with aggressive resuscitation, it survives. This infant will most likely develop which of the following complications?
- A. Meconium ileus
  - B. Asymmetric growth retardation
  - C. Pink acellular membranes lining the alveolar septae
  - D. Intracerebral hemorrhage centered in the basal ganglia
24. A pathology resident is reviewing the slides from a pediatric neoplasm with his attending. The tumor is composed of small round blue cells. Molecular testing of the tumor revealed a t(11;22). Immunohistochemical staining of the tumor cells is positive for CD99. These findings are most consistent with a tumor that originated
- A. in the vagina
  - B. in the diaphysis of the tibia
  - C. in the kidney
  - D. in a jaw mass

- 25.** A 42-year-old man with a history of hypertension and 50 pack years of tobacco use presents to the emergency department because of chest pain, which he describes as “tightness.” He also has nausea and some difficulty breathing. An ECG reveals ST depression. While being evaluated in the emergency department, the chest pain subsides approximately 18 minutes after it started. Cardiac enzyme tests completed at the time of admission to the emergency department and later at 3-hour and 6-hour intervals reveal normal levels of CK-MB and troponin I. What is the most likely diagnosis?
- A. Non-ST elevation myocardial infarct
  - B. Prinzmetal angina
  - C. Unstable angina
  - D. Stable angina
- 26.** A 60-year-old woman is brought to the emergency department by her family after they witnessed seizure activity at home. Laboratory testing in the emergency department reveals normal electrolyte and glucose levels and no evidence of toxic levels of a medication or drug. A CT scan reveals a mass in the left cerebral hemisphere. Prior to surgical biopsy of the mass, the patient’s left pupil becomes dilated. Which of the following has most likely occurred in this patient?
- A. Cerebellar tonsillar herniation
  - B. Overmedication with an opiate
  - C. Herniation of the left uncus
  - D. Herniation of the left cingulate gyrus
- 27.** A 26-year-old white man with no significant past medical history presents to the emergency department because of sudden onset of shortness of breath and chest pain. An arterial blood gas reveals that he is hypoxic. A ventilation-perfusion scan of the chest is consistent with a pulmonary thromboembolus. He has no identifiable risk factors for deep venous thrombi. This patient is most likely to have
- A. an antiphospholipid antibody
  - B. a mutation in the cleavage site for protein C
  - C. a mutation in the prothrombin gene
  - D. an undiagnosed pancreatic adenocarcinoma
- 28.** A 72-year-old man who works for a mine in Libby, Montana, has a clinical history of pulmonary function tests that show a decreased FEV<sub>1</sub> and FVC, with a normal FEV<sub>1</sub>/FVC ratio. He dies and an autopsy is performed. The autopsy reveals a tumor in the right pleural cavity, which completely encases the lung. He also has tan-white pleural plaques in the right pleural cavity. Upon histologic examination of the lung, prominent alveolar septal fibrosis with honeycomb change is identified. This patient was most likely exposed to which of the following agents?
- A. Cigarette smoke
  - B. Beryllium
  - C. Coal
  - D. Asbestos
- 29.** A 38-year-old woman presents to her physician with complaints of having no menstrual period for 7 months. A  $\beta$ -hCG is negative. Her prolactin level is markedly elevated, at 430 ng/mL (normal range 2–17 ng/L). Which of the following is most likely to be identified on a CT scan of the head?
- A. A 0.7-cm nodule in the adenohypophysis of the pituitary gland
  - B. An 8.0-cm nodule in the sella turcica, which compresses the infundibulum
  - C. A 5.0 cm nodule in the pituitary gland, which compresses the optic chiasm
  - D. A mass in the sella turcica, with a mammogram revealing a mass in the left breast
- 30.** A 48-year-old man is brought to the emergency department by his family because he has been acting disoriented and confused. A complete blood cell count reveals hemoglobin of 20 g/dL. A urinalysis indicates hematuria (2+). A CT scan of the abdomen reveals a mass in the right kidney. What is the most likely cause of his disorientation and confusion?
- A. Relative erythrocytosis
  - B. Polycythemia rubra vera
  - C. Secondary polycythemia
  - D. Pure red cell aplasia



31. A 32-year-old woman who weighs 125 kg (275 lb) is in the hospital for open reduction and internal fixation of a fractured ankle. She states that the only medication she is taking is an oral contraceptive. Four days after the surgery, she suddenly complains of chest pain and is noted to have difficulty breathing. Pulse oximetry reveals an arterial  $pO_2$  of 75%. She becomes unresponsive. During resuscitation, she is noted to have pulseless electrical activity. Despite aggressive efforts, she dies. An autopsy is most likely to reveal which of the following conditions?
- A. Saddle pulmonary thromboembolus occluding the bifurcation of the pulmonary trunk
  - B. Thromboembolus occluding the branch of the left pulmonary artery to the left upper lobe
  - C. Acute myocardial infarct of the anterior wall of the left ventricle
  - D. Fat vacuoles within the alveolar capillaries
32. A 24-year old man is involved in a motor vehicle collision and sustains a fracture of his left femur. While in the hospital, 2 days after the accident he is noted to be dyspneic and disoriented, and he develops petechiae on his trunk and axilla. What is the most likely diagnosis?
- A. Fat embolism
  - B. Pulmonary thromboembolus
  - C. Septic emboli
  - D. Air embolus
33. A 65-year-old man with diabetes mellitus is brought to the emergency department by Emergency Medical Services because of increased confusion and gangrene of the left leg. Upon evaluation in the emergency department, he is noted to have an increased heart rate, increased respiratory rate, and decreased blood pressure. A Foley catheter is placed; however, no urine can be obtained for culture. His skin is noted to be warm to the touch. Further evaluation is most likely to reveal which of the following?
- A. Elevated CK-MB and troponin I levels
  - B. Bilateral pulmonary infiltrates on radiograph of the chest
  - C. Elevated central venous pressures
  - D. Hypoglycemia
34. A 1-year-old boy with a history of several infections since birth, including pneumonia, is evaluated for a defect in his immune system. The extensive laboratory testing reveals that his white blood cells are unable to engulf material because of an inability to recognize opsonins coating the surface of the foreign substance. Further testing reveals the abnormality. This infant is most likely to be deficient in which of the following cellular constituents?
- A. CD31 on white blood cells
  - B. CR1 on white blood cells
  - C. Sialyl-Lewis-X molecules on white blood cells
  - D. ICAM-1 on white blood cells
35. A 25-year-old woman presents to her family physician for an annual check-up. She is noted to have a normal heart rate and respiratory rate and blood pressure of 164/91 mm Hg. Laboratory studies show hemoglobin of 12.3 g/dL and normal electrolytes. Physical examination reveals a bruit upon auscultation of the abdomen. Which of the following treatments is most appropriate for this patient?
- A. Prescription of a  $\beta$  blocker
  - B. Dietary supplementation with iron
  - C. Radiologic imaging of the renal arteries
  - D. Nothing at this time
36. A 39-year-old woman who smokes presents to her family physician because of weight gain. She has gained about 9 kg (20 lb) since her last visit 8 months ago. On physical examination, she has marked truncal obesity with abdominal stretch marks. Laboratory testing reveals elevated levels of cortisol and adrenocorticotrophic hormone (ACTH), and suppression of ACTH secretion with high-dose, but not low-dose, dexamethasone. What is the most likely cause of these laboratory results?
- A. Pituitary adenoma
  - B. Bilateral nodular adrenocortical hyperplasia
  - C. Functioning adrenal adenoma
  - D. Small cell lung cancer
37. A 23-year-old pregnant woman is seeing her obstetrician for a routine visit during her third trimester. Her only complaint is some swelling of her arms and legs. She reports no other difficulties with the pregnancy. She has not experienced any headaches, sweating, or vaginal bleeding. Her physical examination reveals a blood pressure of 157/93 mm Hg. Laboratory studies show hemoglobin of 12.6 g/dL. Urinalysis is negative for glucose, but does show an elevated level of protein. This patient is at most risk for
- A. a third trimester stillbirth
  - B. seizures
  - C. an intracerebral hemorrhage
  - D. placental abruption

- 38.** A 54-year-old woman presents to her family physician because of a left temporal headache and diminished vision in the left eye. Upon physical examination, the patient is febrile with tenderness over the left temple. A CT scan of the head does not reveal any abnormalities. Which of the following is the best next step in management of this patient?
- A. Obtain an erythrocyte sedimentation rate (ESR)
  - B. Make the diagnosis of a migraine headache and treat appropriately
  - C. Perform a biopsy of the temporal artery
  - D. Start the patient on a course of steroids
- 39.** A 52-year-old man has been seen several times in the past several months by his family physician for recurrent episodes of sinusitis. However, over the past few weeks, he has developed increasing shortness of breath with exertion, and in the past 24 hours, has had blood in his urine as well as experiencing nausea and vomiting. Physical examination reveals a blood pressure of 165/95 mm Hg (he was previously always normotensive), and a urine dipstick of proteinuria (2+). Which of the following is the most likely diagnosis?
- A. Goodpasture syndrome
  - B. Wegener granulomatosis
  - C. Membranous glomerulonephropathy
  - D. Undiagnosed diabetes mellitus
- 40.** A neonate is noted to have a holosystolic murmur on examination. An echocardiogram is performed, and the pulmonary valve is noted to have a normal structure, and the great vessels arise from the heart as they normally should. The boy is followed by his pediatrician until the age of 10 years, at which point the murmur has disappeared. What was the most likely diagnosis for the abnormalities noted upon examination of the heart?
- A. Ventricular septal defect
  - B. Atrial septal defect
  - C. Tetralogy of Fallot
  - D. Congenital bicuspid aortic valve
- 41.** A 62-year-old woman with diabetes mellitus and hypertension presents to her family physician because of complaints of difficulty breathing while walking 30 yards to her mailbox. She also reports that she requires four pillows to sleep at night. She states that if she doesn't stay propped up that she has difficulty breathing. Physical examination reveals bibasilar crackles, pitting edema of the lower extremities, and pressure in the right upper quadrant of the abdomen causing distension of the right internal jugular vein to 6 cm above the sternal angle. Which of the following is the most likely underlying cause of her symptoms?
- A. Severe pulmonary emphysema due to cigarette use
  - B. Chronic restrictive lung disease due to sarcoidosis
  - C. Chronic ischemic heart disease due to coronary artery atherosclerosis
  - D. Mitral regurgitation due to myxomatous mitral valve
- 42.** A 37-year-old woman with rheumatoid arthritis had what was clinically diagnosed as an adrenal crisis. She does not have increased perioral pigmentation. She dies, and an autopsy reveals atrophic adrenal glands. How might her death have possibly been prevented?
- A. Less rapid withdrawal of her steroid therapy
  - B. More rapid withdrawal of her steroid therapy
  - C. Replacement of her glucocorticoids with dexamethasone
  - D. Treatment of her Addison disease
- 43.** A 35-year-old homeless man presents to the public hospital with complaints of a non-healing wound of his right leg, which has gotten progressively more swollen and painful over the past several days. Physical examination reveals the patient to be febrile, and he has a non-healing laceration of the right leg, overlying the tibia, with bone visible in the depths. Laboratory testing reveals a white blood cell count of 21,000 cells/mm<sup>3</sup>. A radiograph reveals destruction of the underlying bony cortex. This patient is NOT at risk for which of the following?
- A. Development of a sarcoma
  - B. Pathologic fracture
  - C. Amyloidosis
  - D. Fatty emboli

44. A 15-year-old boy notices a swelling around his left knee, which has been progressive over the past few months. The swelling is associated with pain, which becomes unbearable. He is brought by his parents to the emergency department. Radiographic analysis of his left knee reveals an elevation of the periosteum and an infiltrative mass in the distal femur. What is the most likely diagnosis?
- A. Osteosarcoma
  - B. Ewing sarcoma
  - C. Chondrosarcoma
  - D. Metastatic colonic adenocarcinoma
45. A 64-year-old woman presents to her family physician because of pain in her hips. She has also noted a gradual decrease in her ability to walk and climb stairs over the past several months to a year or more. She relates that the pain is worse at the end of the day and sometimes keeps her up late into the evening. Which of the following best explains this patient's disease process?
- A. Physical examination may reveal Heberden or Bouchard nodes
  - B. The articular cartilage within her hip joints is rough, with evidence of pannus formation
  - C. She most likely had some form of accident as a young child that involved trauma to her hips
  - D. Laboratory testing will reveal IgM versus the Fc portion of IgG
46. A 42-year-old man presents to his family physician because of complaints of severe pain in the great toe of his left foot. Which of the following statements best explains this patient's condition?
- A. The condition is not related to his obesity or alcohol use
  - B. Most likely he has some underlying condition that is causing him to produce an excessive amount of uric acid
  - C. This disease process will never cause him to lose renal function
  - D. Histologic analysis of the synovium would reveal needle-shaped, strongly negatively birefringent crystals
47. A 46-year-old man is found by his wife unresponsive on the floor. She immediately calls 911. An interview with the wife by Emergency Medical Services reveals that her husband has complained of a headache for several months now, and that she has noticed some changes in his memory. However, despite her requests, he refused to see a physician. Physical examination reveals left-sided pupillary dilation. Which of the following might a CT scan of the head reveal?
- A. An infarct of the patient's right cerebral hemisphere in the distribution of the right middle cerebral artery
  - B. An infarct of the patient's left cerebral hemisphere in the distribution of the left anterior cerebral artery
  - C. An infarct of the patient's left cerebral hemisphere in the distribution of the left posterior cerebral artery
  - D. An infarct of the left olivary nucleus in the medulla
48. A 42-year-old woman presents to the hospital with complaints of nasal drainage and a stuffy nose. In the past day, she has also had a red discoloration of her urine. Upon physical examination, her blood pressure is noted to be 180/95 mm Hg, when normally it is 110/70 mm Hg. She is positive for c-ANCA. A biopsy of the kidney would most likely show which of the following?
- A. Crescentic glomerulonephritis
  - B. Membranous glomerulonephropathy
  - C. Hyperplastic arteriolosclerosis
  - D. An extensive infiltrate of neutrophils
49. A 35-year-old white woman presents to her physician with complaints of fatigue. She recently has noticed weight loss, which she attributes to feeling full sooner than usual when consuming a meal. She says that when she eats fatty foods, she often has pain on the right side of her abdomen, which gradually subsides. Her family history includes her mother and her mother's father who were diagnosed with some form of anemia. Which laboratory test, in addition to a peripheral blood smear, would help confirm the diagnosis?
- A. A karyotype, looking for a t(9;22)
  - B. An osmotic fragility test
  - C. A hemoglobin electrophoresis
  - D. A direct Coombs test
50. A 73-year-old woman sustains an infarct of her right parietal lobe due to an embolic occlusion of the right middle cerebral artery due to atherosclerosis of the internal carotid artery. She dies 1 year later, and an autopsy is performed. Examination of the brain will most likely reveal
- A. a 4.5 cm cavity in the right parietal lobe
  - B. an ill-defined softening of the right parietal lobe
  - C. a well-defined friable area in the right parietal lobe
  - D. a tiny (< 1.0 cm) cavity in the pons



51. A 3-year-old child is being evaluated by his physician during an office visit. Over the past 2 years, the child has had several bouts of otitis media and one severe case of pneumonia, which required hospitalization. At the time of the examination, the physician also notes that the child's skin is generally very white. The child's mother mentions that one of the child's grandmother's sisters died at a young age from recurrent infections. After further laboratory testing, the physician makes a diagnosis of
- chronic granulomatous disease
  - Chédiak-Higashi syndrome
  - severe combined immunodeficiency syndrome
  - hyper-IgM syndrome
52. A pathologist is viewing a slide of the cerebral cortex, which shows a large collection of foamy macrophages near the surface. Overlying this collection of macrophages, between the macrophages and the meninges, is a thin rim of cerebral parenchyma. No neurons are scattered among the macrophages. What is the pathologist looking at?
- A recent resolving contusion
  - An organizing infarct
  - An active plaque in a patient with multiple sclerosis
  - A resolving small intracerebral hemorrhage
53. A 38-year-old man presents with depression and has uncontrollable writhing movements of the extremities. His uncle died of a similar disease. What would confirm the diagnosis?
- Chromosomal analysis looking for CGG repeats in chromosome 4
  - Chromosomal analysis looking for CAG repeats in chromosome 4
  - Chromosomal analysis looking for CAG repeats in chromosome 8
  - Autopsy of the brain looking for spongiform changes
54. A 7-year-old child is brought to his pediatrician because his parents have noticed a mass in his abdomen. The child has a history of mental retardation, and required surgery on his bladder at a young age to correct a malformation. An ultrasound is performed, and reveals a 10.0 cm mass in the left kidney. Histologic examination of the renal mass following excision reveals three histologic patterns—epithelial cells, immature-appearing cells, and stroma. What is the most likely diagnosis?
- Denys-Drash syndrome
  - WAGR syndrome
  - Beckwith-Wiedemann syndrome
  - A sporadic Wilms tumor
55. An 8-year-old girl is brought by her parents to her pediatrician because of complaints of a headache and rash all over her body. Upon physical examination, her physician notes she has a diffuse petechial rash and also determines that the child has neck stiffness. The physician admits the young girl to the hospital and begins antibiotic treatment. Despite treatment, she dies and an autopsy is performed. The adrenal glands are noted to be markedly hemorrhagic and are described as bags of blood. What organism is causing her symptoms?
- Streptococcal pneumonia*
  - Group B streptococcus
  - Escherichia coli*
  - Neisseria meningitidis*
56. A 56-year-old obese man with a history of a recent ankle fracture, which has impaired his mobility, develops chest pain and difficulty breathing while walking to the bathroom. He is taken to the emergency department by Emergency Medical Services, where an ECG and cardiac enzyme testing are performed, both of which reveal no evidence of an acute myocardial infarct. He is admitted to the hospital for further testing. The next day, 24 hours after his initial pain, the patient has chest pain and dyspnea and then collapses. Despite resuscitation, he dies. An autopsy reveals a large saddle pulmonary thromboembolus and a pleural-based wedge of firm, red-tan parenchyma. Microscopic examination of this wedge-shaped area will reveal
- sheets of lipid-laden macrophages
  - intact alveolar septae with increased eosinophilia of the cytoplasm and loss of nuclear basophilia
  - giant cells surrounding granulomas with a central area of necrosis
  - neoplastic cells lining the alveolar septae, with focal areas of invasion into the pulmonary parenchyma
57. A 42-year-old patient presents to his family physician because of complaints of weight loss despite a good appetite. His other complaints are rapid heart rate and diarrhea. He is subsequently identified to have a thyroid-stimulating hormone-secreting pituitary adenoma. A transsphenoidal resection of the mass is performed. The pathologist evaluating the tumor must identify which of the following conditions to reliably diagnose the mass as malignant?
- A loss of the reticulin framework of the gland
  - Multiple mitotic figures
  - Nuclear and cytoplasmic pleomorphism
  - Evidence of invasion of surrounding tissue

58. A 26-year-old woman presents to the hospital with complaints of a rapid heart rate and palpitations. She has lost about 14 kg (30 lb) in the past 5 months despite having a good appetite. She complains of left lower abdominal pain. Laboratory evaluation reveals that her thyroid-stimulating hormone (TSH) level is barely detectable and her  $T_4$  level is elevated. No autoantibodies are detected in her serum. A brain MRI reveals no masses in the pituitary gland. An ultrasound of her thyroid gland is interpreted as normal. A CT scan of the abdomen and pelvis shows a 7-cm complex cystic mass of the left ovary, but is otherwise unremarkable. What is the most likely diagnosis?
- A. Graves disease
  - B. Toxic goiter
  - C. Struma ovarii
  - D. Ectopic production of TSH
59. A 10-year-old boy develops knee pain while playing soccer. A radiograph reveals a mass in the proximal portion of the tibia. A biopsy is performed, and the diagnosis of osteosarcoma is made. The patient had a brother who was diagnosed with an osteosarcoma and also a tumor of his eye. What is the normal role of the protein product of the gene involved with his tumor?
- A. Down-regulation of  $\beta$ -catenin
  - B. Binding of E2F
  - C. Arresting of cell cycle by transcription of p21
  - D. Arresting of cell cycle by transcription of p27
60. A 46-year-old man has a nodule in the left lobe of his thyroid gland. The nodule is surgically excised, and the diagnosis of a follicular carcinoma is made by the pathologist based upon histologic identification of invasion of the capsule. If a fine needle aspirate (FNA) had been performed prior to the surgery, the diagnosis would have been
- A. follicular carcinoma
  - B. follicular adenoma
  - C. follicular neoplasm
  - D. no thyroid nodules can be effectively diagnosed by FNA
61. A 54-year-old white woman falls at home and sustains an ankle fracture. During her subsequent hospitalization, she is found to have a white blood cell count of 50,000 cells/ $\mu$ L composed predominantly of lymphocytes. Flow cytometry reveals the cells to be positive for CD5. Which of the following is his most likely diagnosis?
- A. Chronic lymphocytic leukemia
  - B. Mantle cell lymphoma
  - C. T-cell acute lymphoblastic leukemia
  - D. Follicular lymphoma with leukemic phase
62. During an assault, a 15-year-old boy is struck on the head with a baseball bat, producing a large 6-inch laceration that requires 25 sutures. He returns to his physician in 3 weeks for removal of the sutures and in 6 months for a follow-up appointment to assess for any neurologic changes and other sequelae of the blow to his head. Evaluation of the scar at 6 months will reveal
- A. a barely visible line in the skin
  - B. a scar that is the same size as the original wound
  - C. a scar that has the strength of the original intact skin
  - D. an easily visible scar that is smaller than the original laceration
63. A 25-year-old woman with a history of phenylketonuria (PKU) has been on a less restrictive diet for a few years. However, she recently has been advised by her family physician to return to a phenylalanine-free diet for a period of 1 year or more. Which of the following best explains her advised change in diet?
- A. She is planning on becoming pregnant
  - B. She has developed cirrhosis of the liver
  - C. She has developed acute renal failure
  - D. She is planning on having elective weight-reduction surgery
64. A 42-year-old African-American man has been diagnosed with hypertension for the past 10 years and treated with medication. One morning, he is found unresponsive by his wife. He is taken to the emergency department and pronounced dead by the physician. An autopsy revealed cardiac hypertrophy and a narrowing of the aorta just distal to the ligamentum arteriosum, with dilation of the intercostal artery's ostia. How could the death have possibly been prevented?
- A. Better management of his hypertension with prescription medication
  - B. Early diagnosis of the cause of his hypertension by physical examination
  - C. Evaluation of the aortic valve with an echocardiogram
  - D. The death could not have been prevented
65. A 17-year-old girl develops an infection that is documented to be caused by *Neisseria gonorrhoeae*. Which of the following is she NOT at risk for in the future?
- A. An ectopic pregnancy
  - B. Tubo-ovarian adhesions and possible torsion and infarction of an ovary
  - C. Infertility
  - D. A surface epithelial serous cystadenocarcinoma

66. A 42-year-old woman with 12 lifetime sexual partners presents to her family physician because of vaginal bleeding. During her visit, a colposcopic examination is performed and a biopsy of an acetowhite lesion on her cervix is taken, which reveals invasive squamous cell carcinoma. Which of the following statements is FALSE?
- A. The lesion most likely resulted from infection with human papillomavirus (HPV) type 11
  - B. Her condition could have been prevented by having regular PAP smears
  - C. The virus responsible for her condition produces a protein (E7), which hinders the ability of the RB protein to bind elongation factor
  - D. A biopsy of the cervix prior to the development of invasive tumor would have shown cervical intraepithelial neoplasia (CIN) grade III
67. On his day for covering frozen sections, a pathology resident received a large uterus that has multiple well-circumscribed nodules within the myometrium, some of which bulge into the endometrium and some of which project from the serosal surface. Which of the following is NOT a common complication of this condition?
- A. Metastases to the lungs
  - B. Pelvic pain
  - C. Vaginal bleeding
  - D. Infertility
68. A 39-year-old woman has a biopsy performed of a mass in the left breast. The biopsy reveals sclerosing adenosis, fibrocystic changes, and lobular carcinoma in situ. No evidence of an invasive carcinoma or ductal carcinoma in situ component is identified. What is the next best step in the treatment of this patient?
- A. Counsel the patient regarding the possibility of a bilateral mastectomy
  - B. Schedule her for surgery again and remove more tissue from the site to prevent a recurrence and possible progression to invasive lobular carcinoma
  - C. Perform a radial mastectomy, followed with chemotherapy and radiation therapy
  - D. Nothing, because the lesion is not invasive and was completely removed by the biopsy
69. A 50-year-old man is witnessed to veer off the road and collide with a telephone pole. He is conscious when the ambulance arrives and is taken to the hospital. He tells the physician in the emergency department that he just passed out at the wheel. Auscultation of the chest reveals a crescendo-decrescendo, ejection-type systolic murmur. If he had died in the motor vehicle accident, which of these would have most likely been identified in his heart at the time of autopsy?
- A. Iron accumulations within the myocardium
  - B. Vacuolated myocardial cells containing glycogen
  - C. Firm yellow nodules on the aortic valve cusps
  - D. A dilated aortic valve ring due to prominent cholesterol accumulation
70. A 40-year-old man presents to the emergency department because of sudden onset of severe sharp substernal pain in his chest, which radiates to his back. On physical examination, his blood pressure is 200/120 mm Hg, and he has a harsh decrescendo diastolic murmur at the left sternal border. Which of the following is the most likely diagnosis?
- A. An aortic dissection
  - B. An acute myocardial infarct
  - C. A pulmonary thromboembolus
  - D. Acute pancreatitis
71. A 53-year-old white man who uses alcohol frequently and takes nonsteroidal anti-inflammatory drugs (NSAIDs) for his knee pain presents to the emergency department with acute abdominal pain. On physical examination, he is pale. His blood pressure is 88/43 mm Hg, and his pulse is 130 beats/min. Laboratory testing shows a hemoglobin of 12.5 g/dL. He is taken to the operating room, where he dies just prior to the start of surgery. An autopsy is performed and will most likely reveal
- A. a perforated gastric peptic ulcer
  - B. diverticulitis
  - C. an ulcerated and bleeding intestinal type gastric adenocarcinoma
  - D. an infarcted segment of small intestine due to a volvulus
72. A 49-year-old white man who smokes, drinks six cans of beer per day, and eats plenty of fatty foods presents to his family physician with complaints of long-standing indigestion. After an ECG and cardiac enzyme testing rule out a myocardial infarct, an esophagogastroduodenoscopy (EGD) is performed. The EGD reveals a reddened esophageal mucosa just proximal to the gastroesophageal junction. A biopsy of this area is most likely to reveal
- A. fungal hyphae
  - B. adenocarcinoma
  - C. glandular metaplasia
  - D. nuclei with viral inclusions



- 73.** A 60-year-old non-alcoholic woman presents to her family physician because of pallor and consistent fatigue after walking six blocks to work. A CBC reveals a hemoglobin of 7.0 g/dL with an MCV of 122. A peripheral blood smear has oval macrocytes and segmented neutrophils. She reports eating a normal healthy diet. A rectal examination reveals stool guaiac test is negative. Evaluation of her gastrointestinal tract will most likely reveal
- A. a perforated duodenal ulcer
  - B. an ulcerated and bleeding intestinal adenocarcinoma
  - C. atrophic gastric mucosa with focal intestinal metaplasia
  - D. atrophic duodenal villi
- 74.** A 43-year-old woman presents to the emergency department because of two episodes of vomiting blood. An emergent EGD reveals two ulcers, one recent and one healed on the greater curvature of the stomach, and a third ulcer in the duodenum. Hypertrophic gastric folds are present throughout the stomach. Which of the following will additional history, physical examination, laboratory testing, and diagnostic studies most likely reveal?
- A. A history of heavy nonsteroidal anti-inflammatory drug (NSAID) use
  - B. An elevated level of gastrin and a mass in the head of the pancreas
  - C. Heavy infection of gastric mucosa with *Helicobacter pylori*
  - D. Antimitochondrial and antiparietal cell antibodies
- 75.** A widowed 78-year-old woman with a history of diabetes mellitus is admitted for elective hip replacement. She tolerates her procedure well, but during her second postoperative night she becomes confused and experiences visual hallucinations. Her pulse is 130 beats/min, and her blood pressure increases from 125/80 mm Hg to 190/120 mmHg. Her oxygen saturation remains stable at 97% on room air. Which of the following is most likely responsible for the patient's alteration in mental status?
- A. Acute alcohol withdrawal
  - B. Fat embolism
  - C. An acute myocardial infarct
  - D. Dementia
- 76.** A 30-year-old woman presents to her family physician because of complaints of stiffness in her fingers. She works as a transcriptionist, and lately her work has caused her a great deal of discomfort. She is afraid of losing her job because of reduced turn-around time on reports. She relates that the stiffness is worse in the morning, but gets better as the day progresses. Which of the following is her most likely diagnosis?
- A. Osteoporosis
  - B. Osteoarthritis
  - C. Rheumatoid arthritis
  - D. Gout
- 77.** A 9-year-old boy is brought by his parents to their pediatrician because of the boy's history of diarrhea and foul-smelling stool. Comparison of the boy's height and weight to a normal growth curve indicates that he is in the less than 5% percentile categories (small for age). A biopsy of his duodenum shows a mucosa with flattened villi. How should this patient be managed?
- A. Contact Child Protective Services because of suspected neglect
  - B. Perform segmental resection of the duodenum
  - C. Increase his caloric intake and reduce the amount of fat in his diet
  - D. Remove food that is wheat-based from his diet
- 78.** A 27-year-old man who is an IV drug user presents to the emergency department because of abdominal pain. He reports red discoloration of his urine. On examination, he is hypertensive and has no dyspnea, chest pain, or hemoptysis. After initial evaluation in the clinic, the patient is admitted to the hospital. A chest radiograph and radiographic imaging of the kidneys, bladder, and pelvis reveal no abnormalities. Laboratory studies reveal elevated levels of amylase and lipase and an elevated level of creatinine. The patient is positive for hepatitis B surface antigen. Which of the following is the most likely diagnosis?
- A. Polyarteritis nodosa
  - B. Kawasaki disease
  - C. Goodpasture syndrome
  - D. Acute pancreatitis
- 79.** A 37-year-old woman presents to the emergency department with complaints of right lower quadrant pain. A review of symptoms reveals that she also has pain in her joints and a skin lesion on the foot. She undergoes surgery, and her appendix is removed. Pathologic evaluation of the appendix reveals granulomas in the submucosa and clusters of lymphocytes throughout the wall. What is her diagnosis?
- A. Ulcerative colitis
  - B. Crohn disease
  - C. Acute tuberculous appendicitis
  - D. *Entamoeba histolytica*
- 80.** A 28-year-old woman presents to her physician because of complaints of a mass on her left shoulder that has grown rapidly in size over the past several months. The nodule is nontender, and the patient is afebrile. She has multiple large (> 2 cm) hyperpigmented macules on her skin, and small brown dome-shaped elevations on her irises. Which of the following conditions is the most likely diagnosis for her rapidly growing mass?
- A. A malignant peripheral nerve sheath tumor
  - B. A hamartoma composed of smooth muscle
  - C. A benign tumor of Schwann cells
  - D. An angiomyolipoma

- 81.** A 63-year-old man presents to his family physician with complaints of abdominal pain and constipation. A subsequent barium enema reveals an “apple-core” lesion in the sigmoid colon. The barium enema also reveals multiple diverticula. The patient is scheduled for surgery. At the time of the surgery, the segment of bowel with the “apple-core” lesion noted on the barium enema is resected. When the pathologist opens the bowel, no mucosal lesions are identified. Which of the following statements is correct?
- A. The surgeon must operate again because the tumor was not resected
  - B. Despite the segmental colonic resection, this condition can recur in this patient
  - C. The patient most likely has segmental loss of Meissner plexus
  - D. The patient most likely has Crohn disease
- 82.** A 53-year-old alcoholic with a history of multiple falls is brought to the hospital by his family, who reports the patient has developed psychiatric symptoms. While in the hospital, he sustains an episode of ventricular fibrillation and is unable to be revived. At autopsy, he is found to have a dilated cardiomyopathy and an extracerebral hemorrhage. Which type is this hemorrhage most likely to be?
- A. An acute subdural hemorrhage
  - B. A chronic subdural hemorrhage
  - C. An acute epidural hemorrhage
  - D. Subarachnoid hemorrhage
- 83.** A neuropathologist is summoned to the pathology gross room by the neurosurgical team to perform a frozen section on a cerebral neoplasm that they are currently resecting. All of the features required for a diagnosis are present on the slide the pathologist will review. Based on the grading criteria, which of the following tumors will be the most difficult for the pathologist to diagnose?
- A. A low-grade astrocytoma
  - B. A glioblastoma multiforme
  - C. A gliosarcoma (glioblastoma multiforme with sarcomatous pattern)
  - D. An anaplastic astrocytoma
- 84.** A 48-year-old white woman with a history of Hashimoto thyroiditis presents to the emergency department because of right upper quadrant abdominal pain. During her subsequent evaluation, a biopsy of the liver is performed. The liver biopsy reveals a prominent number of lymphocytes within the portal tract, some extending beyond the limiting plate. Serologies for viral hepatitis reveal no evidence of an acute or chronic infection. Additional serologies would most likely reveal which antibody that is responsible for the liver disease?
- A. Anti-mitochondrial
  - B. Anti-smooth muscle or anti-liver-kidney
  - C. Anti-TSH receptor
  - D. Anti-scl70
- 85.** A 13-year-old boy is brought to his pediatrician by his parents because of his complaints of fatigue. A CBC reveals a white blood cell count of 200,000 cells/ $\mu$ L. Analysis of the cells reveals hypodiploidy and a t(9;22) translocation. What should the physician tell the family about this boy's condition?
- A. He has acute leukemia with multiple good prognostic indicators
  - B. If he has a recurrence, it is unlikely to involve the central nervous system
  - C. He has acute lymphoblastic leukemia (ALL) with multiple bad prognostic indicators
  - D. He has chronic myelogenous leukemia (CML) with a good prognosis
- 86.** A 3-month-old male infant is placed by his mother face down in his crib. Upon waking the next morning and checking on her child, the mother notices that he is unresponsive. She immediately calls for an ambulance. Upon arrival, the emergency medical technicians determine that the infant is not revivable and do not transport him to the hospital. The death is reported to the medical examiner, who subsequently performs an autopsy. The only gross or microscopic finding is petechial hemorrhages of the thymus and pleurae. Police investigation of the scene and questioning of the parents does not reveal any suspicious circumstances. What is the most likely cause of death?
- A. Sudden infant death syndrome
  - B. Intentional suffocation by the mother
  - C. Accidental suffocation due to the infant being placed into the crib face down
  - D. Accidental ingestion of the mother's prescription medication by the infant

- 87.** A 47-year-old man presents to his family physician because of recent onset of yellow eyes and a generalized feeling of malaise, with some right upper quadrant abdominal pain. As part of his evaluation, his physician orders a biopsy of the liver. The liver biopsy reveals a neutrophilic infiltrate of the parenchyma, rosy and eosinophilic condensations within the hepatocytes, and sclerosis of the central veins. What is the most likely etiology of his condition?
- A. Alcohol abuse
  - B. Hepatitis B infection
  - C. Hepatitis E infection
  - D. Bacterial colitis with hematogenous dissemination to the liver
- 88.** A 58-year-old white man presents to his family physician because of complaints of early satiety. A physical examination reveals splenomegaly. A complete blood cell count indicates a white blood cell count of 73,000 cells/ $\mu$ L. Laboratory testing of his blood reveals a t(9,22) translocation. Which of the following statements regarding his condition is NOT true?
- A. A smear of the peripheral blood will show an increased number of basophils
  - B. The level of leukocyte alkaline phosphatase may be decreased
  - C. A peripheral blood smear will show a large number of myeloblasts
  - D. A smear of his peripheral blood will show a large number of myelocytes, metamyelocytes, and bands
- 89.** A 41-year-old woman presents to her family physician because of intolerable pain upon swallowing. During the physical examination, the physician notices the patient winces upon palpation of her thyroid gland. If a fine needle aspirate (FNA) were performed, what would most likely be identified?
- A. Lymphocytes and follicular epithelial cells with oncocytic change
  - B. Multinucleated giant cells
  - C. Cells with pseudoinclusions and optically clear nuclei
  - D. Papillary collections of follicular epithelial cells without fibrovascular cores
- 90.** A 28-year-old pregnant woman in her third trimester collides with another vehicle while driving to the store. She sustains a compound fracture of the left femur and loses approximately 2.5 L of blood. Because of rapid response by the local ambulance service, she receives blood in a short amount of time and survives the incident. During her subsequent hospitalization, she develops cold intolerance and hypoglycemia. Previously, she had no evidence of gestational diabetes mellitus. What is her most likely diagnosis?
- A. Sudden onset of type 2 diabetes mellitus
  - B. Sheehan syndrome
  - C. Metastatic breast cancer
  - D. An undiagnosed craniopharyngioma
- 91.** A 28-year-old woman has been taking clindamycin for 1 week for cellulitis. She develops a fever and nonbloody diarrhea. Fecal leukocytes are present. A colonoscopy is most likely to reveal
- A. a patchy layer of thin tan material on the mucosa
  - B. flask-shaped ulcers
  - C. mucosal erythema and oval ulcers in the rectum
  - D. patchy mucosal erythema associated with deep linear ulcers
- 92.** A 51-year-old man has a history of hypertension, a 12-year history of diabetes mellitus type 2, and he also has hyperlipidemia. He has smoked one pack of cigarettes a day for 35 years. He takes a  $\beta$  blocker for his hypertension and insulin therapy for his diabetes. He complains of abdominal pain to his wife. She wants to take him to the hospital, but he refuses. Several hours after the pain begins, he becomes unresponsive. Emergency Medical Services are called, and on arrival at the emergency department, the patient's blood pressure is 75 mm over palpable with a pulse of 90 beats per minute. What is the most likely cause of this patient's death?
- A. A ruptured acute myocardial infarct
  - B. Acute pancreatitis
  - C. A ruptured abdominal aortic aneurysm
  - D. An intestinal volvulus, with resultant infarction of the small bowel
- 93.** A 16-year-old girl presents to her family physician with concerns because she has never had a menstrual period. On physical examination, she has Tanner stage 1 breast development with normal axillary and pubic hair development. Her blood pressure is significantly higher in her arms than in her legs. A pelvic examination is unremarkable. Her parents are both phenotypically normal, and she has no brothers or sisters with any type of hereditary condition. What is the most likely diagnosis?
- A. Turner syndrome
  - B. Androgen insensitivity syndrome
  - C. Polycystic ovarian disease
  - D. Hypogonadotropic hypogonadism



94. An 11-year-old child is brought to the hospital by his parents because of a red discoloration of his urine. He is also having blood in his stool and complaints of joint and abdominal pain. A biopsy of the kidney is performed. Which of the following is most likely to be found on the biopsy?
- A. Spikes on the silver stain
  - B. Tram-tracks on the silver stain
  - C. IgA positivity on immunofluorescence
  - D. Fusion of the foot processes
95. A 16-year-old boy is brought to the emergency department by his parents because of his complaints of pain on urination. His work-up includes a urine culture that subsequently grows *Escherichia coli* 2 days after his visit to the emergency department. On the day he was seen in the emergency department, he was placed on antibiotics, which would adequately treat the *E coli* that subsequently grew. How should this boy be followed up?
- A. He needs no follow-up because he received appropriate antimicrobial therapy for his urinary tract infection
  - B. A second antibiotic should be added to ensure coverage of *E coli* and prevent pyelonephritis
  - C. Subsequent renal ultrasound to ensure that the infection did not spread to kidney
  - D. His genitourinary tract should be evaluated for any congenital abnormalities
96. A 15-year-old boy develops acute lymphoblastic leukemia. Shortly after birth, he was diagnosed with duodenal atresia, which was treated with surgical intervention. Which of the following factors most likely contributed to the development of his condition?
- A. Maternal tobacco use
  - B. Maternal alcohol use
  - C. Maternal age of 48 years
  - D. Maternal exposure to ionizing radiation
97. A 13-year-old girl experiences severe leg pain while playing soccer. She reports no falls or recent trauma. A radiograph taken when she is in the emergency department reveals a soft tissue density and fracture of the diaphysis of her right femur. What is the most likely cause of the fracture?
- A. Trauma
  - B. Osteosarcoma
  - C. Ewing sarcoma
  - D. Chondrosarcoma
98. A 23-year-old man with a recent history of a viral-type illness presents to the emergency department because of complaints of weakness in his legs. He is admitted to the hospital and the weakness progresses into his thighs and hips. What is his prognosis?
- A. Fair, with treatment the progression of the muscle weakness will stop, but the weakness will remain for the remainder of his life
  - B. Good, with treatment the muscle weakness will definitely stop and not progress further
  - C. Good, with treatment the condition will run its course, and his life can be saved and he should have no residual sequelae
  - D. Dismal, the condition will continue to progress, involving his respiratory muscles, causing his death even if treated
99. A 67-year-old man with a long history of smoking presents to the hospital with complaints of increasing shortness of breath. During his evaluation, a small mass is identified in the lower lobe of the left lung. Laboratory testing reveals an elevated level of cortisol, a decreased level of ferritin, and increased total iron-binding capacity. A colonoscopy reveals a mass in the descending colon. The patient is taken to the operating room, where a wedge resection of the pulmonary nodule is performed. A frozen section reveals cells with a high nuclear to cytoplasmic ratio and evidence of nuclear molding. What should the surgeon do next?
- A. End the operation; he has removed the pulmonary metastatic nodule derived from the colon carcinoma
  - B. End the operation and inform the clinical team to proceed with radiation and chemotherapy in the treatment of the pulmonary nodule
  - C. Perform a left-sided pneumonectomy to ensure a cure for the pulmonary nodule
  - D. Ask the pathologist if the margins are clear; if not, remove more lung
100. A 5-year-old child is brought to his pediatrician because his parents have noticed that his hands and feet are swelling, and they can feel lumps in his neck. In addition, his mouth appears redder than normal. A physical examination reveals a blood pressure of 110/71 mm Hg, a temperature of 41°C (105°F), and cervical lymphadenopathy. Which of the following complications is this child at most risk for in the future?
- A. A restrictive cardiomyopathy
  - B. Thoracic aortic aneurysm
  - C. Coronary artery aneurysm
  - D. Mitral stenosis

- 101.** A 79-year-old man with Alzheimer disease aspirates a large bolus of food during a meal. The food does not occlude his airway. However, shortly afterward he develops severe dyspnea. He is taken to the hospital and despite therapy, he dies. An autopsy is performed. What will be identified in the lungs of this patient?
- A. Prominent alveolar septal lymphocytic infiltrate
  - B. Thick bands of eosinophilic, proteinaceous material layered on the alveolar septae
  - C. Pulmonary edema
  - D. Most likely nothing of significance
- 102.** A 25-year-old woman presents to the hospital because of blindness in her right eye. She has a twin sister with a similar condition. Many years ago, her sister went blind in one eye, but the blindness resolved and she has never had any other neurologic symptoms. The physician obtains cerebrospinal fluid and submits it for laboratory testing. The laboratory testing reveals oligoclonal bands. What should the physician tell the patient regarding her condition?
- A. The blindness is most likely not caused by the same condition that your sister had, so we need to test you for antinuclear antibodies
  - B. This may be your only episode of neurologic dysfunction, but most likely you will have other episodes in the future, not necessarily involving the eyes
  - C. Like your sister, this will be the only episode you have like this
  - D. Unlike your sister, you will probably have multiple neurologic episodes and end up wheelchair bound
- 103.** A 20-year-old man is being evaluated by his family physician because of an inability to conceive a child with his wife, despite numerous attempts. His physician notices the patient has atrophic testicles and a reduced amount of body hair. Of the following, what further testing should be done to evaluate this patient?
- A. Evaluation of cognitive abilities, looking for mental retardation
  - B. Breast examination
  - C. Echocardiogram, looking for coarctation of the aorta
  - D. Body mass index determination and evaluation of eating habits
- 104.** A 56-year old man with a long-standing history of hypertension presents to his family physician because of complaints of dyspnea on exertion. A physical examination reveals bibasilar crackles. An ECG reveals left ventricular hypertrophy by voltage criteria, but no evidence of ST elevation or depression. Cardiac enzymes levels are within normal limits. An echocardiogram of the heart reveals dilation of the left ventricle. Which of the following is the most likely diagnosis?
- A. Low-output, left-sided congestive heart failure due to systolic dysfunction
  - B. High-output, left-sided congestive heart failure due to diastolic dysfunction
  - C. Low-output, right-sided congestive heart failure due to systolic dysfunction
  - D. High-output, left-sided congestive heart failure due to systolic dysfunction
- 105.** A 38-year-old African-American woman marketing executive has bilateral hilar lymphadenopathy on a plain chest radiograph performed during a health insurance examination. The lung fields are otherwise unremarkable, and her PPD skin test is negative. Which of the following statements concerning her diagnosis is correct?
- A. She may have a decreased level of angiotensin-converting enzyme (ACE)
  - B. Involvement of the lymph nodes is more serious than involvement of the lungs
  - C. The disease process is confined to the lungs and lymph nodes
  - D. The condition may be associated with hypercalcemia
- 106.** A 43-year-old woman underwent an exploratory laparotomy following a motor vehicle accident. At the time of the surgery, she was found to have a right ovarian mass, which was subsequently diagnosed as a granulosa cell tumor. She is nulligravida with a history of diabetes mellitus and obesity. Which of the following is NOT a possible complication of her above-mentioned conditions?
- A. Vaginal bleeding
  - B. Complex hyperplasia of the endometrium
  - C. Invasive ductal carcinoma of the breast
  - D. Invasive endometrial adenocarcinoma
  - E. All of the following are possible complications

**107.** A 28-year-old woman of Mediterranean descent presents to her family physician with complaints of heavy menstrual periods. She reports increased fatigue on review of systems, and she says “anemia” runs in her family. Laboratory testing reveals a hemoglobin of 8.0 g/dL, MCV of 82, and a low MCHC. What additional information would be most helpful in determining if this woman has a genetic cause of anemia?

- A. Sickle index
- B. Meltzer index
- C. HbA<sub>2</sub>
- D. Osmotic fragility test

**108.** An 80-year-old man has experienced a progressive decline of cognitive function over the past 5 years. Currently, he does not remember any family members, with the exception of his wife. He sometimes gets lost within his own house. Evaluation of his brain will reveal cellular accumulations of

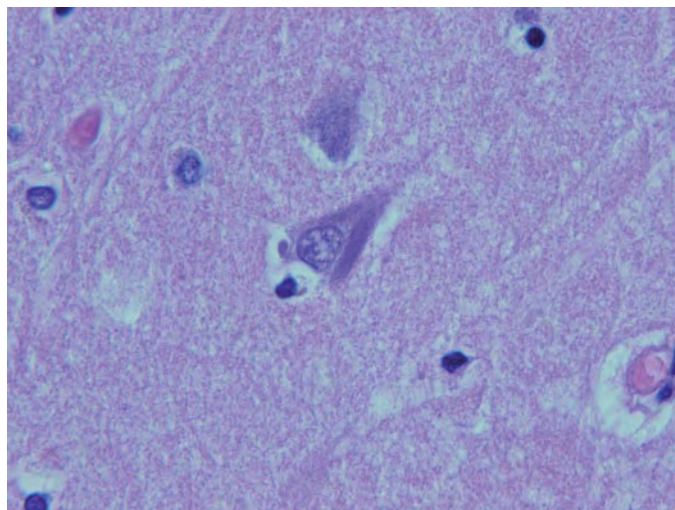
- A. iron
- B. fat
- C. protein
- D. lipofuscin

**109.** A 43-year-old man who is a chronic alcoholic presents to the hospital with fatigue and a burning sensation in his feet. Laboratory testing is performed, and a peripheral blood smear reveals anemia with hypersegmented neutrophils and oval macrocytes. The patient is given folate, and the anemia resolves. However, the burning sensation in his feet worsens. Which of the following statements best explains this patient’s symptomatology?

- A. The patient had megaloblastic anemia due to folate deficiency, and the worsening of the sensation in his feet is unrelated
- B. The patient lacks the ability to absorb the folate due to pancreatic insufficiency from chronic pancreatitis
- C. The patient had a vitamin B<sub>12</sub> deficiency, and the treatment with folate partially masked its effects, treating the anemia but not the neurologic changes
- D. The patient’s peripheral neuropathy is secondary to thiamine deficiency, and addition of folate to the diet without thiamine supplementation caused increased demand for thiamine and acute worsening of his neuropathy

**110.** A 48-year-old man presents to the hospital with back pain. A full-body CT scan reveals a single osteolytic lesion in the vertebral column at the level of the seventh thoracic vertebra. Serum protein electrophoresis does not reveal an M spike. A biopsy of the mass reveals basophilic cells with eccentric nuclei and a clear, perinuclear area. What is the most likely diagnosis?

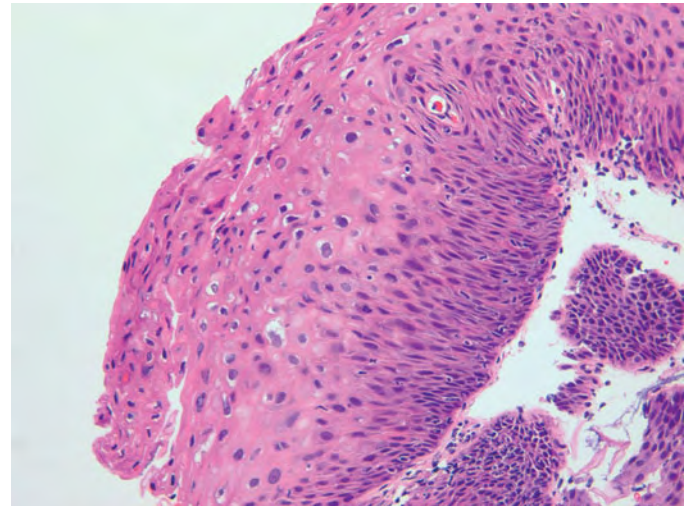
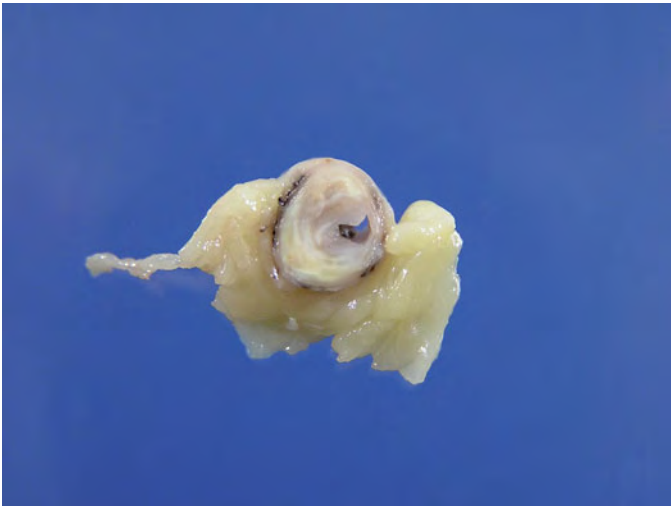- A. Solitary plasmacytoma
- B. Monoclonal gammopathy of undetermined significance (MGUS)
- C. Multiple myeloma
- D. Diffuse large B-cell lymphoma



**111.** How would the patient shown in the above image present?


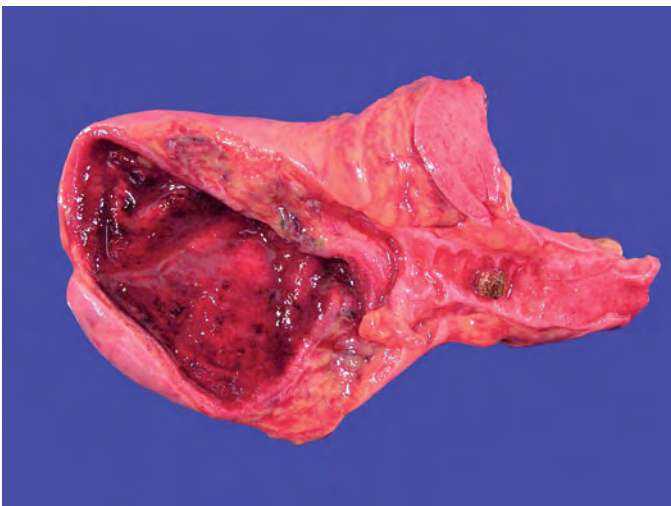
- A. Memory loss
- B. Seizure activity
- C. Choreiform movements
- D. Flat affect and shuffling gait





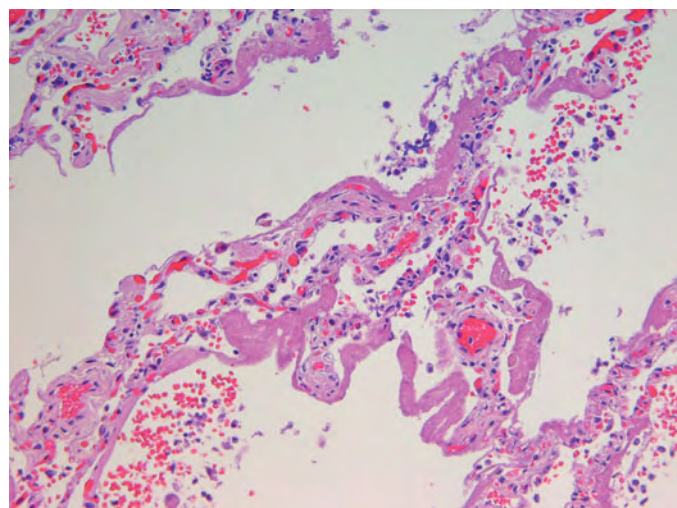
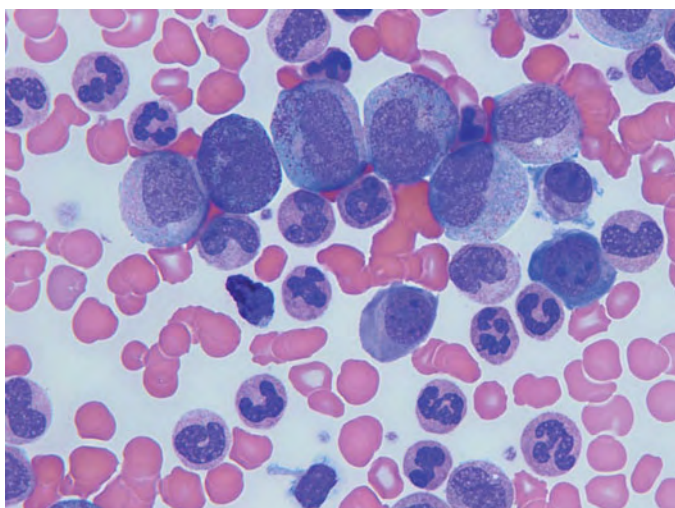
112. At autopsy, the above specimen was taken from a 57-year-old man who died suddenly at home. The lesion above was the direct cause of his death. What symptoms would this man have complained of prior to his death?
- Sudden onset of chest pain with radiation to the left arm, associated with nausea and vomiting
  - Shortness of breath after climbing two flights of stairs, when he normally only becomes short of breath after climbing five flights of stairs
  - Shortness of breath after climbing four flights of stairs, which is unchanged from his normal pattern
  - Difficulty breathing at night and swelling of the ankles

114. The patient in this image was most likely exposed to which of the following infectious agents?
- Human papillomavirus type 6 (HPV-6)
  - HPV-33
  - Herpes simplex virus
  - Neisseria gonorrhoeae*



113. Which of the following is a likely complication of the condition shown in this image?
- Metastases to the liver
  - Peritonitis
  - Acute pancreatitis
  - Gastric peptic ulcer

115. Of the following, which is a likely cause of death of a patient with the condition shown in the image?
- Tumor metastases to the brain and lungs
  - Congestive heart failure
  - Gastrointestinal hemorrhage
  - Bowel obstruction

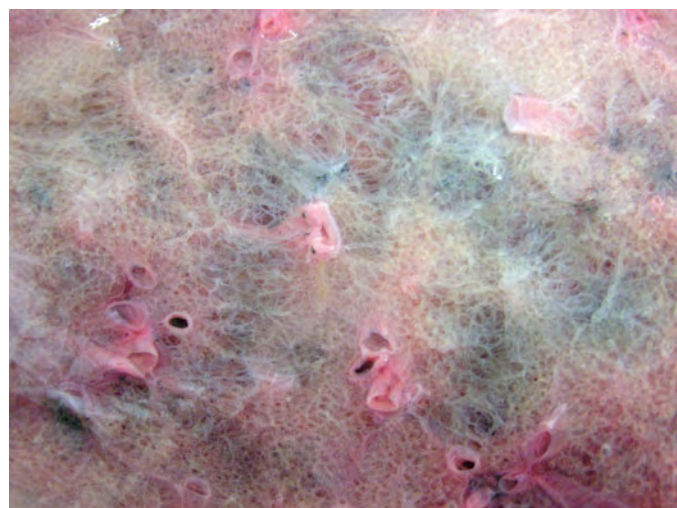
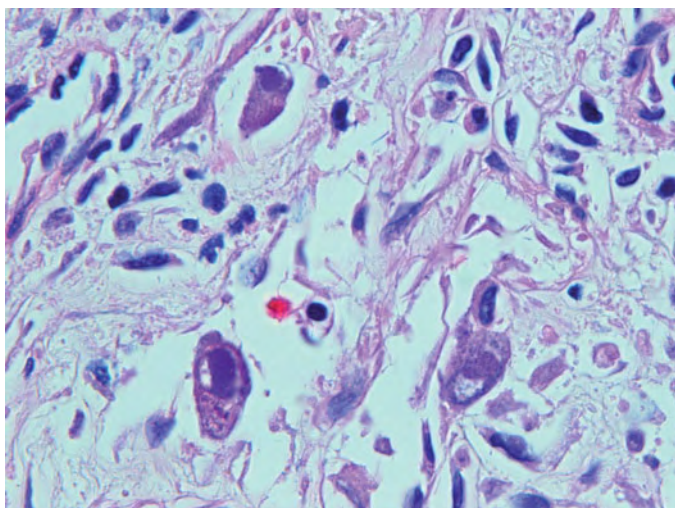


**116.** A patient with the condition shown in the image would most likely have which of the following?

- A. A t(15;17) translocation
- B. CD5 positive neoplastic cells
- C. A decreased or normal leukocyte alkaline phosphatase level
- D. An eosinophilia

**118.** Which of the following conditions is NOT a common cause of the changes featured in the image?

- A. Sepsis
- B. Metastatic neoplasm
- C. Head injuries
- D. Aspiration of gastric contents by a patient with dementia



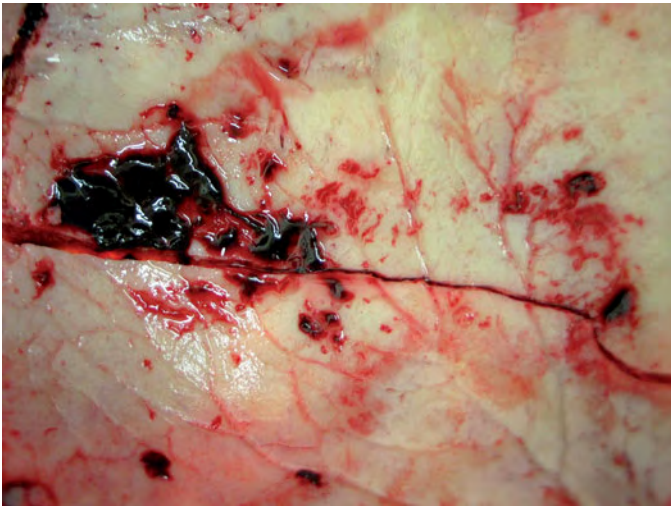
**117.** Which of the following conditions does the patient in this image have?

- A. An infection with cytomegalovirus
- B. An infection with herpes simplex virus
- C. A nodular sclerosis type Hodgkin lymphoma
- D. Infection with *Entamoeba histolytica*

**119.** Which of the following is the etiology for the disease process shown in the above image?

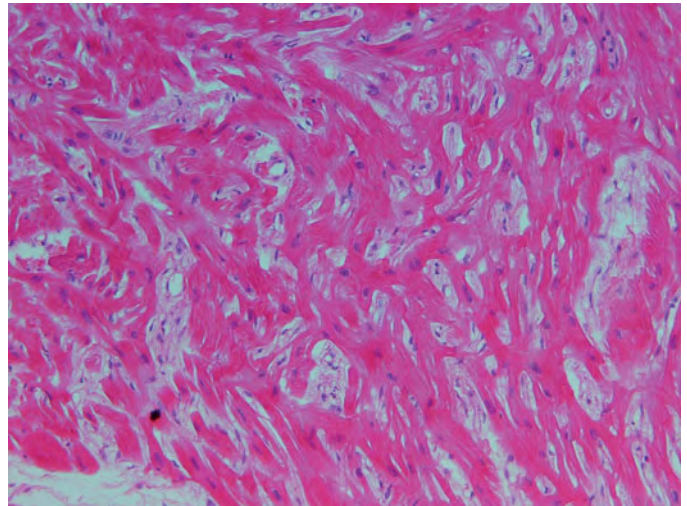
- A. Hypersensitivity to inhaled allergens
- B. Cigarette smoking
- C. Beryllium exposure
- D. An obstructing tumor in the main stem bronchus





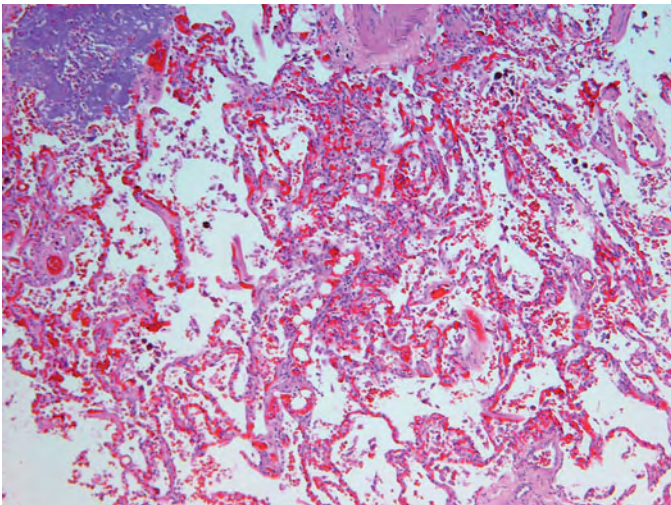
**120.** Which of the following statements best explains the condition shown in this image?

- A. It commonly occurs in alcoholics and the elderly who fall and strike their head
- B. Patients become unconscious immediately and remain unconscious indefinitely
- C. The hemorrhage is most commonly from tears of the sagittal sinus
- D. The condition results most commonly from a fracture of the temporal bone



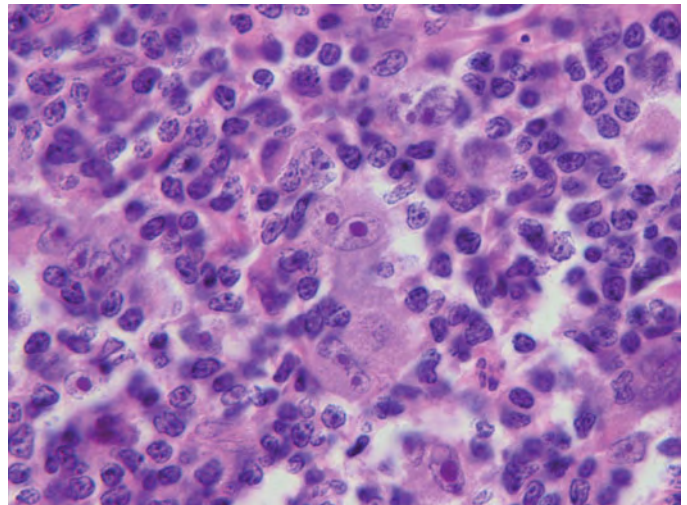
**122.** Which of the following clinical scenarios best fits the image?

- A. A 32-year-old woman with no recent complaints or significant past medical history found dead in bed by her husband
- B. A 45-year-old chronic alcoholic with congestive heart failure
- C. A 77-year-old man with amyloidosis
- D. A 56-year-old man with hypertension and diabetes mellitus who complains of chest pain while bike riding with friends



**121.** Which of the following is the most likely clinical scenario for the condition in the image?

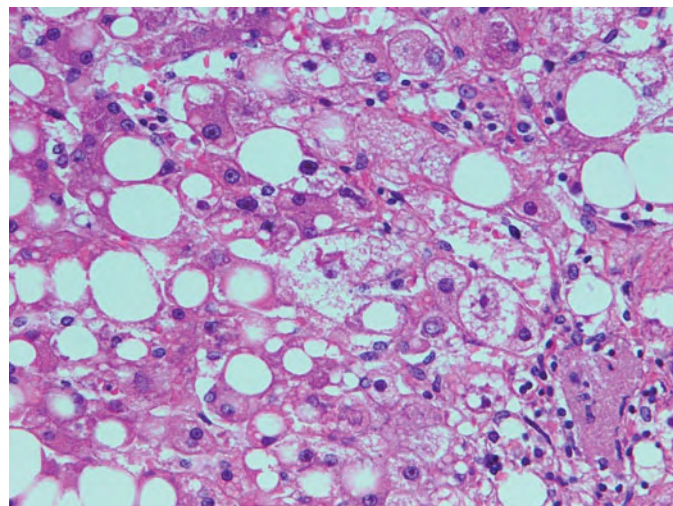
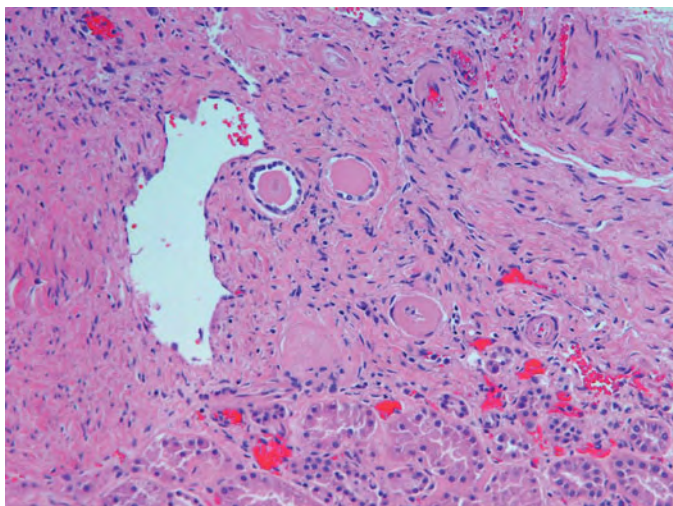
- A. A hospitalized patient who suddenly becomes unresponsive 12 days after a motor vehicle accident that resulted in a femur fracture
- B. Dyspnea and mental status changes in a patient 1 day after a motor vehicle accident, which resulted in a fractured femur
- C. Aspiration of gastric contents by a neuromuscularly impaired individual
- D. A pregnant woman who suddenly becomes short of breath after the delivery of her infant



**123.** The patient in this image has which of the following conditions?

- A. An infection with cytomegalovirus
- B. An infection with herpes simplex virus
- C. The nodular sclerosis variant of Hodgkin lymphoma
- D. Burkitt lymphoma



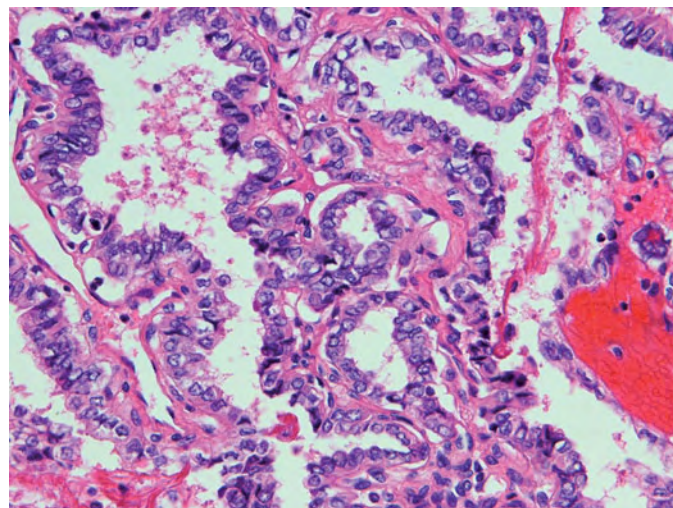
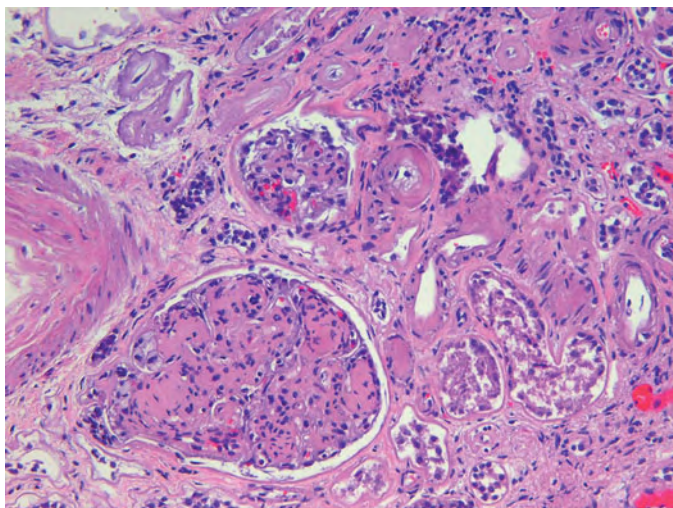


**124.** This image depicts which of the following conditions?

- A. Hyperplastic arteriosclerosis
- B. Kimmelstiel-Wilson lesion
- C. Hyaline arteriosclerosis
- D. A neurofibroma

**126.** What most likely accounted for the microscopic changes in this patient's liver?

- A. Chronic hepatitis C infection
- B. Acute hepatitis B infection
- C. Alcohol use
- D.  $\alpha_1$ -Antitrypsin deficiency



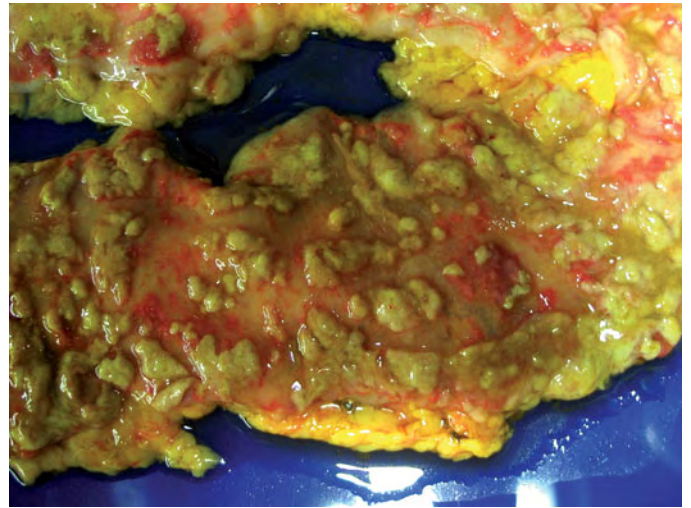
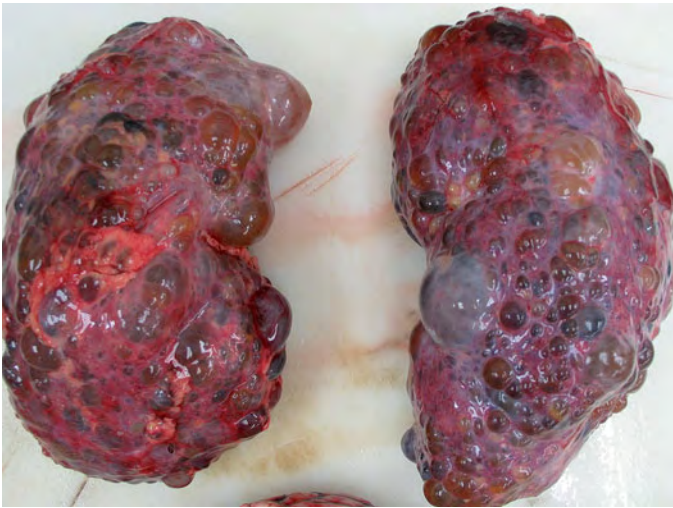
**125.** Physical examination and laboratory evaluation of a patient with the disease process represented by this image would most likely reveal

- A. a blood glucose level of 250 mg/dL
- B. a 24-hour urine protein level of 5.5 grams, hematuria (2+), and a blood pressure of 195/100 mm Hg
- C. schistocytes in the peripheral blood smear
- D. anemia, thrombocytopenia, and elevated BUN and creatinine

**127.** This tissue shown in the image was taken from a resected thyroid mass. Examination of other areas of this tumor would most likely reveal

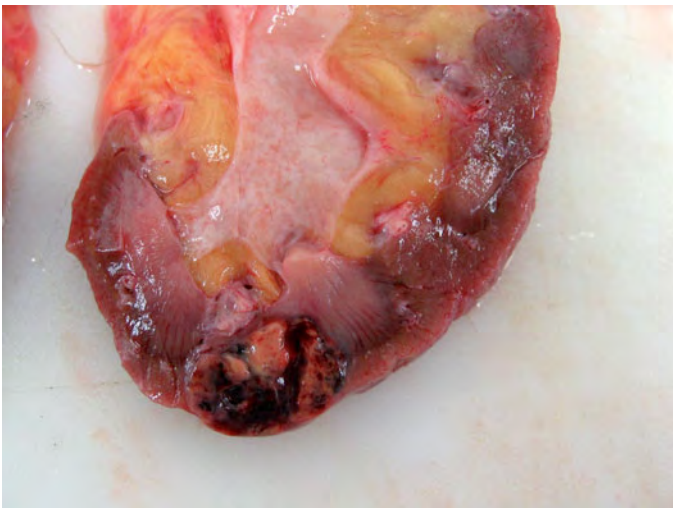- A. amyloid deposition
- B. psammoma bodies
- C. extensive hemosiderin deposition
- D. numerous mitotic figures





- 128.** The kidneys shown in this image are from a 24-year-old man. What would have been the most likely cause of his death?
- A. A subarachnoid hemorrhage due to a ruptured berry aneurysm
  - B. A hypertensive crisis
  - C. Chronic renal failure
  - D. Metastatic renal cell carcinoma

- 130.** Which of the following statements best explains the condition shown in this image?
- A. The patient has a 100% chance of developing an invasive colonic adenocarcinoma during his lifetime
  - B. The condition can affect any segment of the gastrointestinal tract
  - C. The patient recently finished a course of antibiotic therapy
  - D. The patient is most likely septic and hypotensive



- 129.** The kidney shown in the image was resected from a 63-year-old man with a history of smoking two packages of cigarettes a day for 40 years, who presented with hematuria. What is the most likely diagnosis?
- A. Papillary necrosis
  - B. Renal cell carcinoma
  - C. Angiomyolipoma
  - D. Hemangioma

## PRACTICE EXAMINATION ANSWERS

### Question 1

**Answer: C.** Due to conditioning, the marathon runner will have physiologic hypertrophy of the heart. Because physical exercise is a normal process, the changes in the heart are physiologic. The myocardial cells cannot divide, so the heart cannot undergo hyperplasia. A marathon runner would have hypertrophy of skeletal muscle, not atrophy.

### Question 2

**Answer: D.** The sudden focal change in neurologic function is consistent with a stroke. It has lasted longer than 24 hours, so it is not a transient ischemic attack, and it is not global in nature. Weakness of the left leg can be caused by an infarct in the distribution of the right anterior cerebral artery.

### Question 3

**Answer: A.** The patient has stable angina. Stable angina is caused by a fixed (i.e., no recent change) obstruction of the coronary artery, which causes  $\geq 75\%$  stenosis. Choice C (atherosclerotic plaque in the left anterior descending coronary artery that causes 75% stenosis and has a large cluster of intact red blood cells within its core) and choice D (ruptured atherosclerotic plaque in the left anterior descending coronary artery associated with a nearly occlusive thrombus) describe atherosclerotic plaques with recent changes (e.g., hemorrhage and thrombus formation).

### Question 4

**Answer: C.** The location of the retinoblastoma gene is 13q14, and in familial cases, it is associated with retinoblastoma and osteosarcoma. 5q21 is the location of the *APC* gene, and in familial cases, it is associated with colonic adenocarcinoma. 17p13 is the location of the *p53* gene, and in familial cases, it is associated with various sarcomas and with breast carcinoma. 3p25 is the location of the von Hippel-Lindau gene and in familial cases, it is associated with renal cell carcinomas and cerebellar hemangioblastomas.

### Question 5

**Answer: A.** A young healthy patient who sustains head trauma with a lucid interval (a period of consciousness between the injury and subsequent unconsciousness) and subsequently becomes unresponsive with evidence of a space-occupying lesion in the right side of the cranial cavity most likely has an epidural hemorrhage. The epidural hemorrhage can produce a midline shift and uncal and cerebellar tonsillar herniation. An epidural hemorrhage is most commonly due to a fracture of the temporal bone, with subsequent tearing of the middle meningeal artery.

### Question 6

**Answer: A.** The history and findings are consistent with a lobar pneumonia. The most common etiologic agent of lobar pneumonia is *Streptococcus pneumoniae*.

### Question 7

**Answer: B.** Patients with Wernicke encephalopathy have ataxia, disturbed cognition, and ophthalmoplegia. The disorder is caused by a deficiency of thiamine and is classically seen in chronic alcoholics. The three clinical manifestations of thiamine deficiency are peripheral neuropathy, wet beriberi (high output cardiac failure), and Wernicke-Korsakoff syndromes. Overlap exists between Wernicke encephalopathy and Korsakoff syndrome, but Korsakoff syndrome is usually associated with amnesia and is not reversible.

### Question 8

**Answer: C.** The patient's brother most likely had Marfan syndrome. Of the possible choices, patients with Marfan syndrome are most likely to have dislocation of the lens.

### Question 9

**Answer: D.** The patient most likely has Paget disease. Her symptoms are being caused by the compressive effects of bony overgrowth on the cranial nerves, including the left abducens nerve (CN VI). The mosaic pattern of the lamellar bone is characteristic of Paget disease.

### Question 10

**Answer: B.** Choriocarcinomas and seminomas with giant cells produce hCG. Yolk sac tumors produce AFP. An ultrasound would help to determine whether the mass was solid or was a fluid-filled cyst.

### Question 11

**Answer: B.** The patient is describing claudication, which is the characteristic symptom of peripheral vascular disease, a form of atherosclerotic cardiovascular disease. The patient has numerous risk factors for atherosclerosis.

### Question 12

**Answer: D.** The patient's white blood cells are incapable of transmigration, which requires the presence of PECAM (CD31) on both the white blood cells and endothelial cells.

### Question 13

**Answer: C.** A fistula is a possible complication of an acute inflammatory process. In this case, a fistula developed between the infected aortic graft and the duodenum, allowing blood to enter the gastrointestinal tract and move retrograde through the esophagus.

### Question 14

**Answer: B.** The clinical symptomatology, clinical findings, and the flow cytometry results are consistent with hairy cell leukemia.

### Question 15

**Answer: A.** The question describes a patient with fragile X syndrome. Patients with fragile X syndrome have CGG repeats on the X chromosome.



**Question 16**

**Answer: A.** The patient has a meconium ileus. The “soap bubble” pattern is caused by air trapped within the thickened meconium and is highly suggestive, but not pathognomonic, of meconium ileus. Pyloric stenosis (C) is associated with bilious vomiting, but gaseous dilation of the small bowel would not be expected, and most cases of pyloric stenosis occur after 3 weeks of life. Hirschsprung disease (B) can cause delayed passage of meconium and may be associated with a small colon initially, but most cases of meconium ileus are associated with cystic fibrosis.

**Question 17**

**Answer: D.** The patient has the signs and symptoms of nephrotic syndrome. The most common cause of nephrotic syndrome in children is minimal change disease. Minimal change disease is treated with steroids, rarely requiring a biopsy for diagnosis. If a child with suspected minimal change disease responds to steroids, the diagnosis of minimal change disease can be made. If the child does not respond to steroid therapy, a kidney biopsy is warranted to diagnose the cause of the nephrotic syndrome.

**Question 18**

**Answer: A.** Of the listed conditions, the most likely to be occurring in this patient is a placental abruption. Cigarette smoking during pregnancy, trauma, and possibly cocaine use increase the risk for placental abruption. Placenta previa causes painless vaginal bleeding during the third trimester. An ectopic pregnancy is unlikely to be carried to term.

**Question 19**

**Answer: C.** The question describes a patient with pellagra, which is a complication of niacin (vitamin B<sub>3</sub>) deficiency. The manifestations are diarrhea, dermatitis, and dementia.

**Question 20**

**Answer: B.** Hamartomas are the third most common cause of a solitary pulmonary nodule “coin lesion.” A hamartoma is a benign disorganized collection of a tissue type normally found in the organ in which the mass occurred. Most pulmonary hamartomas are solitary, peripherally located, and often have a “popcorn” or stippled pattern of calcification.

**Question 21**

**Answer: D.** The patient is experiencing symptoms from sluggish blood flow due to the high red blood cell count. The pink discoloration of the urine is due to blood. The elevated red blood cell count is due to abnormal erythropoietin production. Both of these features indicate a renal cell carcinoma, which, of the above choices, would be diagnosed with a CT scan of the abdomen and pelvis.

**Question 22**

**Answer: B.** The patient had emphysema, and the icteric conjunctivae indicate possible liver damage. In a young person with this combination,  $\alpha_1$ -antitrypsin deficiency is a possible diagnosis.

**Question 23**

**Answer: C.** Hyaline membrane disease, necrotizing enterocolitis, and germinal matrix hemorrhage are well-known potential complications of prematurity. Pink acellular membranes lining the alveolar septae describe the histologic features of hyaline membrane disease.

**Question 24**

**Answer: B.** The histologic and molecular features of the tumor are most commonly associated with Ewing sarcoma. A common location for Ewing sarcoma is the diaphysis of the tibia.

**Question 25**

**Answer: C.** The lack of elevation in cardiac enzymes indicates that no damage was done to the heart. However, the symptoms are suggestive of a myocardial infarct; therefore, the patient had unstable angina. Unstable angina is also referred to as preinfarct angina. The patient may have had a change in an atherosclerotic plaque (e.g., hemorrhage or thrombus), which resolved prior to causing irreversible damage to the heart.

**Question 26**

**Answer: C.** A mass in the left cerebral hemisphere will cause swelling, which can lead to herniation. Herniation of the left uncus can impinge on the oculomotor nerve, damaging parasympathetic fibers and leading to pupil dilation. Herniation of the uncus can also impinge on the posterior cerebral artery, causing ipsilateral occipital lobe infarcts.

**Question 27**

**Answer: B.** Any of the above conditions are possible causes of a hypercoagulable state. The most common inherited hypercoagulable condition is factor V Leiden, which is an inherited mutation in factor V that removes the cleavage site for protein C; thus, protein C cannot inactivate activated factor V.

**Question 28**

**Answer: D.** The gross appearance of the tumor is consistent with a malignant mesothelioma. A pleural malignant mesothelioma is consistent with a history of asbestos exposure until proven otherwise. The pleural plaques are also an indication of asbestos exposure, and the histology of the lung and clinical testing is consistent with asbestosis.

**Question 29**

**Answer: A.** The patient’s symptoms are consistent with a prolactinoma. The prolactin level could be increased by a nodule in the sella turcica that compresses the infundibulum (stalk effect) and blocks the inhibitory effects of dopamine. However, stalk effect causes a lower level of hyperprolactinemia (100–200 ng/L) compared to a prolactinoma. In most cases, hormone-producing adenomas present with symptoms at a much smaller size than adenomas that do not secrete a hormone (i.e., null cell adenomas), because of the clinical effects of the hormones produced. Null cell adenomas usually present at a much larger size because they require mass effects to present.

**Question 30**

**Answer: C.** Given the history, this patient most likely has a secondary erythrocytosis due to erythropoietin production by a renal cell carcinoma.

**Question 31**

**Answer: A.** The signs and symptoms combined with the clinical scenario (obese woman taking oral contraceptives who dies suddenly) are characteristic of a pulmonary thromboembolus. To cause sudden death, a pulmonary thromboembolus must obstruct > 60% of the pulmonary artery vasculature.

**Question 32**

**Answer: A.** The clinical scenario is characteristic for fatty emboli. The classic clinical triad is dyspnea, mental status changes, and petechial hemorrhages (often axillary) following a traumatic fracture of a long bone.

**Question 33**

**Answer: B.** The patient's clinical features are consistent with septic shock. In hypovolemic or cardiogenic shock, patients will have increased heart rate and decreased blood pressure, but will have cold skin. Septic shock causes a generalized vasodilation, producing the symptoms. However, in response to hypovolemic or cardiogenic shock, the peripheral arteries will constrict to facilitate shunting of blood to the vital organs and cause cold extremities. Acute respiratory distress syndrome (ARDS) is a common complication of septic shock, and is characterized by development of bilateral infiltrates and consolidation on chest radiograph. There is no evidence that this patient has suffered a myocardial infarction (A). Central venous pressures would be expected to be low, secondary to vasodilation in the setting of septic shock. The stress response, the infection, and this patient's diabetes mellitus all make hyperglycemia more likely than hypoglycemia.

**Question 34**

**Answer: B.** CR1 molecules on the surface of leukocytes are used to recognize C3b (an opsonin) coating the surface of the material to be engulfed. CD31 is used for transmigration of white blood cells. Sialyl-Lewis-X molecules and ICAM-1 are used, respectively, for rolling and pavementing of white blood cells.

**Question 35**

**Answer: C.** The physical findings are suggestive of renal artery stenosis, possibly due to renal artery dysplasia. The patient has hypertension, which is secondary to another underlying disorder and potentially can be treated and cured.

**Question 36**

**Answer: A.** Of the choices, only the pituitary adenoma and small cell lung cancer would produce elevated cortisol levels and elevated ACTH level. Ectopic ACTH production as a paraneoplastic process, however, would not result in suppression of ACTH production with dexamethasone challenge. The two processes within the adrenal gland (hyperplasia and adenoma) may produce an elevated cortisol level, but negative feedback would result in a decreased ACTH level.

**Question 37**

**Answer: B.** The patient has features of preeclampsia. Preeclampsia can progress to eclampsia with the development of seizures.

**Question 38**

**Answer: D.** These symptoms suggest the possibility of a temporal arteritis. The definitive diagnosis of temporal arteritis requires a biopsy, although the ESR is usually elevated. However, diagnostic tests should not delay treatment with corticosteroids since the risk for blindness is significant.

**Question 39**

**Answer: B.** The patient's signs and symptoms are most consistent with Wegener granulomatosis. Although the patient has both upper respiratory and renal abnormalities, patients with Goodpasture syndrome often have hemoptysis, and it is the lower respiratory tract that is involved (i.e., the alveolar basement membranes).

**Question 40**

**Answer: A.** The most common congenital cardiac malformation is a ventricular septal defect. The signs and symptoms are consistent with the diagnosis of a ventricular septal defect, and, as happened with this child, many ventricular septal defects close spontaneously.

**Question 41**

**Answer: C.** The patient has features of congestive heart failure. Given her age and history of diabetes mellitus and hypertension, her congestive heart failure likely resulted from multiple ischemic events over the past several years.

**Question 42**

**Answer: A.** Patients with Addison disease usually have increased pigmentation (especially oral) and atrophic adrenal glands. Secondary hypoadrenalism will produce atrophic adrenal glands, but not the increased pigmentation. Secondary hypoadrenalism is commonly due to steroid therapy. Steroids must be withdrawn slowly to allow the atrophic adrenal gland to increase in size and restore normal function.

**Question 43**

**Answer: D.** Patients with osteomyelitis are at risk for future development of a sarcoma, a pathologic fracture, and systemic amyloidosis. Fatty emboli syndrome arises a few days after fracture of a long bone, and has also been associated with diffuse fatty liver and pancreatitis.

**Question 44**

**Answer: A.** Based upon the patient's demographics and location of the mass, of the given choices, the most likely diagnosis is an osteosarcoma.

**Question 45**

**Answer: A.** The patient has symptoms of osteoarthritis. Pannus formation and rheumatoid factor (IgM versus the Fc portion of IgG) are characteristic of rheumatoid arthritis. Although osteoarthritis can be secondary to a traumatic incident, most cases are primary, with wear and tear as one contributory factor.

**Question 46**

**Answer: D.** The patient's clinical presentation is characteristic for gout. Alcohol use and obesity are risk factors for gout. Most patients are underexcretors of uric acid, and not overproducers. Gout can contribute to the development of uric acid stones in the kidney, and also to the precipitation of uric acid into the renal interstitium.

**Question 47**

**Answer: C.** The patient has a rapidly growing, left-sided intracerebral neoplasm, which has resulted in left uncal herniation. Compression of the left oculomotor nerve, with subsequent involvement of the parasympathetic nerve fibers caused the pupillary dilation. Uncal herniation can also compress the posterior cerebral artery.

**Question 48**

**Answer: A.** The patient has features consistent with Wegener granulomatosis (sinusitis, features of nephritic syndrome, positive for c-ANCA). Wegener granulomatosis is associated with type III crescentic glomerulonephritis (pauci-immune type).

**Question 49**

**Answer: B.** The question describes a patient with hereditary spherocytosis. Patients with hereditary spherocytosis have increased osmotic fragility, and can develop splenomegaly (causing early satiety) and gallstones.

**Question 50**

**Answer: A.** Answer A, a 4.5-cm cavity in the right parietal lobe, refers to the appearance of a remote infarct. Answer B, an ill-defined softening of the right parietal lobe, refers to the appearance of an acute infarct. Answer C, a well-defined friable area in the right parietal lobe, refers to the appearance of an organizing infarct. Answer D, a tiny (< 1.0-cm) cavity in the pons, refers to the appearance of a lacunar infarct.

**Question 51**

**Answer: B.** Chédiak-Higashi syndrome is an autosomal recessive disorder (hence skipping generations) that causes increased susceptibility to infections because of impaired transport of bacteria from phagocytic vesicles to lysosomes. Patients can also have albinism.

**Question 52**

**Answer: B.** The thin rim of parenchyma represents subpial sparing, which rules out a contusion. The subpial parenchyma receives its nutrients from the cerebrospinal fluid and meningeal vessels and, in an infarct, will be spared; however, in a contusion, where the force is delivered to the cortical surface, the subpial parenchyma would not be spared. An active plaque in multiple sclerosis is a demyelinating process, but neurons are spared and would be present on the slide.

**Question 53**

**Answer: B.** The history is consistent with Huntington chorea. Spongiform changes would be associated with Creutzfeldt-Jakob disease (CJD).

**Question 54**

**Answer: B.** The histologic features of the tumor are consistent with a Wilms tumor. In combination with the other features the child has (i.e., mental retardation and bladder malformation), the most likely diagnosis is WAGR syndrome.

**Question 55**

**Answer: D.** The age range and clinical and autopsy findings are consistent with *Neisseria meningitidis*. The patient has Waterhouse-Friderichsen syndrome.

**Question 56**

**Answer: B.** The wedge-shaped pleural-based firm red-tan tissue is most likely a pulmonary infarct caused by a smaller pulmonary thromboembolus that occurred 24 hours prior to his saddle thromboembolus. The dead tissue at the site of the infarct would be characterized by coagulative necrosis, which is described in answer B.

**Question 57**

**Answer: D.** In general, the diagnosis of malignant neoplasms of the endocrine system requires documentation of invasion or metastases. Cellular features such as pleomorphism and mitotic figures do not consistently predict malignancy in endocrine neoplasms.

**Question 58**

**Answer: C.** Struma ovarii is a monodermal teratoma of the ovary that produces ectopic thyroid hormone. The complex cystic mass composed of both cystic and solid components that is present in this young female patient is most likely a teratoma (dermoid cyst). A patient with Graves disease would have a detectable autoantibody. A toxic goiter would be identified on ultrasound. The TSH level is not consistent with answer D, ectopic production of TSH, for example, by a small cell lung carcinoma.

**Question 59**

**Answer: B.** The question is describing a family with familial retinoblastoma. Familial retinoblastoma is caused by a mutation of the retinoblastoma (*RB*) gene, whose function is to bind E2F, thereby preventing (and subsequently controlling) progression of the cell cycle.



**Question 60**

**Answer: C.** The differentiation of follicular carcinoma from follicular adenoma (unless metastases are present) requires evaluation of the tumor for capsular or blood vessel invasion—two features that usually are not identifiable with an FNA. The nuclear features of papillary thyroid carcinoma can be easily evaluated with an FNA of a thyroid gland nodule.

**Question 61**

**Answer: A.** The initial diagnosis of chronic lymphocytic leukemia (CLL) is commonly made in patients who are being evaluated or treated for another disease process. Although most cases of CLL are B cell in origin, the neoplastic cells are positive for CD 5.

**Question 62**

**Answer: D.** The nature of the wound (i.e., large laceration), although sutured to prevent blood loss and infection, implies that it will heal, at least partially, through the process of second intention. The scar will be smaller than the original wound due to wound contraction, but will most likely be easily visible and reduced in strength.

**Question 63**

**Answer: A.** After childhood, patients with PKU can use a less restricted diet. However, in pregnant females, an uncontrolled level of phenylalanine can adversely affect fetal neurologic development; therefore, prior to and during pregnancy, women with PKU should return to a phenylalanine-free diet.

**Question 64**

**Answer: B.** The patient has a secondary cause of hypertension, an aortic coarctation. An aortic coarctation can often be identified with an appropriate physical examination, including recording of the blood pressure of both the upper and lower extremities. Once a coarctation is identified, it can potentially be treated with surgery.

**Question 65**

**Answer: D.** Infections caused by *Neisseria gonorrhoeae* or *Chlamydia trachomatis* place a patient at risk for pelvic inflammatory disease (PID). Complications of PID include ectopic pregnancy, tubo-ovarian adhesions, and infertility.

**Question 66**

**Answer: A.** HPV types 6 and 11 are associated with condyloma acuminatum. Types 16, 18, 31, 33, and 35 are associated with high-grade lesions, such as CIN II and III, which more frequently progress to invasive squamous cell carcinoma.

**Question 67**

**Answer: A.** The patient has multiple uterine leiomyomas. Uterine leiomyomas can produce pelvic pain, ulceration of overlying endometrium leading to vaginal bleeding, and infertility due to inability of uterus to expand in size, as is normally required during pregnancy. Although rare case reports of metastasizing benign leiomyomas have been reported, it is definitely *not* a common complication.

**Question 68**

**Answer: A.** Lobular carcinoma in situ is a marker that indicates the patient is at increased risk for the future development of an invasive carcinoma (either lobular or ductal carcinoma) in either breast (i.e., not necessarily in the same breast as the site of the biopsy). Therefore, some women diagnosed with lobular carcinoma in situ will voluntarily elect to undergo a prophylactic bilateral mastectomy to prevent future development of an invasive breast carcinoma.

**Question 69**

**Answer: C.** The patient has aortic stenosis. Given his relatively young age, the stenosis is most likely due to dystrophic calcification of a bicuspid aortic valve.

**Question 70**

**Answer: A.** The symptoms are suggestive of an aortic dissection. The diastolic murmur and widened pulse pressure indicates aortic regurgitation from a dilated aortic root.

**Question 71**

**Answer: A.** Patients who use NSAIDs are at risk for development of a gastric peptic ulcer. The hypotension, tachycardia, and pallor are due to an acute hemorrhagic shock. The cause of this patient's death is an acute bleeding peptic ulcer. In the setting of acute hemorrhage, hemoglobin and hematocrit are normal prior to fluid resuscitation.

**Question 72**

**Answer: C.** The EGD would most likely reveal glandular metaplasia. Smoking, excessive alcohol intake, and fatty foods are among the list of things that increase the risk for gastric reflux. Gastric reflux can lead to glandular metaplasia of the distal esophagus (i.e., Barrett esophagus).

**Question 73**

**Answer: C.** The patient most likely has megaloblastic anemia. Of the choices, atrophic gastric mucosa with focal intestinal metaplasia is the histologic description of autoimmune gastritis, which is one cause of megaloblastic anemia.

**Question 74**

**Answer: B.** Zollinger-Ellison syndrome is due to a gastrin-secreting endocrine tumor in the head of the pancreas or duodenum. These patients have a history of multiple ulcers, and ulcers in unusual locations such as the jejunum. Hypertrophic gastric folds are a classic finding in Zollinger-Ellison syndrome.

**Question 75**

**Answer: A.** Patients with delirium tremens will have confusion, disorientation, hallucinations, tremor, and signs of autonomic instability. This patient most likely has a history of surreptitious drinking. Dementia can predispose a patient to sundowning, but it is not an acute alteration in mental status.

**Question 76**

**Answer: C.** The symptoms are consistent with rheumatoid arthritis.

**Question 77**

**Answer: D.** This patient has celiac sprue. Celiac sprue is caused by sensitivity to gluten in wheat, and is treated by alteration of the diet to remove gluten-containing substances.

**Question 78**

**Answer: A.** Polyarteritis nodosa (PAN) is characterized by segmental necrotizing vasculitis of small and medium sized arteries. PAN can present with a broad constellation of findings, including renal disease but not pulmonary disease. Up to 30% of cases of PAN are associated with hepatitis B. The clinical scenario is not suggestive of Kawasaki disease. The lack of upper respiratory symptoms, including the lack of hemoptysis, and the patient's young age is less suggestive of Goodpasture syndrome. Acute pancreatitis would not easily explain his hematuria.

**Question 79**

**Answer: B.** The histologic description and location (appendix) are consistent with Crohn disease. Both Crohn disease and ulcerative colitis can have many extra-intestinal manifestations, which account for the patient's joint pain and skin lesion.

**Question 80**

**Answer: A.** The patient has neurofibromatosis type 1. The macules are café au lait spots, and the lesions on her iris are Lisch nodules. Patients with neurofibromatosis are prone to malignant degeneration of neurofibromas (especially plexiform neurofibromas) with subsequent development of a malignant peripheral nerve sheath tumor. Angiomyolipomas are associated with tuberous sclerosis.

**Question 81**

**Answer: B.** The lesion in the colon is the result of acute diverticulitis. The "apple-core" lesion seen on barium enema is the result of segmental constriction of the lumen of the colon. An "apple-core" lesion is suggestive of colonic adenocarcinoma, but can also be seen with acute diverticulitis. The segmental resection removed the area of acute inflammation, but because the patient has other diverticuli in the colon, he is at risk for another episode of diverticulitis in the future.

**Question 82**

**Answer: B.** Chronic subdural hemorrhages are known for causing psychiatric symptoms and should always be considered in elderly patients who present with such symptoms. Elderly patients and alcoholic patients are especially at risk for subdural hemorrhages, because atrophy of the brain facilitates easier tearing of the bridging veins due to less extensive head trauma.

**Question 83**

**Answer: A.** The four criteria for grading astrocytomas are mitotic figures, necrosis, angiogenesis, and pleomorphism. A low-grade astrocytoma has only pleomorphism, making the differential diagnosis between a reactive process and a low-grade astrocytoma difficult on frozen section. Mitotic figures, angiogenesis, and necrosis are more easily identified on the slide.

**Question 84**

**Answer: B.** The patient has histologic features of autoimmune hepatitis (i.e., similar histology to chronic viral hepatitis but with negative viral serologies). Autoimmune hepatitis is associated with anti-smooth muscle and anti-liver-kidney antibodies.

**Question 85**

**Answer: C.** Recurrences of ALL often involve the central nervous system. The age of the boy ( $> 12$  years), hypodiploidy, and t(9;22) translocation are all unfavorable prognostic indicators.

**Question 86**

**Answer: A.** The diagnosis of sudden infant death syndrome (SIDS) is made after complete investigation of the death, including examination of the scene of death and a full autopsy. Thymic petechial hemorrhages are nonspecific findings seen with a SIDS death. A prone sleeping position is felt to be a risk factor for SIDS.

**Question 87**

**Answer: A.** The histology describes alcoholic hepatitis (neutrophilic infiltrate, Mallory hyaline, and central vein fibrosis).

**Question 88**

**Answer: C.** The patient has chronic myelogenous leukemia (CML). Although patients with CML may have a few myeloblasts, the peripheral smear will consist mainly of more mature myelocytes, with an associated basophilia. One differential diagnosis is a leukemoid reaction (a profound reactive increase in white blood cells), but a leukemoid reaction will have an elevated leukocyte alkaline phosphatase (LAP).

**Question 89**

**Answer: B.** A painful thyroid gland is consistent with subacute (de Quervain) thyroiditis. Histologic examination of the thyroid gland in these patients will reveal multinucleated giant cells. Lymphocytes and oncocytic change are consistent with Hashimoto thyroiditis, a usually painless condition. Pseudoinclusions and optically clear nuclei are consistent with papillary thyroid carcinoma, which is usually painless.

**Question 90**

**Answer: B.** During pregnancy, the anterior pituitary gland increases in size due to hyperplasia of prolactin-producing cells. Because of the increased size of the gland, the blood supply becomes tenuous and an event that reduces the blood supply, such as an acute hemorrhage, can lead to ischemia and resultant necrosis of the gland. This damage to the gland results in decreased levels of the anterior pituitary hormones, a condition referred to as Sheehan syndrome.

**Question 91**

**Answer: A.** The patient has pseudomembranous colitis due to *Clostridium difficile* following antibiotic treatment. Flask-shaped ulcers are seen in *Entamoeba histolytica* infections.

**Question 92**

**Answer: C.** The patient has all four modifiable risk factors for atherosclerosis. The abdominal pain and subsequent shock suggest a ruptured abdominal aortic aneurysm. Despite hemorrhagic shock, the patient's heart rate remains relatively stable because of the  $\beta$  blocker.

**Question 93**

**Answer: A.** Turner syndrome is a common cause of primary amenorrhea. It is associated with coarctation of the aorta, a webbed neck, short stature, and wide-spaced nipples.

**Question 94**

**Answer: C.** The patient has Henoch-Schönlein purpura (HSP). One component of HSP is an IgA nephropathy. Other systemic manifestations, including arthritis and gastrointestinal involvement, are found in patients with Henoch-Schönlein purpura.

**Question 95**

**Answer: D.** Urinary tract infections in males, especially young males, are uncommon and are often due to an anomaly in the genitourinary tract.

**Question 96**

**Answer: C.** The question is describing two well-known complications for patients with Down syndrome, acute lymphoblastic leukemia, and duodenal atresia. Of the choices, Down syndrome is associated with increased maternal age.

**Question 97**

**Answer: C.** A pathologic fracture implies that the fracture is secondary to another lesion in the bone and not just the result of trauma. Of the tumors listed, Ewing sarcoma is the most likely to occur in the diaphysis of a long bone in a 13-year-old child.

**Question 98**

**Answer: C.** The patient has the symptoms of Guillain-Barré syndrome (ascending paralysis). If the patient's airway is managed, the symptoms will pass and there will be no residual sequelae.

**Question 99**

**Answer: B.** The histology is consistent with small cell carcinoma. Small cell carcinoma of the lung can produce ACTH, resulting in increased cortisol level, and is considered to have metastasized at the time of diagnosis. Therefore, once the diagnosis was made by frozen section, no further resection of the lung would have been performed.

**Question 100**

**Answer: C.** The patient has Kawasaki syndrome (edema of the hands and feet, cervical lymphadenopathy, oral erythema, and fever). A possible late-term complication of this disease is a coronary artery aneurysm.

**Question 101**

**Answer: B.** The patient has diffuse alveolar damage (clinically termed acute respiratory distress syndrome, or ARDS). The four main causes of diffuse alveolar damage are diffuse pulmonary infection, head trauma, sepsis, and aspiration.

**Question 102**

**Answer: B.** The patient most likely has multiple sclerosis (MS). In most cases, MS has a waxing and waning course, but the clinical history can vary from patients having one episode with no subsequent episodes to patients having multiple episodes one after the other, leaving them wheelchair bound or worse. Patients often present with visual symptoms.

**Question 103**

**Answer: B.** The question is describing a patient with Klinefelter syndrome. These patients usually have normal intelligence. They are at increased risk for breast cancer. A gynecoid habitus, breast enlargement, and long legs are common physical manifestations of Klinefelter syndrome. Coarctation of the aorta is associated with Turner syndrome.

**Question 104**

**Answer: A.** The patient has features of congestive heart failure. Given his long-standing history of hypertension, he most likely has a low-output, left-sided form of congestive heart failure with predominant systolic dysfunction.

**Question 105**

**Answer: D.** The patient most likely has sarcoidosis. In the United States, sarcoidosis is 10 times more common in African Americans than in whites. Fewer than 5% of patients with sarcoidosis have normal chest radiographs. Patients with sarcoidosis often have an elevated level of ACE. Lung involvement is more serious than lymph node involvement, and the disease can affect many other organs, including the skin and heart. Sarcoidosis may be associated with hypercalcemia due to secretion of 1,25-OH-vitamin D, and the histology is noncaseating granulomas.

**Question 106**

**Answer: E.** Granulosa cell tumors produce large amounts of estrogen. Elevated levels of estrogen are risk factors for breast carcinoma and endometrial adenocarcinoma. Complex hyperplasia of the endometrium is a risk factor for endometrial adenocarcinoma and can result from prolonged elevated levels of estrogen. Either hyperplasia of the uterus or endometrial adenocarcinoma can present with vaginal bleeding.



**Question 107**

**Answer: C.**  $\beta$ -Thalassemia is found in people of Mediterranean and African descent. Patients with  $\beta$ -thalassemia major have severe disease and, from childhood, are dependent upon transfusions. This patient has a hypochromic microcytic anemia, and may have either iron deficiency, thalassemia minor, or both, based on her history. The Meltzer index may be useful in distinguishing iron deficiency from thalassemia minor, but in this patient with menorrhagia and a family history of anemia, it would be of questionable use. In  $\beta$ -thalassemia, the excess  $\alpha$  chains pair with  $\delta$  chains, resulting in elevated hemoglobin A<sub>2</sub>.

**Question 108**

**Answer: C.** The patient has Alzheimer disease, which is characterized by the intracellular accumulations of tau protein.

**Question 109**

**Answer: C.** Both vitamin B<sub>12</sub> and folate deficiency will cause a megaloblastic anemia. A vitamin B<sub>12</sub> deficiency (not a folate deficiency) is associated with neurologic symptoms. If a patient with a vitamin B<sub>12</sub> deficiency is treated with folate supplementation, the treatment will resolve the anemia, but it will not prevent the effects of vitamin B<sub>12</sub> deficiency on the nervous system. In alcoholics or otherwise malnourished patients with altered mental status, supplementation with both vitamin B<sub>12</sub> and thiamine is advisable. Always give thiamine before dextrose in the DONT algorithm (dextrose, oxygen, naloxone, thiamine), because a large glucose load in a thiamine-deficient patient will acutely increase the metabolic need for thiamine and may precipitate Korsakoff syndrome.

**Question 110**

**Answer: A.** In multiple myeloma, the patient would almost always have an M spike (unless the clone was a nonsecretor) and osteolytic bone lesions. In MGUS, the patient has an M spike, but not osteolytic bone lesions. Patients with MGUS and those with a solitary plasmacytoma can later develop multiple myeloma.

**Question 111**

**Answer: A.** The image depicts a neurofibrillary tangle, characteristic of Alzheimer disease.

**Question 112**

**Answer: C.** The image depicts a stable atherosclerotic plaque in a coronary artery, causing > 75% stenosis. The patient most likely died of an arrhythmia related to his cardiac disease. An acute myocardial infarction would be associated with acute plaque change such as rupture or hemorrhage, resulting in occlusion of the vessel.

**Question 113**

**Answer: C.** The image depicts a gallstone in the cystic duct. One of the two main causes of acute pancreatitis is a gallstone. If this gallstone had become lodged in the common bile duct (choledocholithiasis), obstruction would have resulted in gallstone pancreatitis.

**Question 114**

**Answer: A.** The image depicts cervical intraepithelial neoplasia (CIN) grade I. The dysplastic changes only involve the lower third of the mucosa. Within the upper layers of mucosa can be seen several koilocytes. CIN I is associated with low-grade types of HPV, such as type 6.

**Question 115**

**Answer: C.** The image depicts cirrhosis. Patients with cirrhosis are prone to develop esophageal varices, which can lead to fatal gastrointestinal hemorrhages.

**Question 116**

**Answer: C.** The image depicts chronic myelogenous leukemia (CML). Patients with CML will have a decreased or normal leukocyte alkaline phosphatase (LAP) level, which helps distinguish the condition from a leukemoid reaction, in which patients will have an elevated LAP.

**Question 117**

**Answer: A.** The enlarged cells with the large intranuclear inclusion with a clear peripheral halo are characteristic of infection with cytomegalovirus.

**Question 118**

**Answer: B.** The image depicts hyaline membranes in the lung, characteristic of diffuse alveolar damage (histologic correlate of acute respiratory distress syndrome). Metastatic neoplasms are *not* a common cause of diffuse alveolar damage.

**Question 119**

**Answer: B.** The image depicts pulmonary emphysema. The most common cause of pulmonary emphysema is tobacco use.

**Question 120**

**Answer: D.** The image depicts a small epidural hemorrhage. The fracture line in the temporal bone involves the distribution of the middle meningeal artery.

**Question 121**

**Answer: B.** The image depicts fatty emboli (vessel in center of image). Patients with fatty emboli usually develop dyspnea, mental status changes, and petechial hemorrhages shortly (within a few days) after a motor vehicle accident in which long bones are fractured.

**Question 122**

**Answer: A.** The image depicts myocardial disarray, which is the characteristic histologic feature of hypertrophic cardiomyopathy.

**Question 123**

**Answer: C.** In the center of the image is a Reed-Sternberg cell, which is characteristic of Hodgkin lymphoma.

**Question 124**

**Answer: C.** The vessel with the thick acellular eosinophilic wall is characteristic of hyaline arteriosclerosis.

**Question 125**

**Answer: A.** The glomerulus has nodular glomerulosclerosis (Kimmelstiel-Wilson lesion), which is characteristic of diabetes mellitus.

**Question 126**

**Answer: C.** The hepatocyte in the center of the image has Mallory hyaline (the ropy, eosinophilic condensation in the cell). In combination with the macrovesicular and microvesicular steatosis, of the choices given, the Mallory hyaline is most likely due to alcohol use.

**Question 127**

**Answer: B.** The tumor is a papillary thyroid carcinoma (note the optically clear, overlapping nuclei). Another common histologic feature of papillary thyroid carcinoma is psammoma bodies.

**Question 128**

**Answer: C.** Although patients with autosomal dominant polycystic kidney disease can have an associated berry aneurysm, the most common cause of death for these patients is chronic renal failure.

**Question 129**

**Answer: B.** The yellow (glycogen) and red (hemorrhage) coloration of this tumor are characteristic gross features of renal cell carcinoma.

**Question 130**

**Answer: C.** The patient has pseudomembranous colitis, which is most frequently the result of a course of antibiotic therapy that unintentionally causes the death of gut flora and allows overgrowth of *Clostridium difficile*.

*This page intentionally left blank*



# INDEX

Page numbers followed by “*f*” indicate figures; page numbers follow by “*t*” indicate tables.

- Abnormal uterine bleeding, 320
- Abortion, 326–327
- Abrasions, 50, 50*f*
- Absence seizures, 137
- Acalculous cholecystitis, acute, 278
- Acanthosis nigricans, 323, 382, 382*f*
- Achalasia, 236
- Achondroplasia, 361–362
- Acid-base disorders
  - metabolic acidosis, 305*t*, 306
  - metabolic alkalosis, 305*t*, 306
  - respiratory acidosis, 305, 305*t*
  - respiratory alkalosis, 305, 305*t*
- Acidophil bodies, 270
- Acoustic schwannoma, 57
- Acquired Immunodeficiency Syndrome (AIDS), 33–34
- Acromegaly, 339
- ACTH. *See* Adrenocorticotrophic hormone
- ACTH-secreting adenoma, 339
- Acute disseminated encephalomyelitis, 168
- Acute fatty liver of pregnancy, 265
- Acute interstitial pneumonia, 220
- Acute lymphoid leukemia (ALL), 191–192, 191*t*, 192*f*, 403, 418
- Acute multiple sclerosis (Marburg), 167
- Acute myeloid leukemia (AML), 193–194, 193*t*, 194*f*
  - megakaryoblastic, 66, 194
  - myelomonocytic, 194
  - promyelocytic, 194, 194*f*, 207
- Acute necrotizing hemorrhagic encephalomyelitis, 168
- Acute respiratory distress syndrome (ARDS), 210, 215
- Acute tubular necrosis, 90–91, 298, 298*f*
- Addison disease, 286, 356, 357*f*
- Adenocarcinoma
  - colonic, 257–258, 257*f*–258*f*
  - endometrial, 321–322, 321*f*
  - esophageal, 240
  - gallbladder, 279
  - gastric, 244–245, 244*f*–245*f*
  - pancreatic, 281
  - prostatic, 315–316, 315*f*
  - pulmonary, 227, 227*f*–228*f*
- Adenomas
  - adrenal, 358
  - fibroadenoma, 332, 332*f*
  - hepatic, 277
  - intestinal, 256–257, 256*f*
  - liver, 277
  - parathyroid, 8, 349*t*, 350, 350*f*
  - pituitary, 338*f*, 339
  - pleomorphic, 234–235, 235*f*
  - thyroid follicular, 347–348, 348*f*
- Adenoma sebaceum, 58
- Adenomyosis, 319, 319*f*
- ADPKD (autosomal dominant polycystic kidney disease), 302, 302*f*
- Adrenal disorders
  - Addison disease, 356, 357*f*
  - adenoma, 358
  - congenital adrenal hyperplasia, 357
  - Cushing syndrome, 354–355, 355*f*, 355*t*
  - hyperaldosteronism, 358
  - hypoadrenalism, 356, 356*f*–357*f*
  - neoplasms, 358–360, 359*f*
    - adrenal adenoma, 358
    - adrenocortical carcinoma, 358
    - multiple endocrine neoplasia, 359–360
    - pheochromocytoma, 358–359, 359*f*
- Adrenocortical carcinoma, 358
- Adrenocorticotrophic hormone (ACTH), 40, 338–339, 354–358, 355*t*
- Adult T-cell leukemia/lymphoma, 202
- Agyria, 141
- AIDS (acquired immunodeficiency syndrome), 33–34
- Alanine aminotransferase, 261, 262*t*
- Alcoholic liver disease. *See also* Hepatitis
  - hepatic stenosis, 271, 271*f*
  - Mallory hyaline, 9, 9*f*, 271*f*, 272
- Alcohol withdrawal, 48, 402, 417
- Alkaline phosphatase, 261, 262*t*
- Alkaptonuria, 61
- ALL. *See* Acute lymphoid leukemia
- Allergic asthma, 212
- ALP (alkaline phosphatase), 261, 262*t*
- Alobar holoprosencephaly, 140
- $\alpha$ -Fetoprotein, 44*t*, 45*t*, 311, 311*f*
- $\alpha$ -Thalassemia, 177–178
- $\alpha$ -Thalassemia trait, 177
- $\alpha_1$ -Antitrypsin deficiency, 58, 211, 267, 273
- Alport syndrome, 290, 296
- ALS (amyotrophic lateral sclerosis), 166
- ALT (alanine aminotransferase), 261, 262*t*
- Alzheimer disease, 9, 162–163, 163*f*–164*f*
- Amenorrhea, 318–319
- AML. *See* Acute myeloid leukemia
- Amnesia, 135–136
- Amniotic band syndrome, 71
- Amniotic fluid embolus, 87
- Amyloid, 31, 31*t*, 32*f*, 130, 242, 353, 353*f*
- Amyloidosis, 31, 31*t*, 32*f*
- Amyotrophic lateral sclerosis (ALS) (Lou Gehrig disease), 166
- Anaphylactic shock, 24, 90
- Anaplastic carcinoma of the thyroid, 349, 349*f*
- Anasarca, 83, 288

- ANCA (antineutrophilic cytoplasmic antibody)  
 c-ANCA, 102, 105, 294  
 p-ANCA, 102, 105, 274  
 ANCA-mediated vasculitis, 102  
 Anemia, 173–187, 174*t*  
   aplastic, 180–181, 180*f*  
   clinical presentation of, 176  
   hemolytic, 181–187, 184*t*  
   macrocytic (megaloblastic), 179–180, 180*f*, 180*t*  
   microcytic, 176–178, 176*f*, 176*t*, 178*f*  
   morphology of, 175  
   myelophthisic, 181, 181*f*  
   paroxysmal nocturnal hemoglobinuria (PNH), 175  
   pure red cell aplasia, 181, 181*f*  
   sickle cell, 186–187, 186*f*  
 Anemia of chronic disease, 176*t*, 178  
 Anencephaly, 139, 140*f*  
 Aneurysm, 95, 100–101, 100*f*, 101*f*, 119, 121*f*  
   berry, 148, 150*f*, 302  
 Angelman syndrome, 68  
 Angina  
   stable, 113–114, 114*f*  
   unstable, 113–117, 115*f*  
   variant, 115  
 Angiodysplasia, 254  
 Angiomyolipoma, 58  
 Angiosarcoma  
   liver, 277  
   vascular, 107  
 Anhidrosis, 228  
 Ankylosing spondylitis, 27, 375  
 Anorexia, 51  
 Antibody  
   anti-centromere, 27*t*, 30  
   anti-desmoglein-3, 386, 387*t*  
   anti-dsDNA, 27*t*, 28  
   anti-endomysial, 249  
   anti-gliadin, 249, 387, 387*t*  
   anti-hemidesmosome, 386, 387*t*  
   anti-histone, 27*t*, 28  
   anti-liver/kidney, 270  
   anti-mitochondrial, 273  
   anti-scl70, 27*t*, 30  
   anti-smooth muscle, 270  
   anti-SSA/SSB, 27*t*, 30  
 Antibody-mediated red blood cell destruction  
   ABO incompatibility, 182–183  
   blood transfusion reactions, 183  
   cold autoimmune hemolytic anemia, 184–185, 184*t*  
   erythroblastosis fetalis, 183  
   isohemagglutinin reaction, 182  
   warm autoimmune hemolytic anemia, 184, 184*t*  
 Anticipation, 164  
 Antineutrophilic cytoplasmic antibody. *See* ANCA  
 Antiphospholipid antibody syndrome, 29  
 Aortic disorders  
   coarctation, 112–113, 112*f*, 125  
   dissection, 98–99, 99*f*, 100*f*, 125  
 Aortic valvular disorders  
   regurgitation  
     acute, 122*f*, 126–127  
     chronic, 126–127  
   stenosis, 112, 125–126  
     congenital bicuspid aortic valve degenerative calcification, 125, 126*f*  
     pulsus parvus et tardus, 126  
     rheumatic valvulitis, chronic, 125  
     tricuspid aortic valve degenerative calcification, 125, 125*f*  
 APC/ $\beta$ -catenin, 41*t*, 43–44  
 Aphasia, 135  
 Aplastic anemia, 180–181, 180*f*  
 Apoptosis, 5–6, 5*f*  
 Apoptosis genes, 44  
 Appendicitis, acute, 256, 256*f*  
 ARDS (acute respiratory distress syndrome), 210, 215  
 Argyll-Robertson pupils, 76  
 ARPKD (autosomal recessive polycystic kidney disease), 302–303  
 Arteriosclerosis, 93, 98, 98*f*  
 Arteriosclerosis, 93  
 Arteriovenous fistula, 101  
 Arteriovenous malformation, 141  
 Arthritis, 373*t*  
   osteoarthritis, 373–374, 374*f*, 375*t*  
   rheumatoid, 29–30, 374–375, 375*f*, 375*t*  
 Asbestosis, 217–218, 218*f*  
 Ascending acute cholangitis, 279  
 Aschoff nodules, 124  
 ASD (atrial septal defect), 111–112, 112*f*  
 Asherman syndrome, 318  
 Ash-leaf patches, 58  
 Aspartate aminotransferase (AST), 261, 262*t*  
*Aspergillus flavus*, 276  
 Aspiration pneumonia, 224, 224*f*–225*f*  
 AST (aspartate aminotransferase), 261, 262*t*  
 Asterixis, 266  
 Asteroid bodies, 219, 220*f*  
 Asthma, 106, 212–213, 213*f*–214*f*  
   allergic, 212  
   mast cell tryptase, 213  
   morphology, 213, 213*f*  
   nonallergic, 212  
 Astrocytic reactions, 137  
 Astrocytomas, 158–159, 158*f*–159*f*  
   grading criteria, 158  
   pilocytic, 159, 159*f*  
 Asymptomatic hematuria, 295–296  
   Alport syndrome, 296  
   Henoch-Schönlein purpura, 296  
   IgA nephropathy, 295–296  
 Ataxia-telangiectasia, 41*t*  
 Atelectasis  
   compressive, 210, 210*f*  
   contraction, 210  
   microatelectasis, 210  
   obstructive, 210

- Atherosclerosis, 48, 93–95, 97  
     complications of, 95  
         aneurysm, 95  
         emboli, 95  
         peripheral vascular disease, 95  
     vessels affected by, 94, 94*f*
- Atrial myxoma, 132
- Atrial septal defect (ASD), 111–112, 112*f*
- Atrophy, 2
- Atypical adenomatous hyperplasia, 227
- Auer rods, 194, 194*f*
- Auspitz sign, 385
- Autoimmune disease(s)  
     CREST syndrome, 27*t*, 30  
     hemolytic anemias, 184–185, 184*t*  
     hepatitis, 270–271  
     mixed connective tissue disorder, 30  
     Sjögren syndrome, 30, 30*f*  
     systemic lupus erythematosus (SLE), 28–29, 29*f*, 131*t*, 132  
     systemic sclerosis, 30
- Autosomal disorders  
     dominant, 55–58, 56*f*–58*f*, 56*t*  
     recessive, 58–62, 59*t*
- Autosomal dominant polycystic kidney disease (ADPKD),  
     302, 302*f*
- Autosomal recessive polycystic kidney disease (ARPKD),  
     302–303
- Avascular necrosis. *See* Osteonecrosis
- Axonal neuropathy, 169
- Azotemia, 283–285  
     intrinsic, 284  
     postrenal, 284  
     prerenal, 284
- B<sub>12</sub> deficiency, 52, 179–180, 180*t*
- Bacillary angiomatosis, 34
- Bacterial meningitis, 151–153, 152*f*
- Baló disease, 167
- Barrett esophagus, 3, 3*f*, 238, 238*f*
- Basal cell carcinoma, 383, 383*f*–384*f*
- Basal cell nevus syndrome, 383
- bcl-2, 44, 197*t*, 200
- Becker muscular dystrophy, 65
- Beckwith-Wiedemann syndrome, 80
- Bence-Jones proteins, 203, 203*f*
- Benign prostatic hyperplasia, 314, 314*f*
- Berger disease. *See* IgA nephropathy
- Berry aneurysm, 148, 150*f*, 302
- β-Thalassemia, 177–178, 178*f*
- Bicuspid aortic valve, 125, 126*f*
- Biliary pain, 278
- Biliary tract disorders, obstructive, 273–274, 274*f*, 274*t*
- Bisferious pulse, 127
- Bite cells, 187
- Bitemporal hemianopsia, 339
- Bladder, ureter disorders  
     ureter obstruction, 305  
     urothelial neoplasm, 304–305, 304*f*–305*f*
- Blistering diseases of the skin, 387*t*  
     bullous pemphigoid, 386–387  
     dermatitis herpetiformis, 249, 387  
     pemphigus, 386
- Blueberry muffin baby, 76
- Boerhaave syndrome, 236
- Bone, joint disorders  
     ankylosing spondylitis, 27, 375  
     arthritis, 373, 373*t*  
     fractures, 367, 367*f*  
     gout, 375–377, 376*f*  
     inherited diseases, 361–363  
     osteoarthritis, 373–374, 374*f*  
     osteodystrophy, renal, 366–367  
     osteomyelitis, 364–365, 365*f*  
     osteonecrosis, 364  
     osteoporosis, 363–364  
     Paget disease, 365–366, 366*f*  
     pseudogout, 377  
     rheumatoid arthritis, 29–30, 374–375, 375*f*, 375*t*  
     tumors, 367–372, 368*t*  
         chondroma, 368*t*, 370  
         chondrosarcoma, 368*t*, 370–371, 371*f*  
         giant cell tumor, 368*t*, 372, 372*f*  
         metastases, 37, 39*f*–40*f*, 372–373  
         osteochondroma, 368*t*, 370, 370*f*  
         osteoid osteoma/osteoblastoma, 368–369  
         osteoma, 368, 368*t*  
         osteosarcoma, 41*t*, 368*t*, 369, 369*f*  
         primitive neuroectodermal (PNET), 78, 368*t*,  
             372, 372*f*
- Bouchard nodes, 374
- Bowen disease, 313
- Brain. *See* Central Nervous System; Neuropathology  
     abscess, 153–154, 154*f*
- Brainstem glioma, 159
- BRCA1/BRCA2, 38, 334
- Breast carcinoma, 334–336, 335*f*  
     colloid, 335, 336  
     inflammatory, 335  
     invasive ductal, 335  
     invasive lobular, 335, 336  
     medullary, 335, 336  
     tubular, 335, 336
- Breast diseases, nonneoplastic, 331*t*  
     fibroadenoma, 331*t*, 332, 332*f*  
     fibrocystic change, 331–332, 331*t*, 332*f*  
     intraductal papilloma, 333, 333*f*  
     mastitis, acute, 331  
     phyllodes tumor, 332–333  
     sclerosing adenosis, 331*t*, 332
- Brenner tumor, 325, 326*f*
- Breslow depth, 381
- Bridging necrosis, 262
- Broca aphasia, 135
- Brodie abscess, 365
- Bronchiectasis, 214–215, 215*f*
- Bronchioalveolar carcinoma, 227



- Bronchitis, chronic, 214  
 Bronchopneumonia, 222, 222f  
 Bronchopulmonary dysplasia, 75  
 Brown tumors, 350  
 Brudzinski sign, 153  
 Budd-Chiari syndrome, 196, 275  
 Buerger disease. *See* Thromboangiitis obliterans  
 Bulimia, 52  
 Bullous pemphigoid, 386–387  
 Burkitt lymphoma, 38, 43, 78, 78t, 201, 201f
- Cachexia, 39  
 Café-au-lait spots, 57  
 Calcium oxalate/phosphate kidney stones, 301  
 Calcium pyrophosphate crystal deposition.  
     *See* Pseudogout  
 Calculous cholecystitis, acute, 278, 279f  
 Call-Exner bodies, 326  
 c-ANCA, 102, 105, 294  
 Cancer. *See also* Neoplasm/neoplasia; *specific types of*  
     Tumors  
 Cancer stem cells, 37  
 CA-125, 44t  
 Capillary angioma, 142  
 Caplan syndrome, 375  
 Caput medusae, 267  
 Carcinogenesis. *See also* Neoplasm/neoplasia  
     apoptosis genes, 40, 44  
     DNA repair defects, 45  
     DNA repair genes, 40  
     initiators, 40  
     nuclear transcription factors, 42–43  
     oncogenes role, 42  
     promoters, 40  
     proto-oncogene conversion, 42  
     proto-oncogenes, 40, 42–43  
     tumor suppressor genes, 40, 43–44  
     two-hit hypothesis, 43  
 Carcinoid syndrome, 259  
 Carcinoid tumor, 258–259, 259f  
 Carcinoma ex pleomorphic adenoma, 135  
 Carcinoma in situ, breast  
     ductal (DCIS), 333–334, 333f–334f  
     lobular (LCIS), 334  
 Cardiac death, sudden, 120  
 Cardiac disorders  
     aortic valvular disease, 125–127, 125f–126f  
     cardiomyopathies, 128–130, 129f–130f  
     congenital heart disease, 110–113, 111–112f  
     congestive heart failure, 9, 109, 121–122  
     coronary syndromes, acute, 116  
     endocarditis, 122–124, 122f–123f  
     hypertensive cardiovascular disease, 120  
     ischemic heart disease, 113–115, 114f–115f, 120, 121f  
     mitral valvular disease, 127–128, 128f  
     myocardial infarcts, 116–120, 116f, 117t, 119t,  
         118f–120f  
     pericardial disease, 119, 119t, 131–132, 131f–132f, 131t  
         rheumatic fever, 124–125, 124t, 124f–125f  
         sudden death, 120  
         tumors, 132  
 Cardiac tamponade, 132  
 Cardiogenic shock, 89, 118, 118f  
 Cardiomyopathies, 128  
     dilated, 48, 60, 129, 129f, 130  
     hypertrophic, 129, 129f  
     restrictive, 130, 130f  
 Caspases, 5  
 Casts  
     red blood cell, 292  
     white blood cell, 299  
 Catalase, 4  
 Cavernous angioma, 142  
 CD markers of leukemia, lymphoma, 190, 191t,  
     192–193, 197t, 200–202  
 CD10, 191, 191t  
 CD99, 372, 372f  
 CD117, 245  
 Celiac sprue, 249  
 Cellular disorders  
     accumulations, 7–10  
         calcium, 8, 8f  
         cholesterol, 10  
         fat, 9, 9f  
         glycogen, 10  
         iron, 9, 9f  
         lipofuscin, 7–8, 8f  
         pigments 10, 10f–11f  
         protein, 9, 9f  
     aging, 11  
     apoptosis, 5–6, 5f  
     atrophy, 2, 2f  
     death, 5–7  
         apoptosis, 5–6, 6f  
         necrosis, 6–7, 6f–7f  
     hyperplasia, 1  
     hypertrophy, 2, 2f  
     hypoplasia, 2  
     injury, 3–5  
         cellular system vulnerability, 3  
         chemical injury, 4  
         electron microscope morphologic changes, 5  
         free radicals, 4  
         hypoxia, 3–4  
         irreversible, 5  
         ischemia, 3  
         light microscope morphologic changes, 5  
         mitochondrial cytosolic calcium, 4  
         reactive oxygen species, 4  
         reversible, 4  
     metaplasia, 3, 3f  
     necrosis, 6–7, 6f–7f  
 Cellular rejection, 26, 26f  
 Central nervous system (CNS). *See also* Neuropathology  
     infections, 150  
         abscess, 153–154, 154f

- encephalitis, 154–155, 155*f*
- meningitis, 151–153, 152*f*–153*f*, 151*t*, 154*t*
- malformations
  - associated with hydrocephalus, 140
  - forebrain developmental disorders, 140–141
  - neural tube defects, 139–140, 140*f*
  - neuronal migration disorders, 141
- morphologic changes
  - astrocytic reactions, 137
  - microglial reactions, 137
  - neuronal, 137, 137*f*
- tumors, 156–157, 156*t*
  - astrocytoma, 158, 158*f*, 403, 418
  - brainstem glioma, 159
  - clinical presentation, 157
  - ependymoma, 159
  - lymphoma, 34, 160–161, 161*f*
  - medulloblastoma, 160, 161*f*
  - meningioma, 161, 162*f*
  - oligodendroglioma, 159, 160*f*
  - pilocytic astrocytoma, 159, 159*f*
- Central pontine myelinolysis, 168
- Centriacinar emphysema, 211
- Centrilobular necrosis, 90, 90*f*
- Cerebellar tonsillar herniation, 82, 138, 138*f*
- Cerebral amyloid angiopathy, 145
- Cerebral cortex, subpial sparing, 399, 416
- Cerebral edema, herniation, 82, 138–139, 138*f*
  - cerebellar tonsillar, 82, 138, 138*f*
  - cingulate (subfalcine), 82, 139
  - cytotoxic edema, 138
  - Duret hemorrhage, 139, 139*f*
  - transcalvarial, 139
  - uncal (transtentorial) 82, 139, 139*f*
  - vasogenic edema, 138
- Cerebral infarcts, 143*t*
  - borderzone, 144
  - hemorrhagic, 143
  - lacunar, 145, 146*f*
  - morphology of, 143–144
  - nonhemorrhagic, 143
- Cervical intraepithelial neoplasia, 38, 41*t*, 42*f*, 316–317, 317*f*
- C5a, 14*t*, 16
- C5b, 14*t*, 16
- Chalkstick-type fracture, 366
- Chancre, 76
- Charcot-Bouchard aneurysm, 145
- Charcot-Leyden crystals, 213
- Charcot triad, 279
- Chédiak-Higashi syndrome, 17
- Chemical injury, 4
- Chemical meningitis, 151
- Chemotaxis, 16
- Cheyne-Stokes respirations, 139
- Chiari syndrome, types I and II, 140
- Chocolate cyst, 320
- Cholangiocarcinoma, 276, 277*f*
- Cholecystitis, chronic, 278–279
- Cholelithiasis, 277–278, 279*f*
- Cholestasis/jaundice, 11, 262–265, 262*f*, 263*t*, 264*f*
  - neonatal, 264
- Chondroma, 368*t*, 370
- Chondrosarcoma, 368*t*, 370–371, 371*f*
- Choreiform movement, 164
- Chorioamnionitis, 327
- Choriocarcinoma, 44*t*, 312, 312*f*, 327–329, 328*t*
- Choristoma, 36
- Chromophobe renal cell carcinoma, 303
- Chronic granulomatous disease, 16–17
- Chronic lymphoid leukemia (CLL), 192–193, 191*t*, 193*f*, 200
- Chronic myeloid leukemia (CML), 194–195, 195*f*
- Chronic obstructive pulmonary disease (COPD), 210, 215
- Chronic passive congestion
  - of liver, 84, 84*f*
  - of lung, 83, 83*f*
- Churg-Strauss syndrome, 106
- Chvostek sign, 350
- Cingulate (subfalcine) herniation, 82, 139
- Circulatory disorders, liver, 274–275
- Cirrhosis, 9, 48, 58, 60, 82, 262, 262*t*, 266–268, 266*t*, 266*f*–268*f*
  - ascites in, 267, 268*f*
  - cryptogenic cirrhosis, 267
  - esophageal varices in, 267, 267*f*
  - hepatocellular dysfunction in, 267
  - portal hypertension in, 267, 267*f*
  - primary biliary, 273–274, 274*f*, 274*t*
  - spontaneous bacterial peritonitis, 267, 268*f*
- CK-MB (creatin kinase-MB), 117
- Claudication, 95
- Clear cell adenocarcinoma of vagina, 316
- Clear cell renal cell carcinoma, 303, 303*f*
- CLL. *See* Chronic lymphoid leukemia
- Clostridium difficile*, 247
- CML (chronic myeloid leukemia), 194–195, 195*f*
- CMV. *See* Cytomegalovirus
- CNS. *See* Central nervous system
- Coarctation of the aorta, 112–113, 112*f*, 125
- Codman triangle, 369
- Cold hemolysin hemolytic anemia, 185
- Collapsing variant of focal segmental glomerulosclerosis (FSGS), 290
- Colonic adenocarcinoma, 39*f*–40*f*, 41*t*, 44, 44*t*, 257–258, 257*f*–258*f*
- Coma, 134–135
- Common variable immunodeficiency, 32
- Community-acquired atypical pneumonia, 223–224, 224*f*
- Community-acquired typical pneumonia, 222–223, 222*f*–223*f*
- Compressive atelectasis, 210, 210*f*
- Concussion, 150
- Condyloma lata, 76
- Congenital bicuspid aortic valve degenerative calcification, 125, 126*f*
- Congenital disorders
  - adrenal hyperplasia, 357
  - anomalies, 71–73

Congenital disorders (*continued*)

heart disease  
 aortic coarctation, 112–113, 112*f*, 125  
 aortic stenosis, 112  
 atrial septal defect (ASD), 111–112, 112*f*  
 atrioventricular defect, 112  
 patent ductus arteriosus (PDA), 112  
 tetralogy of Fallot, 110  
 totally anomalous pulmonary venous return, 111  
 transposition of the great vessels, 111  
 tricuspid atresia, 110–111  
 truncus arteriosus, 111  
 ventricular septal defect (VSD), 111, 111*f*  
 pyloric stenosis, 232  
 rubella, 76  
 syphilis, 76  
 Congestive heart failure, 9, 82, 109, 121–122  
 left-sided, 121–122  
 right-sided, 121–122  
 Consciousness disorders, 133–135  
 coma, 134–135  
 confusion, 133  
 drowsiness, 133  
 stupor, 134  
 Constipation/ diarrhea  
*Entamoeba histolytica* infection, 247, 247*f*  
 mechanism, 245–246, 245*t*, 246*f*  
 pseudomembranous colitis, 247, 247*f*  
 Contraction atelectasis, 210  
 Contrecoup contusion, 149, 151*f*  
 Contusions, 50, 50*f*, 149, 151*f*  
 Coombs test, 182  
 COPD (chronic obstructive pulmonary disease), 210, 215  
 Cor pulmonale, 211  
 Corrigan pulse, 127  
 Coup contusion, 149  
 Courvoisier sign, 281  
 Cowden syndrome, 44  
 Coxsackie B virus, 130, 130*f*, 131  
 Craniopharyngioma, 341  
 Creatine kinase-MB (CK-MB), 117  
 Creeping fat, 251, 252  
 Crescentic glomerulonephritis. *See* Rapidly progressive glomerulonephritis  
 CREST syndrome, 27*t*, 30  
 Cretinism, 345  
 Creutzfeldt-Jakob disease, 155  
 Cri-du-chat syndrome, 67  
 Crigler-Najjar syndrome, 263*t*, 264  
 Crohn disease, 250–252, 250*t*, 251*f*  
 Crooke hyaline change, 355  
 Crypt abscesses, 252  
 Cryptococcal meningitis, 152, 153*f*  
 Cryptogenic cirrhosis, 267, 272  
 Cryptorchidism, 310  
 Curling ulcer, 243  
 Curschmann spirals, 213  
 Cushing disease, 354

Cushing syndrome, 40, 354–355, 355*f*, 355*t*  
 Cushing ulcer, 243  
 Cutaneous squamous cell carcinoma, 382–383  
 Cyclin-D1, 197*t*, 202  
 Cystic fibrosis, 59, 59*t*  
 Cystic medial degeneration, 57, 99, 100*f*  
 Cystic renal diseases  
 autosomal dominant polycystic kidney (ADPKD), 302, 302*f*  
 autosomal recessive polycystic kidney (ARPKD), 302–303  
 cystic renal dysplasia, 302  
 simple cysts, 302  
 Cystic teratoma, mature, 325–326, 327*f*  
 Cystitis, 298–299  
 Cytomegalovirus (CMV), 33*f*, 34, 76, 226  
 Cytotoxic edema, 138  
 DCIS. *See* Ductal carcinoma in situ  
 Degenerative joint disease. *See* Osteoarthritis  
 Dehiscence, 21  
 Delirium tremens, 48  
 Dementia, 162  
 Demyelinating disorders, 166  
 central pontine myelinolysis, 168  
 disseminated encephalomyelitis, acute, 168  
 multiple sclerosis, 167–168, 167*f*  
 necrotizing hemorrhagic encephalomyelitis, acute, 168  
 progressive multifocal leukoencephalopathy, 168  
 De novo 5q- syndrome, 189  
 Denys-Drash syndrome, 80  
 Dependent edema, 83  
 De Quervain thyroiditis, 346–347  
 Dermatitis herpetiformis, 387, 387*t*  
 Dermatomyositis/polymyositis, 170  
 Dermatopathology  
 blistering diseases. *See* Blistering diseases of the skin  
 inflammatory dermatoses  
 acute, 383–385, 384*f*–385*f*  
 chronic, 385–386, 386*f*  
 inherited skin neoplasia syndromes, 383  
 melanocytic nevus, 380, 380*f*  
 melanocytic proliferations, 380–382, 380*f*–382*f*  
 nonmelanocytic lesions, 382–383, 383*f*–384*f*  
 other skin diseases  
 infectious, 388  
 inflammatory, 387–388  
 pigment disorders, 379–380  
 systemic disease, cutaneous manifestations, 389  
 DES (diethylstilbestrol), 316  
 Devic disease, 167  
 Diabetes insipidus, 286, 307, 342  
 Diabetes mellitus, 9, 60, 72, 291–292, 292*f*, 295, 295*f*, 351, 363  
 DKA, 351–352, 351*t*  
 type 1, 351, 351*t*  
 type 2, 352–354, 353*f*–354*f*  
 Diabetic ketoacidosis (DKA), 351–352, 351*t*  
 Diabetic nephropathy, 291–292, 292*f*  
 Diamond-Blackfan syndrome, 181  
 DIC. *See* Disseminated intravascular coagulation



- Diethylstilbestrol, 316  
 Diffuse alveolar damage, 90, 215–216, 216f  
 Diffuse axonal injury, 149–150, 151f  
 Diffuse large B-cell lymphoma (DLBCL), 197t, 200–201, 201f  
 Diffuse Lewy body disease, 163  
 Diffuse pulmonary hemorrhage, 220–221  
 DiGeorge syndrome, 66–67  
 Dilated cardiomyopathy, 48, 60, 129, 129f, 130  
 Dimorphic fungi, 225  
 Direct antibody interaction-mediated vasculitis, 102  
 Disaccharidase deficiency, 248–250  
 Disseminated intravascular coagulation(DIC), 185, 206–207, 207f, 280, 280f  
 Diverticular disease, 254–255, 254f–255f  
 Diverticulitis, 255  
 Dizziness, 136  
 DKA (diabetic ketoacidosis), 351–352, 351t  
 DLBCL. *See* Diffuse large B-cell lymphoma  
 DNA repair defects, 45  
 Donath-Landsteiner antibody, 185  
 Down syndrome, 65–66, 66f, 112, 194, 232, 346  
 DPC4, 44  
 Dressler syndrome, 119  
 Drop metastases, 160  
 Drug-induced lupus, 29  
 Drug interactions, liver, 271  
 Dry beriberi, 52  
 Dubin-Johnson syndrome, 263t, 264  
 Duchenne muscular dystrophy, 64–65, 129  
 Ductal carcinoma in situ (DCIS), 331t, 333–334, 333f–335f  
 Duodenal atresia, 232  
 Dupuytren contracture, 374  
 Duret hemorrhage, 139, 139f  
 Dwarfism, 362  
 Dysgerminoma, 326  
 Dysplastic nevus, 380–381, 381f, 383  
 Dysplastic nevus syndrome, 383  
 Dyspnea, 109, 121  
 Dystrophic calcification, 8, 8f, 125f
- EBV. *See* Epstein-Barr virus  
 Ecchymoses, 84  
 Eclampsia. *See* Toxemia of pregnancy  
 Ecthyma gangrenosum, 389  
 Ectopia lentis, 57  
 Ectopic kidney, 73  
 Ectopic pregnancy, 317, 318f, 329–330  
 Eczematous dermatitis, acute, 384  
 Edema, 81–83, 82f–83f  
   decreased plasma osmotic pressure, 82  
   increased vascular hydrostatic pressure, 82  
 Edward syndrome, 66  
 Eisenmenger syndrome, 110  
 Ehlers-Danlos syndrome, 65  
 Embolus  
   amniotic fluid, 87  
   fatty emboli, 87, 87f  
   paradoxical, 110–112, 153  
   pulmonary thromboembolus, 86–87, 86f–87f  
 Embryonal carcinoma, 311  
 Emphysema, 58, 211–212, 211f  
   centriacinar, 211  
   cor pulmonale, 211  
   morphology of, 211, 211f  
   panacinar, 211  
   pulmonary, 211  
 Empty sella syndrome, 340  
 Empyema, 223, 223f, 226  
 Encephalitis  
   cytomegalovirus (CMV), 154–155  
   features of, 154, 154f  
   HIV, 154–155  
   HSV-1, 154–155  
   HSV-2, 154–155  
   rabies, 154–155  
 Endocarditis. *See also* Infective endocarditis  
   Libman-Sacks, 28  
 Endocrine disorders  
   adrenal neoplasms, 358–360, 359f  
   diabetes mellitus, 351–354, 351t, 353f–354f  
   goiter, 342–343, 343f  
   hyperadrenalism, 354–355, 355f, 355t  
   hyperaldosteronism, 358  
   hyperparathyroidism, 349–350, 350f  
   hyperpituitarism, 337–339, 338f  
   hyperthyroidism, 343–344, 343t, 344f  
   hypoadrenalism, 356–357, 356f–357f  
   hypoparathyroidism, 350  
   hypopituitarism, 340, 340f  
   hypothyroidism, 343t, 345–346, 346f  
   mass effect, 340–341  
   posterior pituitary pathology, 341–342  
   thyroiditis, 346–347  
   thyroid neoplasms, 347–349, 347f–349f  
 Endogenous pigments, 10, 10f  
 Endometrial disorders  
   adenocarcinoma, 321–322, 322f  
   adenomyosis, 319, 319f  
   endometriosis, 319–320, 320f  
   endometritis, acute/chronic, 319  
   hyperplasia, 320–321, 321f  
   neoplasms, 321–323, 322f–323f  
 Endometrioid tumor, 325  
 Endometriosis, 319–320, 320f  
 Endometritis, acute/chronic, 319  
 Endothelial cell retraction, contraction, 15  
*Entamoeba histolytica* infection, 247, 247f  
 Enterocolitis, necrotizing, 75, 75f  
 Environmental disorders  
   physical trauma, 50–51, 50f–51f  
   toxic substances, 47–50, 48f–49f  
 Ependymoma, 159  
 Epidural hemorrhage, 146, 148f  
 Epilepsy, 136–137  
 Epispadias, 73

- Epstein-Barr virus (EBV), 38, 198, 201, 234  
 Erlenmeyer flask deformity, 363  
 Erosion, 18, 242  
 Erythema chronicum migrans, 124, 124*t*  
 Erythema multiforme  
   Stevens-Johnson syndrome, 384, 384*f*  
   toxic epidermal necrolysis, 385, 385*f*  
 Erythema nodosum, 219, 251–252, 388  
 Erythroblastosis fetalis, 24, 183  
 Erythropoiesis, ineffective, 180  
 Erythropoietin, 40  
 Esophageal disorders  
   esophagitis, 237–238, 237*f*–238*f*  
   motor function  
     achalasia, 236  
     hiatal hernia, 235–236  
   neoplasms  
     adenocarcinoma, 240  
     morphology of, 240  
     squamous cell carcinoma, 239–240  
   varices, 237, 237*f*  
 Esophagitis  
   Barrett esophagus, 238, 239*f*  
   gastroesophageal reflux disease (GERD), 237–238, 237*f*  
 Essential hypertension. *See* Primary essential hypertension  
 Essential thrombocytosis, 195–196  
 Ewing sarcoma, 78, 78*t*, 368*t*, 372, 372*f*  
 Exogenous pigments, 10, 10*f*  
 Exostosis. *See* Osteochondroma  
 Extracerebral hemorrhage  
   epidural, 146, 148*f*  
   subarachnoid, 148, 150*f*  
   subdural, 146–147, 149*f*  
 Exudate, 83, 229  
  
 Factor V Leiden mutation, 85  
 False aneurysm, 100, 119  
 Familial adenomatous polyposis. *See* Familial polyposis coli  
 Familial hypercholesterolemia, 56, 56*t*  
 Familial melanoma syndrome. *See* Dysplastic nevus syndrome  
 Familial polyposis coli, 41*t*, 56, 56*f*, 257  
 Fatty streak, 95, 95*f*  
 Felty syndrome, 375  
 Female pseudohermaphrodite, 68  
 Female reproductive tract disorders, 309  
   amenorrhea, 318–319  
   breast carcinoma, 334–336, 335*f*  
   breast diseases, nonneoplastic, 331–333, 331*t*, 332*f*–333*f*  
   carcinoma in situ, breast, 333–334, 333*f*–334*f*  
   cervical intraepithelial neoplasia, 38, 41*t*, 42*f*, 316–317, 317*f*  
   fibroids, 322–323, 323*f*  
   nonneoplastic uterine diseases, 319–321, 319*f*–321*f*  
   ovarian disease, nonneoplastic, 323  
   ovarian tumors, 324*f*–327*f*, 324–326, 324*t*  
   pelvic inflammatory disease (PID), 317–318, 318*f*  
   placental, pregnancy-related, 326–331, 328*f*, 328*t*, 330*f*  
   squamous intraepithelial lesion, 316–317  
     uterine tumors, 321–323, 322*f*–323*f*  
     vaginal tumors, 316  
 Ferruginous body, 218, 218*f*  
 Fetal alcohol syndrome, 48, 69  
 Fetal hydrops, 76–77, 76*f*  
   immune/nonimmune causes, 77  
 Fetus hepaticus, 266  
 Fibrinous inflammation, 17  
 Fibroadenoma, 332, 332*f*  
 Fibrocystic change, 331*t*, 331–332, 332*f*  
 Fibroids. *See* Leiomyoma  
 Fibrothecoma, 326  
 Fibrous cortical defect, 371  
 Fibrous dysplasia, 371  
 Field effect, 230  
 Fistula, 18, 19*f*  
   arteriovenous, 101  
   tracheoesophageal, 72  
 Fitz-Hugh-Curtis syndrome, 318  
 Focal nodular hyperplasia, 276, 277*f*  
 Focal segmental glomerulosclerosis (FSGS), 290, 290*f*, 296  
 Folate deficiency, 52, 52*t*, 180, 180*f*, 180*t*  
 Follicular adenoma, carcinoma of the thyroid, 347–348, 348*f*  
 Follicular lymphoma, 197*t*, 200, 200*f*  
 Forebrain developmental disorders  
   alobar holoprosencephaly, 140  
   lobar holoprosencephaly, 141  
   semilobar holoprosencephaly, 141  
 Foregut cysts, 72  
 Fractures, 367  
 Fragile X syndrome, 68  
 Freckles, 379  
 Free radicals, 4  
 Frontotemporal dementia, 163  
 FSGS. *See* Focal segmental glomerulosclerosis  
 Fungal meningitis, 153  
 Fusiform aneurysm, 100  
  
 Galactosemia, 60  
 Gamma-glutamyltransferase, 261, 262*t*  
 Gardner syndrome, 368  
 Gastric neoplasms  
   adenocarcinoma, 244–245, 244*f*–245*f*  
   gastrointestinal stromal tumor, 245  
   polyps, 244  
 Gastric ulcers, acute, 91, 91*f*, 243  
 Gastrinoma triangle, 243  
 Gastritis  
   acute, 240–241, 241*f*  
   chronic, 241–242, 242*f*  
 Gastroesophageal reflux disease (GERD), 237–238, 237*f*, 239*f*  
 Gastrointestinal disorders  
   abdominal pain, 231, 232*t*  
   acute  
     inflammation, 231, 232*t*  
     obstruction, 231, 232*t*  
     perforation, 231, 232*t*  
     vascular disease, 231, 232*t*

- chronic
  - abdominal wall pain, 231, 232*t*
  - functional, 231, 232*t*
  - inflammation, 231, 232*t*
  - metabolic disease, 231, 232*t*
  - vascular disease, 231, 232*t*
- appendicitis, acute, 256, 256*f*
- bleeding, 231, 232*t*
- constipation/diarrhea, 245–247, 245*t*, 246*f*–247*f*
- diverticular disease, 254–255, 254*f*–255*f*
- esophageal motor function, 235–236
- esophageal neoplasms, 239–240
- esophagitis, 237–238, 237*f*–239*f*
- gastric neoplasms, 244–245, 244*f*–245*f*
- gastric ulcers, acute, 243
- gastritis, 240–242, 241*f*–242*f*
- intestinal obstruction, 253*f*, 255, 255*f*
- intestinal tumors, 256–259, 256*f*–259*f*
- malabsorption, 248–253, 248*t*, 250*t*, 251*f*–252*f*
- nonneoplastic disorders of esophagus alcohol-related, 236–237, 236*f*–237*f*, 239
- oral cavity, salivary glands, 234–235, 235*f*
- pediatric, 232–233
- peptic ulcer disease, 242–243, 243*f*
- vascular disorders, 253–254, 253*f*
- Gastroschisis, 73, 73*f*
- Gaucher disease
  - Type I, 62
  - Type II, 62
  - Type III, 63
- GBM (glioblastoma multiforme), 158, 158*f*
- Genetic disorders
  - autosomal dominant, 55, 56*t*
    - familial hypercholesterolemia, 56, 56*t*
    - familial polyposis coli, 41*t*, 56, 56*f*, 257
    - hereditary spherocytosis, 56, 56*t*, 186
    - Marfan syndrome, 56–57, 56*t*, 98–99, 100*f*
    - myotonic dystrophy type 1, 58
    - NF-1, 44, 56*t*, 57, 57*f*
    - NF-2, 56*t*, 57
    - tuberous sclerosis, 56*t*, 58, 58*f*
    - VHL disease, 41*t*, 44, 57
  - autosomal recessive, 58, 59*t*
    - alkaptonuria, 61
    - $\alpha_1$ -Antitrypsin, 58, 211, 267, 273
    - cystic fibrosis, 59, 59*t*
    - galactosemia, 59*t*, 60
    - hereditary hemochromatosis, 9, 9*f*, 59*t*, 60, 129–130, 266*t*, 267, 272–273, 273*f*
    - maple syrup urine disease, 59*t*, 61
    - mucopolysaccharidosis (MPS), 62
    - phenylketonuria (PKU), 59*t*, 60–61
    - Wilson disease, 59*t*, 61, 266*t*, 267, 273, 276
  - Cri-du-chat syndrome, 67
  - Down syndrome, 65–66, 66*f*, 112, 194, 232
  - Edward syndrome, 66
  - genomic imprinting, Prader-Willi and Angelman syndromes, 68
  - glycogen storage
    - hepatic forms, 63
    - miscellaneous forms, 64, 64*f*
    - myopathic forms, 64
  - lysosomal storage, 62
    - Gaucher disease, 62–63
    - Niemann-Pick disease, 63
    - Tay-Sachs disease, 63
  - mixed inheritance patterns, Ehlers-Danlos syndrome, 65
  - Patau syndrome, 66
  - sex chromosome abnormalities
    - fragile X syndrome, 68
    - Klinefelter syndrome, 67
    - Turner syndrome, 67, 67*f*
  - sexual differentiation
    - female pseudohermaphrodite, 68
    - male pseudohermaphrodite, 69
    - true hermaphrodite, 68
  - 22q11.2 deletion, 66–67
  - X-linked inheritance patterns
    - Becker muscular dystrophy, 65
    - Duchenne muscular dystrophy, 64–65
- Genomic imprinting, 68
- GERD. *See* Gastroesophageal reflux disease
- Germ cell neoplasms, 35, 310, 310*t*
- Germinal matrix hemorrhage, 75, 75*f*
- Gestational hypertension, 97
- Gestational trophoblastic disease. *See* Hydatidiform mole
- GGT (gamma-glutamyltransferase), 261, 262*f*
- Ghon complex/focus, 225, 226*f*
- Giant cell arteritis, 103, 103*f*, 103*t*
- Giant cell tumor of bone, 368*t*, 372, 372*f*
- Giardia lamblia*, 246, 246*f*
- Gigantism, 339
- Gilbert syndrome, 263–264
- Glioblastoma multiforme (GBM), 158, 158*f*
- Global hypoxic-ischemic encephalopathy, 90, 90*f*, 142–143
- Glomerular disorders, 287–288
- Glomerulonephritis
  - chronic, 295, 295*f*
  - membranoproliferative, 289*t*, 294–295, 294*f*
  - postinfectious, 289*t*, 293, 293*f*
  - rapidly progressive (RPGN), 289*t*, 293–294, 293*f*
- Glucose-6-phosphate dehydrogenase deficiency (G6PD), 187
- Glycogen storage disorders, 63–64, 64*f*
- Goiter, 342–343, 343*f*
- Goodpasture syndrome, 221, 294
- Gout, 373*t*, 375–377, 376*f*
  - saturnine, 377
- Grade of tumor, 46
- Graft-versus-host disease (GVHD), 27
- Granulation tissue, 20
- Granuloma, 19, 20*f*
- Granuloma annulare, 388
- Granulomatous inflammation, 19
- Granulosa cell tumor, 326



- Graves disease, 24, 344, 344f  
 Gray hepatization, 223  
 Growth hormone-secreting adenoma, 339  
 G6PD deficiency (glucose-6-phosphate dehydrogenase deficiency), 187  
 Guillain-Barré syndrome, 169  
 Gunshot wound, 50, 51f  
 GVHD (graft-versus-host disease), 27
- Hairy cell leukemia, 202, 202f  
 Hairy leukoplakia, 44t, 234  
 Hamartoma, 36  
 HbH disease, 177  
 HBV. *See* Hepatitis B virus  
 HCC. *See* Hepatocellular carcinoma  
 Headache, 136  
 Healing, regeneration, 19  
   first intention, 20  
   general wound, 21  
   mediators, 20  
   scar replacement, 20  
   second intention, 21  
 Heart. *See* Cardiac disorders  
 Heart failure cells, 83  
 Heat cramps, 50  
 Heat exhaustion, 51  
 Heat stroke, 51  
 Heavy chain disease, 205  
 Heberden nodes, 374  
 Heinz bodies, 187  
*Helicobacter pylori*, 241–242  
 HELLP syndrome, 97, 331  
 Hemangioma, 106, 277, 278f  
 Hematemesis, 231  
 Hematocele, 313  
 Hematochezia, 231, 254  
 Hematoma, 85  
 Hematopathology  
   anemia, 173–187, 174t, 176f, 176t, 178f, 180t, 180f–181f, 184t, 185f–186f  
   hemolytic anemia, 181–182, 185  
   Hodgkin lymphoma, 196–198, 197f–198f, 197t  
   immune-mediated platelet destruction, 205–206  
   leukemia, 190–195, 190f, 191t, 192f–195f, 193t  
   lymphoma, 190  
   macrocytic anemia, 179–180, 180f, 180t  
   myelodysplastic syndromes (MDS), 189  
   microcytic anemia, 176–178, 176f, 176t, 178f  
   myeloproliferative disorders, chronic, 195–196, 196f  
   non-Hodgkin lymphoma, 197t, 199–202, 199f–202f  
   nonimmune-mediated platelet destruction, 206–207, 206f, 207f  
   plasma cell dyscrasias, 203–205, 203f  
   platelet disorders, 207  
   polycythemia, 188  
   primary hemostasis disorders, 205  
   red blood cell (RBC) destruction  
   antibody-mediated, 182–185, 184t  
   hereditary causes, 185–187, 186f  
   infectious causes, 185, 185f  
   secondary hemostasis disorders, 208  
 Hematopoietic transplantations, 27  
 Hemochromatosis, 9. *See also* Hereditary hemochromatosis  
 Hemodynamics  
   edema, 82–83, 82f–83f  
   embolus, 86–87, 86f–87f  
   hemorrhage, 84–85, 84f–85f  
   hemostasis, thrombosis, 85–86  
   hyperemia, congestion, 83–84, 83f–84f  
   infarcts, 81, 87f–88f, 88–89  
   shock, 89–91, 90f–91f  
 Hemolytic anemia, 181–187, 184f, 184t, 185f–186f  
 Hemolytic uremic syndrome (HUS), 206  
 Hemophilia A, 208  
 Hemophilia B, 208  
 Hemorrhage, 84  
   corticomedullary, 91  
   Duret, 139, 139f  
   ecchymoses, 84  
   epidural, 146, 148f  
   extracerebral, 146–148, 148f–150f  
   gastric petechial, acute, 91, 91f  
   germinal matrix, 75, 75f  
   intracerebral, 48, 98, 145–146, 147f  
   petechiae, 77, 77f, 84, 84f  
   pulmonary, 220–221  
   purpura, 84  
   subarachnoid, 148, 150f  
   subdural, 146–147, 149f  
   terminology, 85, 85f  
 Hemosiderosis, 9  
 Hemostasis  
   primary, 205  
   secondary. *See* Secondary hemostasis  
   thrombus formation, 85–86  
 Henoch-Schönlein purpura (HSP), 294, 296  
 Heparin-induced thrombocytopenia, 205–206  
 Hepatic disorders. *See also* Hepatitis  
   alcoholic liver disease, 271–272, 271f–272f  
   circulation, 274–275  
   cirrhosis, 9, 58, 82, 262, 262t, 266–268, 266t, 266f–268f  
   drugs affecting, 271  
   encephalopathy, 266  
   failure  
   complications, 265  
   hepatic encephalopathy, 266  
   hepatorenal syndrome, 266  
   massive hepatic necrosis, 265  
   metabolic liver disease, 272–273, 272f–273f  
   neoplasms, 275–277, 276f–278f  
   obstructive biliary tract disorders, 273–274, 274f, 274t  
 Hepatitis  
   acute, 268, 268f  
   alcoholic, 271–272, 272f  
   autoimmune, 270–271  
   chronic, 268, 268f–269f  
   viral, 269–270, 269t

- Hepatitis B virus (HBV), 38, 104, 269–270, 269*t*, 276, 291, 293  
Hepatoblastoma, 277  
Hepatocellular carcinoma (HCC), 38, 41*t*, 276, 276*f*  
Hepatocellular dysfunction, 267–268  
Hepatojugular reflux, 122  
Hepatolenticular degeneration. *See* Wilson disease  
Hepatorenal syndrome, 266  
Hepcidin, 178  
Hereditary hemochromatosis, 9, 9*f*, 59*t*, 60, 129–130, 266*t*, 267, 272–273, 273*f*  
Hereditary immunodeficiency states, 31–33  
    common variable immunodeficiency, 32  
    hyper-IgM syndrome, 32  
    isolated IgA deficiency, 32  
    severe combined immunodeficiency disease (SCID), 32–33  
    Wiskott-Aldrich syndrome, 33  
    X-linked agammaglobulinemia of Bruton, 31–32  
Hereditary nonpolyposis colon cancer, 257  
Hereditary spherocytosis, 56, 56*t*, 186, 398, 416  
Herniation  
    cerebellar tonsillar, 82, 138, 138*f*  
    cerebral edema, 82, 138–139, 138*f*–139*f*  
    cingulate (subfalcine), 82, 139  
    transcalvarial, 139  
    uncal (transtentorial), 82, 139, 139*f*  
Herpes simplex virus (HSV), 75, 154–155, 238, 238*f*, 317  
Her-2–Neu, 335  
HHV-8. *See* Human herpesvirus 8  
Hiatal hernia, 235–236  
Hill sign, 127  
Hirschsprung disease, 233  
HIV. *See* Human immunodeficiency virus  
Hives (urticaria), 24, 384  
HLA-B27, 27, 375, 385  
Hodgkin lymphoma, 196–197, 197*f*, 197*t*  
    lymphocyte predominant, 198  
    mixed cellularity, 198, 198*f*  
    nodular sclerosis type, 198, 198*f*  
Holoprosencephaly  
    alobar, 140  
    lobar, 141  
    semilobar, 141  
Homer-Wright rosettes, 78, 160, 372  
Horner syndrome, 228  
Horseshoe kidney, 67, 67*f*, 73  
HPV. *See* Human papillomavirus  
HSP (Henoch-schönlein purpura), 294, 296  
HSV. *See* Herpes simplex virus  
HTLV-1 (human T-cell leukemia virus type 1), 38, 202  
Human herpesvirus 8 (HHV-8), 39, 106, 201  
Human immunodeficiency virus (HIV), 33–34, 234, 388  
Human papillomavirus (HPV), 38, 42*f*, 313, 316–317, 317*f*, 388  
Human T-cell leukemia virus type 1 (HTLV-1), 38, 202  
Humoral rejection, 26  
Huntington chorea, 164  
HUS (hemolytic uremic syndrome), 206  
Hutchison teeth, 76  
Hyaline arteriosclerosis, 98, 98*f*, 292*f*  
Hyaline membrane disease, 74, 74*f*  
    bronchopulmonary dysplasia, 75  
    retrolental fibroplasia, 74  
Hyaline membranes, 74, 74*f*, 90, 216, 216*f*  
Hydatidiform mole, 327–329, 328*f*, 328*t*, 344  
Hydrocele, 313  
Hydrocephalus  
    communicating, 137, 137*f*  
    noncommunicating, 138  
    normal pressure, 138, 164  
    pseudotumor cerebri, 138  
Hydrocephalus ex vacuo, 138  
Hyperadrenalism. *See* Cushing syndrome  
Hyperaldosteronism, 286, 358  
Hyperemia, congestion, 83  
    passive liver chronic, 84, 84*f*  
    passive lung chronic, 83, 83*f*  
Hyper-IgM syndrome, 32  
Hyperkalemia, 284, 307, 356  
Hypernatremia, 286, 307  
Hyperparathyroidism, 349, 349*t*, 350*f*  
    primary, 350, 350*f*  
    secondary, 350  
    tertiary, 350  
Hyperpituitarism, 337–339  
    pituitary adenomas, 338*f*, 338–339  
Hyperplasia, 1  
    adrenal, 355*f*, 355*t*  
    benign prostatic, 314, 314*f*  
    endometrial, 320–321, 321*f*  
    focal nodular, 276, 277*f*  
Hyperplastic arteriosclerosis, 98, 98*f*  
Hypersensitivity pneumonitis, 220  
Hypersensitivity reactions  
    Type I, 23–24  
    Type II, 24–25  
    Type III, 25  
    Type IV, 25  
Hypertension, 2*f*, 96–98, 354  
    benign (idiopathic), 97  
    chronic, 97  
    gestational, 97  
    malignant, 97  
    preeclampsia, 97  
    pulmonary, 86, 99–100, 219, 221, 221*f*  
    secondary. *See* secondary hypertension  
    systemic. *See* Systemic hypertension  
Hypertensive cardiovascular disease, 2*f*, 120  
Hyperthermia, malignant, 51  
Hyperthyroidism, 245*t*, 343–344, 343*t*  
Hypertrophic cardiomyopathy, 129, 129*f*  
Hypertrophy  
    concentric, 120  
    pathologic/physiologic, 2, 2*f*, 98  
Hypoadrenalism, 356–357, 356*f*–357*f*  
Hypokalemia, 51, 308  
Hyponatremia, 284, 286, 307, 342, 356  
Hypoparathyroidism, 350

- Hypopituitarism, 340, 340*f*  
 Hypoplasia, 2  
 Hypospadias, 73  
 Hypothyroidism, 343*t*, 345–346  
     cretinism, 345  
     myxedema, 345–346  
 Hypovolemic shock, 89  
 Hypoxia, 3–4
- Icterus, 262, 262*f*  
 Idiopathic (benign) hypertension, 97  
 Idiopathic Parkinson disease, 165, 165*f*  
 Idiopathic pulmonary fibrosis, 219–220  
 Idiopathic thrombocytopenic purpura, 185, 205  
 IgA nephropathy, 295–296  
 Ileus, 245  
 Immune complex deposition-mediated vasculitis, 102  
 Immune-mediated platelet destruction, 205  
 Immune system disorders  
     AIDS, 33–34, 33*f*, 34*f*  
     amyloidosis, 31, 31*t*, 32*f*  
     antibody-mediated red blood cell (RBC) destruction, 182–185  
     autoimmune diseases, 27*t*, 27–30  
     fetal hydrops, 77  
     hematopoietic transplantations, 27  
     hereditary immunodeficiency states, 31–33  
     immune cytopenic purpura (ITP), 205  
     neuropathy, 169  
     transplantation pathology, 25–26, 26*f*  
     Type I hypersensitivity reaction, 23  
         early phase, 23–24  
         late phase, 24  
     Type II hypersensitivity reaction, 24  
         antibody-dependent cell-mediated cytotoxicity, 24  
         antibody-dependent cellular dysfunction, 24–25  
         complement-dependent reactions, 24  
     Type III hypersensitivity reaction, 25  
     Type IV hypersensitivity reaction, 25  
         cell-mediated cytotoxicity, 25  
         vasculitis, 102  
 Immune thrombocytopenic purpura (ITP), 185, 205  
 Impetigo, 388  
 Incised wound, 50  
 Inclusion body myositis, 171  
 Ineffective erythropoiesis, 180  
 Infarcts, 81, 88–89, 88*f*  
     cerebral, 143–145, 143*f*–146*f*, 143*t*  
     lacunar, 145, 146*f*  
     myocardial, 113, 116–120, 116*f*, 117*t*, 119*t*, 118*f*–121*f*  
     red (hemorrhagic), 87*f*, 88  
     white (anemic), 88, 88*f*  
 Infective endocarditis, 122*f*–123*f*, 123–124  
     Janeway lesions, 123  
     Osler nodes, 123  
     Roth spots, 123  
 Inflammation  
     acute 14–18  
         mediators of, 14–16, 14*t*  
         morphology of  
             fibrinous, 17  
             purulent, 17, 17*f*  
             serous, 17  
     outcomes of  
         abscess, 18, 18*f*  
         fistula, 18, 19*f*  
         resolution, 17–18  
         ulcer, 18, 18*f*  
     signs of 14, 14*t*  
     chemotaxis, 16  
     chronic, 19  
     healing *versus* regeneration, 19–20  
     impaired inflammatory response diseases  
         Chédiak-Higashi syndrome, 17  
         chronic granulomatous disease, 16–17  
     increased vascular permeability, 14–15  
         delayed prolonged response, 15  
         endothelial cell retraction, 15  
         endothelial contraction, 15  
     scar formation, 18  
     vasodilation, 14  
     white blood cell movement  
         pavementing, 15  
         rolling, 15  
         transmigration, 15  
 Inflammatory carcinoma of the breast, 335  
 Inherited bone diseases  
     achondroplasia, 361–362  
     osteogenesis imperfecta, 362  
     osteopetrosis, 362–363  
 Inherited skin neoplasia syndromes  
     basal cell nevus, 383  
     dysplastic nevus, 383  
 INK4a/ARF, 44  
 Interstitial nephritis  
     acute, 297, 297*f*  
     chronic, 297–298  
 Intestinal metaplasia, 242, 242*f*  
 Intestinal tumors  
     adenomas, 256–257, 256*f*–257*f*  
     carcinoid tumor, 258–259, 258*f*–259*f*  
     colonic adenocarcinoma, 257–258, 257*f*–258*f*  
     nonneoplastic polyps, 256  
 Intracerebral hemorrhage, 48, 98, 145–146, 147*f*  
 Intraductal papilloma, 333, 333*f*  
 Intratubular germ cell neoplasia, 311  
 Intrinsic azotemia, 284  
 Intussusception, 233  
 Involucrum, 365  
 Inv16, 193*t*, 194  
 Iron deficiency anemia, 176, 176*f*, 176*t*  
 Ischemia, 3  
 Ischemic bowel disease, 253–254, 253*f*  
 Ischemic heart disease  
     clinical syndromes, 113–115, 114*f*–115*f*  
     myocardial infarction, 113, 116–120, 116*f*, 118*f*–121*f*, 117*t*, 119*t*



- non-ST segment elevation (NSTEMI), 113, 116–117, 116f
- ST segment elevation STEMI, 113, 116–117
- stable angina, 114, 114f
- unstable angina, 113–117
- variant angina, 115
- Islet cell tumor, 281
- Isohemagglutinin reaction, 182
- Isolated IgA deficiency, 32
- ITP (immune thrombocytopenic purpura), 185, 205
- Janeway lesions, 123
- Jaundice, cholestasis, 11, 262–265, 262f, 263t, 264f
  - Crigler-Najjar syndrome, 264
  - Dubin-Johnson syndrome, 264
  - Gilbert syndrome, 263–264, 263t
  - neonatal cholestasis, 264
  - physiologic jaundice of newborn, 263
- Kaposi sarcoma, 34, 34f, 39, 106–107
- Kartagener syndrome, 214–215
- Karyolysis, 5
- Kasabach-Merritt syndrome, 106
- Kawasaki disease, 103t, 105
- Kayser-Fleischer rings, 61
- Keloid scar, 21, 21f
- Kernicterus, 183
- Kernig sign, 153
- Kidney disorders. *See also* Renal disorders
  - asymptomatic hematuria, 295–296
  - congenital anomalies, 73
  - cystic diseases, 301–303, 302f
  - glomerular disorders, 82, 287–288
  - glomerulonephritis, chronic, 295, 295f
  - infections, 298–300, 299f–300f
  - neoplasms, 303–304, 303f–304f
  - nephritic syndrome, 289t, 292t, 292–295, 293f–294f
  - nephrolithiasis, 301, 301f, 301t
  - nephrotic syndrome, 288–292, 288f, 289t, 290f–292f, 292t
  - renal failure
    - acute 283–285, 284t
    - chronic renal failure, 285–286
  - tubulointerstitial disease, 296–298, 297f–298f
  - volume disorders, 286
- Kidney stones. *See* Nephrolithiasis
- Kimmelstiel-Wilson lesion, 292, 292f, 353
- Klinefelter syndrome, 67
- Koilocytes, 317, 317f
- Korsakoff syndrome, 48, 52, 136
- Krukenberg tumor, 326
- Kussmaul sign, 122, 131
- Kwashiorkor, 51
- Laceration, 50, 50f
- Lactose intolerance. *See* Disaccharidase deficiency
- Lacunar infarcts, 145, 146f
- Lambert-Eaton syndrome, 40, 171–172, 227
- Laminar cortical necrosis, 142–143
- Large cell carcinoma, 227, 228f
- Laron dwarfism, 362
- LCIS (lobular carcinoma in situ), 334
- Left-sided heart failure, 83, 83f, 121–122
- Leiomyoma, 36, 322–323, 323f
- Leiomyosarcoma, 36, 323
- Leipidic growth, 227
- Lentigo, 380
- Lesch-Nyhan syndrome, 376
- Leser-Trélat, sign of, 381
- Leukemia, 191, 191t
  - acute lymphoid (ALL), 191–192 191t, 192f
  - acute myeloid (AML), 191t, 193–194, 193t, 194f
  - adult T-cell leukemia, 38, 202
  - chronic lymphoid (CLL), 192–193 191t, 193f
  - chronic myeloid (CML), 191t, 194–195, 195f
  - cytogenetic abnormalities of acute lymphoid, 194
  - hairy cell, 202, 202f
  - T-cell lymphoblastic, 201
- Leukoplakia, 234
- Leukotrienes, 14, 14t, 16
- Lewy body, 165, 165f
- Lewy body disease, diffuse, 163
- LFA-1, 14t, 15
- Libman-Sacks endocarditis, 28
- Li-Fraumeni, 41t
- Lines of Zahn, 86, 86f
- Linitis plastica, 245
- Lipofuscin, 7–8, 8f
- Lipoprotein A (Lpa), 94
- Lisch nodules, 57
- Lissencephaly, 141
- Liver disorders. *See* Hepatic disorders
- Liver neoplasms
  - angiosarcoma, 277
  - cholangiocarcinoma, 276, 277f
  - focal nodular hyperplasia, 276, 277f
  - hemangioma, 277, 278f
  - hepatic adenoma, 277
  - hepatoblastoma, 277
  - hepatocellular carcinoma (HCC), 38, 41t, 276, 276f
- Lobar holoprosencephaly, 141
- Lobar pneumonia, 222, 223, 223f
- Lobular carcinoma in situ (LCIS), 334
- Lou Gehrig disease [amyotrophic lateral sclerosis (ALS)], 166
- LPL (lymphoplasmacytic lymphoma), 204
- Lutetic aortic aneurysm. *See* Syphilitic aortitis
- Lymphocyte predominant Hodgkin lymphoma, 197t, 198
- Lymphocytic (aseptic) meningitis, 151–152
- Lymphocytic myocarditis, 130, 130f
- Lymphoma, 190
  - cell markers, 197t
  - central nervous system (CNS), 160, 161f
  - Hodgkin, 196–198, 197f–198f, 197t
  - non-Hodgkin, 197t, 199–202, 199f–202f
  - testicular, 313
  - translocations, 197t

- Lymphomatoid polyposis, 202  
 Lymphoplasmacytic lymphoma (LPL), 204  
 Lysosomal storage disorders, 62–63
- Mac-1, 14*t*, 15
- Macrocytic anemia  
   B<sub>12</sub> deficiency, 179–180, 180*f*, 180*t*  
   folate deficiency, 180, 180*f*, 180*t*
- Macrovesicular steatosis, 262
- Malabsorption, 248, 248*t*  
   celiac sprue, 249  
   Crohn disease, 250*t*, 251–252, 251*f*  
   disaccharidase deficiency, 249–250  
   inflammatory bowel disease, 250, 250*t*  
   steatorrhea, 248–249  
   ulcerative colitis, 252–253, 252*f*  
   Whipple disease, 253
- Male pseudohermaphrodite  
   5 $\alpha$ -reductase deficiency, 69  
   testicular feminization, 69
- Male reproductive tract disorders. *See also* Testicular neoplasms  
   congenital anomalies, 73  
   prostate pathology, 314–316, 314*f*–315*f*  
   squamous cell carcinoma of penis, 313  
   testicular neoplasms, 309–313, 310*t*, 310*f*–312*f*
- Malignant hypertension, 97
- Malignant hyperthermia, 51
- Malignant melanoma, 44*t*, 380–381, 381*f*
- Malignant peripheral nerve sheath tumor, 57, 57*f*
- Mallory hyaline, 9, 9*f*, 271*f*, 272
- Mallory-Weiss laceration, 236, 236*f*
- Maltese cross, 288
- MALToma, 30, 202
- Mantle cell lymphoma, 202
- Maple syrup urine disease, 61
- Marasmus, 51
- Marfan syndrome, 56–57, 56*t*, 98–99, 100*f*
- Marginal zone lymphoma. *See* MAL Toma
- Marjolin ulcer, 382
- Mass effect, endocrine disorders, 339–341
- Massive hepatic necrosis, 265
- Mast cell tryptase, 213
- Mastitis, acute, 331
- McArdle syndrome, 10
- McCune-Albright syndrome, 371
- MDS (myelodysplastic syndrome), 189
- Meckel diverticulum, 233, 254, 254*f*
- Meconium ileus, 59
- Medullary thyroid carcinoma, 348–349, 349*f*, 359–360
- Medulloblastoma, 78, 78*t*, 160, 161*f*
- Megaloblastic anemia. *See* Macrocytic anemia
- Meigs syndrome, 326
- Meiosis, 228
- Melanocytic nevus, 380, 380*f*
- Melanocytic proliferations  
   acanthosis nigricans, 382, 382*f*  
   basal cell carcinoma, 383, 383*f*  
   cutaneous squamous cell carcinoma, 382–383  
   dysplastic nevus, 380  
   malignant melanoma, 380–381, 381*f*  
   melanocytic nevus, 380, 380*f*  
   seborrheic keratosis, 381, 382*f*
- Melanoma, malignant, 44*t*, 380–381, 381*f*
- Melena, 231, 237, 243
- Membranoproliferative glomerulonephritis (MPGN), 289*t*, 294–295, 294*f*
- Membranous glomerulonephropathy, 289*t*, 291, 291*f*
- MEN (multiple endocrine neoplasia), 359–360
- Meningioma, 57, 161, 162*f*
- Meningitis, 151*t*, 154*t*  
   bacterial, 151–153, 151*t*, 152*f*  
   brain abscess, 153–154, 154*f*  
   Brudzinski sign, 153  
   chemical, 151  
   chronic, 151  
   cryptococcal, 152, 153*f*  
   fungal, 153  
   Kernig sign, 153  
   lymphocytic (aseptic), 151–152  
   purulent (pyogenic), 151, 152*t*  
   tuberculous, 152–153, 153*f*  
   viral, 151–152  
   Waterhouse-Friderichsen syndrome, 152, 357, 357*f*
- Mesocapillary glomerulonephritis, 294
- Mesothelioma, 230
- Metabolic acidosis, 306
- Metabolic alkalosis, 306
- Metabolic syndrome, 94
- Metaplasia, 3, 3*f*  
   glandular, 238, 239*f*  
   intestinal, 242, 242*f*
- Metastatic calcification, 8
- MGUS (monoclonal gammopathy of undetermined significance), 204
- Microalbuminuria, 291
- Microatelectasis, 210
- Microcytic anemia, 176*t*, 176–178, 176*f*, 178*f*
- Microglial reactions, 137, 155, 155*f*
- Microscopic polyarteritis, 102, 105
- Microvesicular steatosis, 262
- Miliary TB, 225
- Minimal change disease, 289–290, 289*t*
- Mismatched ventilation-perfusion, 211
- Mitochondrial cytosolic calcium, 4
- Mitral regurgitation  
   mitral annular calcification, 128  
   myxomatous mitral valve, 127–128, 128*f*
- Mitral stenosis, 124, 124*f*, 127
- Mitral valve prolapse, 128
- Mixed acid-base disorders, 306
- Mixed cellularity Hodgkin lymphoma, 198, 198*f*
- Mixed connective tissue disorder, 30
- Mönckeberg medial calcification, 93
- Monoclonal gammopathy of undetermined significance (MGUS), 204

- MPGN. *See* Membranoproliferative glomerulonephritis
- MPS. *See* Mucopolysaccharidosis
- MS. *See* Multiple sclerosis
- M-spike, 203
- Mucinous ovarian tumors, 325, 326*f*
- Mucocutaneous lymph node syndrome. *See* Kawasaki disease
- Mucoepidermoid carcinoma, 235
- Mucopolysaccharidosis (MPS)
- Hunter disease (type II), 59*t*, 62
  - Hurler disease (type I), 59*t*, 62
- Multiple endocrine neoplasia 1, 359. *See also* Wermer syndrome
- Multiple endocrine neoplasia 2A, 359. *See also* Sipple syndrome
- Multiple endocrine neoplasia 2B, 358, 360
- Multiple myeloma, 203–204, 203*f*
- Multiple sclerosis (MS), 167–168
- acute (Marburg), 167
  - Baló disease, 167
  - clinical presentation, lab studies, 167–168
  - Devic disease, 167
  - morphology, 167, 167*f*
- Munro microabscesses, 385
- Mural thrombi, 119, 119*t*, 119*f*–120*f*
- Myasthenia gravis, 25, 171
- MYC, 42–43, 79, 201, 257
- Mycosis fungoides/Sézary syndrome, 202
- Mycotic aneurysm, 100
- Myelin ovoids, 169
- Myelodysplastic syndromes (MDS), 189
- Myelofibrosis with myeloid metaplasia, 196, 196*f*
- Myeloperoxidase, 16
- Myelophthisic anemia, 181, 181*f*
- Myeloproliferative disorders, chronic
- chronic myeloid (myelogenous) leukemia, 191*t*, 194–195, 195*f*
  - essential thrombocytosis, 195–196
  - myelofibrosis with myeloid metaplasia, 196, 196*f*
  - polycythemia rubra vera, 196
- Myocardial infarcts
- complications of, 119*t*
    - aneurysm, 119, 121*f*
    - arrhythmia, 119
    - cardiogenic shock, 118, 118*f*
    - conduction abnormalities, 119
    - electrical, 119
    - infarct expansion, 120, 120*f*
    - infarct extension, 120
    - mural thrombi, 119, 119*f*–120*f*
    - pericarditis, 119, 119*t*, 131, 131*t*
    - pseudoaneurysm, 119
    - right ventricular infarct, 120
    - rupture, 118–119, 119*f*–120*f*
  - morphology of, 117–118, 117*t*, 116*f*–118*f*
  - non-ST segment elevation (NSTEMI), 113, 116–117, 116*f*
  - reperfusion of, 116*f*, 118
  - ST segment elevation (STEMI), 113, 116–117, 116*f*
- Myocardial rupture, 118–119, 120*f*
- Myocarditis, lymphocytic, 130, 130*f*
- Myocyte disarray, 129, 129*f*
- Myopathies, 170–171
- congenital, 171
  - mitochondrial, 171
- Myotonic dystrophy type 1, 58
- Myxedema, 345–346, 346*f*
- Myxomatous mitral valve, 57, 127–128, 128*f*
- NAFLD (nonalcoholic fatty liver disease), 272, 272*f*
- Nasopharyngeal carcinoma, 38
- Necrobiosis lipoidica, 389
- Necrosis, 6–7
- caseous, 7, 7*f*
  - centrilobular, 90, 90*f*
  - coagulative, 6, 6*f*, 117, 117*t*, 118*f*
  - fat, 7
  - laminar cortical, 142–143
  - liquefactive, 6–7, 6*f*
  - massive hepatic, 265
  - osteo-, 364
  - subendocardial contraction band, 90
  - tubular, acute, 90–91
- Necrotizing enterocolitis, 75, 75*f*
- Necrotizing pneumonia, 224
- Negri bodies, 155
- Nelson syndrome, 339
- Neonatal cholestasis, 264
- Neonates, acquired CNS abnormalities, 141, 141*f*
- Neoplasm/neoplasia, 34, 34*f*, 35. *See also specific types of Tumors*
- adrenal, 358–360, 359*f*
  - benign *versus* malignant
    - growth rates, 37
    - histiologic features, 36–37, 38*f*–39*f*
    - invasion, metastases, 37, 39*f*–40*f*
  - cancer epidemiology, etiology, 37–39
  - cancer morphology, 45
  - cancer stem cells, 37
  - carcinogenesis, 40, 42–45
  - carcinogens, 42*t*
  - central nervous system (CNS), 156–161, 156*t*, 158*f*–162*f*
  - diagnosis of, 44*t*–45*t*, 46
  - effects of, 39–40
  - endometrial, 321–323, 322*f*
  - gastric, 244–245, 244*f*–245*f*
  - germ cell, 35, 310, 310*t*
    - intratubular, 311
  - grade and stage, 46
  - liver. *See also* Liver neoplasms
  - microscopic appearance of
    - anaplasia, 36, 38*f*
    - carcinoma in situ, 36
    - differentiation, 36, 37*f*
    - dysplasia, 36, 38*f*
  - nomenclature, general, 35, 36*f*
  - pediatric, 77–80, 78*f*–79*f*, 78*t*
  - pulmonary, 226–228, 227*f*–229*f*



- Neoplasm/neoplasia (*continued*)
- renal, 303–304, 303f–304f
  - testicular. *See also* Testicular neoplasms
  - thyroid, 347–349, 347f–349f
  - tumor antigens, 45
  - urothelial, 304–305, 304f–305f
  - viruses associated with, 38
- Nephritic syndrome, 289t, 292, 292t
- membranoproliferative glomerulonephritis (MPGN), 289t, 294–295, 294f
  - postinfectious glomerulonephritis, 289t, 293, 293f
  - rapidly progressive glomerulonephritis (RPGN), 289t, 293–294, 293f
- Nephrolithiasis, 301, 301f, 301t
- Nephrotic syndrome, 292t, 288–289
- components, complications, 288–289, 289t
  - diabetic nephropathy, 291–292, 292f
  - focal segmental glomerulosclerosis (FSGS), 289t, 290, 290f
  - membranous glomerulonephropathy, 289t, 291, 291f
  - minimal change disease, 289–290, 289t
- Neural tube defects, 139–140, 140f
- Neuroblastoma, 78–79, 78f, 78t
- opsoclonus-myoclonus syndrome, 79
  - prognostic factors, 79
- Neurodegenerative diseases
- primarily with dementia
    - Alzheimer disease, 9, 9f, 162–163, 163f–164f
    - frontotemporal dementia, 163
    - Lewy body disease, diffuse, 163
    - normal pressure hydrocephalus, 164
    - vascular dementia, 164
  - primarily without dementia
    - amyotrophic lateral sclerosis, 166
    - Huntington chorea, 164
    - idiopathic Parkinson disease, 165, 165f
    - Lou Gehrig disease, 166
    - progressive supranuclear palsy, 165–166
    - secondary Parkinsonism, 165
    - spinal muscular atrophy, 166
- Neurofibrillary tangles, 162, 164f
- Neurofibromatosis (NF)
- NF-1, 44, 57, 57f, 159
  - NF-2, 57, 159
- Neurofibromin, 44, 57
- Neurogenic shock, 90
- Neuroleptic malignant syndrome, 51
- Neuromyelitis optica. *See* Devic disease
- Neuronal migration disorders, 141
- Neuropathology
- cerebral edema, herniation, 138–139, 138f–139f
  - CNS infections, 150–155, 152f–154f, 151t, 154t, 155f
  - CNS tumors, 156–161, 156t, 158f–162f
  - consciousness disorders, 133–135
  - cortical defects, localized, 135–136
  - demyelinating diseases, 166–168, 167f
  - dizziness, 136
  - extracerebral hemorrhage, 146–148, 148f–150f
  - general morphologic changes, 137, 137f
  - headache, 136
  - hydrocephalus, 137–138, 137f
  - malformations, 139–141, 140f
  - neonates, acquired abnormalities, 141, 141f
  - neurodegenerative diseases
    - primarily with dementia, 162–164, 163f–164f
    - primarily without dementia, 164–166, 165f
  - peripheral nerve pathology, 169
  - seizures, 136–137
  - skeletal muscle pathology, 170–172
  - spongiform encephalopathies, 155–156
  - trauma of parenchyma, 149–150, 151f
  - vascular disease, 142–146, 143f–147f, 143t
  - vascular malformations, 141–142
- Neuropathy
- axonal, 169
  - demyelinating, 169
  - immune, 169
  - infectious, 169
- NF. *See* Neurofibromatosis
- Niemann-Pick disease, Types A, B, and C, 63
- Nikolsky sign, 386, 387
- Nodular sclerosis Hodgkin lymphoma, 198, 198f
- Nonalcoholic fatty liver disease (NAFLD), 272, 272f
- Nonallergic asthma, 212
- Non-Hodgkin lymphoma, 197t, 199–200, 199f
- adult T-cell leukemia/lymphoma, 202
  - Burkitt, 201, 201f
  - diffuse large B-cell (DLBCL), 200–201, 201f
  - follicular, 200, 200f
  - hairy cell leukemia, 202, 202f
  - MALToma, 202
  - mantle cell, 202
  - mycosis fungoides/Sézary syndrome, 202
  - precursor T-cell lymphoblastic leukemia/lymphoma, 201
  - small lymphocytic (SLL), 200
- Nosocomial pneumonia, 224
- NSTEMI (non-ST segment elevation myocardial infarct), 116–117, 116f
- Null cell adenoma, 338
- Nutmeg liver, 84, 84f
- Nutritional disorders. *See also specific* Nutritional deficiencies
- anorexia, 51
  - bulimia, 52
  - kwashiorkor, 51
  - marasmus, 51
- Nystagmus, 136
- Obliterative endarteritis, 101
- Obstructive atelectasis, 210
- Obstructive biliary tract disorders
- primary biliary cirrhosis, 273–274, 274f, 274t
  - primary sclerosing cholangitis, 274, 274t
- Obstructive lung disease, 210–211
- asthma, 212–213, 213f–214f
  - bronchiectasis, 214–215, 215f
  - bronchitis, chronic, 214

- chronic obstructive pulmonary disease, 215
- emphysema, 58, 211–212, 211*f*–212*f*
- Obstructive pulmonary disease, chronic, 215
- Ochronosis, 61
- Oligodendroglioma, 159, 160*f*
- Omphalocele, 73
- Opsoclonus-myoclonus syndrome, 79
- Opsonin, 14*t*, 16
- Oral cavity, salivary glands
  - hairy leukoplakia, 234
  - leukoplakia, 234
  - mucoepidermoid carcinoma, 235
  - pleomorphic adenoma, 234–235, 235*f*
  - salivary gland tumors, 234
  - squamous cell carcinoma, 234
- “Orphan Annie eye” nuclei, 347, 347*f*
- Orthopnea, 109, 121
- Osler nodes, 123
- Osteitis deformans. *See* Paget disease
- Osteitis fibrosa cystica, 350
- Osteoarthritis, 373*t*, 373–374, 374*f*
- Osteochondroma, 368*t*, 370, 370*f*
- Osteodystrophy, renal, 366–367
- Osteogenesis imperfecta, 362
- Osteoma, 368–369, 368*t*
- Osteomyelitis
  - pyogenic, 364–365, 365*f*
  - tuberculous, 365
- Osteonecrosis, 364
- Osteopetrosis, 362–363
- Osteoporosis, 363–364
- Osteosarcoma, 41*t*, 368*t*, 369, 369*f*
- Ovarian disease, nonneoplastic, polycystic, 323
- Ovarian tumors
  - Brenner tumor, 325, 326*f*
  - cystic teratoma, mature, 325–326, 327*f*
  - dysgerminoma, 326
  - endometrioid, 325
  - epithelial, 324, 324*t*
  - fibrothecoma, 326
  - granulosa cell, 326
  - Krukenberg, 326
  - mucinous, 325, 326*f*
  - serous, 324, 324*t*, 324*f*–325*f*
  - surface epithelial, 324, 324*t*
- Paget disease
  - of bone, 365–366, 366*f*
  - of breast, 333–334, 334*f*
- Panacinar emphysema, 211
- p-ANCA, 102, 105, 274
- Pancreas divisum, 73
- Pancreatic adenocarcinoma, 44, 44*t*, 281
- Pancreatic disorders
  - cysts, 281
  - islet cell tumor, 281
  - pancreatic adenocarcinoma, 44, 44*t*, 281
  - pancreatic cysts, 281
  - pancreatitis
    - acute, 280, 280*f*
    - chronic, 281, 281*f*
- Pannus, 374
- Papillary necrosis, 187, 300, 300*f*
- Papillary renal cell carcinoma, 304, 304*f*
- Papillary thyroid carcinoma, 347, 347*f*–348*f*
- Paradoxical embolus, 110–112, 153
- Paraneoplastic syndromes, 39–40, 304
  - ACTH (adreno corticotropic hormone)-like protein, 40, 227
  - erythropoietin, 40
  - nerve, muscle, 40, 227
  - PTH (parathyroid)-like protein, 39, 227
  - syndrome of inappropriate antidiuretic hormone (SIADH), 40
- Paraphimosis, 73
- Parathyroid gland disorders
  - hyperparathyroidism, 349–350, 349*t*, 350*f*
  - hypoparathyroidism, 350
- Parathyroid hormone (PTH), 39, 227
- Paroxysmal cold hemoglobinuria. *See* Cold hemolysin
  - hemolytic anemia
- Paroxysmal nocturnal dyspnea, 109, 121
- Paroxysmal nocturnal hemoglobinuria (PNH), 175
- Patau syndrome, 66
- Patched gene (PTCH), 183
- Patent ductus arteriosus (PDA), 112
- Pautrier microabscess, 202
- Pavementing, 15
- PCOD (polycystic ovarian disease), 321, 323
- PDA (patent ductus arteriosus), 112
- Pearson disease, 178
- Peau d’orange, 335
- Pediatric disorders, 71
  - congenital anomalies, 71–73, 73*f*
  - fetal hydrops, 76–77, 76*f*
  - gastrointestinal
    - congenital pyloric stenosis, 232
    - duodenal atresia, 232
    - Hirschsprung disease, 233
    - intussusception, 233
    - Meckel diverticulum, 233
  - neoplasms, 77, 78*t*
    - Burkitt lymphoma, 78, 78*t*, 197*t*, 201, 201*f*
    - Ewing sarcoma, 78, 78*t*, 368*t*, 372, 372*f*
    - medulloblastoma, 78, 78*t*, 160, 161*f*
    - neuroblastoma, 78–79, 78*f*, 78*t*
    - osteosarcoma, 41*t*, 368*t*, 369, 369*f*
    - primitive neuroectodermal tumor (PNET), 78, 78*t*, 368*t*, 372, 372*f*
    - retinoblastoma, 41*t*
    - rhabdomyosarcoma, 78, 78*t*
    - Wilms tumor, 79–80, 79*f*, 399, 416
- perinatal infections, 75–76
- prematurity, 73–75
- sudden infant death syndrome (SIDS), 77
- Peliosis hepatitis, 275
- Pellagra, 52

- Pelvic inflammatory diseases (PID), 317–318, 318*f*  
 Pemphigus, 386, 387*t*  
 Peptic ulcer disease, 242–243, 243*f*  
 Pericardial disease, 131–132, 131*f*–132*f*, 131*t*  
   cardiac tamponade, 132  
   pericardial effusion, 132  
   pericarditis, 119, 119*t*, 131, 131*f*–132*f*, 131*t*  
 Perinatal infections  
   congenital rubella, 76  
   congenital syphilis, 76  
   cytomegalovirus (CMV) infection, 76  
   herpes simplex virus (HSV) infection, 75  
 Peripheral vascular disease, 95  
 Periventricular leukomalacia, 141  
 Pernicious anemia, 179, 242  
 Petechiae, 77, 77*f*, 84, 84*f*  
 Peutz-Jeghers syndrome, 256  
 p53 gene, 41, 41*t*, 43–44, 153, 240, 382  
 Phenylketonuria (PKU), 60–61  
 Pheochromocytoma, 96, 96*t*, 358–360, 359*f*  
 Phimosis, 73  
 Phosphatase and tensin homologue (PTEN), 44, 321–322  
 Phyllodes tumor, 332–333  
 Physical trauma, 50, 50*f*–51*f*  
   hyperthermia  
     heat cramps, 50  
     heat exhaustion, 51  
     heat stroke, 51  
   hypothermia, 51  
   thermal burns, 50  
 Physiologic jaundice of newborn, 263  
 PID (pelvic inflammatory disease), 317–318, 318*f*  
 Pigment disorders  
   freckles, 379  
   lentigo, 380  
   vitiligo, 379  
 Pigments, exogenous, 10, 10*f*  
 Pilocytic astrocytomas, 159, 159*f*  
 Pitting edema, 83  
 Pituitary disorders  
   adenomas, 338*f*, 338–339  
   hyperpituitarism, 337–339  
   hypopituitarism, 340  
   posterior gland disorders  
     diabetes insipidus, 342  
     syndrome of inappropriate antidiuretic hormone (SIADH), 341–342  
 PKU (phenylketonuria), 60–61  
 Placental, pregnancy-related disorders  
   abortion, 326–327  
   abruption, 329, 394, 414  
   chorioamnionitis, 327  
   eclampsia/preeclampsia, 97, 330–331  
   ectopic pregnancy, 329–330  
   hydatidiform mole, 327–329, 328*f*, 328*t*  
   hypertension, 97, 330–331  
   placental abruption, 47, 48, 329  
   placenta accreta, 330, 330*f*  
   placenta previa, 330, 330*f*  
   toxemia of pregnancy, 97, 330–331  
 Plasma cell dyscrasias  
   heavy chain disease, 205  
   lymphoplasmacytic lymphoma (LPL), 204  
   monoclonal gammopathy of undetermined significance (MGUS), 204  
   multiple myeloma, 203–204, 203*f*  
   plasmacytoma, 204  
   Russell bodies, 203  
   Waldenström macroglobulinemia, 204  
 Plasmacytoma, 204  
 Platelet destruction  
   immune-mediated  
     heparin-induced thrombocytopenia, 205–206  
     immune thrombocytopenic purpura (ITP), 185, 205  
   nonimmune-mediated  
     disseminated intravascular coagulation (DIC), 185, 206–207, 207*f*  
     hemolytic uremic syndrome (HUS), 206  
     thrombotic thrombocytopenic purpura, 185, 206, 206*f*  
 Platelet disorders, 205–207, 206*f*–207*f*  
 Pleomorphic adenoma, 234–235, 235*f*  
 Pleomorphism, 37  
 Pleural conditions  
   effusions, 223*f*, 229  
   mesothelioma, 218, 230  
   pneumothorax, 210, 226, 229–230  
 Plummer-Vinson syndrome, 239  
 PNET. *See* Primitive neuroectodermal tumor  
 Pneumatosis intestinalis, 75  
 Pneumoconioses, 217–218, 217*f*–218*f*  
*Pneumocystis* pneumonia, 32, 33*f*, 34, 226  
 Pneumonia  
   aspiration, 224, 224*f*–225*f*  
   bronchopneumonia, 222, 222*f*  
   chronic, 224–225, 226*t*  
   community-acquired  
     atypical, 223–224, 224*f*  
     typical, 222–223, 222*f*–223*f*  
   in immunocompromised, 226  
   lobar, 222, 223, 223*f*  
   necrotizing, 224  
   nosocomial, 224  
   usual interstitial, 219–220  
 Pneumothorax, 210, 226, 229–230  
   tension, 229  
 PNH (paroxysmal nocturnal hemoglobinuria), 175  
 Polyarteritis nodosa (PAN), 96*t*, 103*t*, 104, 104*f*  
 Polycystic ovarian disease (PCOD), 321, 323  
 Polycythemia, 188  
 Polycythemia rubra vera, 108, 196  
 Polymicrogyria, 141  
 Polymyositis, dermatomyositis, 170  
 Polyps, 36  
   gastric, 244



- intestinal, 256
- Peutz-Jeghers syndrome, 256
- Pompe disease, 64*f*
- Porencephaly, 141, 141*f*
- Porphyria cutanea tarda, 389
- Portal hypertension, 267, 267*f*-268*f*
- Postinfectious glomerulonephritis, 289*t*, 293, 293*f*
- Postrenal azotemia, 284–285
- Pott disease, 365
- Potter sequence, 71
- Prader-Willi syndrome, 68
- Precursor T-cell lymphoblastic leukemia/lymphoma, 197*t*, 201
- Preeclampsia. *See* Toxemia of pregnancy
- Pregnancy. *See* Placental, pregnancy-related disorders
- Prematurity
  - complications of
    - germinal matrix hemorrhage, 75, 75*f*
    - hyaline membrane disease, 74–75, 74*f*
    - necrotizing enterocolitis, 75, 75*f*
  - fetal causes of, 74
  - maternal causes of, 74
  - placental causes of, 74
- Prerenal azotemia, 284
- Primary biliary cirrhosis, 266*t*, 273–274, 274*f*, 274*t*
- Primary ciliary dyskinesia, 215
- Primary effusion lymphoma, 201
- Primary hemostasis disorders, 205
- Primary (essential) hypertension, 96–97
- Primary pulmonary hypertension, 99–100, 221, 221*f*
- Primary Raynaud disease. *See* Raynaud phenomenon
- Primary sclerosing cholangitis, 274, 274*t*
- Primitive neuroectodermal tumor (PNET), 78, 78*t*, 368*t*, 372, 372*f*
- Prinzmetal angina. *See* Variant angina
- Progressive massive fibrosis, 218
- Progressive multifocal leukoencephalopathy, 168
- Progressive supranuclear palsy, 165–166
- Prolactinoma, 338, 359
- Prolymphocytic leukemia, 192
- Prostate disorders
  - benign prostatic hyperplasia, 314, 314*f*
  - prostatic adenocarcinoma, 315–316, 315*f*
  - prostatitis, acute, 314, 314*f*
- Prostate specific antigen (PSA), 44*t*, 315–316
- Proteus vulgaris*, 301
- Prothrombin gene mutation, 85
- PSA. *See* Prostate specific antigen
- Psammoma bodies, 161, 324, 347, 348*f*
- Pseudoaneurysm. *See* False aneurysm
- Pseudogout, 377
- Pseudohermaphrodite
  - female, 68
  - male, 69
- Pseudomembranous colitis, 247, 247*f*
- Pseudomonas*, 59, 224, 301
- Pseudomyxoma peritonei, 325
- Pseudo Pelger-Huët anomaly, 189
- Pseudopolyps in ulcerative colitis, 252, 252*f*
- Psoriasis, 385, 385*f*
- PTCH (patched gene), 183
- PTEN. *See* Phosphatase and tensin homologue
- PTH (parathyroid hormone), 39, 227
- Ptois, 228
- Pulmonary disorders, 210*t*
  - abscess, 226
  - atelectasis, 210
  - diffuse pulmonary hemorrhage, 220–221
  - field effect, 230
  - general categories, 210*t*
  - Goodpasture syndrome, 221
  - hypertension, 99–100, 211, 221, 221*f*
  - infections
    - aspiration pneumonia, 224, 224*f*-225*f*
    - community-acquired
      - atypical, 223–224, 224*f*
      - typical, 222–223, 222*f*-223*f*
    - dimorphic fungi, 225
    - immunocompromised patient, 226
    - lobar pneumonia, 392, 413
    - necrotizing pneumonia, 224
    - nosocomial pneumonia, 224
    - pneumonia
      - chronic, 224
    - pulmonary tuberculosis, 225, 226*f*
  - neoplasms
    - adenocarcinoma, 227, 227*f*-228*f*
    - large cell carcinoma, 227, 228*f*
    - small cell carcinoma, 227–228, 229*f*
    - squamous cell carcinoma, 226–227, 227*f*
  - obstructive lung disease, 210–215, 211*f*-215*f*
  - obstructive pulmonary disease, chronic, 215
  - pleural conditions, 223*f*, 228–230
  - respiratory failure, acute, 209–210
  - restrictive lung disease
    - acute, 215–216, 216*f*
    - chronic, 216–220, 217*f*-220*f*, 216*t*
  - sequestration, 72
  - tuberculosis, 225, 226*f*
  - upper respiratory tract pathology, 230
- Pulmonary osteoarthropathy, 215
- Pulmonary thromboembolus, 86–87, 86*f*, 221
- Pulsus paradoxus, 131–132
- Pure red cell aplasia, 181, 181*f*
- Pure vasospastic angina, 115
- Purpura, 84
- Purulent inflammation, 17, 17*f*
- Purulent (pyogenic) meningitis, acute, 151, 152*t*
- Pyelonephritis
  - acute, 299–300, 299*f*-300*f*
  - chronic, 300, 300*f*
  - xanthogranulomatous, 300, 301*f*
- Pyknosis, 5
- Pyoderma gangrenosum, 389
- Pyogenic osteomyelitis, 364–365, 365*f*

- QRS alternans, 132  
 Queen Anne sign, 345
- Rabies, 154–155  
 Ranson criteria, 280  
 Rapidly progressive glomerulonephritis (RPGN), 289*t*, 293–294, 293*f*  
 RAS, 42, 44  
 Raynaud disease, 107  
 Raynaud phenomenon, 107  
 RB. *See* Retinoblastoma  
 RBC. *See* Red blood cell  
 Red blood cell (RBC), destruction of  
   antibody-mediated, 182–185, 184*t*  
   hereditary causes, 185–187, 186*f*  
   infectious causes, 185, 185*f*  
 Red blood cell disorders. *See* Hematopathology  
 Red hepatization, 223  
 Red (hemorrhagic) infarct, 87*f*, 88  
   reperfusion, 88  
   venous infarcts, 88  
 Reed-Sternberg cell, 197, 197*f*, 198, 198*f*  
 Reflux esophagitis. *See* Gastroesophageal reflux disease  
 Regurgitation  
   aortic, 126–127, 122*f*  
   mitral, 127–128, 128*f*  
 Reid index, 214  
 Reiter syndrome, 375  
 REM (roentgen-equivalent-man), 49–50  
 Renal artery stenosis, 96*t*, 97  
 Renal disorders. *See also* Kidney disorders,  
   congenital anomalies, 73  
   cysts, 302  
   hepatorenal syndrome, 266  
   hypertension, 96, 96*t*  
   neoplasms  
     renal cell carcinoma  
       chromophobe, 303  
       clear cell, 303, 303*f*  
       papillary, 304, 304*f*  
     osteodystrophy, 366–367  
 Renal failure  
   acute, 283–285, 284*t*  
   azotemia  
     intrinsic, 284, 284*t*  
     postrenal, 284–285  
     prerenal, 284, 284*t*  
   chronic, 285–286  
 Respiratory acidosis, alkalosis, 305  
 Respiratory failure, acute, 209–210  
 Restrictive cardiomyopathy, 130, 130*f*  
 Restrictive lung disease  
   acute, 215–216, 216*f*  
   chronic, 216–220, 216*t*, 217*f*–220*f*  
     asbestos, 217–218, 218*f*  
     beryllium-induced, 218  
     coal-induced, 218  
     hypersensitivity pneumonitis, 220  
     idiopathic pulmonary fibrosis, 219–220  
     pneumoconioses, 217–218  
     sarcoidosis, 8, 18, 129–130, 130*f*, 219, 220*f*  
     silica-induced, 218, 219*f*  
 RET proto-oncogene, 41*t*, 42, 359–360  
 Retinoblastoma (RB), 43  
   familial, 41*t*  
 Retinopathy, 98  
 Retrolental fibroplasia, 74  
 Reye syndrome, 265  
 Rhabdomyoma, 132  
 Rhabdomyosarcoma, 78, 78*t*  
 Rheumatic fever  
   acute, 124, 124*t*  
   Aschoff nodules, 124  
   rheumatic valvulitis, chronic, 124–125, 124*f*–125*f*  
   stenotic, regurgitant valvular disease, 125  
 Rheumatic valvulitis, chronic, 124–125, 124*f*–125*f*  
 Rheumatoid arthritis, 29–30, 30*f*, 374–375, 375*f*, 375*t*  
 Richter transformation, 192  
 Right-sided heart failure, 121–122  
 Rodent ulcers, 383  
 Roentgen-equivalent-man (REM), 49–50  
 Rokitsky-Aschoff sinus, 279  
 Rolling, 15  
 Rosenthal fibers, 159, 159*f*  
 Rosettes, 78, 160  
 Roth spots, 123  
 Rouleaux, 175  
 RPGN. *See* Rapidly progressive glomerulonephritis  
 Rubella, 76  
 Russell bodies, 203
- Saccular aneurysm, 100  
 Salivary gland tumors, 234  
*Salmonella* osteomyelitis, 187  
 Sarcoidosis, 8, 18, 129–130, 130*f*, 219, 220*f*  
 Saturnine gout, 377  
 Schaumann bodies, 219  
 Schiller-Duval bodies, 311  
 Schistocytes, 175, 206  
 SCID (severe combined immunodeficiency disease), 32–33  
 Sclerosing adenosis, 331*t*, 332  
 Seborrheic dermatitis, 385–386  
 Seborrheic keratosis, 381, 382*f*  
 Secondary hemochromatosis, 273  
 Secondary hemostasis  
   hemophilia A, 208  
   hemophilia B, 208  
   von Willebrand disease, 208  
 Secondary hypertension, 97  
   cardiovascular causes, 96, 96*t*  
   endocrine causes, 96, 96*t*  
   neurologic causes, 96, 96*t*  
   renal causes, 96, 96*t*  
   stress-induced causes, 96  
 Secondary Parkinsonism, 165  
 Second intention, 21

- Secondary Raynaud disease. *See* Raynaud phenomenon
- Seizures, 136–137, 349  
     absence, 137  
     epilepsy, 136–137
- Semilobar holoprosencephaly, 141
- Seminoma, 311, 311*f*
- Senile (neuritic) plaques, 162, 163*f*
- Septic shock, 89–90  
     superantigen, 90
- Sequestration crises, 187
- Sequestrum, 365
- Serous inflammation, 17
- Serous ovarian tumors, 324, 324*f*–325*f*
- Severe combined immunodeficiency disease (SCID), 32–33
- Sex chromosome abnormalities, 67–68
- Sexual differentiation disorders, 68–69
- Sézary syndrome, 202
- Shagreen patch, 58
- Sheehan syndrome, 340
- Shock  
     anaphylactic, 90  
     cardiogenic, 89, 118, 118*f*  
     complications of  
         corticomedullary hemorrhage, 91  
         diffuse alveolar damage, 90  
         gastric petechial hemorrhage, acute, 91, 91*f*  
         global hypoxic-ischemic encephalopathy, 90, 90*f*  
         necrosis  
             acute tubular, 90–91  
             centrilobular, 90, 90*f*  
             subendocardial contraction band, 90  
     hypovolemic, 89  
     neurogenic, 90  
     septic, 89–90  
     stages of, 91
- SIADH. *See* Syndrome of inappropriate antidiuretic hormone
- Sickle cell anemia, 186–187, 186*f*, 300
- Sideroblastic anemia, 178
- SIDS (sudden infant death syndrome), 77
- Signet-ring cell adenocarcinoma, 244, 245*f*
- Simple renal cysts, 302
- Sipple syndrome, 358–359
- Sjögren syndrome, 30, 202
- Skeletal muscle disorders  
     inclusion body myositis, 171  
     Lambert-Eaton syndrome, 171–172  
     myasthenia gravis, 171  
     polymyositis, dermatomyositis, 170
- Skin. *See* Dermatopathology
- SLE. *See* Systemic lupus erythematosus
- SLL (small lymphocytic lymphoma), 192, 200
- SMAD, 44
- Small cell carcinoma, 227–228, 229*f*
- Small lymphocytic lymphoma (SLL), 192, 200
- Smudge cells, 193
- Spermatocytic seminoma, 313
- Spherocytes, 175, 186
- Spina bifida, 139–140
- Spina bifida occulta, 139
- Spinal muscular atrophy, 166
- Splenomegaly, 195, 267
- Spongiform encephalopathies, 155–156
- Squamous cell carcinoma  
     cervix, 316–317  
     cutaneous, 382–383  
     esophageal, 239–240  
     larynx, 230  
     oral cavity, 234  
     penis, 313  
     pulmonary, 226, 227*f*
- Squamous intraepithelial lesion, 316–317
- Stable angina, 113–114, 114*f*
- Stab wound, 50
- Stage of tumor, 46
- Staghorn calculi, 301, 301*f*
- Staphylococcus aureus*, 59, 203, 222, 224, 293, 317, 388
- Steatorrhea, 248–249
- Steatosis, 9, 9*f*  
     macrovesicular, 262  
     microvesicular, 262
- Stein-Leventhal syndrome, 323
- STEMI (ST segment elevation myocardial infarct), 116–117, 116*f*
- Stenosis  
     aortic, 112, 125–126  
     mitral, 127
- Stenotic, regurgitant valvular disease, 125
- Stevens-Johnson syndrome, 384, 384*f*
- Stillbirth, 326
- Streptococcus pneumoniae*, 151–152, 152*f*, 203, 222–223, 293, 297, 317, 388
- Stroke, 142
- Struma ovarii, 344
- Struvite stones, 301, 301*f*
- Sturge-Weber syndrome, 358
- Subacute combined degeneration, 179
- Subacute thyroiditis, 346–347
- Subarachnoid hemorrhage, 148, 150*f*
- Subdural hemorrhage, 146–147, 149*f*
- Subendocardial contraction band necrosis, 90
- Subependymal giant cell astrocytoma, 58, 58*f*
- Subpial sparing, 145*f*
- Sudden infant death syndrome (SIDS), 77
- Superior vena cava syndrome, 228
- Superoxide dismutase, 4
- Sydenham chorea, 124, 124*t*
- Syndrome of inappropriate antidiuretic hormone (SIADH), 40, 286, 341–342
- Syphilis, 76
- Syphilitic aortitis, 76, 100–101
- Systemic disease, cutaneous manifestations  
     ecthyma gangrenosum, 389  
     necrobiosis lipoidica, 389  
     porphyria cutanea tarda, 389  
     pyoderma gangrenosum, 389



- Systemic hypertension, 2*f*, 96  
 complications of  
   aortic dissection, 98–99, 99*f*–100*f*  
   arteriolosclerosis, 98  
     hyaline, 98, 98*f*  
     hyperplastic, 98, 98*f*  
   atherosclerosis, 97  
   cardiac hypertrophy, 98  
   intracerebral hemorrhage, 98  
   retinopathy, 98  
 chronic, 97  
 eclampsia, 97, 330–331  
 gestational, 97  
 HELLP syndrome, 97, 331  
 idiopathic, 97  
 malignant, 97  
 preeclampsia, 97, 330–331  
 primary, 96  
 secondary, 96, 96*t*
- Systemic lupus erythematosus (SLE), 28–29, 131*t*, 132, 294  
 antiphospholipid antibody syndrome, 29  
 drug-induced lupus, 29  
   Libman-Sacks endocarditis, 28
- Systemic sclerosis, 30, 130
- t(8;14), 197*t*, 201  
 t(8;21), 191*t*, 193*t*, 194  
 t(9;22), 191*t*, 192, 195  
 t(15;17), 191*t*, 193*t*, 194
- Tabes dorsalis, 76
- Takayasu arteritis, 103–104, 103*t*, 104*f*
- Tamm-Horsfall protein, 298
- Target cells, 175
- Tay-Sachs disease, 63
- TB. *See* Tuberculosis; *Tuberculous entries*
- Telomerase, 11
- Temporal arteritis. *See* Giant cell arteritis
- Teratoma, 76*f*, 312  
   immature, 312  
   mature, 312  
   mature cystic, 325–326, 327*f*
- Testicular neoplasms, 309–310  
   choriocarcinoma, 312, 312*f*  
   embryonal carcinoma, 311  
   germ cell tumors, 310, 310*t*  
   intratubular germ cell neoplasia, 311  
   lymphoma, 313  
   seminoma, 311, 311*f*  
   spermatocytic seminoma, 313  
   teratoma, 312  
   yolk sac tumor, 311, 311*f*
- Tetralogy of Fallot, 110
- TGF- $\beta$  (transforming growth factor  $\beta$ ), 44
- Thalassemias, 176*t*, 177–178, 178*f*  
   major, 177  
   minor, 177
- Thin basement membrane disease, 196
- Thromboangiitis obliterans, 103*t*, 105
- Thrombotic thrombocytopenic purpura (TTP), 185, 206
- Thrombus 85–86, 86*f*  
   fates of thrombi, 85  
   hereditary conditions  
     factor V Leiden mutation, 85  
     prothrombin gene mutation, 85  
   predispositions, 85
- Thymoma, 181, 181*f*
- Thyroid disorders  
   Graves disease, 344, 344*f*, 400, 416  
   hyperthyroidism, 343–344, 343*t*  
   hypothyroidism, 343*t*, 345–346, 346*f*  
   neoplasms, 347–349, 347*f*–349*f*  
     anaplastic carcinoma, 349, 349*f*  
     follicular adenoma/carcinoma, 347–348, 348*f*  
     medullary thyroid carcinoma, 348–349, 349*f*, 359–360  
     papillary thyroid carcinoma, 347, 347*f*  
   thyroiditis, 346–347  
   thyroid storm, 344
- Tophi, 376, 376*f*
- Torsion of testis, 313
- Toxemia of pregnancy, 97, 330–331
- Toxic epidermal necrolysis, 385, 385*f*
- Toxic megacolon, 233
- Toxic substances  
   carbon monoxide, 49, 49*f*  
   cigarette smoke, 47  
   cocaine, 48  
   cyanide, 49  
   ethanol, 48, 271–272, 271*f*–272*f*  
     Korsakoff syndrome, 48  
     Wernicke encephalopathy, 48, 48*f*  
   ionizing radiation, REM exposure, 49–50  
   lead, 49
- Tracheoesophageal fistula, 72
- Tram-track, 294
- Transcalvarial herniation, 139
- Transforming growth factor- $\beta$  (TGF- $\beta$ ), 44
- Transient ischemic attack, 142
- Transitional cell carcinoma. *See* Urothelial neoplasm
- Transmigration, 15
- Transplantation disorders, rejection of  
   cellular, 26, 26*f*  
   chronic, 26  
   humoral, 26  
   hyperacute, 26
- Transudate, 83, 229
- Tricuspid atresia, 110–111
- Trisomy 13. *See* Patau syndrome
- Trisomy 18. *See* Edward syndrome
- Trisomy 21. *See* Down syndrome
- Tropical sprue, 249
- Troponin I, 117
- Trousseau sign, 350
- Trousseau syndrome, 281
- True hermaphrodite, 68
- Truncus arteriosus, 111
- TTP (thrombotic thrombocytopenic purpura), 185, 206

- Tuberculosis, pulmonary, 225, 226*t*  
 Tuberculous meningitis, 152–153, 153*f*  
 Tuberculous osteomyelitis, 365  
 Tuberos sclerosi, 58, 58*f*  
 Tubulointerstitial disease, 296–297  
   acute, 297  
   acute interstitial nephritis 297, 297*f*  
   acute tubular necrosis, 90–91, 298, 298*f*  
   chronic, 297–298  
 Tumor lysis syndrome, 201  
 Turner syndrome, 67, 67*f*, 318, 346  
 22q11.2 deletion, 66–67  
   DiGeorge syndrome, 66  
   velocardiofacial syndrome, 66  
 Two-hit hypothesis, 43
- Ulcerative colitis, 250*t*, 252–253, 252*f*, 389  
 Uncal (transtentorial) herniation, 139, 139*f*  
 Unstable angina, 113–115, 115*f*  
 Upper respiratory tract disorders, 230  
 Uremia, 131, 131*f*, 131*t*, 285–286  
 Ureter obstruction, 305  
 Uric acid stones, 301  
 Urothelial neoplasm, 304–305, 304*f*–305*f*  
 Urticaria. *See* Hives  
 Usual interstitial pneumonia, 219–220  
 Uterine disorders  
   bleeding, abnormal, 320  
   fibroids, 322–323, 323*f*  
   nonneoplastic, 319–321, 319*f*–321*f*  
   tumors, 321–323, 322*f*, 323*f*  
     endometrial adenocarcinoma, 321–322, 322*f*  
     endometrial stromal sarcoma, 323  
     leiomyoma, 322, 323*f*  
     leiomyosarcoma, 323  
     neoplasms, other, 323
- Vacuolar myelopathy, 34  
 Vaginal adenosis, 316  
 Vaginal tumors, 316  
 Valvular disease  
   aortic, 125–127, 125*f*–126*f*  
   general, 122–125, 122*f*–125*f*  
   mitral, 127–128, 128*f*  
   stenotic, regurgitant, 125  
 Variant angina, 115  
 Varicocele, 313  
 Vascular disorders, 93  
   aneurysms, 100–101, 100*f*–101*f*  
   aortic dissection, 98–99, 99*f*–100*f*  
   arteriosclerosis, 93  
   arteriovenous fistula, 101  
   atherosclerosis, 93–95, 94*f*–95*f*  
   ischemic bowel disease, 253–254, 253*f*  
   malformations  
     arteriovenous malformation, 141  
     capillary angioma, 142  
     cavernous angioma, 142  
     pulmonary hypertension, 99–100  
     Raynaud phenomenon, 107  
     systemic hypertension, 96–99, 96*t*, 98*f*–100*f*  
   tumors  
     angiosarcoma, 107  
     hemangioma, 106  
     Kaposi sarcoma, 106–107  
   vasculitis, 102–106, 103*f*–104*f*, 103*t*  
 Vasculitides, major, 102, 103*t*  
   Buerger disease, 103*t*, 105  
   Churg-Strauss syndrome, 106  
   giant cell arteritis (temporal arteritis), 103, 103*f*–104*f*, 103*t*  
   Kawasaki disease, 103*t*, 105  
   microscopic polyarteritis, 105  
   polyarteritis nodosa, 103*t*, 104, 104*f*  
   Takayasu arteritis, 103–104, 103*t*, 104*f*  
   Wegener granulomatosis, 103*t*, 104–105  
 Vasculitis  
   ANCA-mediated, 102  
   direct antibody interaction-mediated, 102  
   immune complex deposition-mediated, 102  
   major vasculitides. *See* Vasculitides, major  
 Velocardiofacial syndrome, 66  
 Veno-occlusive disease of the liver, 275  
 Venous infarct, 88  
 Ventricular septal defect (VSD), 110–111, 111*f*  
 Verrucae vulgaris, 388  
 Vertigo, 136  
 VHL syndrome. *See* von Hippel-Lindau syndrome  
 Viral hepatitis, 268*f*–269*f*, 269–270, 269*t*, 270*f*  
 Viral meningitis, 151–153  
 Virchow node, 228  
 Virchow triad, 85  
 Vitamin deficiencies, 52, 52*t*, 179–180, 180*t*  
   B<sub>1</sub> (thiamine), 52  
   B<sub>2</sub> (riboflavin), 52  
   B<sub>3</sub> (niacin), 52  
   B<sub>6</sub> (pyridoxine), 52  
   B<sub>12</sub>, 52, 179–180, 180*f*, 180*t*  
   folate, 52, 180, 180*f*, 180*t*  
   vitamin A, 52, 52*t*  
   vitamin C, 52*t*, 53  
   vitamin D, 52*t*, 53  
   vitamin E, 52*t*, 53  
   vitamin K, 52*t*, 53, 53*f*  
 Vitiligo, 379  
 Volume disorders, 286  
 Vulvulus, 253, 253*f*  
 von Gierke disease, 63  
 von Hippel-Lindau (VHL syndrome), 41*t*, 44, 57, 304  
 von Willebrand disease, 208  
 VSD (ventricular septal defect), 110–111, 111*f*
- WAGR syndrome, 79  
 Waldenström macroglobulinemia, 204  
 Wallerian degeneration, 169  
 Waterhouse-Friderichsen syndrome, 152, 357, 357*f*  
 Wegener granulomatosis, 102, 103*t*, 104–105

- Wermer syndrome, 359
- Werner syndrome, 11
- Wernicke aphasia, 135
- Wernicke encephalopathy, 48, 48*f*, 52
- Werdnig-Hoffmann disease, 166
- Wet beriberi, 52, 52*t*, 121
- Whipple disease, 253
- White (anemic) infarct, 88, 88*f*
- White blood cell disorders. *See* Hematopathology
- Wilms tumor, 79, 79*f*
  - Beckwith-Wiedemann syndrome, 80
  - Denys-Drash syndrome, 80
  - WAGR syndrome, 79
- Wilson disease, 61, 273, 276
  - Kayser-Fleischer rings, 61
- Wiskott-Aldrich syndrome, 33
- Woltman sign, 345
- Wound, incised, 50
- Xanthogranulomatous pyelonephritis, 300, 301*f*
- Xeroderma pigmentosa, 41*t*
- X-linked agammaglobulinemia of Bruton, 31–32
- X-linked inheritance patterns, 64–65
- Yolk sac tumor, 311, 311*f*
- Zellballen pattern, 359
- Zenker diverticulum, 239
- Zollinger-Ellison syndrome, 243